

Traumatic Dislocations of the Hip in Athletes: A Case Report and Review of the Literature

Tara M Connelly, Paul O'Grady

Tara M Connelly, Division of Trauma and Orthopaedic Surgery, Mayo General Hospital, Castlebar, Co Mayo, Ireland

Paul O'Grady, Division of Trauma and Orthopaedic Surgery, Mayo General Hospital, Castlebar, Co Mayo, Ireland

Correspondence to: Paul O'Grady, MCh, FRSCI, FRCS (Tr & Orth), Division of Trauma and Orthopaedic Surgery, Mayo General Hospital, Castlebar, Co Mayo, Ireland

Email: paul.ogrady@hse.ie

Telephone: +353-94-9044453 Fax: +353-94-9044958

Received: April 29, 2015 Revised: June 12, 2015

Accepted: June 18, 2015

Published online: August 23, 2015

ABSTRACT

AIM: High velocity athletic injuries account for approximately 5% of adult traumatic hip dislocations (TDHs). The aims of this literature review and case study are to highlight the presentation, pathophysiology and treatment of TDH in athletes and to propose a management algorithm.

MATERIALS AND METHODS: A Pubmed search using keywords 'Traumatic hip dislocation,' 'hip injury in athletes' and 'sporting injury' was performed. Each manuscript was individually reviewed. For all cases of TDH secondary to athletic injury, patient presentation, treatment and outcome were recorded. A case of athletics associated TDH from our institution is described.

RESULTS: 55 cases of athletics associated TDH were identified in the literature (82% male, 84% posterior). 54.5 % were sustained in snowboarding, 16.4% in skiing, 14.5% in football, 7.3% in rugby and 1.8% in basketball, skating, gymnastics and tennis. A concomitant femoral or acetabular fracture was demonstrated in 16 and 9 patients respectively. Two sustained a sciatic nerve injury. Conservative closed hip reduction was successful in 100% of cases

attempted. We present a case of a 31 year old female who sustained a TDH playing Gaelic football treated with closed reduction.

CONCLUSION: TDH from sporting injury is a relatively rare, commonly isolated injury that is amenable to closed reduction in the majority of cases. We report the first documented case of traumatic hip dislocation in Gaelic football and propose a management algorithm.

© 2015 The Authors. Published by ACT Publishing Group Ltd.

Key words: Traumatic hip dislocation; Athletic injury; TDH; Hip injury; Sports

Connelly TM, O'Grady P. Traumatic Dislocations of the Hip in Athletes: A Case Report and Review of the Literature. *International Journal of Orthopaedics* 2015; 2(4): 373-378 Available from: URL: <http://www.ghrnet.org/index.php/ijo/article/view/1186>

INTRODUCTION

Sports associated hip injuries are relatively uncommon and account for approximately 2.5% of soccer, 1% of basketball, 2% of rugby and 1.5% of karate injuries^[1]. These injuries are amongst the most debilitating and cause the longest delay in return to sport^[2]. Traumatic dislocation of the hip (TDH) is one of the most severe types of hip injury. Due to the anatomical configuration of the hip joint, namely, a deep socket made deeper by the labrum and a fibrous capsule and a network of ligaments and muscles such as the ischiofemoral ligament, significant force is typically required to dislocate the femoral head. Therefore, the most common mechanism for TDH is road traffic accidents (RTAs) followed by falls. However, in 2-17% of cases, TDH can also occur as the result of a sporting injury with high energy tackles in rugby, American football and soccer and falls

in basketball, skiing and snowboarding reported mechanisms^[3-8]. The majority of TDH literature is based on data from RTAs and falls and treatment is guided by this literature. In the following literature review and case study, we aim to highlight the presentation, pathophysiology and treatment of TDH in athletes and to propose a management algorithm.

MATERIALS

A Pubmed search using keywords ‘traumatic hip dislocation,’ ‘hip injury in athletes’ and ‘sporting injury’ was performed. Each manuscript was individually reviewed. For all cases of TDH secondary to athletic injury, presentation, treatment and outcome were recorded. A case of athletic associated TDH from our institution is described.

RESULTS

Fifteen manuscripts describing TDHs resulting from sporting injury were identified (Table 1). One of the 15 manuscripts provided data on incidence only^[4]. In another reporting results from a study on sciatic nerve injury and time to reduction, over 100 TDHs were described. Fifteen were related to skiing or snowboarding. However, details on the outcomes of these 15 patients were not provided separately^[9]. Matsumoto provided details on mechanism and associated injuries in

38 skiing and snowboarding associated TDHs; however, no details on outcome were provided^[4].

In the literature, TDH was described in 55 individuals and was found predominately in men (45 of 55, 81.8%). Mean age at injury was 29.9 years of age (range 13-50 years). The majority were sustained in snowboarding and skiing (*n*=30 and 9 respectively), followed by football (*n*=8), rugby (*n*=4) and basketball, gymnastics, speeding staking and tennis (all with 1 reported case each). The majority were posterior in nature (46 of 55, 83.6%). Sixteen patients also sustained a concomitant femoral fracture. A posterior acetabular wall fracture was found in nine patients. Three of these nine had other documented hip injuries (2=femoral fractures, 1=ileo-femoral ligament tear). Two patients sustained a sciatic nerve injury. Interestingly, no case described in the literature sustained any other non-hip related trauma with the exception of one partial ipsilateral anterior cruciate ligament (ACL) tear in a rugby player^[10]. Details on the type of reduction performed were available for 17 patients. Ten underwent successful closed reduction only (3 under a general anaesthetic, 4 under sedation, 3 unknown). Seven underwent closed reduction followed by ORIF. All were successfully reduced using closed methods and the subsequent operative intervention was required to address other pathology (ie acetabular or femoral fracture). One patient experienced subsequent avascular necrosis.

Table 1 Cases of TDH in Athletes. GA=general anaesthetic, ORIF=open reduction internal fixation, AVN=avascular necrosis.

| Number of Patients (Age) Gender | Sport | Anterior or Posterior | Mechanism | Associated Injuries | Treatment | Outcome | Ref |
|---------------------------------|------------|-----------------------|---|--|---|---|-------------------------------------|
| 1 (age 22) male | Basketball | Posterior | Jumping | Deep peroneal branch of sciatic nerve (foot drop) | Closed reduction within 2 hours | Common peroneal palsy persisted for approximately 6 months | Tennent et al ^[11] |
| 1 (age 28) male | Football | Posterior | Tackled from behind | Posterior wall fracture | Closed reduction within 6 hours followed by ORIF of posterior acetabulum | 1 year, pain free, short musculoskeletal function assessment score of 5 | Giza et al ^[12] |
| 1 (age 41) female | Football | Posterior | Fell forward with hip in internal rotation | Posterior wall fracture | Closed reduction within 4 hours followed by ORIF of posterior acetabulum | 1 year pain free, short musculoskeletal function assessment score of 9 | |
| 1 (age 17) male | Football | Posterior | Tackled from behind | Sciatic nerve involvement | Closed reduction under conscious sedation | Returned to play on football team the following year | Yates et al ^[13] |
| 1 (age 28) male | Rugby | Posterior | Player fell on his lower back while he was prone | Comminuted fracture of posterior superior acetabular rim | Closed reduction under GA | Satisfactory | Newton et al ^[14] |
| 1 (age 38) male | Football | Anterior | Kicking the ball | Ileofemoral ligament rupture | Closed reduction under GA within 2 hours | Return to football after 6 months | Schuh et al ^[15] |
| 1 (age 13) female | Gymnastics | Posterior | Landed on an angulated springboard | Posterior wall fracture | Closed reduction under GA followed by ORIF for posterior wall fracture | Returned to light sporting activities within 6 months. | Mitchell et al ^[16] |
| 1 (age 28) male | Rugby | Posterior | Opponent fell on player when his hip was in flexion and adduction | Posterior wall fracture with loose fragments | Closed reduction under GA within 4 hours followed by ORIF for acetabular injury | Return to rugby at 12 months | Venkatachalam et al ^[17] |
| 1 (age 31) male | Rugby | Posterior | Opponent fell on his left leg forcing abduction | Ipsilateral ACL injury | Closed reduction under conscious sedation in Emergency Department | Not provided | Croft et al ^[10] |
| 1 (age 34) male | Rugby | Posterior | Tackle with a forced landing on a flexed knee | Displaced fragment of the posterior acetabular wall | Closed reduction under GA within 3 h of admission. ORIF Acetabulum | Return to non contact sport after 9 months. | Giannoudis et al ^[1] |

Table 1 Cases of TDH in Athletes. GA=general anaesthetic, ORIF=open reduction internal fixation, AVN=avascular necrosis.

| Number of Patients (Age) Gender | Sport | Anterior or Posterior | Mechanism | Associated Injuries | Treatment | Outcome | Ref |
|-------------------------------------|--------------------------|-------------------------------|--------------------------------------|--|--|---|--------------------------------|
| 30 (age 17-28) 28 male/2 f | Snowboarding | 3 Anterior/27 Posterior | Falls (18), jumps (9), collisions(3) | Femoral neck fracture (2) Pipkin 1 femoral head fracture (7) Pipkin II (1) Pipkin IV (1) Sciatic nerve palsy | Not provided | Not provided | Matsumoto et al ^[4] |
| 8 (age 18-31) 4 males/ 4 females | Skiing | 5 Anterior/3 Posterior | Falls (6), jumps (2) | Femoral neck fracture (1) Pipkin 1 femoral head fracture (1) Not given | | | |
| 1 (age 26) female | Tennis | Posterior | Slip while running | No other injury or fracture | Closed reduction under sedation (Allis') | Returned to 'normal activities' in 6 months | Turkmen et al ^[18] |
| 1 (age 50) male | Indoor football (futsal) | Posterior | Stepped on the ball | Femoral head fracture (Pipkin 1) | Closed reduction within 6 hours ORIF of the femoral head with screw fixation | | |
| 1 (age 22) male | Indoor football (futsal) | Posterior | Twisted leg when tackling | Posterior wall acetabular fracture (Pipkin IV) femoral head fracture | Reduced under sedation ORIF femoral head | Not provided | Yasin et al ^[19] |
| 1 (age 35) male | Soccer | Posterior | Jump for ball and subsequent fall | Posterior wall fracture | Closed reduction within 6 hours ORIF of fracture | Movement was 'normal and painless' at 6 months | Nahas et al ^[20] |
| 1 (age 27) male | Soccer | Posterior | Unknown | Fracture acetabular rim, ruptured ileofemoral ligament, tear | Closed reduction | Re-dislocation approx. 1 year post injury | |
| 1 (age 27) male | Speed skating | Posterior | Unknown | Posterior capsule rupture | Closed reduction | Has resumed sporting activity to pre injury level | Stiris et al ^[21] |
| 1 (age 42) female | Skiing | Posterior | Unknown | None | Closed reduction | AVN diagnosed 2 years post injury | |

CASE REPORT

A 31 year old female was struck by another player when her feet were immobilised in mud whilst playing Gaelic football. Gaelic football is not dissimilar to rugby or football. The ball is kicked, carried, passed or punched across a pitch at speed to score points in the opposing team's goal^[22]. At the moment of impact, her knee was in flexion. Immediately after the collision, she complained of pain and the inability to weight bear. On examination, her right leg was shortened and internally rotated. She was immediately brought to the Emergency Department by on site paramedics. Posterior TDH of the right hip was confirmed by xray (Figure 1A). The TDH was reduced under sedation and skin traction was applied post reduction (Figure 1B). No fracture of the acetabulum or femur was identified on CT scan. Traction was removed five days post injury. She was mobilised during physiotherapy and returned to work after eight weeks and Gaelic football 6 months following injury.

DISCUSSION

In the above literature review, the demographics, mechanisms and outcomes of sports associated TDHs are highlighted. The majority of sports associated TDHs were found in males and in high speed or high impact sports. Our case is unusual as it involves a female athlete and an impact at a relatively lower speed. Like the majority of sports associated TDHs, a posterior dislocation was found and, as a result of lack of concomitant injuries, closed reduction was successfully

performed without the need for open surgery.

In our literature review, several differences between TDHs that are sports associated vs TDHs resulting from other aetiologies such as RTAs or falls are demonstrated. Inability to perform or failure of closed reduction requiring conversion to open reduction is documented in up to 15% of TDHs of other aetiologies^[7,23-24]; however, interestingly, no cases of failed closed reduction in athletics associated TDHs were found in the literature. Although seven patients required surgery, all intervention was to address other associated hip injuries not the dislocation itself. Additionally, no case of a sports associated TDH with concomitant abdominal, thoracic, head, upper limb or contralateral limb injury has been reported in the literature to date. This is in contrast to TDHs resulting from RTAs and falls, which commonly present with multiple injuries, often of significance. These observations suggest that sports associated TDH is appropriately treated with closed reduction under conscious sedation if possible.

During TDH, the hip is typically in flexion and adduction, as in a seated passenger who strikes his or her knee on the dashboard during a high velocity RTA or in a mechanism similar to that demonstrated in our case. In athletes, documented actions and positions associated with TDH include a fall onto a knee when the hip is flexed, following an impact from another player when the player is down on hands and knees and when the internally rotated and flexed hip is forced into a pivot^[12]. Two main forms of dislocation are found. In a posterior dislocation, the head of the femur is displaced posteriorly behind the

acetabulum. In comparison, in an anterior dislocation, the head of the femur is forced in front of the acetabulum^[13]. The majority of cases in the literature are of posterior dislocation.

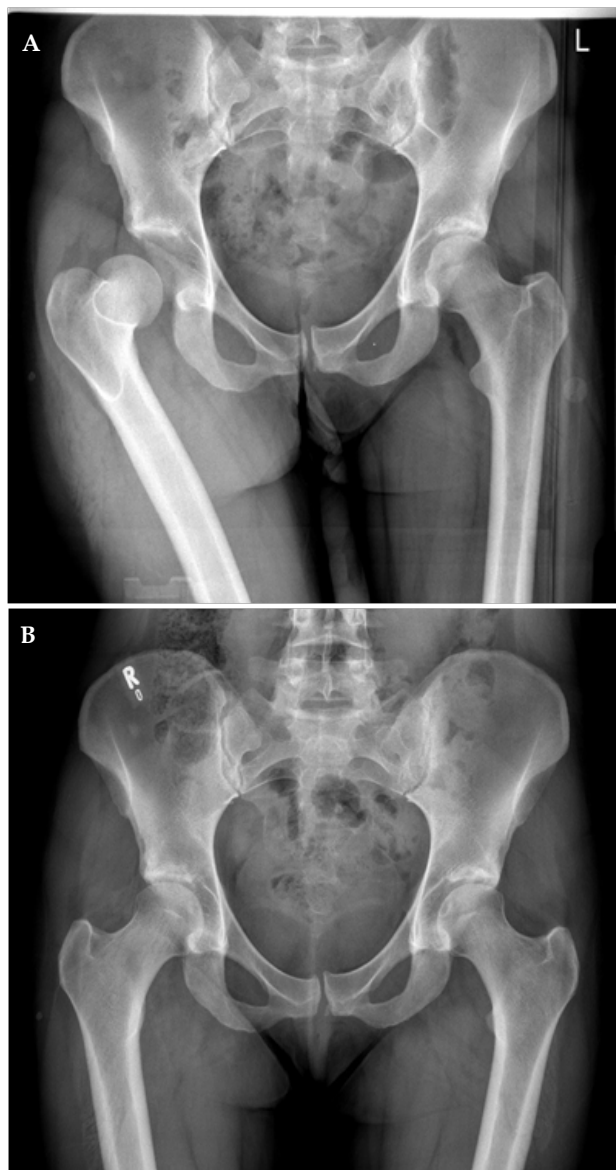


Figure 1 Pre and post reduction pelvic xrays of a 31 year old female who sustained a posterior traumatic hip dislocation without other injury whilst playing Gaelic football. X-ray after closed reduction (B) confirms concentric reduction.

As demonstrated in the literature review, TDH can be found with or without a concomitant acetabular or femoral fracture. Several grading systems have been developed, all of which account for the presence of these associated injuries. The most commonly used systems are the Levin (anterior or posterior dislocation), Stewart-Milford (posterior dislocation), Pipkin (posterior dislocation with femoral head fracture) and Thompson-Epstein (posterior dislocation) (Table 2). Our case was a Grade 1 dislocation in all scoring systems.

Complications of TDH include sciatic nerve injury, traumatic osteoarthritis (OA, in up to 25% of patients 2-10 years post injury)^[23,26] and avascular necrosis (AVN, in up to 50%)^[26]. Sciatic nerve damage may be caused by compression of the nerve by the dislocated femoral head or by traction on the nerve during reduction^[27]. Risk is increased in the presence of a femoral fracture^[7]. The rate of sciatic nerve damage in the athletic TDHs in our review (3.6%) is lower than that demonstrated in TDHs of all aetiologies (>5%)^[8,23,26,29,30]. A 2003 study of TDH (17% of which were sports associated, namely skiing or snowboarding) suggested that increased time to relocation or transfer to a second facility prior to reduction is associated with a higher risk of sciatic nerve damage. This could be due to the nature of the associated injuries which delayed the time to reduction rather than the time itself^[9]. The femoral artery is also at risk in anterior dislocations. If damaged, emergency treatment is required. However, this has not yet been reported in the sports literature. The potential for venous thromboembolism is also present due to the immobility, trauma and stasis found in TDH. Similarly, this has not been reported in an athletics associated TDH to date^[29]. OA may occur due to trauma to the cartilage during both the dislocation and the reduction^[6]. AVN is more commonly caused by obstruction and spasm of the vessels supplying the femoral head through stretching, tearing or thrombosis while the hip is in the dislocated position rather than disruption of these vessels^[7]. This supports the paradigm that shorter time to relocation decreases risk^[26]. In fact, Hougaard *et al* report a 4.8% incidence of AVN in patients with posterior TDH reduced within 6 hours in a study of 98 patients with traumatic hip dislocations followed for a minimum of 5 years. The rate rose to greater than 50% in those with a reduction more than 6 hours after the injury^[24].

Mechanism of injury should be considered during the diagnosis of a TDH. A shortened, painful limb and the inability to weight bear, as in our case, are characteristic. In the presence of a posterior dislocation, the leg is shortened and can be internally rotated, adducted and/or flexed. In cases of anterior dislocation, the limb may be abducted and internally rotated. Buttock and adductor spasm may also be present^[29]. Due to the high rate of concomitant hip and femur injury demonstrated in our literature review, we recommend

Table 2 Classification Systems for Hip Dislocation.

| | Levin classification for Anterior or Posterior Dislocations ^[25] | Stewart-Milford Classification for Posterior Dislocations ^[26] | Thompson-Epstein Classification for Posterior Dislocations ^[27] | Pipkin Classification for Posterior Dislocation + Femoral Head Fractures ^[28] |
|-----------|---|--|--|--|
| Grade I | Stable, no fracture | Dislocation +/- insignificant chip fracture of the acetabular ring | Dislocation +/- minor fracture | Dislocation + femoral head fracture caudad to the fovea capitis femoris |
| Grade II | Irreducible, no fracture | Dislocation +/- rim fragments that do not compromise stability after reduction | Dislocation + single large fracture of posterior acetabular ring | Dislocation + femoral head fracture cephalad to the fovea capitis femoris |
| Grade III | Unstable after reduction and/or incarcerated fragments | Dislocation +/- acetabular blast fragments and instability after reduction | Dislocation + comminuted rim fracture +/- large fragment | I or II + fractured neck of femur |
| Grade IV | Acetabular fracture requiring repair | Dislocation + fracture neck or head of femur | Dislocation + acetabular floor fracture | I or II + fractured acetabular rim |
| Grade V | Femoral neck or head fracture | NA | Dislocation + femoral head fracture | NA |

that any patient with a suspected hip fracture or dislocation should have an xray of the hip performed as a matter of urgency. No attempt should be made to 'reduce' a hip injury until a fracture is ruled out radiologically. It is the opinion of the authors that attempted 'blind' reduction maneuvers of a hip may displace undiagnosed fractures and increase the risk of avascular necrosis. Plain radiographs should be taken in two planes and treatment should be directed following interpretation of these xrays. CT may be a useful adjunct to xrays in determining the presence of a femoral or acetabular fracture. MRI can detect avascular necrosis and/or cartilaginous injury that may result from a dislocation. Prior to reduction, a thorough neurovascular exam should be performed. Reduction should focus on avoiding further cartilage damage when placing the head back into the acetabulum. Several methods can be used. Among the most commonly used is the Allis technique. This entails a gentle flexion of the hip from 60-90 degrees. A modified Allis where a gentle traction is applied laterally to the proximal femur while the pelvis and non-affected leg are held stable, allows the head to slip back into the acetabulum. Alternatively, for posterior dislocations, the Whistler technique may be used. The knee of the affected leg is flexed to 120 degrees is firmly grasped by the physician who is standing on the affected side passing his or her arm under the affected knee. When the pelvis is stabilised and the physician raises his or her arm, the femur is forced forward into place. After reduction, the neurovascular exam should be repeated and documented and the X-ray repeated to confirm concentric reduction. A suggested algorithm is presented in figure 2.

The majority of outcomes studies on closed reduction in TDH do not separate the results by mechanism of injury (ie RTA vs fall vs athletic injury) and are comprised mainly of TDHs resulting from RTAs. Outcome is dependent upon several factors, of which the most consistently demonstrated is time to reduction. In a retrospective study of 58 posterior dislocations followed up for a minimum of 24 months (of which 57 patients underwent initial closed reduction within a mean time of 7 hours, followed by traction), complications included OA in 5 patients, residual painful hip in 8 and osteonecrosis in two. Complications were higher in those who underwent traction for 3 weeks (8 of 14) vs those who were maintained in traction for 4 weeks (4 of 22). However, only 3 patients in this cohort had a sports

related injury and their outcomes are not reported separately^[7]. In a large early study of 194 dislocations of which 90 were treated non-surgically, outcome as measured by hip function was better in those without an associated fracture or a small acetabular chip vs those with greater acetabular damage or femoral fractures. Outcome was also better in those who were reduced within 12 hours vs 24 vs 48 vs ≥49, regardless of other associated injury to the joint. No patient who was reduced after 24 hours experienced a good functional outcome. AVN was seen in 15% of those treated nonsurgically with a mean time to onset of 17 months. Forty nine percent of those treated with closed reduction vs 72% of those treated with surgery developed OA. However, this may be due to the severity of the injury^[26]. Dreinhofer et al studied 50 patients with conservatively treated TDHs without associated fractures, reduced within 3 hours (48 of which were reduced by a physician at the scene of the accident) and followed for a minimum of 2 years^[8]. Objective and reported subjective clinical measures demonstrated good functional outcomes in 55% and 74% of patients respectively. Time to reduction did not affect OA or AVN. Of these 50 patients, 1 had a skiing accident, 1 was biking and 1 was sledging. Their results were not reported separately. Outcomes may be slightly different in the presence of a concomitant fracture. Chen et al performed a small randomised control trial on patients with non sports associated posterior dislocations with Pipkin type 1 fractures reduced within 12 hours all followed for at least 2 years. Eight patients were treated conservatively with closed reduction and traction for 6 weeks. Eight were initially treated conservatively followed by surgical excision of fragments. Heterotrophic ossification was 4 times more likely in the surgical group. Using Thompson and Epstein and Merle d'Aubigne scores, the surgical group's functional outcome was demonstrated to be better than the closed reduction group. The only 2 cases of AVN were found in the conservatively treated group^[31]. No consensus regarding care after closed reduction of TDH is in place. However, the majority of studies report the use of traction post reduction. A detailed physiotherapy regimen including ortosis for neuropraxia and pool based exercises for non-weight bearing rehabilitation has been described by Yates *et al* in their case study of a 17 year old football player post closed reduction^[13].

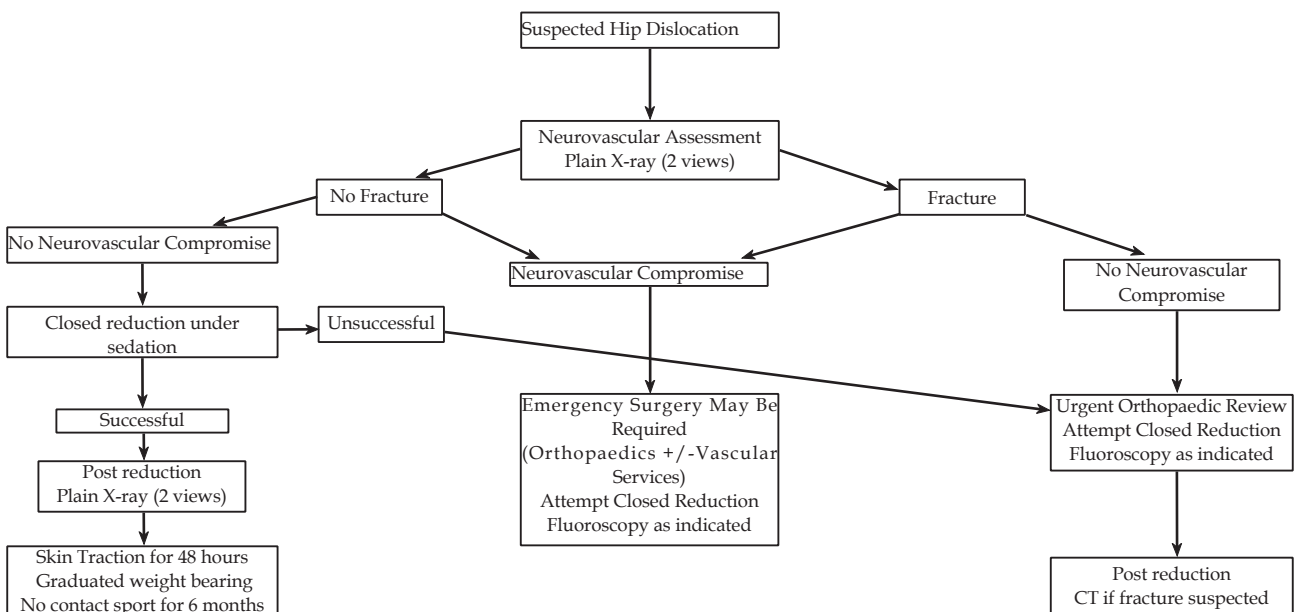


Figure 2 Suggested Treatment Algorithm for Posterior Hip Dislocation.

LIMITATIONS

Due to the variation in the literature and methods of studies cited, this review has a few limitations. The longest follow up in any study was two years. Therefore, the true incidence of OA or AVN and long term outcomes in this patient population cannot be extrapolated. Additionally, various measures of outcome from survey to validated classifications were used precluding a uniform conclusion on functional or clinical outcome. Only one study utilised MRI to determine ligamentous and/or cartilaginous damage. It is very likely that the incidence would be higher if all studies used MRI evaluation of ligaments. The lack of outcome details on the majority of anterior dislocations leads to the inability to compare both types of dislocations accurately in this review.

CONCLUSION

TDHs involving athletics differ from those sustained in RTAs in several ways. The velocity of the impact is less than that of an RTA. Patients are almost exclusively under 40 years old and otherwise healthy. Often, the athletic TDH injury is isolated to the hip as compared to the associated head, abdominal, multi-limb injuries commonly found in RTA and falls patients. We present a literature review of sports injuries resulting in a TDH. We also present what we believe is the first case of a female who has sustained TDH playing Gaelic football and have suggested treatment algorithm for the treatment of these injuries.

CONFLICT OF INTERESTS

There are no conflicts of interest with regard to the present study.

REFERENCES

- 1 Giannoudis P, Zelle A, Kamath R et al. Posterior Fracture-Dislocation of the Hip in Sports Case Report and Review of the Literature. *European J of Trauma.* 2003;6:399-402.
- 2 Kujala U, Taimela S, Antti-Poika I, Acute injuries in soccer, ice hockey, volleyball, basketball, judo, and karate. Analysis of national registry data. *BMJ* 1995;31:465-1468.
- 3 Wong P and Hong Y. Soccer injury in the lower extremities. *Br J Sports Med.* 2005;39:473-482.
- 4 Matsumoto, K, Sumi H, Sumi Y, et al. An analysis of hip dislocations among snowboarders and skiers: a 10-year prospective study from 1992 to 2002. *J Trauma.* 2003;5:946-8.
- 5 Chudik S, Allen A, Lopez V et al. Hip dislocations in athletes *Sports Medicine and Arthroscopy Review.* 2002;10:123-133.
- 6 Sahin, V, Karakas W, Aksu S et al. Traumatic Dislocation and Fracture-Dislocation of the Hip: A Long-Term Follow-Up Study. *J Trauma.* 2003;54:520-529.
- 7 Al-Bahlool A, Bubshait D and Sadat-Ali M. Outcome of traumatic hip dislocation. *Turkish J of Trauma & Emerg Surgery.* 2009;15:463-466.
- 8 Dreinhofer, K, Schwarzkopf S, Haas N et al. Isolated traumatic dislocation of the hip: Long-term results in 50 patients. *J Bone Joint Surg (Br).* 1994;76:B6-12.
- 9 Hillyard R and Fox J. Sciatic nerve injuries associated with

traumatic posterior hip dislocations. *Am J of Emerg Medicine.* 2003;21:545-548.

- 10 Croft S, Brenchley J, Badhe S et al. An unusual rugby injury. *Emerg Med J.* 2006;23:e40
- 11 Tennent T, Chamblor A and Rossouw D. Posterior dislocation of the hip while playing basketball. *Case Reports.* 1998; 342-343
- 12 Giza E. Hip Fracture-dislocation in football: A Report of 2 cases and a review of the literature. *Br J Sports Med.* 2004;38:e17.
- 13 Yates C, Bandy W and Blaiser R. Traumatic Dislocation of the HIP IN A high school football player. *Phys Ther.* 2008;88:780-788.
- 14 Newton R and du Plessis M. An unusual presentation of a traumatic hip dislocation. *BMJ Case Rep.* 2014. 1-2.
- 15 Schuh A, Doleschal S and Schmickal T. Anterior dislocation in a football player: a case report. *Case reports in medicine* 2009; 2009:1-3.
- 16 Mitchell J, Giannoudis V, Millner P. A rare fracture-dislocation of the hip in a gymnast and review of the literature. *Br J Sports Med* 1999;33:283-284.
- 17 Venkatachalam S, Heidari N and Greer T. Traumatic fracture-dislocation following a rugby tackle. *Sports Medicine, Arthroscopy, Rehabilitation, Therapy and Technology.* 2009;1:28.
- 18 Turkmen I, Turkmensoy F, Ozkan K et al. An unusual hip dislocation during tennis playing. *IJCRI.* 2013;4:532-535.
- 19 Yasin FN and Singh VA. Can posterior hip fracture- dislocation occur in indoor football (futsal)? A report of two cases. *BMJ Case Rep.* 2009;2009: bcr12.2008.1317
- 20 Nahas R, Netto E, Chikude T et al. Traumatic hip fracture-dislocation in soccer: a case report. *Rev Bras Med Esporte.* 2007;13:253e-255e.
- 21 Stiris, M. MR imaging after sports-induced hip dislocations. Report of three cases. *Acta Radiol.* 2000;41:300-302.
- 22 Crowley J, Jordan J, Falvey E et al. A comparison of Gaelic football injuries in males and females in primary care. *Ir Med J.* 2011;104:268-70.
- 23 Sanders S, Tejwani N, Ego K et al. Traumatic Hip Dislocation: A review. *Bulletin of the NYU Hospital for joint diseases.* 2010;68:91-96.
- 24 Hougaard K and Thomsen P. Traumatic posterior dislocation of the hip —Prognostic factors influencing the incidence of avascular necrosis of the femoral head. *Archives of Orthopaedic and Traumatic Surgery.* 1986;106:32-35.
- 25 Levin P. Hip Dislocations. In Browner B, Jupiter J, Levine A eds. *Skeletal Trauma.* Philadelphia. WB Saunders. 1992. 1329-67.
- 26 Stewart M and Milford. Fracture-Dislocation of the hip. *The J of Bone and Joint Surgery.* 1954;36:315-342.
- 27 Epstein HC. Traumatic dislocations of the hip. *Clin Orthop.* 1973;92:116-142.
- 28 Pipkin G (1957) Treatment of grade IV fracture-dislocation of the hip. *J Bone Joint Surg.* 1957; 39-A:1027-1042.
- 29 Pallia C. Traumatic hip dislocation in athletes. *Competitive sports and pain management.* 2002; 338-335.
- 30 Cornwall, R. Nerve injury in traumatic dislocation of the hip. *Clin Orthop Relat Res.* 2000;377:84-91.
- 31 Chen Z, Zhai W, Guo Z et al. Conservative versus surgical management of Pipkin type I fractures associated with posterior dislocation of the hip: a randomised controlled trial. *International Orthopaedics (SICOT).* 2011;35:1077-1081.

Peer reviewer: Luigi Sabatini, University of Turin, Italy.