

The Achilles Tendinopathy: Pathogenesis Review

Manuel Bondi, Nicola Rossi, Bruno Magnan, Lodovico Renzi Brivio

Manuel Bondi, Nicola Rossi, Lodovico Renzi Brivio, Department of Orthopaedics and Traumatology, Carlo Poma Hospital, Strada Lago Paiolo 10, 46100 Mantova, Italy

Bruno Magnan, Department of Orthopaedic and Traumatology, University of Verona (Italy), Surgical Center "P. Confortini", Piazzale A. Stefani 1, 37126 Verona, Italy

Correspondence to: Manuel Bondi, MD, Department of Orthopaedics and Traumatology, Carlo Poma Hospital, Strada Lago Paiolo 10, 46100 Mantova, Italy.

Email: bondimanuel@gmail.com

Telephone: +390376201606

Received: December 21, 2014

Revised: January 18, 2015

Accepted: January 21, 2015

Published online: June 23, 2015

ABSTRACT

Achilles tendinopathy is a degenerative disease with high prevalence in runners. For the comprehension of achilles tendinopathy we have to consider intrinsic conditions such as age, sex, BMI, tendon temperature, systemic diseases, flexibility, previous injuries and anatomical variations, genetic predisposition and blood supply and extrinsic factors such as drugs and overuse. Both categories can be responsible for development of achilles' degenerative tendinopathy. Different hypothesis were studied, those concerning the pathogenesis of tendinopathy and those concerning the etiology of complaints in patients. This review of the literature demonstrates the heterogeneity of Achilles tendinopathy pathogenesis.

© 2015 ACT. All rights reserved.

Key words: Achilles tendinopathy; Achilles pathogenesis; Achilles tendon; Tendon degeneration; Tendinopathy

Bondi M, Rossi N, Magnan B, Renzi Brivio L. The Achilles Tendinopathy: Pathogenesis Review. *International Journal of Orthopaedics* 2015; 2(3): 289-299 Available from: URL: <http://www.ghrnet.org/index.php/ijo/article/view/1256>

INTRODUCTION

Pathology of the Achilles tendon is a common source of posterior ankle and heel pain.

The Achilles tendon is prone to load injuries if compared to other tendons in the body^[1,2]. The incidence of overuse injury in sports has risen enormously as a result of the increased duration and intensity of training^[3-5].

Tendinitis, paratenonitis, and peritendinitis are misleading because their suffixes imply an inflammatory process. However, inflammatory cells are rarely present in biopsies from involved tendons^[6].

According to this fact, tendinopathy is the correct term to use, and it is a degenerative process characterized by disorganized collagen, abnormal neovascularization, necrosis and mucoid degeneration. The symptoms are pain, swelling and impaired performance^[7-9]. This may be worsened by external irritants, including shoe wear, or an increased activity level.

It is not always associated with excessive physical activity, and in a series of 58 patients, 31% did not participate in sports or vigorous physical activity^[10]. Furthermore, the use of some drugs is associated with Achilles tendinopathy and rupture^[11-13].

The location of the pain is an important discriminating factor, as insertional (tendon-bone junction) pain is often treated differently than non-insertional (2 to 6 cm proximal to the insertion) pain.

Insertional Achilles tendinopathy is typically associated with a prominent posterolateral calcaneal tuberosity (Haglund's prominence) and/or radiographically apparent calcification at the tendon's insertion that is the tendinopathy chronic stage^[14].

Although the Achilles tendon experiences such high mechanical loads, the tendon exhibits biomechanical properties that are similar to those of other tendons, increasing the risk for failure and injury^[2]. Overuse from repetitive loading, overloading, and natural aging may lead to Achilles tendon injuries, including tendinitis, tendinosis, and tendon rupture^[15], but the etiology and pathogenesis have not yet been scientifically clarified. Many different explanations have been raised and consequently the range of conservative and surgical treatment options is actually very wide^[16].

With this review we explain the different hypothesis formulated

concerning the pathogenesis of tendinopathy and the etiology of complaint in patients.

BACKGROUND

Anatomy and Histology of the Achilles tendon

The Achilles tendon is the largest and strongest tendon in the human body, measuring approximately 15 cm in length with an average thickness of 6 mm; it results from the combination of aponeurosis of soleus and gastrocnemius muscles and ends onto the calcaneus^[17]. Medial to the Achilles tendon the Plantaris one is located^[16]: the two tendons are collectively surrounded by the paratenon^[18]. It is richly vascularized: blood supply of the Achilles tendon essentially derives from the anterior side of the paratenon. The arteries involved in the Achilles tendon vascularization are: a. tibialis posterior, that gives the largest contribution, a. peroneal, with a small participation of a. tibialis anterior's collaterals^[19]. Blood supply allows to distinguish three different portions in the tendon, one proximal and one distal, that are both perfused by the a. tibialis posterior, and a middle-portion perfused by the a. peroneal. Several studies demonstrate that the middle-portion is less vascularized than the others^[20]: it is approximately located 4-5 cm proximal to the calcaneal insertion; in addition, the tendon vascularity diminishes with age^[17]. The Achilles tendon derives its innervation from the nerves of the attaching muscles and cutaneous nerves, in particular the sural nerve with a smaller supply from the tibial nerve^[21]. It is well known that the number of nerves and nerve endings is relatively low, and the tendon proper is relatively aneuronal^[16]. Just anterior to the Achilles tendon, proximal to the point of insertion, lies the retrocalcaneal bursa and over it there is the pre-Achilles fat also called "Kager's fat pad", a triangular mass of adipose tissue; located posteriorly and caudally between the tendon and the underlying skin there is another bursa^[17]. Histologically tendons are composed by cellular elements and extracellular matrix^[21]: tenocytes (specialized fibrocytes) and tenoblasts comprise 90-95% of the cellular elements of the tendon, with chondrocytes, vascular cells, synovial cells and smooth muscle cells forming the remaining 5-10%; collagen and elastin form the major part of the extracellular matrix: in healthy tendons, 95% of the collagen is type I^[17]. Ultrastructurally, tendons have a hierarchy of fibrillar arrangement that is sequentially composed of collagen molecules, fibrils, fibers, fascicles (or fiber bundles), and the tendon unit. The tendon units are surrounded by epitenon, which functions to reduce friction with adjacent tissues. Such a hierarchical structure aligns all structural levels parallel to the long axis of the tendon, making it ideal for carrying and transmitting large tensile mechanical loads^[22].

Biomechanics

Tendons are stiff and resilient, with high tensile strength: it depends on their cross sectional area and length, but also on their metabolic properties^[23]. From a functional perspective, it is possible to distinguish between two types of tendons, depending on the main course of a muscle and its tendon^[24]: traction and gliding tendons. Gliding tendons (e.g. tibialis posterior tendon) change direction by turning around a bony or fibrous hypomochlion; in traction tendons instead the origin and the insertion are in line with the muscle (e.g. the tendon of coracobrachialis muscle). The biomechanical behavior of gliding tendons is fundamentally different from a traction tendon where only tension forces exist; in the contact area between a gliding tendon and the pulley there are strong compressive forces decreasing continuously towards the periphery,

while the tensional forces are at their maximum at the outer part of the gliding area and decrease towards the contact area^[24]. The overlapping of pressure and tension in the transition zone results in shear stress. The Achilles tendon, under mechanical aspects, is a traction tendon, but its structure doesn't correspond to a traction tendon: gastrocnemius and soleus fibres rotate as they descend to the calcaneal insertion (from anterior to medial the soleus fibres, from posterior to lateral the gastrocnemius ones): such spiralization, the so-called "twisting", confers a mechanical advantage to the tendon but produces an area of concentrated stress where the rotation becomes more marked (approximately 2-7 cm proximal to the insertion onto the calcaneus^[17]); this region is also named Achilles tendon waist^[25]: like the waist of a wasp it is reduced in diameter and, as already mentioned, many studies reveal a hypovascularized area in the tendon waist^[20] that should be considered an adaptation to the mechanical function and not a sign of degeneration (according to the theory of "causal histogenesis" by Pauwels^[24]). The structure, composition and organization of the matrix of tendons are critically important for their physical properties. It has been demonstrated that when longitudinal sections are viewed under polarized light, tendon at rest shows a wavy configuration from crimping of its collagen fibrils, but such kind of configuration is lost when tendon is stretched more than 2%. Collagen fibres exhibit a linear response to increasing strain as collagen fibres deform, being able to regain the normal wavy appearance if the strain exerted on them is less than 4%; so tendons can stretch up to 4% before damage^[26]. Physiological loads usually cause less than a 4% increase in length of the tendon^[27]. Strain above 4% results in damage to one or more of the tendon fibre bundles while strains in excess of 8-12% result in complete tendon rupture. However, also microstrains below the failure threshold can damage the tendon, when repeated in time (overuse) (Figure 1).

Tendon healing process

Tendon healing occurs in three overlapping phases^[28,29]. The acute inflammatory phase lasts from 3 to 7 days after injury and the process starts with a hematoma where erythrocytes and inflammatory cells, particularly neutrophils, enter the site of injury. In the first 24 hours,

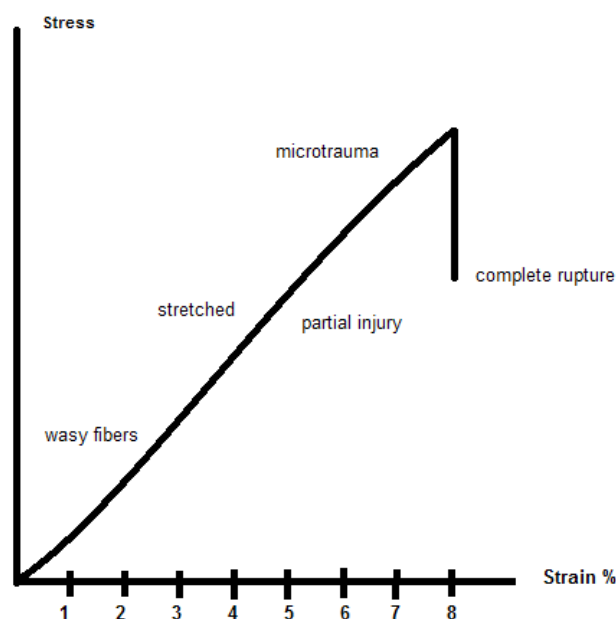


Figure 1 Tendon stretching capacity.

monocytes and macrophages predominate, and phagocytosis of necrotic material occurs. Then the proliferation phase begins and lasts from 5 to 21 days: vasoactive and chemotactic factors are released, leading to increased vascular permeability, angiogenesis, stimulation of tenocytes proliferation and type III collagen synthesis; exogenous fibroblasts gradually migrate to the wound and predominate over endogenous ones, determining tissue adhesion to the repair site. The last phase is the maturation and remodeling phase and it can last for up to one year; the cross-linking among collagen fibres increases and the tensile strength, elasticity and structure are improved. Despite remodeling, the biomechanical properties of healed tendon tissue never match those of intact tendon.

ETIOLOGY OF INTRATENDINOUS DEGENERATIVE CHANGES

Intratendinous changes can be caused by intrinsic or extrinsic factors, the combination of which is responsible for chronic tendinopathy onset and development^[30].

Intrinsic risk factors

Age: The most affected age group is from third to fifth decade; aging causes changes in tendon matrix: we observe decreased cellularity, increased glycosaminoglycan content, lack of fiber organization. There is no significant change in the total collagen concentration and type I collagen remains the predominant one, but the distribution of minor collagens (such as type III) may change, with a greater proportion incorporated into the type I fibers^[31]. Collagen fiber bundles tend to become larger and the tendon become stiffer and less elastic^[32]. These changes are all associated with deterioration in the physical properties of the tendon. In-fact, even if some tendons may be unaffected^[33], there is often evidence of accumulated physical damage in ageing tendons, with increases in the amount of denaturated collagen and increased proteolytic cleavage of matrix components^[34]. The effect of ageing on mechanical properties could be due to reduced arterial blood flow, local hypoxia, free radical production, impaired metabolism and nutrition, and advanced glycation end products (AGEs)^[35,36]; such AGEs result from condensation of glucose and amino groups, best observed in diabetic patients^[37]. Because the turnover of matrix proteins is generally very low, AGEs accumulate gradually with age^[27]. It has been shown in diabetes that high amounts of AGEs cause a fusion of collagen fibrils, which become larger in diameter^[28]; AGEs also up-regulate connective tissue growth factor in fibroblasts causing the formation of fibrosis over time^[38,39]. Moreover, glycated tendons can withstand more load and tensile stress than non-glycated ones, but the tissue becomes stiffer^[40]. Also skeletal maturity has been shown to play a major role in the biomechanical properties of tendon and ligaments, because of the development at their insertions^[41]. Studies on animal models show that the stiffness in skeletally mature groups are higher than skeletally immature animals^[25,42]. In conclusion, it must be kept in mind that even if age-related changes are reported, tendinopathy is not an age-related degeneration because similar pathological changes are observed in young people^[43].

Sex: Also if we observe higher incidence of tendon overuse injuries in males, we have to consider the differences in physical activity, so it's difficult to evaluate gender as an independent etiological factor. The proportion of women interested in sports, including those that have a high risk of overuse injuries, has increased during the past few decades^[44] and, for example, it is reported that female cyclists suffer a higher risk for overuse injury in general than their male

counterpart^[45]. Gender-specific differences have been reported for ligaments, that especially in women may cause excessive joint laxity, while for tendons data are somewhat inconclusive^[46,47]. In monkeys, for example, endogenous estrogen does not affect the mechanical or material properties of the patellar tendon^[48]. Menopause in the absence of hormone therapy has been associated with a decrease in quantity of collagen I, compromising the tensile strength^[49]. Another report found a significant association of hormone replacement therapy and oral contraceptives with Achilles tendinopathy, supporting the importance of their effects on microcirculation^[46,50]. Recently a study suggested that the ability of the Achilles tendon to adapt in response to loading such as running is attenuated in women^[51]; another one showed that symptomatic females suffering Achilles tendinopathy do not benefit as much as symptomatic males from eccentric training^[52]. A recent paper stated that male gender and age are not significant risk factors for development of Achilles tendon tendinopathy^[53].

Body Weight: Obesity lead people to reduce physical activity: lack of training with loss of muscular compensation or forefoot disorders favor overuse problems^[54].

Tendon temperature: Another factor that might predispose avascular tissue for degeneration is its poor capability to regulate the tissue temperature. Exercise increases the temperature of the tendons, when we can't control hyperthermia we can have a cellular damage. Measurements of intratendinous temperature from superficial digital flexorum tendon of exercising horses have showed pick of 43-45°C^[55] where temperatures above 42,5°C result in fibroblast death *in vitro*^[40]. Although short periods at 45°C are unlikely to result in tenocyte death, repeated hyperthermic insults and prolonged durations of exposure may compromise cell viability and produce tendon degeneration^[55,56].

Systemic Diseases: Many systemic diseases are associated with general defects in matrix metabolism and structure that compromise tendon strength and elasticity or result in inflammation of the tendon or its insertion^[27,30,57-60]. These conditions must be considered as part of the differential diagnosis. We can have Inherited disorders (Homocystinuria –Ochronosis-, Aspartylglycosaminuria, Menkes kinky hair syndrome, Marfan syndrome), Endocrine and metabolic diseases (Diabetes mellitus, Adrenal disorders, Thyroid and parathyroid disorders) or Rheumatological diseases (Rheumatoid arthritis Reactive arthritis and Reiter's syndrome).

Previous injuries and Anatomical variants: malalignment: For a better understanding, it must be mentioned the gait cycle^[17]. The gait cycle of each leg could be divided into two phases: the stance phase and the swing phase. During the stance phase the foot is in contact with the ground; during the swing phase the foot is off the ground and swinging forward. The stance phase can be additionally subdivided into three component phases: contact (supination), midstance (pronation) and propulsion. During the midstance phase, the foot pronates. Such pronation leads to an internal rotation force on the tibia and activation of the triceps surae muscle that results in a tensile force, leading to plantar flexion of the foot and an overall inversion moment. With the foot pronated and the knee extended this inversion contributes to an increased stress across the Achilles tendon (considering that at the end of the stance phase in normal walking, muscle tension through the Achilles tendon is estimated at 250% of body weight). The tendon can be exposed to increased forces secondary to malalignment of the lower extremity (such as leg-length discrepancy, genu valgum, hyperpronated foot, cavus foot). Malalignment is proposed to increase forefoot pronation, limit mobility of the subtalar joint, decrease/increase the range of motion of the ankle, lead to varus deformity of the forefoot and increase hind

foot inversion and impingement; all these factors and others such as muscle weakness, decreased flexibility, joint laxity or stiffness, independently or together, may affect the way the Achilles tendon is loaded^[28,61].

Blood Supply: Tendons and ligaments have 7.5 times lower oxygen consumption compared with skeletal muscle^[62]. The low metabolic rate and well developed anaerobic energy generation capacity are essential to carry loads and maintain tension for long periods, reducing the risk of ischemia and subsequent necrosis^[29]. The development and maintenance of hypo- or avascular tissues is based on the inhibition of angiogenesis that could be get either by production of an inhibitory factor or by a reduction of the angiogenesis factor: both was seen to work in tendons^[24]. Many factors control angiogenesis, one of the most important is the vascular endothelial growth factor (VEGF). High concentration of VEGF proteins are detectable in fetal tendons, while in tendon of adults VEGF expression is normally largely downregulated^[63]. In-fact, in adult tendons, the anti-angiogenesis factor endostatin is expressed, especially in those areas exposed to higher stress^[64]. Endostatin is a proteolytic fragment of collagen type XVIII with strong anti-angiogenic potency^[65]: it inhibits proliferation and migration of endothelial cells abolishing VEGF signal transduction. This is the reason why the hypovascularization derives from stress. Despite this, many studies have shown that degenerative tendon disorders mainly develop in the region where the tendon has a poor or no blood supply: poor vascularization or avascularity are believed either directly to decrease tensile strength or indirectly to weaken the tendon through degenerative changes, hence increasing the likelihood of rupture (hypothesis of hypovascularization)^[28,66-71]. They are suggested to be important risk factors also for chronic tendinopathy (high intratendinous lactate levels, indicating ischemic conditions, where found in chronic Achilles tendinosis^[72]) especially in the way they influence tendons' metabolism and healing mechanisms. In-fact, recovery processes in hypovascularized tissue are slower, so stress forces act before complete healing^[24] and the tendinosis cycle starts. Deepening the mechanisms with which ischemia could damage tendons, it has been demonstrated that when a tendon is under maximal tensile load, ischemia occurs^[29], and then, upon relaxation, reperfusion occurs, generating oxygen free radicals^[73] that may result in damage to the tendon. However, recently was demonstrated a correlation between hypoxia and VEGF production: in vitro studies with isolated tenocytes from rat Achilles tendons have shown that hypoxia is an important inducer of VEGF expression^[30,63]. In order to understand what this correlation between hypoxia and VEGF increasing consists in, it must be firstly remembered that oxygen tension plays a key role in regulating the expression of various genes; among them there is, for example, the well-known erythropoietin (Epo) gene: low oxygen tension stimulates Epo-gene expression to increase new red cells production. But, how exactly does oxygen tension act its regulation role? The answer is in the presence of the hypoxia inducible factor 1 (HIF-1) binding site within the Epo gene^[24]. Interestingly, a base sequence identified in the 5' promoter of the rat and human VEGF gene reveals a high degree of homology and similarity in protein binding characteristics with the HIF-1 binding site: hypoxemic stimulus induces VEGF gene expression^[24,74]. It is well known that digestion of extracellular matrix must precede sprouting of new vessels and their invasion^[75]. Members of the matrix metalloproteinase (MMP) superfamily, are important regulators of extracellular matrix remodeling^[76]. Degenerative tendons present high levels of MMPs^[6,54] and low levels of tissue inhibitor of metalloproteinase (TIMP): factors that regulate

enzymes activities in tendon are consequently likely to have a role in tendinopathy; among them there are cytokines and growth factors^[27]. Hypoxia condition determines tendon weakening: VEGF up-regulate MMPs production and down-regulates TIMP^[24,28,77-80] while favoring tissue invasion by new vessels: this is the core of the pathogenetic role of tendon hypervascularization. Recently was demonstrated that hypoxia increases collagen type III synthesis at the expense of type I; such phenotypical change in the extracellular matrix is detrimental since the greater is the content in collagen type III, the lower is the resistance of tendon to tensile forces^[81], when neovascularization occurs, producing further weakening of the tendon, the risk of rupture is amplified. In conclusion, tendinopathy, that time ago was considered caused by hypoxia, has nowadays been related to hypervascularization.

Genetic predisposition of tendinopathy: Among the intrinsic factors many are complex phenotypes determined by an interaction between genetic and environmental factors: examples are body weight and height, biologic age, muscles' strength, tendons' flexibility^[82]. Since 2005 genetic association studies have been employed to establish the identity of risk variants for Achilles tendon injuries^[83]. The range of genes taken into consideration is wide open: it includes genes codifying for proteins involved in the structural or regulatory integrity of tendon or the extracellular matrix or genes codifying for substances found to be expressed in an anomalous way thanks to microdialytic techniques^[82]. A recent work, moreover, demonstrates that polygenic profiling of a complex phenotype like Achilles tendinopathy maybe a superior strategy to use, compared to the single candidate approach, when it comes to understanding the intricate involvement of numerous variants that increase the risk of Achilles tendon problems^[84]. Nowadays, the results indicate that the genetic contribution for tendon injuries is polygenic and that several biological pathways are involved^[85,86].

Extrinsic risk factors

Drugs: The use of several drugs has been associated with tendinopathy: the association has been proved for fluoroquinolone antibiotics, such as ciprofloxacin. This may be because fluoroquinolones interact with cytokines leading to enhanced interleukin-1 mediated matrix metalloproteinase 3 (MMP3) release, causing reduced cells proliferation and collagen extracellular matrix synthesis^[87]. For other drugs held liable for tendon rupture (statins^[88], oral contraceptives, locally injected steroids^[89]) debate remains open. For what concern corticosteroids injections there are several case reports^[90,91] of tendon rupture after their use in patients while animal studies have shown that they lead to a reduction in tendon strength^[92], but these findings are not universal and there is a lack of good-quality research data to support their use in tendinopathy^[93]. Non-steroidal anti-inflammatory drugs (NSAIDs) are shown to modulate tendon cell proliferation, the expression of extracellular matrix components and degenerative enzymes^[94,95]. As their use is common for sport-related symptoms, it is possible that they contribute to the development of tendinopathy^[96].

Training errors, Environmental Conditions, Shoes, Equipment, Surfaces and Physical activity/Sport: Excessive distance, too high intensity, too much up- or down-hill work, too fast progression, erroneous running technique or monotonous and specialized training, such as running only, are thought to be significantly related to Achilles tendon injuries; environmental conditions such as too high or low temperature or humidity, slippery or hard running surfaces, particularly with faulty footwear and equipment, too^[28]. Athletes performing sport activities that include running or jumping are those

more susceptible to develop Achilles tendinopathy, even though it has also been demonstrated in physically inactive individuals^[8]. Direct measurements of forces reveal loading in the Achilles tendon as high as 9 KN during running, which is up to 12.5 times body weight^[21]. Excessive loading of tendons during physical activity is regarded as the main pathological stimulus for degeneration^[3]: it could be either due to one abnormal loading cycle of high strain or a series of lower subfailure strains^[41]. In-fact, it must be kept in mind that tendon damage may even occur from stresses within physiological limits, as frequent cumulative microtrauma may not allow enough time for repair^[3]. Microtrauma can also result from a non-uniform stress within tendons, producing abnormal load concentrations on the fibrils, resulting in localized fibre damage and increased loading of the remainder^[97]. When a repetitive strain acts on the affected tendon, so that it can no longer endure stress and tension, we can by definition talk about overuse; overuse can be considered as the initial disease factor as it leads to the expression of several molecules, some of which (such as growth factors) promote the healing process, while others (such as inflammatory cytokines) act as disease mediators^[28]. Among the disease mediators, for example, it has been observed that repetitive mechanical stretching increases prostaglandin E2 (PGE2) concentrations in human patellar tendon fibroblasts^[98]. PGE2 is a potent inhibitor of type I collagen synthesis and it has recently been shown that it has catabolic effects on tendon structure, decreasing proliferation and collagen production in human patellar tendon fibroblasts^[99]. Other mediators of inflammation and vascular perfusion were found to be stimulated by exercise, such as bradykinin, adenosine, interleukin-6 and thromboxane^[100]. These findings seem to be in contradiction with the histological pattern (tendinosis) that characterizes chronic tendinopathy, which is dominated by degeneration, with either absent or minimal inflammation^[101]. Nowadays, however, it is conceivable that inflammation and degeneration are not mutually exclusive: tendons respond to repetitive overload beyond physiological threshold by either inflammation of their sheath, degeneration of their body, or a combination of both^[102,103]; inflammation has been shown to play its role mainly in early human tendinopathy, while in the late phase of tendinopathy degeneration gradually occurs. Over time, possibly due to the lack of blood vessels within the tendon, instead of a chemical, a neurogenic inflammatory process takes place^[104,105].

The “neurogenic hypothesis”

Substance P and other neuropeptides have been detected in tendon and in fluids collected from around painful tendons^[104,105]. Substance P has been shown to modulate the expression of several tendon matrix genes and enzymes (in rabbit models^[106]), possibly causing some of the morphologic changes in Achilles tendinopathy. These findings support the “neurogenic hypothesis” of tendon overuse injury^[27]: neuropeptides or calcitonin gene-related peptide (CGRP) induce mast cells degranulation changing matrix environment and cell activities. Besides the mechanism involved, it has already been mentioned that the alteration of tendon matrix turnover has a key role. In addition, such neuropeptides (substance P, acetylcholine, catecholamines and glutamate) seems to be related to the bilateral nature of changes seen in Achilles tendinopathy; many patients present with bilateral Achilles tendinosis^[107] and many of those initially presenting unilateral symptoms develop contralateral ones over time^[108]. It has been demonstrated in the rat that unilateral training leads to bilateral changes in levels of neuropeptides in the synovial fluids^[109,110]; on the basis of these and other observation has recently been formulated the hypothesis of the “central neuronal

mechanism” as a possible explanation for the frequent bilateral involvement in Achilles tendinopathy^[30,111].

The role of nitric oxide (NO) and tendon stem cells (TSCs)

In addition to the effect on tendon matrix, overuse can act on tendon cells: tenocytes, the dominant cell population in tendons, are responsible for changes in tendons by altering extracellular matrix gene and protein expression^[22]. Mechanical overload, hypoxia, oxidative stress (caused by free radicals) are all factors thought to determine dysregulated apoptosis, probably a cause of tendinopathy^[117]. The caspase and nitric oxide (NO) pathways play a role in tendon apoptosis; the expression of caspase-8 and the enzyme that catalyses the formation NO, named nitric oxide synthase (NOS), were found to be elevated in tendinopathy^[118,119]. The nitric oxide represents a free radical molecule produced as a co-product in the reaction of L-arginine to L-citrulline: like other free radicals it could be toxic because it has unpaired electrons making it very reactive, but, interestingly, in small physiological doses, NO functions as a messenger molecule participating in various cellular processes^[120]; different isoforms of NOS have been identified: eNOS (found in endothelial cells) and bNOS (found in brain and neuronal tissue) are constitutive and important in blood pressure regulation and memory respectively; iNOS is an isoform that can be induced by proinflammatory cytokines and is important in host defense^[28]. Recent *in vitro* experiments^[19] demonstrated that NO stimulates perfusion and increases collagen synthesis from fibroblasts in degenerated tendons. It is very important to keep separate the two concepts of perfusion and neovascularization: on the one side, thanks to the perfusion, that represents the blood flow per unit of time, nutrients and oxygen are transported in the tissue and toxic molecules removed; on the other side it has already been discussed the pathogenetic role of neovascularization, which, even if it could be regarded as attempt at healing, leads at the end to tendon weakening. These findings justify the current interests to investigate the potentially beneficial role of drugs containing L-arginine alpha-chetoglutarate (AAKG), the specific precursor of NO, in Achilles tendinopathy^[74,121]. Concluding this analysis of the effects of overuse on tendons, it must be remembered that recent studies found tendon stem cells (TSCs) in human and animal tendon tissue^[122,123]. Effects on mechanical loading on TSCs have been investigated on both *in vivo* and *in vitro* models^[22,124]; findings from these studies suggest that TSCs undergo loading magnitude-dependent differentiation: under large mechanical stress TSCs differentiate into nontenocytes, such as adipocytes, chondrocyte and osteocytes^[125]. Such nontenocyte differentiation may explain the histopathological features of tendinopathy at later stages (tendinosis patterns of degeneration: hypoxic, mucoid or mixoid, hyaline, fatty, fibrinoid, calcific, or some combination of these^[58]).

ETIOLOGY OF COMPLAINT

The source of pain and the background to the pain mechanisms associated with mid-portion Achilles tendinopathy have not yet been clarified^[16]. Typically, pain was attributed to inflammation. This could be true in the early phase of tendinopathy^[126] but, since chronic tendinopathies have been shown to be mainly degenerative conditions, other causes have been proposed^[29]. Pain in patients with Achilles tendinopathy comes from surrounding tissues more than from the tendon itself: it is known that the tendon itself is relatively aneuronal and that intratendinous degenerative changes often occur without symptoms (up to 34% of asymptomatic tendons show

histopathological changes). Recent evidences show that the transition to symptomatic tendinopathy is marked by nerve and vascular proliferation, arising from the ventral/anterior side of the paratenon. Vascular ingrowth, as already said, has the aim to repair tendon's defects, but it has been found to correlate with the location of pain in patients with symptomatic tendinopathy^[127]. Neovascularization with thick walls, a tortuous appearance and small lumen ventral from the Achilles tendon and in the paratenon is found in 50-88% of symptomatic tendons but not in pain-free tendons^[128,129]; these blood vessels are accompanied by sensory neones^[130,131] causing an increase in pain signaling by producing nociceptive substances such as glutamate, substance P, calcitonin gene-related peptide (CGRP) past the critical threshold^[132,133]. Myofibroblasts proliferate and are transported by the new blood vessels into the peritendineum and the tendon proper^[16,30]. Myofibroblasts synthesise abundant amount of collagen to repair the tendon causing also the formation of scar tissue around the tendon: consequently adhesions of the paratenon onto the Achilles tendon can be found at the location of the neurovascular ingrowth. Scarring in turn may lead to impaired circulation with mechanical constriction until the obliteration of neovessels: in 20-50% of long-lasting tendinopathy patients no neovascularization is found^[128,129]. This reduction in blood flow may also be explained by the fact that pathological tendons exhibit a decreased occurrence of sympathetic nerve fibres: the reduction in vasoregulatory noradrenalin causes vasoconstriction^[105]. Nerve however will survive causing persistence of pain.

The Plantaris Longus Tendon and its relationship with the Achilles tendon

It has been described that the location of the pain in patients with Achilles tendinopathy is most often located on the medial side of the tendon^[134]. This is supported by the finding that most ultrasonographic mid-portion disorders (91%) are found in the posteromedial segment of the tendon^[131,135]. The Plantaris Longus Tendon (PLT) origins from the homonymous muscle, that can be considered a rudimental muscle in humans, absent in 7-20% of human lower limbs, and, in the majority of cases inserts medially onto the calcaneus^[136]. The PLT runs closely with and parallel to the medial side of the Achilles tendon; it is believed that in a healthy situation the two tendons can move freely in relation to each other. Now, two aspect need to be taken into consideration: the first is related to the fact that tendinopathy is often accompanied by inflammatory response of the paratenon^[28], which involves both the tendons, often leading to the formation of adhesions between them. The plantaris muscle-tendon complex is nowadays a weak ankle and knee flexor and ankle inverter, whereas the triceps surae is a flexor only. Adhesions between the plantaris and Achilles tendons obstruct the opposite forces of these two bi and triarticular muscle groups. Although the movement between the two will be limited, traction on the surrounding paratenon will take place with every step (with a mean of 5,000-12,500 steps/days in people with a low active lifestyle^[119]). Repetitive traction onto this richly innervated area might contribute to the medially located pain and stiffness during and after walking. The other aspect concerns the biomechanical properties, found to be different for the two tendons: the Plantaris Longus Tendon is a stronger, stiffer and less extensible tendon than Achilles tendon, which consequently is strained more than the PLT during activity^[137]; this statement is the basis of the "compression theory" (that even if proposed for insertional tendinopathy may be actual also for midportion tendinopathy^[138]): the mechanical properties of PLT have the potential to create repeated share stresses not only to

the peritendineous tissue, but also to the Achilles tendon itself^[139], potentially acquiring a pathogenetic role. Other structures, such as the accessory soleus muscle, another inconstant structure medial to the Achilles tendon, has been reported to be associated with chronic Achilles tendinopathy^[140,141].

DISCUSSION AND CONCLUSION

In order to prevent Achilles tendon injuries is necessary understand the pathogenesis and the role of risk factors in the genesis of degenerative tendinopathy (Figure 2). Although load is a major patho-etiological component, it is almost certainly modulated by an interaction between factors such as genes, age, circulating and local cytokine production, sex, biomechanics and body composition^[142]. The process may start with localized tendon micro-injuries, which stimulate the tissue to react with a repair process. The repair process is adequate in most cases but inadequate in patients developing tendinopathy; such inadequate repair causes a repetitive cycle of inadequate collagen and matrix production, tenocyte disruption, a further decrease in collagen and matrix and an increased vulnerability to further micro-injuries. The result is that the healing process fails and the pathogenic cascade leading to symptomatic tendinopathy occurs^[16]. Given the low metabolic rate of tendons, the optimal conditions for good healing are: adequate recovery time, absence of further overloading and suitable metabolism and blood supply. Unfavorable situations may be represented by the extrinsic and intrinsic risk factors, variously combined: this explains why subjects respond differently to overloading^[28]. Since tendon healing includes many sequential processes such as inflammation, neovascularization, neural modulation, recruitment of healing cells, proliferation, apoptosis, matrix synthesis and remodeling, tenogenic

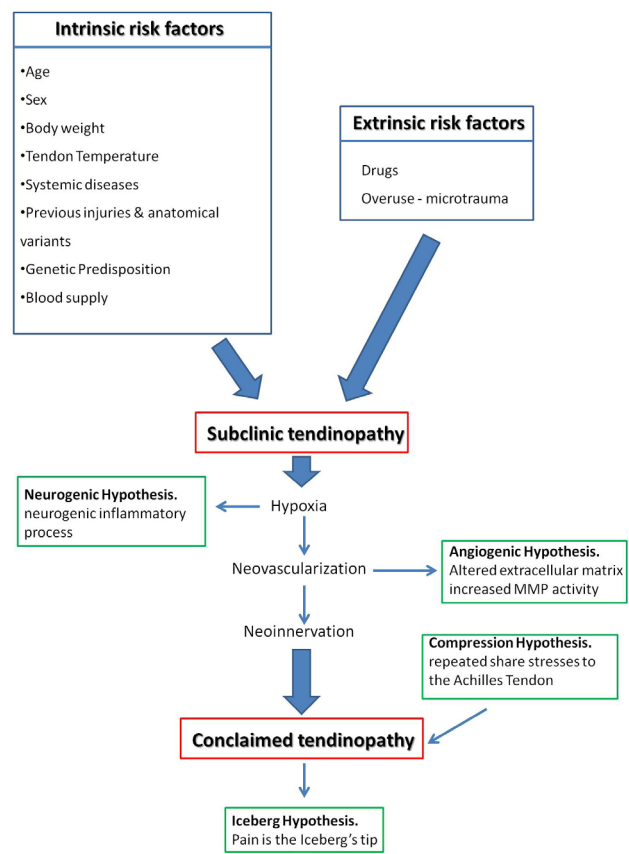


Figure 2 Algorithm of the pathogenesis of the Achilles tendinopathy.

differentiation, many of the mechanisms mentioned as possibly involved in tendinopathy pathogenesis appear now to interfere with the healing process, supporting the pathogenetic theory of “failed healing response” among the several proposed to explain chronic tendinopathy^[143-145].

However, blood supply is nowadays one of the most important factors taken into consideration either to explain tendon degeneration or to explain complaint in patients. Starting from a condition of hypovascularization, hypoxia induces the production of hypoxia inducible factor (HIF) which in turn leads to subsequent VEGF expression^[24,30,79]; the missing link between the mechanical overload induced by steady cyclic strain and the VEGF expression consists in the observation that HIF-1 is also inducible by mechanical overload: in cell culture models it has been shown that the regulatory α subunit of HIF-1 is strongly increased in tenocytes after incubation with cyclic strain^[146] (as already shown in myocardial cells^[147]). The results of the increased levels of VEGF in tendons are mainly two: on the one hand the alteration of the tendon matrix which leads to a weakening of the tendon structure; on the other hand the following nervous ingrowth that causes pain symptoms.

It was recently shown that human tendon increase in proliferation (as well as gene expression and type I collagen production) in a stretching magnitude-dependent manner^[112]; overload, on the opposite, can decrease proliferation and collagen production in human tendon fibroblasts, changing the extracellular matrix composition and even resulting in tenocytes apoptosis (programmed cell death)^[113-115]. Since tenocytes are required to maintain homeostasis of the extracellular matrix (ECM) by regulating the balance between its synthesis and degradation^[116], tenocyte apoptosis may compromise the ability of the tendon to regulate repair processes.

In order to give an organic explanation, a comprehensive pathogenetic theory was proposed^[28,30]: the pathogenesis of tendinopathy may be considered a continuum from physiology to overt clinical presentation; the sequence of events can be compared with an iceberg (the ‘iceberg’ theory), having several thresholds, pain being the tip of the iceberg while the base represents what happens under physiological conditions. In conclusion, we must keep in mind that, although loading history and individual factors may influence the onset and amount of tendon pathology, these are not generally considered when developing a treatment plan for painful tendons^[142]. The first aim in treatment of Achilles tendinopathy is to lessen pain: in the first inflammatory phase NSAIDs could be effective^[126], but they fail in the advanced ones^[148]. Pain relief thus could be obtained by the destruction of the sensory nerves that penetrate the tendon from paratenon: if pain can be relieved with denervation, extensive surgery of the tendon proper becomes redundant^[16,30].

CONFLICT OF INTERESTS

There are no conflicts of interest with regard to the present study.

REFERENCES

1. Komi, PV; Fukashiro, S; Jarvinen, M: Biomechanical loading of Achilles tendon during normal locomotion. *Clin Sports Med* 1992; 11:521 – 531.
2. Wren, TA; Yerby, SA; Beaupre, GS; Carter DR: Mechanical properties of the human Achilles tendon. *Clin Biomech* 2001; 16:245 – 251.
3. Selvanetti A, Cipolla M, Puddu, G. Overuse tendon injuries: Basic science and classification. *Oper Tech Sports Med* 1997; 5:110-17.
4. Kvist M. Achilles tendon overuse injuries. PhD thesis, University of Turku, Finland, 1991.
5. Perry J. Achilles tendon anatomy. *Foot and Ankle Clinics* 1997;2:363–70.
6. Astrom, M; Rausing, A: Chronic Achilles tendinopathy. A survey of surgical and histopathologic findings. *Clin Orthop Rel Res* 1995. 316:151– 64.
7. Kvist M. Achilles tendon injuries in athletes. *Sports Medicine* 1994; 18(3):173-201.
8. Maffulli N, Khan KM, Puddu G. Overuse tendon conditions: time to change a confusing terminology. *Arthroscopy* 1998; 14:840-843.
9. Rufai, A; Ralphs, JR; Benjamin, M: Structure and Histopathology of the Insertional Region of the Human Achilles Tendon. *J Orthop Res* 1995. 13:585 – 93.
10. Rolf C, Movin T. Etiology, histopathology, and outcome of surgery in achillodynia. *Foot Ankle Int* 1997;18:565–9.
11. Casparian JM, Luchi M, Moffat RE, Hinthorn D. Quinolones and tendon ruptures. *South Med J* 2000; 93:488–91.
12. West MB, Gow P. Ciprofloxacin, bilateral Achilles tendonitis and unilateral tendon rupture: a case report. *N Z Med J* 1998;111:18–19.
13. Royer RJ, Pierfitte C, Netter P. Features of tendon disorders with fluoroquinolones. *Therapie* 1994; 49:75–6.
14. DeOrto MJ, Easley ME. Surgical Strategies: Insertional Achilles Tendinopathy. *Foot & Ankle International* May 2008; Vol. 29, No. 5.
15. Alfredson, H; Lorentzon, R: Chronic Achilles tendinosis: recommendations for treatment and prevention. *Sports Med* 2000; 29:135 – 146.
16. Maayke N. van Sterkenburg, C. Niek van Dijk. Mid portion Achilles tendinopathy: why painful? An evidence-based philosophy; *Knee Surg Sports Traumatol Arthrosc* 2011; 19:1367-1375.
17. Pierre-Jerome C, Moncayo V, Terk MR. MRI of the Achilles tendon: A comprehensive review of the anatomy, biomechanics, and imaging of overuse tendinopathies. *Acta Radiol* 2010 May;51(4):438-54.
18. Carmont MR, Highland AM, Rochester JR, Paling EM, Davies MB. An Anatomical and radiological study of the fascia cruris and paratenon of the Achilles tendon. *Foot And Ankle Surgery* 2011; 17: 186–192.
19. Wolff KS, A.G. Wibmer, H. Binder, T. Grissmann, K. Heinrich, S. Schauer, R. Nepp, S. Rois, H. Ritschl, H. Teufelsbauer, M.L. Pretterklieber. The avascular plane of the Achilles tendon: A quantitative anatomic andangiographic approach and a base for a possible new treatment option after rupture. *European Journal of Radiology* 2012; 81:1211– 1215.
20. Chen Tony M, Warren M. Rozen, Wei-Ren Pan, Mark W. Ashton, Martin D. Richardson, G. Ian Taylor. The Arterial Anatomy of the Achilles Tendon: Anatomical Study and Clinical Implications. *Clinical Anatomy* 2009; 22:377–385.
21. Mahmut ND, Mahbub A, Murat B, Egemen T, Ozgu`r AA, Gu`rhan D, Maffulli N. Functional anatomy of the Achilles tendon. *Knee Surg Sports Traumatol Arthrosc* 2010; 18:638–643.
22. Wang James H- C., Guo Qianping, Li Bin. Tendon Biomechanics and Mechanobiology—A Minireview of Basic Concepts and Recent Advancements; *Journal of hand therapy* 2012.
23. Yamamoto E, Hayashi K, Yamamoto N. Mechanical properties of collagen fascicles from the rabbit patellar tendon. *J Biomech Eng* 1999; 121:124-131.
24. Pufe T, Petersen WJ, Mentlein R, Tillmann BN. The role of vasculature and angiogenesis for the pathogenesis of degenerative tendons disease. *Scand J Med Sci Sports* 2005; 15: 211–222.
25. Woo SL-Y, Orlando CA, Gomez MA, Frank CB, Akeson WH. Tensile properties of the medial collateral ligament as a function of age. *J Orthop Res* 1986; 4:133-141.
26. O’Brien M. The anatomy of the Achilles tendon. *Foot Ankle Clin N Am* 2005; 10:225-238.

27. Riley G. The pathogenesis of tendinopathy. A molecular perspective. Review. *Rheumatology* 2004; 43:131–142.
28. Abate M, Gravare-Silbernagel K, Siljeholm C, Di Iorio A, De Amicis D, Salini V, Werner S, Paganelli R. Pathogenesis of tendinopathies: inflammation or degeneration? Review *Arthritis Research & Therapy* 2009;11:235.
29. Sharma P, Maffulli N. Basic biology of tendon injury, *Clinical Review. Surgeon* 2005; 3: 5; 309-316.
30. Magnan B, Bondi M, Pierantoni S, Samaila E. The pathogenesis of Achilles tendinopathy: a systematic review. *Foot Ankle Surg* 2014 Sep; 20(3):154-9.
31. Riley GP, Harrall RL, Constant CR, Chard MD, Cawston TE, Hazleman BL. Tendon degeneration and chronic shoulder pain: Changes in the collagen composition of the human rotator cuff tendons in rotator cuff tendinitis. *Ann Rheum Dis* 1994; 53: 359–66.
32. Moore MJ, De Beaux A. A quantitative ultrastructural study of rat tendon from birth to maturity. *J Anat* 1987; 153:163–9.
33. Riley GP, Goddard MJ, Hazleman BL. Histopathological assessment and pathological significance of matrix degeneration in supraspinatus tendons. *Rheumatology* 2001; 40:229–30.
34. Riley GP, Curry V, DeGroot J, van El B, Verzijl N, Hazleman BL, Bank RA. Matrix metalloproteinase activities and their relationship with collagen remodelling in tendon pathology. *Matrix Bio.* 2002; 21:185–95.
35. Dalal M, Ferrucci L, Sun K, Beck J, Fried LP, Semba RD: Elevated serum advanced glycation end products and poor grip strength in older community-dwelling women. *J Gerontol A Biol Sci Med Sci* 2009; 64:132-137.
36. Langberg H, Olesen J, Skovgaard D, Kjaer M. Age related blood flow around the Achilles tendon during exercise in humans. *Eur J Appl Physiol* 2001; 84:246-248.
37. Grant WP, Sullivan R, Sonenshine DE, Adam M, Slusser JH, Carson KA, Vinik AI. Electron microscopic investigation of the effects of diabetes mellitus on the Achilles tendon. *J Foot Ankle Surg* 1997; 36:272-278.
38. Reddy GK, Stehno-Bittel L, Enwemeka CS: Glycation-induced matrix stability in the rabbit achilles tendon. *Arch Biochem Biophys* 2002; 399:174-180.
39. Twigg SM, Chen MM, Joly AH, Chakrapani SD, Tsubaki J, Kim HS, Oh Y, Rosenfeld RG. Advanced glycosylation end products up-regulate connective tissue growth factor (insulin-like growth factor-binding protein-related protein 2) in human fibroblasts: a potential mechanism for expansion of extracellular matrix in diabetes mellitus. *Endocrinology* 2001; 142: 1760-1769.
40. Batista F, Nery C, Pinzur M, Monteiro AC, de Souza EF, Felipe FH, Alcântara MC, Campos RS. Achilles tendinopathy in diabetes mellitus. *Foot Ankle Int* 2008; 29:498-501.
41. Jung Ho-Joong, Fisher Matthew B and Woo Savio L-Y. Role of biomechanics in the understanding of normal, injured, and healing ligaments and tendons Review. *Sports Medicine, Arthroscopy, Rehabilitation, Therapy & Technology* 2009;1:9.
42. Woo SL-Y, Ohland KJ, Weiss JA. Aging and sex-related changes in the biomechanical properties of the rabbit medial collateral ligament. *Mech Ageing Dev* 1990; 56:129-142.
43. Cook JL, Khan KM, Kiss ZS, Griffiths L. Patellar tendinopathy in junior basketball players: a controlled clinical and ultrasonographic study of 268 patellar tendons in players aged 14-18 years. *Scand J Med Sci Sports* 2000; 10(4):216-220.
44. Kannus P, Niittymäki S and Jarvinen M. Recent trends in women's sports injuries. *J Sports Traumatol* 1990; 3:161-167.
45. Wilber CA, Holland GJ, Madison RE, Loy SF. An epidemiological analysis of overuse injuries among recreational cyclists. *Int J Sports Med.* 1995; 16(3):201-206.
46. Holmes GB, Lin J. Etiologic factors associated with symptomatic Achilles tendinopathy. *Foot Ankle Int* 2006; 27:952–959.
47. Landry SC, McKean KA, Hubley-Kozey CL, Stanish WD, De-luzio KJ. Neuromuscular and lower limb biomechanical differences exist between male and female elite adolescent soccer players during an unanticipated side-cut maneuver. *Am J Sports Med* 2007; 35:1888–1900.
48. Wentorf FA, Sudoh K, Moses C, Arendt EA, Carlson CS. The effects of estrogen on material and mechanical properties of the intra- and extra-articular knee structures. *Am J Sports Med* 2006; 34:1948–1952.
49. Miller BF, Hansen M, Olesen JL, Schwarz P, Babraj JA, Smith K, Rennie MJ, Kjaer M. Tendon collagen synthesis at rest and after exercise in women. *J Appl Physiol* 2007; 102:541–546.
50. Moalli PA, Talarico LC, Sung VW, Klingensmith WL, Shand SH, Meyn LA, Watkins SC. Impact of menopause on collagen subtypes in the arcus tendineus fasciae pelvis. *Am J Obst Gyn* 2004; 190:620–627.
51. Westh E, Kongsgaard M, Bojsen-Moller J, Aagaard P, Hansen M, Kjaer M, Magnusson SP. Effect of habitual exercise on the structural and mechanical properties of human tendon, in vivo, in men and women. *Scand J Med Sci Sports* 2008; 18:23–30.
52. Knobloch K, Schreibleueller L, Kraemer R, Jagodzinski M, Vogt PM, Redeker J. Gender and eccentric training in Achilles mid-portion Tendinopathy. *Knee Surg Sports Traumatol Arthrosc* 2010; 18:648–655.
53. Kraemer R, Wuerfel W, Lorenzen J, Busche M, Vogt PM, Knobloch K. Analysis of hereditary and medical risk factors in Achilles tendinopathy and Achilles tendon ruptures: a matched pair analysis. *Arch Orthop Trauma Surg* 2012; 132:847-853.
54. Geyer M. Achillodynie. *Orthopade Chirurgie* 2005; 34:677-681.
55. Birch HL, Wilson AM, Goodship AE. The effect of exercise-induced localized hyperthermia on tendon cell survival. *J Exp Biol* 1997; 200: 1703–1708.
56. Arancia G, Crateri Trovalusci P, Mariutti G, Mondovi B. Ultrastructural changes induced by hyperthermia in Chinese hamster V79 fibroblasts. *Int J Hyperthermia* 1989; 5(3):341-50.
57. Abboud JA, Beason DP, Soslowky LJ. Emerging ideas: the effect of hypercholesterolemia on tendons. *Clin Orthop Relat Res* 2012 Jan;470(1):317-20.
58. Józsa L, Kannus P. Tendon alterations in endocrinologic and metabolic diseases. In: Józsa L, Kannus P, eds. *Human tendons: anatomy, physiology and pathology*. Champaign: Human Kinetics 1997; p403–12.
59. Józsa L, Kannus P. Tendon alterations in inherited diseases. In: Józsa L, Kannus P, eds. *Human tendons: anatomy, physiology and pathology*. Champaigns: Human Kinetics 1997; p390–402.
60. Józsa L, Kannus P. Tendon alterations in rheumatic diseases. In: Józsa L, Kannus P, eds. *Human tendons: anatomy, physiology and pathology*. Champaign: Human Kinetic. 1997; p412–29.
61. Mahieu NN, Witvrouw E, Stevens V, Van Tiggelen D, Roget P. Intrinsic risk factors for the development of achilles tendon overuse injury: a prospective study. *Am J Sports Med* 2006; 34:226-235.
62. Vailas AC, Tipton CM, Laughlin HL, Tchong TK, Matthes RD. Physical activity and hypophysectomy on the aerobic capacity of ligaments and tendons. *J Appl Physiol* 1978; 44(4): 542-46.
63. Pufe T, Petersen W, Tillmann B, Mentlein R. The angiogenic peptide vascular endothelial cell growth factor (VEGF) is expressed in fetal and ruptured tendons. *Virchows Arch* 2001; 439: 579–585.
64. Pufe T, Petersen W, Kurz B, Tsokos M, Tillmann B, Mentlein R. Mechanical factors influence the expression of endostatin – an inhibitor of angiogenesis – in tendons. *J Orthop Res* 2003; 21: 610–616.
65. O'Reilly MS, Behm T, Sing Y, Fikai N, Vasios G, Lane WS, Flynn E, Birkhead JR, Olsen BR, Folkman J. Endostatin: an endogenous inhibitor of angiogenesis and tumor growth. *Cell* 1997; 88: 277–285.
66. Astrom M. Laser Doppler flowmetry in the assessment of tendon blood flow. *Scand J Med Sci Sports* 2000; 10:365-7.
67. Lesic A, Bumbasirevic M. Disorders of the Achilles tendon. *Curr*

- Orthop 2004; 18:63-75.
68. Niculescu V, Matusz P. The clinical importance of the calcaneal tendon vasculature(tendocalcaneus). *Morphol Embryol (Bucur)* 1988; 34:5-8.
 69. Zantop T, Tillmann B, Petersen W. Quantitative assessment of blood vessels of the human Achilles tendon: an immunohistochemical cadaver study. *Arch Orthop Trauma Surg* 2003; 123:501-4.
 70. Alfredson H, Öberg L, Forsgren S. Is vasculo-neural ingrowth the cause of pain in chronic Achilles tendinosis? An investigation using ultrasonography and colour Doppler, immunohistochemistry, and diagnostic injections. *Knee Surg Sports Traumatol Arthrosc* 2003; 11(5):334-8.
 71. Ohberg L, Lorentzon R, Alfredson H. Neovascularisation in Achilles tendons with painful tendinosis but not in normal tendons: an ultrasonographic investigation. *Knee Surg Sports Traumatol Arthrosc* 2001 Jul;9(4):233-8.
 72. Alfredson H, Bjur D, Thorsen K, Lorentzon R, Sandstrom P. High intratendinous lactate levels in painful chronic Achilles tendinosis. An investigation using microdialysis technique. *J Orthop Res* 2002; 20: 934-938.
 73. Bestwick CS, Maffulli N. Reactive oxygen species and tendon problems: review and hypothesis. *Sports Med Arthroscopy Rev* 2000; 8:6-16.
 74. Notaricola A, Pesce V, Vicenti G, Tafuri S, Forcignanò M, Moretti B. SWAAT Study: Extracorporeal Shock Wave Therapy and Arginine Supplementation and Other Nutraceuticals for Insertional Achilles Tendinopathy. *Adv Ther* 2012; 29(9):799-814.
 75. Ferrara N. Molecular and biological properties of vascular endothelial growth factor. *J Mol Med* 1999; 77: 527-543.
 76. Nagase H, Woessner JF. Matrix metalloproteinases. *J Biol Chem* 1999; 274:21491-4.
 77. Alfredson H, Lorentzon M, Backman S, Backman A, Lerner UH. cDNA-arrays and real-time quantitative PCR techniques in the investigation of chronic Achilles tendinosis. *J Orthop Res* 2003; 21(6):970-75.
 78. Ireland D, Harrall R, Curry V, Holloway G, Hackney R, Hazleman B, Riley G. Multiple changes in gene expression in chronic human Achilles tendinopathy. *Matrix Biol* 2001; 20(3):159-69.
 79. Petersen W, Pufe T, Zantop T, Tillmann B, Tsokos M, Mentlein R. Expression of VEGFR-1 and VEGFR-2 in degenerative Achilles tendons. *Clin Orthop* 2004; 420: 286-291.
 80. Qi JH, Ebrahim Q, Moore N, Murphy G, Claesson-Welsh L, Bond M, Baker A, Anand-Apte B. A novel function for tissue inhibitor of metalloproteinases-3 (TIMP3): inhibition of angiogenesis by blockage of VEGF binding to VEGF receptor-2. *Nat Med* 2003; 9:407-415.
 81. Millar NL, James H Reilly, Shauna C Kerr, Abigail L Campbell, Kevin J Little, William J Leach, Brian P Rooney, George A C Murrell, Iain B McInnes. Hypoxia: a critical regulator of early human Tendinopathy; EXTENDED REPORT; *Ann Rheum Dis* 2012; 71:302-310.
 82. Stuart M. Raleigh and Malcolm Collins. Gene Variants that Predispose to Achilles Tendon Injuries: An Update on Recent Advances. *Achilles Tendon* Edited by Andrej Čretnik; Copyright © 2012 InTech
 83. Collins M and Raleigh SM. Genetic risk factors for musculoskeletal soft tissue injuries. *Medicine Sport Science* 2009; 54:136-149.
 84. September AV, Nell EM, O'Connell K, Cook J, Handley CJ, van der Merwe L, Schweltnus M and Collins M: A pathway-based approach investigating the genes encoding interleukin-1 {beta}, interleukin-6 and the interleukin-1 receptor antagonist provides new insight into the genetic susceptibility of Achilles tendinopathy. *British Journal of Sports Medicine* 2011.
 85. Dean BJ, Franklin SL, Carr AJ. The Peripheral Neuronal Phenotype is Important in the Pathogenesis of Painful Human Tendinopathy: A Systematic Review. *Clin Orthop Relat Res* 2013 Apr 23.
 86. Ribbans WJ, Collins M. Pathology of the tendo Achillis. Do our genes contribute? *The Bone and Joint Journal* 2013; 95-B:305-13.
 87. Williams RJ, Attia E, Wickiewicz TL, Hannafin JA. The effect of ciprofloxacin on tendon, paratenon, and capsular fibroblast metabolism. *Am J Sports Med* 2000; 28(3):364-69.
 88. Marie I, Delafenetre H, Massy N, Thuillez C, Noblet C. Tendinous disorders attributed to statins: a study on ninety-six spontaneous reports in the period 1990-2005 and review of the literature. *Arthritis Rheum* 2008; 59:367-372.
 89. van der Linden PD, Sturkenboom MC, Herings RM, Leufkens HM, Rowlands S, Stricker BH. Increased risk of achilles tendon rupture with quinolone antibacterial use, especially in elderly patients taking oral corticosteroids. *Arch Intern Med* 2003; 163:1801-1807.
 90. Ford LT, DeBender J. Tendon rupture after local steroid injection. *South Med J* 1979; 72:827-30.
 91. Kleinman M, Gross AE. Achilles tendon rupture following steroid injection. Report of three cases. *J Bone Joint Surg Am* 1983; 65:1345-7. 1983
 92. Kapetanos G. The effect of the local corticosteroids on the healing and biomechanical properties of the partially injured tendon. *Clin Orthop Relat Res* 1982; 163:170-9.
 93. Maffulli N, Longo UG, Denaro V. Novel approaches for the management of tendinopathy. *Current concepts Review. J Bone Joint Am* 2010; 92:2604-13.
 94. Riley GP, Cox M, Harrall RL, Clements S, Hazleman BL. Inhibition of tendon cell proliferation and matrix glycosaminoglycan synthesis by nonsteroidal anti-inflammatory drugs in vitro. *J Hand Surg Br* 2001; 26(3):224-228.
 95. Tsai WC, Hsu CC, Chang HN, Lin YC, Lin MS, Pang JH. Ibuprofen upregulates expressions of matrix metalloproteinase-1, -8, -9, and -13 without affecting expressions of types I and III collagen in tendon cells. *J Orthop Res* 2010; 28(4):487-491.
 96. Chan KM, Fu SC. Anti-inflammatory management for tendon injuries - friends or foes? *Sports Med Arthrosc Rehabil Ther Technol* 2009; 1(1):23.
 97. Arndt AN, Komi PV, Bruggemann GP, Lukkariniemi J. Individual muscle contributions to the in vivo achilles tendon force. *Clin Biomech* 1998;13(7):532-41.
 98. Yang G, Im HJ, Wang JH. Repetitive mechanical stretching modulates IL-1beta induced COX-2, MMP-1 expression, and PGE2 production in human patellar tendon fibroblasts. *Gene* 2005; 363:166-172.
 99. Riquet FB, Lai WF, Birkhead JR, Suen LF, Karsenty G, Goldring MB. Suppression of type I collagen gene expression by prostaglandins in fibroblasts is mediated at the transcriptional level. *Mol Med.* 2000; 6:705-719.
 100. Kjaer M, Langberg H, Skovgaard D, Olesen J, Bülow J, Krosgaard M, Boushel R. In vivo studies of peritendinous tissue in exercise. *Scand J Med Sci Sports* 2000; 10:326-31.
 101. Alfredson H, Forsgren S, Thorsen K, Lorentzon R. In vivo microdialysis and immunohistochemical analyses of tendon tissue demonstrated high amounts of free glutamate and glutamate NMDAR1 receptors, but no signs of inflammation, in Jumper's knee. *J Orthop Res* 2001; 19:881-886.
 102. Benazzo F, Maffulli N. An operative approach to Achilles tendinopathy. *Sports Med Arthroscopy Rev* 2000; 8:96-101.
 103. Ohberg L, Lorentzon R, Alfredson H.. Effects on neovascularisation behind the good results with eccentric training in chronic mid-portion Achilles tendinosis? *Knee Surg Sports Traumatol Arthrosc* 2004; 12(5):465-70.
 104. Andersson G, Danielson P, Alfredson H, Forsgren S. Presence of substance P and the neurokinin-1 receptor in tenocytes of the human Achilles tendon. *Regul Pept* 2008; 150:81-87.
 105. Bjur D, Danielson P, Alfredson H, Forsgren S. Presence of a non-neuronal cholinergic system and occurrence of up- and down-regulation in expression of M2 muscarinic acetylcholine receptors: new aspects of importance regarding Achilles tendon tendinosis

- (tendinopathy). *Cell Tissue Res* 2008; 331:385–400.
106. Hart DA, Kydd A, Reno C. Gender and pregnancy affect neuro-peptide responses of the rabbit Achilles tendon. *Clin Orthop* 1999; 365:237–46.
 107. Shalabi A. Magnetic resonance imaging in chronic Achilles tendinopathy. *Acta Radiol Suppl (Stockholm)* 2004; (432):1–45.
 108. Paavola M, Kannus P, Paakkala T, Pasanen M, Järvinen M. Long-term prognosis of patients with achilles tendinopathy. An observational 8-year follow-up study. *Am J Sports Med* 2000; 28:634–42.
 109. Bileviciute I, Lundeberg T, Ekblom A, Theodorsson E. Bilateral changes of substance P-, neurokinin A-, calcitonin gene-related peptide- and neuropeptide Y-like immunoreactivity in rat knee joint synovial fluid during acute monoarthritis. *Neurosci Lett* 1993; 153:37–40.
 110. Bileviciute I, Stenfors C, Theodorsson E, Lundeberg T. Unilateral injection of calcitonin gene-related peptide (CGRP) induces bilateral oedema formation and release of CGRP-like immunoreactivity in the rat hindpaw. *Br J Pharmacol* 1998; 125:1304–12.
 111. Andersson G, Forsgren S, Scott A, Gaida JE, Stjernfeldt JE, Lorentzon R, Alfredson H, Backman C, Danielson P. Tenocyte hypercellularity and vascular proliferation in a rabbit model of tendinopathy: contralateral effects suggest the involvement of central neuronal mechanisms; *Br J Sports Med* 2011; 45:399–406.
 112. Yang G, Crawford RC, Wang JH. Proliferation and collagen production of human patellar tendon fibroblasts in response to cyclic uniaxial stretching in serum-free conditions. *J Biomech* 2004; 37:1543–50.
 113. Cilli F, Khan M, Fu F, Wang JH. Prostaglandin E2 affects proliferation and collagen synthesis by human patellar tendon fibroblasts. *Clin J Sport Med* 2004; 14:232–6.
 114. Nell E-M, van der Merwe L, Cook J, Handley CJ, Collins M, September AV. The Apoptosis Pathway and the Genetic Predisposition to Achilles Tendinopathy. *Journal of Orthopaedic Research* 2012.
 115. Scott A, Khan KM, Heer J, Cook JL, Lian O, Duronio V. High strain mechanical loading rapidly induces tendon apoptosis: an ex vivo rat tibialis anterior model. *Br J Sports Med* 2005; 39(5):e25.
 116. Clancy W. Failed healing responses in sports-induced inflammation: clinical and basic science concepts. In: W Leadbetter, J Buckwater, S Gordon, editors. Park Ridge, IL: American Orthopedic Society for Sports Medicine 1989.
 117. Xu Y, Murrell GA. The basic science of tendinopathy. *Clin Orthop Relat Res* 2008; 466:1528–38.
 118. Hashimoto S, Takahashi K, Ochs RL, Coutts RD, Amiel D, Lotz M. Nitric oxide production and apoptosis in cells of the meniscus during experimental osteoarthritis. *Arthritis Rheum* 1999; 42:2123–2131.
 119. Szomor ZL, Appleyard RC, Murrell GA. Overexpression of nitric oxide synthases in tendon overuse. *J Orthop Res* 2006; 24:80–86.
 120. Bokhari A R, Murrell GAC. The role of nitric oxide in tendon healing. *J Shoulder Elbow Surgery* 2012; 21, 238-244.
 121. Paoloni J, Murrell GAC. Three-year followup study of topical glyceryl trinitrate application in the treatment of chronic noninsertional Achilles tendinopathy. *Foot Ankle Int* 2007; 28:1064-8.
 122. Bi Y, Ehrichtiou D, Kilts TM, Inkson CA, Embree MC, Sonoyama W, Li L, Leet AI, Seo BM, Zhang L, Shi S, Young MF. Identification of tendon stem/progenitor cells and the role of the extracellular matrix in their niche. *Nat Med* 2007;13:1219–27.
 123. Zhang J, Wang JH. Characterization of differential properties of rabbit tendon stem cells and tenocytes. *BMC Musculoskelet Disord* 2010; 11:10.
 124. Zhang J, Pan T, Liu Y, Wang JH. Mouse treadmill running enhances tendons by expanding the pool of tendon stem cells (TSCs) and TSC-related cellular production of collagen. *J Orthop Res* 2010; 28:1178–83.
 125. Zhang J, Wang JH. Mechanobiological response of tendon stem cells: implications of tendon homeostasis and pathogenesis of tendinopathy. *J Orthop Res* 2010; 28:639–43.
 126. Millar NL, Hueber AJ, Reilly JH, Xu Y, Fazzi UG, Murrell GA, McInnes IB. Inflammation is present in early human tendinopathy. *Am J Sports Med.* 2010; 38:2085–91.
 127. Divani K, Chan O, Padhiar N, Twycross-Lewis R, Maffulli N, Crisp T, Morrissey D. Site of maximum neovascularisation correlates with the site of pain in recalcitrant mid-tendon Achilles tendinopathy. *Man Ther* 2010; 15:463–468.
 128. Peers KH, Brys PP, Lysens RJ. Correlation between power Doppler ultrasonography and clinical severity in Achilles tendinopathy. *Int Orthop* 2003; 27:180–183.
 129. Zanetti M, Metzdorf A, Kundert HP, Zollinger H, Vienne P, Seifert B, Hodler J. Achilles tendons: clinical relevance of neovascularization diagnosed with power Doppler US. *Radiology* 2003; 227:556–560.
 130. Bjur D, Alfredson H, Forsgren S. The innervation pattern of the human Achilles tendon: studies of the normal and tendinosis tendon with markers for general and sensory innervation. *Cell Tissue Res* 2005; 320:201-206.
 131. Gibbon WW, Cooper JR, Radcliffe GS: Distribution of sonographically detected tendon abnormalities in patients with a clinical diagnosis of chronic achilles tendinosis. *J Clin Ultrasound* 2000; 28:61–66.
 132. Alfredson H, Forsgren S, Thorsen K, Fahlstrom M, Johansson H, Lorentzon R. Glutamate NMDAR1 receptors localised to nerves in human Achilles tendons. Implications for treatment? *Knee Surg Sports Traumatol Arthrosc* 2001; 9:123–126.
 133. Andersson G, Danielson P, Alfredson H, Forsgren S. Nerve-related characteristics of ventral paratendinous tissue in chronic Achilles tendinosis. *Knee Surg Sports Traumatol Arthrosc* 2007; 15:1272–1279.
 134. Steenstra F, van Dijk CN. Achilles tendoscopy. *Foot Ankle Clin* 2006; 11:429–438.
 135. van Schie HT, de Vos RJ, de JS, Bakker EM, Heijboer MP, Verhaar JA, Tol JL, Weinans H. Ultrasonographic tissue characterisation of human Achilles tendons: quantification of tendon structure through a novel non-invasive approach. *Br J Sports Med* 2010; 44:1153–1159.
 136. Daseler EH. The plantaris muscle: an anatomical study of 750 specimens. *J Bone Joint Surg* 1943; 25:822–827.
 137. Leadbetter WB. Cell–matrix response in tendon injury. *Clin Sports Med* 1992; 11: 533–542.
 138. Alfredson H. Midportion Achilles tendinosis and the plantaris tendon; *Br J Sports Med* 2011; 45:1023-1025.
 139. Linz F, Higgs A, Millet M, Barton T, Raghuvanshi M, Adams MA, Winson IG. The role of Plantaris Longus in Achilles tendinopathy: a biomechanical study. *Foot and Ankle Surgery* 2011; 17:252-255.
 140. Luck MD, Gordon AG, Blebea JS, Dalinka MK. High association between accessory soleus muscle and Achilles tendinopathy. *Skeletal Radiol* 2008; 37:1129-33.
 141. Padhiar N, Al-Sayegh H, Chan O, King J, Maffulli N. Pennation angle of the soleus in patients with unilateral Achilles tendinopathy. *Disabil Rehabil* 2008; 30:1640-5.
 142. Cook JL, Purdam CR. Is tendon pathology a continuum? A pathology model to explain the clinical presentation of load-induced tendinopathy. Review. *Br J Sports Med* 2009; 43:409–416.
 143. Longo UG, Ronga M, Maffulli N. Achilles tendinopathy. *Sports Med Arthrosc* 2009; 17:112–126.
 144. Rees JD, Maffulli N, Cook J. Management of tendinopathy. *Am J Sports Med* 2009; 37:1855–1867.
 145. Sai-Chuen Fu, Christer Rolf, Yau-Chu Cheuk, Pauline PY Lui, KaiMing Chan. Deciphering The pathogenesis of tendinopathy: a three-stages process, Review. *Sports Medicine, Arthroscopy, Rehabilitation, Therapy & Technology* 2010; 2:30.
 146. Petersen W, Varoga D, Zantop T, Hassenpflug J, Mentlein R, Pufe T. Cyclic strain influences the expression of the vascular endothelial growth factor (VEGF) and the hypoxia inducible factor 1 alpha (HIF-1a) in tendon fibroblasts. *J Orthop Res* 2004; 22: 847–853.

147. Li J, Hampton T, Morgan JP, Simons M. Stretch-induced VEGF expression in the heart. *J Clin Invest* 1997; 100: 18–24.
148. Rompe JD, Furla JP, Maffulli N. Mid-portion Achilles tendinopathy - current options for treatment. *Disabil Rehabil* 2008; 30: 1666-1676.

Peer reviewers: Mamoru Yoshida, Department of orthopaedic surgery, the Jikei univ. school of medicine, 3-25-8, Nishi-shinbashi, Minato-ku, Tokyo Japan; Abdel-Rahman Aly, M.D., Physical Medicine & Rehab Department, 701 Queen Street, 7th Floor, SCH, Saskatoon, SK, Canada.