

Crystal Arthropathy following Knee Arthroplasty: A Review of the Literature

Mahdi Y Khalfaoui, Rafik Yassa

Mahdi Y Khalfaoui, Central Manchester Teaching Hospitals, Trafford General Hospital, Manchester, the United Kingdom

Rafik Yassa, Central Manchester Teaching Hospitals, Manchester Royal Infirmary, Manchester, the United Kingdom

Correspondence to: Mahdi Y Khalfaoui, Department of Trauma & Orthopaedics, Trafford general hospital, Moorside Road, Davyhulme, Manchester M41 5SL, Permanent Address: 8 Winsford Road, Fallowfield, Manchester, M14 7HP, the United Kingdom

Email: mahdikhalfaoui@nhs.net

Telephone: +447742781020

Received: July 30, 2015

Revised: August 26, 2015

Accepted: August 30, 2015

Published online: October 23, 2015

ABSTRACT

INTRODUCTION: Crystal arthropathy is a well-established differential diagnosis in suspected native joint septic arthritis however it is often overlooked in the setting of a prosthetic joint.

OBJECTIVES: In the current review we evaluate all of the available literature on the subject of crystal arthropathy in the setting of prosthetic knees, in order to determine the patterns of presentation, diagnostic protocols and management of such cases.

FEATURES OF REVIEW: A total of 30 individual reported cases of peri-prosthetic crystal arthropathy affecting the knee joint, were identified for inclusion. Of these, 17 cases reported a confirmed diagnosis of gout, with 13 concluding a diagnosis of pseudogout. Inflammatory and infectious markers were usually raised or borderline high across both groups of patients, with the following combined mean values; ESR: 65.5mm, CRP: 95.6ml/L and Wcc: $10.8 \times 10^9/L$ for gout and pseudogout respectively. There were 4 cases (13.3%) of concomitant infection and crystal arthropathy. Management varied widely across cases, with gout patients commonly undergoing invasive surgical washout (59%), and pseudogout cases largely managed conservatively (71%).

CONCLUSIONS: Correctly diagnosing crystal arthropathy in a prosthetic joint can result in the avoidance of invasive surgical

intervention. We would advocate the use of routine crystal microscopy in the diagnostic process of all suspected peri-prosthetic infections. A high degree of caution should be taken however in view of the possibility of concomitant prosthetic crystal arthropathy and septic arthritis.

© 2015 The Authors. Published by ACT Publishing Group Ltd.

Key words: Crystal arthropathy; Knee arthroplasty; Infection; Septic arthritis; Gout; Pseudogout

Khalfaoui MY, Yassa R. Crystal Arthropathy following Knee Arthroplasty: A Review of the Literature. *International Journal of Orthopaedics* 2015; 2(5): 411-417 Available from: URL: <http://www.ghrnet.org/index.php/ijo/article/view/1328>

INTRODUCTION

Crystal arthropathies encompass a range of disorders characterized by the abnormal deposition of mineral content within joints leading to an inflammatory response. The two most common crystals deposited include monosodium urate (MSU) and calcium pyrophosphate dihydrate (CPPD) representing gout and pseudogout respectively^[1].

The rising incidence and prevalence of gout over the last decade has continued to strain healthcare systems, with a recent review reporting an incidence of 1.77 per 1000 person years in the UK^[2]. Cases of pseudogout are seen less commonly with an incidence of 1.30 per 1000 persons^[3]. Acute crystal arthropathies in the native joint can mimic septic arthritis in their pattern of presentation. In both conditions patients are often reported to present with localized symptoms of knee pain, reduced range of motion, swelling and erythema as well as systemic symptoms of general malaise and fevers^[4,5]. Investigative protocols in the acute setting differ broadly but largely incorporate, routine laboratory blood analysis, plain radiography, and joint fluid examination^[3]. Diagnosis is primarily dependent on the observation of negatively or positively birefringent crystals on microscopy for a diagnosis gout and pseudogout

respectively. Differentiation of crystal arthropathy from septic arthritis is the primary aim of the diagnostic workup process. Cases of simultaneous crystal arthropathy and septic arthritis can also occur however, further complicating the clinical evaluation^[6].

The growing trend in arthroplasty surgery rates both in the UK and globally will likely lead to an increase in presentations of periprosthetic arthropathy^[7,8]. Since 2003, the UK national joint registry has recorded data on 676,082 knee replacements^[9]. Infection was reported to be the third most common indication for revision surgery across all fixation types, with an overall incidence of 1.06 per 1,000 person years.

Established deep Infection of the prosthetic knee remains a difficult complication to treat, posing a significant dilemma to the treating surgeon whilst causing considerable disability to the patient. Major invasive surgical intervention is usually required in the management of such cases. A two-stage revision process, signified by removal of the infected prosthesis, implantation of an antibiotic impregnated cement spacer, followed by a delayed re-implantation of prosthesis procedure, was widely the accepted management gold-standard^[10]. The success of single stage revision surgery for the infected hip prosthesis, has led to a recent re-emergence of studies demonstrating similar successful outcomes with one-stage procedures for periprosthetic knee infections^[11].

Early recognition of peri-prosthetic infection is paramount to minimizing patient morbidity, and hence a high index of suspicion is usually exercised when dealing with possible cases. The diagnostic process however is not always clear-cut. In the acute setting it largely resembles that for the native joint. The results from the diagnostic tests available are not always conclusive for confirming peri-prosthetic infection. It is at this stage when alternative diagnoses should be actively pursued in order to ensure rare pathology is not overlooked and invasive procedures are avoided for presumed infection.

The aim of the current review is to evaluate all of the available literature on the subject of crystal arthropathy in the setting of a prosthetic knee joint, in order to determine the patterns of presentation, diagnosis and management of such cases.

MATERIALS

Search Strategy

An electronic search of the PubMed, EMBASE, Ovid, CINAHL and Cochrane databases was conducted using the terms: "gout", "pseudogout", "chondrocalcinosis", "crystal arthropathy", "total knee replacement", "knee arthroplasty" and "TKR". Titles and abstracts were screened to determine their eligibility for inclusion into the current review by two independent reviewers. Inclusion into the review was open to all literature discussing the occurrence of crystal arthropathy in the setting of knee arthroplasty. Studies discussing crystal arthropathy in prosthetic joints other than the knee were excluded. Reference lists were further scrutinized to identify additional relevant literature. Articles were limited to those published in the English language with no date restrictions applied. Full texts were obtained for all articles meeting our initial broad inclusion criteria.

Information was evaluated from the literature according to three main domains. The first domain related to details on presenting symptomatology and signs on clinical examination. The second area pertained to diagnostics and broadly focused on radiological findings, laboratory blood analysis and joint fluid analysis. The last area of interest was based around management and considered both medical

and surgical pathways.

Information extraction from the literature was conducted by two assessors, with a third assessor available for discussion around any discrepancies. All data was recorded using Microsoft Excel 2010. The unpaired students T-test was used to analyse all parametric data variables.

RESULTS

Our search strategy returned a total of 89 articles. Of these articles there were no systematic reviews, met-analyses or cohort studies available on the current topic. A selection of 23 articles were deemed relevant for the purpose of the current review as they related to the topic of crystal arthropathy affecting prosthetic knee joints. This selection comprised of individual case studies as well as several case series see tables 1 & 2. From these articles, a total of 30 independent cases of reported peri-prosthetic crystal arthropathy affecting the knee joint were extracted from the evaluated literature across a period from Jan 1994 to Feb 2014. A total of 17 of these cases reported a confirmed diagnosis of gout, with the remaining 13 concluding a diagnosis of pseudogout. The average age of patients diagnosed with gout was 66.6 years (std dev: 13.1, range: 39-88 years) in comparison to 72.1 years (std dev: 11.2, range 52-90 years) for the pseudogout group. A known history of gout was documented in 9 of the 17 reported cases, with none of the pseudogout patients' known to have previously suffered with the condition.

The majority of the reports for the gout cohort of cases originated from the USA (65%, $n=11$), with the UK and New Zealand the next significant contributors of cases, see figure 1. In contrast to this 46% of cases with a diagnosis of peri-prosthetic pseudogout originated from Japan with the USA the second largest contributor of cases.

Presenting features and Clinical Examination

Across all of the case reports included in this review, patients uniformly presented with a painful and swollen prosthetic knee joint. Bilateral prosthetic knee involvement was noted in four cases diagnosed with gout (24%) and three diagnosed with pseudogout (23%). The majority of the cases reviewed had presented on the background of a primary total knee replacement, however 24% of the overall gout cases were following revision arthroplasty surgery and 23% of the pseudogout presentations were on the background of a unicompartmental knee replacement, see figure 2. The time interval between presentation and the original arthroplasty procedure varied significantly between those diagnosed with gout and pseudogout, averaging 6.8 months and 2.5 months respectively. Similarly the duration of symptoms during the presenting encounter also differed, lasting on average 7.5 days in the gout series of patients (range: 1-28 days) compared to just 3.8 days for the pseudogout cohort (range: 1-28 days).

Features of night sweats and rigors during the bouts described were noted in 35% and 31% of cases in those with gout and pseudogout respectively. Body temperature was another commonly reported feature with the mean temperature on admission recorded at 38.2°C (range: 37.3°C-39.9°C) in the gout series and 38.1°C (range: 37.5°C-38.8°C) in those cases of pseudogout. All of the authors across the literature were reported to have elicited a clinical effusion during their examinations. Joint movements were universally restricted on admission across the studies reviewed, and this was more pronounced amongst pseudogout patients with a mean reported range of motion of 57°, see table 3.

Table 1 Publications Describing Confirmed Monosodium Urate Peri-Prosthetic Crystal Arthropathy of the Knee.

Year	Author [Reference]	Journal	Country	Article Type
1994	S C Williamson et al ^[12]	Journal of Bone & Joint Surgery am	USA	Single Case
1999	P Blyth & V S Pai ^[13]	Journal of Arthroplasty	New Zealand	Case Series (2)
2001	M J Archibeck et al ^[14]	Clinical orthopaedics and related research	USA	Case Series (2)
2006	G Roberts ^[15]	British Medical Journal	UK	Single Case
2007	L Crawford et al ^[16]	J Orth Surg	UK	Single Case
2008	J C Rompen et al ^[17]	Nederlands tijdschrift voor geneeskunde	Netherlands	Single Case
2008	J W Salin et al ^[18]	Am J Orth	USA	Case Series (2)
2009	J S Berger et al ^[19]	PM&R	USA	Single Case
2010	S K Fokter et al ^[20]	Wiener klinische Wochenschrift	Slovenia	Single Case
2010	M T Freehill et al ^[21]	Journal of Arthroplasty	USA	Single Case
2010	A Zadaka et al ^[22]	Journal of knee surgery	USA	Case Series (2)
2011	S Soloway ^[23]	Journal of clinical rheumatology	USA	Single Case
2014	M Buck & M Delaney ^[24]	Orthopaedic Nursing	USA	Single Case

Table 2 Publications Describing Confirmed Calcium Pyrophosphate Peri-Prosthetic Crystal Arthropathy of the Knee.

Year	Author [Reference]	Journal	Country	Article Type
2002	H Kobayashi et al ^[25]	Arch Orthop Trauma Surg	Japan	Case Series (3)
2005	G Holt et al ^[26]	British Medical Journal	UK	Single Case
2007	C Hirose & R Wright ^[27]	The Journal of Arthroplasty	USA	Single Case
2007	P Sonsale et al ^[28]	The Journal of Arthroplasty	UK	Single Case
2012	J L Carter et al ^[29]	JBJS Case Connect	USA	Single Case
2012	T Hunte et al ^[30]	Journal of Clinical Rheumatology	USA	Single Case
2012	K Koyama et al ^[31]	JBJS Case Connect	Japan	Case Series (2)
2012	G Levi et al ^[32]	orthop Clin N Am	USA	Single Case
2013	K Harato & H Yoshida ^[33]	The Journal of Arthroplasty	Japan	Single Case
2013	A Swayamprakasam et al ^[34]	British Journal Of Hospital Medicine	UK	Single Case

Table 3 Summary of descriptive findings.

	Gout				Pseudogout				P-value	95% CI
	Number reported	Mean	Std Dev	Range	Number reported	Mean	Std Dev	Range		
Time since Surgery, months	16	82.13	68.27	0.107 to 240	13	30.48	42.52	0.25 to 120	0.0249	7.022 to 96.277
Duration of symptoms, days	13	7.5	9.23	1 to 28	8	3.75	4.68	1 to 15	0.2971	-3.61 to 11.18
Temperature, °C (*)	7 (6)	38.2 (38.2)	0.83 (0.90)	37.3 to 39.9	6	38.1	0.42	37.5 to 38.8	0.736	-0.703 to 0.964
Movement Range, ° (*)	6 (5)	62.5 (70)	23.82 (16.96)	25-90	7	57.14	39.35	15-110	0.7772	-35.31 to 46.02
Time to Discharge, days (*)	8 (6)	22.2 (7.6)	30.29 (5.50)	1.5-90	9	9.1	6.82	3-23	0.2254	-8.967 to 35.120

* Figures following exclusion of cases with later confirmed concomitant infection.

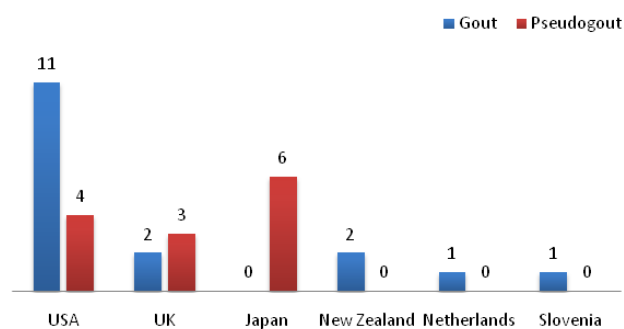


Figure 1 Cases by country of origin.

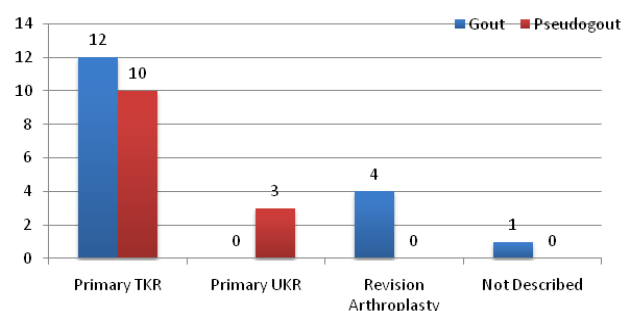


Figure 2 Background arthroplasty procedure.

Diagnostics

Plain radiography was performed and the results described in 21 of the 30 cases reviewed. We assessed for radiographic features of infection and prosthetic malposition using combinations of reports as well as actual radiographic images when available. The majority of radiographs (81%) were reported as normal with only one case reporting features of loosening and three of intra-articular calcification, see figure 3.

All authors from the literature we reviewed described performing a compliment of laboratory tests during the investigative process of their patients. There were significant variations in the combinations of tests utilised, however these largely comprised of using routine full blood count testing, along with inflammatory marker determination in the form of ESR or C-reactive protein, and serum uric acid levels. The mean white cell count was borderline elevated for cases in the gout cohort, at $12.32 \times 10^9/L$, and normal in those with pseudogout, see table 4. However the range of values varied considerably in both cohorts reaching as high as $17.3 \times 10^9/L$ and $18 \times 10^9/L$ across the gout and pseudogout cases respectively. The use of ESR was more common than C-reactive protein as an inflammatory marker across the cases we reviewed. Inflammatory markers were globally raised in both cohorts, however this response was most notable in the gout series with the mean C-reactive protein and ESR responses showing 13-fold and 3-fold rises respectively on the upper borders of the normal limits. Overall serum uric acid levels were frequently measured in the gout series however our results demonstrated only a minor rise in the mean levels.

All patients across the literature underwent joint fluid aspiration during their investigative process. The gross appearance of the aspirate was most often described as “cloudy/turbid” in both gout and pseudogout cases, with “purulent” aspirate the second commonest appearance description across all patients, see figure 4. Joint fluid microscopy was positive in all but one case of those with prosthetic gouty arthropathy and in all cases for pseudogout. In the one negative case, negatively birefringent crystals were later confirmed following histological examination of samples taken from an open washout procedure.

Gram stain and culture analysis identified four cases of concomitant bacterial infection. All of these cases were associated with an end definitive diagnosis of gouty arthropathy.

Management

There were large variations in the management protocols instituted between cases. In those eventually diagnosed with gout, 59% underwent surgical intervention. Of those treated surgically, the majority (92%) underwent an open washout procedure, with only one case of arthroscopic washout described, see figure 5.

In contrast to this, only 23% of patients from the pseudogout series underwent surgical intervention, with the vast majority managed conservatively using either non-steroidal anti-inflammatory drugs or colchicine, see figure 6.

Management also varied amongst the four patients found to have simultaneous infection and gouty arthropathy, with one undergoing an open washout procedure only, two requiring open washout procedures and change of the polyethylene insert and the last patient undergoing the first of a two-stage revision procedure.

Authors infrequently described the time interval from admission until discharge, see table 3. The mean time to discharge for those with gout was 22.2 days (Range: 1.5-90 days, Std Dev: 30.29). After exclusion of patients in the gout series with concomitant infection, the mean time to discharge fell considerably to 7.6 days (Range: 1.5-14 days, Std Dev: 5.50). The mean time to discharge for the pseudogout cohort of patients was insignificantly higher at 9.1 days (*p*-value: 0.6555, 95% CI: -8.757 -5.702).

DISCUSSION

The rising incidence of crystal arthropathy and knee arthroplasty rates in the UK is likely to see an increase in the diagnoses of peri-prosthetic crystal arthropathy. The exact incidence of crystal arthropathy following total knee replacement is not known. To our knowledge this is the first study to formally review all of the current available literature pertaining to crystal arthropathy following knee arthroplasty surgery.

Our review highlights several significant practical points concerning patients with peri-prosthetic crystal arthropathy. Generic features of joint swelling, localised warmth, pyrexia and painful reduced range of movement were evident in the presentation

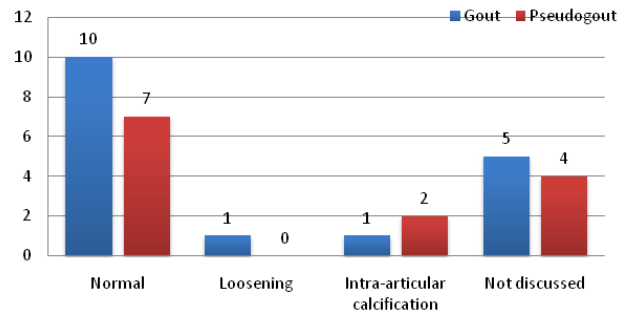


Figure 3 Radiographic findings.

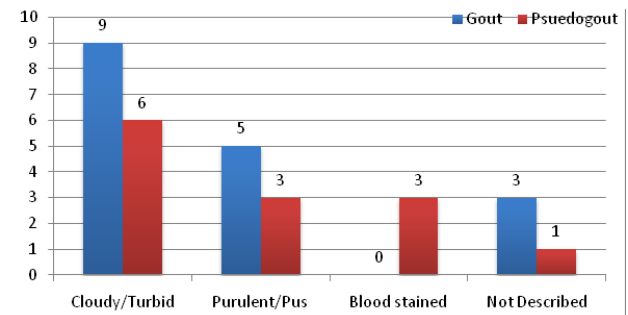


Figure 4 Joint aspirate appearance.

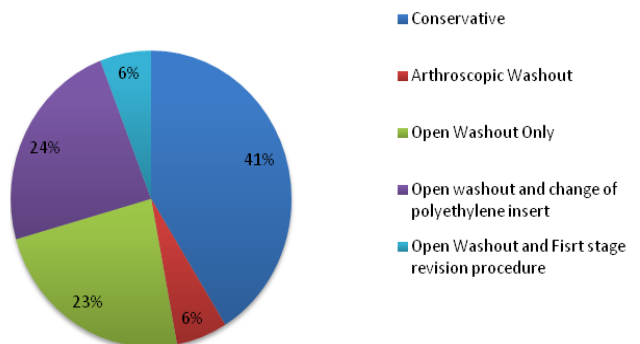


Figure 5 Management protocols instituted in gout cases.

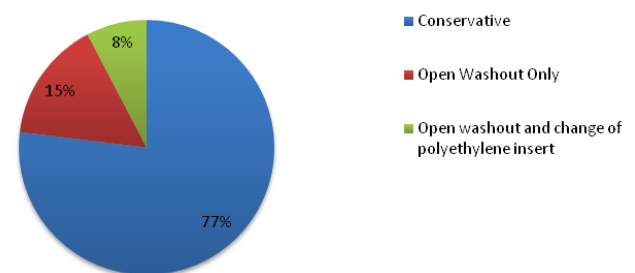


Figure 6 Management protocols instituted in pseudogout patients.

Table 4 Summary of biochemical results.

	Gout				Pseudogout				P-value	95% CI
	Number reported	Mean	Std Dev	Range	Number reported	Mean	Std Dev	Range		
Erythrocyte Sedimentation rate, mm (*)	13 (10)	76.0 (78.3)	32.29	27 to 120	6	55.0	35.70	25 to 120	0.2189	-13.71 to 55.71
C-Reactive Protein, mg/l (*)	6 (6)	107.2	(36.04)	10.3 to 320	8	84.0	111.10	5.4 to 333	0.7183	-113.70 to 160.13
White Cell Count, cells*10 ⁹ /L (*)	13 (10)	12.32 (11.7)	123.35	8.2 to 17.3	8	9.28	5.27	1.3 to 18	0.1568	-1.276 to 7.357
Serum Uric Acid, mmol/L (*)	12 (10)	0.58 (0.57)	4.14 (4.43)	0.33 to 0.91	N/A	N/A	N/A	N/A	N/A	N/A
Synovial fluid wcc, cells*10 ⁶ /L (*)	7 (7)	12,906.5	0.18 (0.15)	1000 to 22000	5	45,063.4	23809.17	4917 to 64200	0.0068	-53252.01 to 11061.65
Synovial fluid Neutrophil % (*)	5 (5)	91.4	7603.42.19	81 to 97	4	89.6%	9.75	76 to 99	7309	-10.65 to 14.45

* Figures following exclusion of cases with later confirmed concomitant infection.

descriptions of all of the cases we reviewed emphasizing the close resemblance of peri-prosthetic arthropathy with infection. A high index of suspicion for crystal arthropathy was clearly evident amongst authors across the literature we reviewed.

Although just over half of patients diagnosed with peri-prosthetic gouty arthropathy in this review were known to suffer from gout previously, none of those diagnosed with pseudogout were known to suffer from any type of crystal arthropathy, further highlighting the need for a high index of suspicion when met with cases of this nature. This raises the question of whether routine evaluation for crystal arthropathy prior to knee arthroplasty is warranted.

Full blood counts and inflammatory markers have traditionally played a vital role when aiming to distinguish between infection and alternative causes of a painful, swollen prosthetic joint. Our review demonstrates a pattern of mild elevation in the mean white cell counts and a marked rise in inflammatory markers amongst patients with gouty arthropathy despite the exclusion of cases with concomitant infection. The picture was slightly different amongst pseudogout peri-prosthetic arthropathy, with a normal mean white cell count evident amongst cases and only a moderate elevation in the inflammatory markers reported. In both groups of patients the rise in inflammatory markers, made them less useful in excluding infection. This finding is in keeping with previous literature relating to native joints, which has established poor discriminatory ability of serum inflammatory markers between patients with infection and crystal arthropathy^[35].

Cell count and differential of aspirated fluid have previously been reported to have higher sensitivity and specificity for diagnosing infection in the setting of a prosthetic joint than other conventional investigations^[36]. Optimal cut-off values have been investigated and a synovial white cell count of 1,590 cells/ μ l with a neutrophilia of 65% or more has been suggested for use in diagnosing infection with total hip and knee arthroplasty^[37]. According to our review six of the seven cases reporting aspirated fluid cell counts with gout would have exceeded the cut-off levels suggested for infection. Furthermore in the pseudogout series, all reported cell counts and differentials were above the suggested threshold for infection, rendering such testing alone as inadequate for excluding infection in the setting of peri-prosthetic crystal arthropathy.

Radiographic features of crystal arthropathy in the native joint play an important role in diagnosing such pathology and help in monitoring its progress^[38]. Up to 45% of patients with gout, manifest radiological features supporting its diagnosis^[39]. In our review over 80% of radiographs revealed no features of pathology, demonstrating once again the poor discriminatory capabilities of non-invasive diagnostic adjuncts in the setting of a prosthetic joint. Computerized tomography and magnetic resonance imaging have both demonstrated promising diagnostic capability in this setting.

Concomitant crystal arthropathy and septic arthritis in the native joint is well recognized^[40]. Our review highlights that simultaneous infection and crystal arthropathy in the prosthetic joint is also possible with 4 of the 17 cases eventually diagnosed with gout demonstrating this diagnosis. Three of the four cases reported their respective full blood count and inflammatory marker results, and this did not significantly differ from the average of those cases without proven infection, further highlighting the difficulty in identifying infected cases for invasive treatment. Those with concomitant pathology did however have significantly longer inpatient stay averaging 9 weeks.

The use of antibiotics prior to the aspiration of joint fluid can account for negative gram-stain and culture growth results. A previous study revealed that up to half of all patients treated for septic

arthritis had received antibiotic treatment prior to synovial fluid aspiration^[41]. The sensitivity of initial microscopy and later culture growth following aspiration of prosthetic knee joints have both been shown to drop significantly by 45% and 55% respectively^[41]. Physicians are well aware of this phenomenon and although pre-hospital based antibiotic administration was not well discussed across the case studies we reviewed, it is highly likely that this would have contributed to the large number of cases in our review undergoing invasive washout procedures despite negative results for infection.

CONCLUSION

An awareness of the diagnosis of acute crystal arthropathy in the setting of a prosthetic joint is crucial to all orthopaedic specialists. Failure or delay of making this diagnosis can lead to invasive intervention causing significant morbidity and prolonged disability to patients. Although crystal arthropathies are well described in the chronic form, an acute attack in the setting of a prosthetic joint is a less well recognised complication. An acute attack can present with a warm, swollen and painful joint. Discerning between acute crystal arthropathy and infection is difficult on clinical grounds alone.

From this review however we would recommend a detailed history is essential, focusing on determining whether patients have previously suffered unknowingly from crystal arthropathy or whether risk factors for such pathology are present. Routine serum blood counts and inflammatory markers seem to exhibit a similar response pattern to that found in infection. We would however insist on routine blood testing including; full blood count, inflammatory markers (both ESR and CRP) with the addition of a serum urate level. These blood tests play a crucial role in stratifying the overall risk for periprosthetic infection. We would also recommend a low threshold for joint fluid aspiration in this setting. We feel the safest way to interpret joint fluid results from a prosthetic joint would be to utilise the American association of orthopaedic surgeons (AAOS) definition for periprosthetic infection^[42]. In this definition, 6 criterion are described including; raised serum inflammatory markers (either ESR or CRP), elevated synovial white cell count, elevated synovial neutrophil percentage, identification of purulence in the joint, isolation of a microorganism in one culture of joint fluid or tissue and raised neutrophils from histological tissue analysis. If four or more of these criterion are present or a pathogen is identified from cultures in 2 separate tissue/fluid samples, than a diagnosis of periprosthetic infection should be made. If microscopy is positive for crystal arthropathy indicating concomitant pathology then treatment for both should be instituted. In the event that the AAOS definition for infection is not met and there are positive microscopy results, we would recommend initial conservative management for crystal arthropathy and observation of clinical and biochemical markers to ensure normalisation.

A further consideration complicating the issue, are the effects of empirical antibiotic treatment prior to joint aspiration. Identification of organisms on gram staining and later growth on cultures is significantly compromised following systemic antibiotic administration. We therefore recommend that healthcare professionals in the primary care setting, should be educated on early referral to the orthopaedic specialist in these scenarios, before attempting any form of treatment. In the event that empirical treatment has already been commenced, orthopaedic specialists should act with strict vigilance even when faced with negative gram stain and culture growth results, relying more upon clinical and biochemical trends discussed in this article.

CONFLICT OF INTERESTS

There are no conflicts of interest with regard to the present study.

REFERENCES

- Pascual E. (1999) Management of crystal arthritis. *Rheumatology* 38(10):912-916. doi: 10.1093/rheumatology/38.10.912
- Kuo CF, Grainge MJ, Mallen C, Zhang W, Doherty M. (2014) Rising burden of gout in the UK but continuing suboptimal management: a nationwide population study. *Annals of the rheumatic diseases*, annrheumdis-2013. doi: 10.1136/annrheumdis-2013-204463
- Ellis S, Koduri G. (2010) Crystal arthropathies. *Medicine* 38(3):146-150. doi: 10.1016/j.pmpmed.2009.11.006
- Kalore NV, Gioe TJ, Singh JA. (2011) Diagnosis and management of infected total knee arthroplasty. *The open orthopaedics journal* 5:86-91. doi: 10.2174/1874325001105010086
- Rubenstein J, Pritzker KP. (1989) Crystal-associated arthropathies. *American Journal of Roentgenology* 152(4):685-695. doi: 10.2214/ajr.152.4.685
- Weng CT, Liu MF, Lin LH, Weng MY, Lee NY, Wu AB et al. (2009) Rare coexistence of gouty and septic arthritis: a report of 14 cases. *Clin Exp Rheumatol* 27(6):902-6.
- Culliford DJ, Maskell J, Beard DJ, Murray DW, Price AJ, Arden NK. (2010) Temporal trends in hip and knee replacement in the United Kingdom 1991 TO 2006. *Journal of Bone & Joint Surgery, British* 92(1):130-135. doi: 10.1302/0301-620X.92B1.22654
- Losina E, Thornhill TS, Rome BN, Wright J, Katz JN. (2012) The dramatic increase in total knee replacement utilization rates in the United States cannot be fully explained by growth in population size and the obesity epidemic. *The Journal of Bone & Joint Surgery* 94(3):201-207. doi: 10.2106/JBJS.J.01958
- National Joint Registry: 11th annual report. (2013) <http://www.njrcentre.org.uk> (Accessed: 10th Dec 2014).
- Parkinson RW, Kay PR, Rawal A. (2011) A case for one-stage revision in infected total knee arthroplasty?. *The Knee* 18(1):1-4. doi: 10.1016/j.knee.2010.04.008
- Masters JPM, Smith NA, Foguet P, Reed M, Parsons H, Sprowson AP. (2013) A systematic review of the evidence for single stage and two stage revision of infected knee replacement. *BMC musculoskeletal disorders* 14(1):222. doi: 10.1186/1471-2474-14-222
- Williamson SC, Roger DJ, Petrer P, Glockner F. (1994) Acute gouty arthropathy after total knee arthroplasty. A case report. *JBJS Case Connector* 1 76(1):126-128.
- Blyth P, Pai VS. (1999) Recurrence of gout after total knee arthroplasty. *The Journal of arthroplasty* 14(3):380-382. doi: 10.1016/S0883-5403(99)90067-0
- Archibeck MJ, Rosenberg AG, Sheinkop MB, Berger RA, Jacobs JJ. (2001) Gout-induced arthropathy after total knee arthroplasty: a report of two cases. *Clinical orthopaedics and related research* 392:377-382.
- Roberts G. (2006) Acute Gout Presenting as an acutely swollen prosthetic knee joint. *British Medical Journal*. <http://www.bmj.com/rapid-response/2011/10/31/acute-gout-presenting-acutely-swollen-prosthetic-knee-joint> (Accessed: 12th Oct 2014).
- Crawford L, Kumar A, Shepard GJ. (2007) Gouty synovitis after total knee arthroplasty: a case report. *Journal of Orthopaedic Surgery* 15(3):384-5.
- Rompen JC, Kuiper-Geertsma DG, Verheyen CC. (2008) Gouty arthritis in a total knee prosthesis. *Nederlands tijdschrift voor geneeskunde* 152(19):1117-1119.
- Salin JW, Lombardi Jr AV, Berend KR, Chonko DJ. (2008) Acute gouty arthropathy after total knee arthroplasty. *Am J Orthop (Belle Mead NJ)* 37:420-422.
- Berger JS, Weinik MM. (2009) Acute gouty arthropathy mimicking infection after total knee arthroplasty. *American Academy of Physical Medicine and Rehabilitation* 1(3):284-286. doi: 10.1016/j.pmrj.2008.11.007
- Fokter SK, Repše-Fokter A. (2010) Acute gouty arthritis in a patient after total knee arthroplasty. *Wiener klinische Wochenschrift* 122(11-12): 366-367. doi: 10.1007/s00508-010-1384-3
- Freehill, MT, McCarthy EF, Khanuja HS. (2010) Total knee arthroplasty failure and gouty arthropathy. *The Journal of arthroplasty* 25(4):658-e7. doi: 10.1016/j.arth.2009.03.004
- Zadaka A, Gioe T, Gertner E. (2010) Acute crystal-induced arthritis following arthroplasty. *Journal of Knee Surgery* 23(01):017-020.
- Soloway S. (2011) Tophaceous Gout in a Knee With Total Joint Replacement. *JCR: Journal of Clinical Rheumatology* 17(1):48. doi: 10.1097/RHU.0b013e3182056687
- Buck M, Delaney M. (2014) Diagnosis and Management of Gout in Total Knee Arthroplasty. *Orthopaedic Nursing* 33(1):37-40. doi: 10.1097/NOR.0000000000000021
- Kobayashi H, Akizuki S, Takizawa T, Yasukawa Y, Kitahara J. (2002) Three cases of pseudogout complicated with unicondylar knee arthroplasty. *Archives of orthopaedic and trauma surgery* 122(8):469-471. doi: 10.1007/s00402-002-0414-7
- Holt G, Vass C, Kumar CS. (2005) Acute crystal arthritis mimicking infection after total knee arthroplasty *British Medical Journal* 331:1322. doi: <http://dx.doi.org/10.1136/bmj.331.7528.1322>
- Hirose CB, Wright RW. (2007) Calcium pyrophosphate dihydrate deposition disease (pseudogout) after total knee arthroplasty. *The Journal of arthroplasty* 22(2):273-276. doi: 10.1016/j.arth.2004.11.022
- Sonsale PD, Philipson MR. (2007) Pseudogout after total knee arthroplasty. *The Journal of arthroplasty* 22(2):271-272. doi: 10.1016/j.arth.2006.10.004
- Carter JL, Endres NK, Halsey DA. (2012) Bilateral Acute Calcium Pyrophosphate Crystal Arthritis After Bilateral Total Knee Arthroplasty A Case Report. *The Journal of Bone & Joint Surgery Case Connector* 2(4):e59-1. doi: 10.2106/JBJS.CC.K.00167
- Hunte TC, Bernstein HM, Dickinson GM. Acute Crystalline Arthritis in an Artificial Knee. *JCR: Journal of Clinical Rheumatology* 2012;18(4):203-204. doi: 10.1097/RHU.0b013e318258b582
- Koyama K, Ohba T, Sato H, Haro H. (2012) Pseudogout Mimicking Infection Following Total Knee Arthroplasty A Report of Two Cases. *The Journal of Bone & Joint Surgery Case Connector* 2(1):e3-1. doi: 10.2106/JBJS.CC.K.00049
- Levi GS, Sadr K, Scuderi GR. (2012) Bilateral pseudogout 8 years after bilateral total knee arthroplasty. *Orthopedic Clinics of North America* 43(5):e59-e62. doi: 10.1016/j.ocl.2012.07.009
- Harato K, Yoshida H. (2013) Pseudogout in the early postoperative period after total knee arthroplasty. *The Journal of arthroplasty* 28(2):374-e9. doi: 10.1016/j.arth.2012.03.017
- Swayamprakasam AP, Taqvi S, Hossain S. (2013) A case of mistaken identity: pseudogout in a prosthetic knee. *British journal of hospital medicine (London, England; 2005)* 74(1):54. doi: 10.12968/hmed.2013.74.1.54
- Söderquist B, Jones I, Fredlund H, Vikerfors T. (1998) Bacterial or crystal-associated arthritis? Discriminating ability of serum inflammatory markers. *Scandinavian journal of infectious diseases* 30(6):591-596. doi: 10.1080/0036554985016115
- Ghanem E, Parvizi J, Burnett RSJ, Sharkey PF, Keshavarzi N, Aggarwal A et al. (2008) Cell count and differential of aspirated fluid in the diagnosis of infection at the site of total knee arthroplasty. *The Journal of Bone & Joint Surgery* 90(8):1637-1643. doi: 10.2106/JBJS.G.00470
- Dinneen A, Guyot A, Clements J, Bradley N. (2013) Synovial

fluid white cell and differential count in the diagnosis or exclusion of prosthetic joint infection. *Bone & Joint Journal* 95(4):554-557. doi: 10.1302/0301-620X.95B4.30388

38. Choi MH, MacKenzie JD, Dalinka MK. (2006) Imaging features of crystal-induced arthropathy. *Rheumatic Disease Clinics of North America* 32(2):427-446. doi: 10.1016/j.rdc.2006.04.001
39. Schlesinger N. (2005) Diagnosis of gout: clinical, laboratory, and radiologic findings. *Am J Manag Care* 11(15):S443-50.
40. Yu KH, Luo SF, Liou SB, Wu YJJ, Tsai WP, Chen JY et al. (2003) Concomitant septic and gouty arthritis—an analysis of 30 cases. *Rheumatology* 42(9):1062-1066. doi: 10.1093/rheumatology/keg297
41. Hindle P, Davidson E, Biant LC. (2012) Septic arthritis of the knee: the use and effect of antibiotics prior to diagnostic aspiration. *Annals of the Royal College of Surgeons of England* 94(5):351-355. doi: 10.1308/003588412X13171221591015
42. Parvizi J, Zmistowski B, Berbari EF, Bauer TW, Springer BD & Della Valle CJ. (2011) New definition for periprosthetic joint infection. *Am J Orthop (Belle Mead NJ)* 40(12):614-615.

Peer reviewer: Bakir Kadum, Orthopedic department, Sundsvall hospital, 856 43 Sundsvall, Sweden.