

Bilateral Supracondylar Femoral Stress Fractures in an Adolescent: A Case Report

Bardia Barimani, Donald Davidson, Bilal Al-Obaidi, Reza Mobasheri

Bardia Barimani, Donald Davidson, Bilal Al-Obaidi, Reza Mobasheri, St Mary's Hospital, Imperial College London NHS Healthcare Trust, London, the United Kingdom

Donald Davidson, Queen Elizabeth Hospital, University Hospitals Birmingham NHS Foundation Trust, Birmingham, the United Kingdom

Correspondence to: Bardia Barimani, St Mary's Hospital, Imperial College London NHS Healthcare Trust, London, the United Kingdom

Telephone: +44-07837638371

Email: bardia.barimani@nhs.net

Received: September 5, 2015

Revised: October 3, 2015

Accepted: October 8, 2015

Published online: October 23, 2015

ABSTRACT

Bilateral supracondylar stress fractures of the femur in adolescents is a rare presentation. Due to the uncommon and non-specific presentation there is a high risk of misdiagnosis and thus detrimental complications. We report a case of bilateral supracondylar femur stress fractures in an 18 year old male of Somali ethnic background who presented to our institution with a right oblique supracondylar fracture of the femur with evidence of sclerotic fracture edges. The patient was found to have symmetrical bilateral stress fractures of the femur which were missed in primary care and as a result of this weakening it ultimately lead to a fracture. Although stress fractures are most commonly seen in the osteoporotic population, other factors include: exercise type, anatomical and hormonal variables. Our case report highlights predisposition to stress fractures and the importance of heightened clinical suspicion when faced with adolescents presenting with chronic musculoskeletal pain.

© 2015 ACT. All rights reserved.

Key words: Stress Fractures; Bilateral; Supracondylar Femur

Barimani B, Davidson D, Al-Obaidi B, Mobasheri R. Bilateral Supracondylar Femoral Stress Fractures in an Adolescent: A Case Report. *International Journal of Orthopaedics* 2015; 2(6): 484-486 Available from: URL: <http://www.ghrnet.org/index.php/ijo/article/view/1349>

CASE REPORT

An 18-year-old male of Somali ethnic background presented to accident and emergency with severe pain and swelling in his right knee. He had been playing football and described jumping and landing awkwardly on his right side. The patient described a mild but constant right knee pain over the last few years which exacerbated with strenuous activity. He also described similar left sided knee symptoms but had been reassured by his GP that the diagnosis was likely to be growing pains. He had no other past medical history and was a recreational footballer. On examination he had right-sided suprapatellar swelling with moderate effusion of the knee, was neurovascularly intact distally in the limb, had soft compartments and no evidence of an open injury.

Bilateral radiographs were performed at presentation with Figure 1 A and B demonstrating an oblique supracondylar fracture of the right femur with evidence of sclerotic fracture edges and Figure 1 C showing a left distal femur indicating evidence of an oblique lucency in the supracondylar region associated with circumferential cortical thickening but no acute cortical break evident.

Due to the acute right sided fracture, the patient was admitted and underwent a right retrograde femoral intramedullary nailing to stabilise the injury (Figure 2). A diagnosis of bilateral femoral stress fractures was made by exclusion of a pathological fracture. Pathological fracture was ruled out by clinical examination and history, sending specimens for analysis via histopathology and microscopy showing no evidence of infection or neoplasia and via imaging as described above.

The patient was assessed by the endocrine and rheumatology teams who diagnosed a serum Vitamin D deficiency [serum Vitamin D 14.6 ug/L (range 25-80 ug/L)] with his metabolic bone screen being unremarkable.

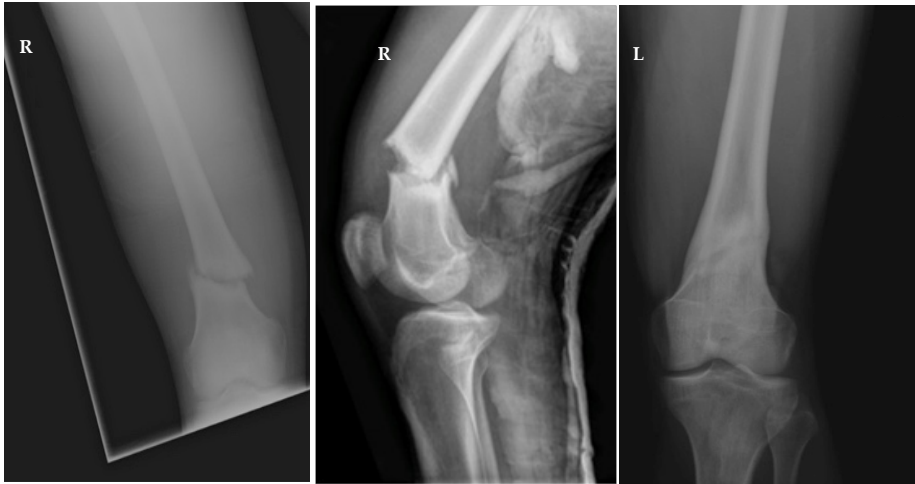


Figure 1 Radiographs at presentation. A,B) Right, AP and lateral (respectively), distal femur, oblique supracondylar fracture. C) Left, AP, oblique lucency in the supracondylar region, circumferential cortical thickening.

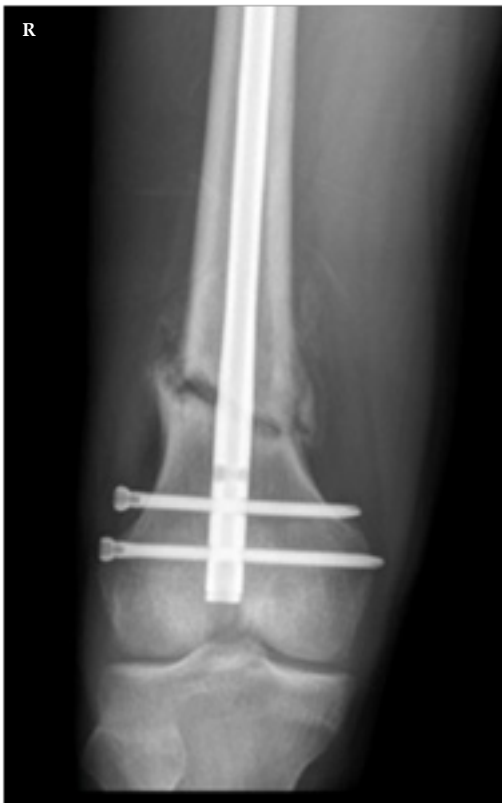

Figure 2 Post-op radiograph - Right, AP, post retrograde femoral intramedullary nailing.

OUTCOME AND FOLLOW-UP

The patient made a full recovery and the screws were removed without imaging guidance. He returned to sports and has a full range of knee and hip motion. The patient was commenced on Vitamin D replacement therapy.

DISCUSSION

A Stress fracture is an overuse injury that occurs as a result of repetitive loading below yield^[1]. They occur if the loading frequency is high enough so that the rate of bone resorption exceeds the rate of

bone formation during the remodelling process^[3]. The epidemiology of stress fractures in athletes is that they tend to occur in the early phases of training or when a training regimen is significantly increased^[4]. The commonest area for stress fractures has been found to be the tibia with 23.6% of all stress fractures followed by the tarsal navicular with 17.6% and metatarsals with 21%^[2]. Stress fractures of the femur are uncommon (6.6%)^[2] and can be split into femoral neck (50%), condylar region (24%) or proximal shaft (18%)^[1]. Stress fractures are more common in the elderly osteoporotic population where physiological muscular activities stress bone, deficient in mineral and elastic resistance, causing what are termed insufficiency fractures^[5]. Stress fractures are diagnosed by clinical examination and history, imaging if chronic stress fracture and exclusion of pathological fracture.

Stress fractures present with localised pain that comes on at the end of physical activity, which can be juxtaposed to soft tissue injuries that tend to be painful first thing in the morning and improve with exercise^[4]. If the stress fracture is not treated, the pain experienced will usually have an earlier onset during the exercise regime and stay for a longer period of time. A history is very important because usually you will find that the patient has changed their normal training regime 2 to 6 weeks prior to their presentation^[4]. On examination you expect to find local tenderness over the affected area and thus a thorough examination must be conducted and any abnormal features taken note of.

Radiographic findings are found 2 to 8 weeks after symptom onset. At this time point the sensitivities of the radiographs can be as low as 10%, which increases up to 70% on follow up^[6]. With the potential that stress fractures will take 8 weeks to become evident on radiological imaging this may not be of great diagnostic use^[6,7]. Typical findings include a fine area of periosteal bone elevation, sclerosis and an area of low-density bone may also be seen^[8]. MRI is currently the gold standard to assess stress fractures due to its ability to exhibit soft tissue and bone oedema, an early feature of stress fractures.

Vitamin D deficiency is very common with 30-50% of the global population being at risk of vitamin D deficiency^[8]. In children, vitamin D deficiency will cause growth retardation and potentially signs and symptoms of rickets^[9]. In adults vitamin D deficiency will lead to osteopaenia and osteoporosis thus increasing the risk of fractures^[10]. Low vitamin D levels lead to un-mineralised bone which lack support for the periosteal covering^[10]. This can cause generalised

bony pain^[11] and as with our patient, increase risk of stress fractures. Calcium for bone mineralisation and vitamin D for bone homeostasis and remodelling have been shown to be protective agents^[12]. The commonest cause of vitamin D deficiency is insufficient exposure to sunlight and the management for this being vitamin D and calcium supplementation^[10].

The treatment for stress fractures depends on the severity; initially conservative therapy can be trialled including rest or immobilisation for 6-8 weeks progressing to low impact rehabilitation exercises to maintain strength (e.g. pool walking and elliptical exercise machines)^[13]. If conservative therapies are unsuccessful or not clinically indicated, then surgical interventions can be deployed as in our case^[13].

Despite the prevalence of vitamin D deficiency and stress fractures, it is evident from reviewing the current literature that our patient's presentation of bilateral supracondylar femoral stress fractures is uncommon. There are only two previous reported similar cases; the first being a female long-distance runner with bilateral femoral shaft stress fractures as a consequence of over-use from inappropriate training, mal-alignment, nutritional deficiencies, and an endocrine disorder^[14] and the second being bilateral femoral supracondylar stress fractures in a cross country runner caused by a vegan diet resulting in low protein and calcium levels^[15].

Bilateral supracondylar femoral stress fractures in adolescents is a rare presentation. This case highlights the importance of heightened clinical suspicion and early diagnosis of stress fractures in patients presenting with a typical history (i.e. musculoskeletal pain associated with activity that subsides with rest) in order to prevent subsequent morbidity. It also highlights the importance of assessing vitamin D levels in patients diagnosed with a stress fracture.

CONFLICT OF INTERESTS

There are no conflicts of interest with regard to the present study.

REFERENCES

- 1 Behrens SB, Deren ME, Matson A, Fadale PD, Monchik KO. Stress fractures of the pelvis and legs in athletes: a review. *Sports Health* 2013; Mar;5(2):165-74.
- 2 Kahanov L, Eberman LE, Games KE, Wasik M. Diagnosis, treatment, and rehabilitation of stress fractures in the lower extremity in runners. *Open Access J Sports Med* 2015 Mar 27;6:87-95.
- 3 Zadpoor AA, Nikooyan AA. The relationship between lower-extremity stress fractures and the ground reaction force: a systematic review. *Clin Biomech (Bristol, Avon)* 2011; Jan;26(1):23-8.
- 4 Magness S, Ambegaonkar JP, Jones MT, Caswell SV. Lower Extremity Stress Fracture in Runners: Risk Factors and Prevention. *Injury Prevention & Performance Enhancement* 2011; Jul 16 (4): 11-15.
- 5 Prasad N, Murray JM, Kumar D, Davies SG. Insufficiency fracture of the tibial plateau: an often missed diagnosis. *Acta Orthop Belg* 2006; Oct;72(5):587-91.
- 6 Niva MH, Mattila VM, Kiuru MJ, Pihlajamaki HK. Bone stress injuries are common in female military trainees: a preliminary study. *Clin Orthop Relat Res* 2009; Nov;467(11):2962-
- 7 Delvaux K, Lysens R. Lumbosacral pain in an athlete. *Am J Phys Med Rehabil* 2001 May;80(5):388-391.
- 8 Tangpricha V, Pearce EN, Chen TC, Holick MF. Vitamin D insufficiency among free-living healthy young adults. *Am J Med* 2002; Jun 1;112(8):659-62.
- 9 Holick MF. Resurrection of vitamin D deficiency and rickets. *J Clin Invest* 2006; Aug;116(8):2062-72.
- 10 Holick MF. Vitamin D deficiency. *N Engl J Med* 2007; Jul 19;357(3):266-81.
- 11 Holick MF, Chen TC. Vitamin D deficiency: a worldwide problem with health consequences. *Am J Clin Nutr* 2008; Apr;87(4):1080S-6S.
- 12 Pepper M, Akuthota V, McCarty EC. The pathophysiology of stress fractures. *Clin Sports Med* 2006; Jan;25(1):1,16, vii.
- 13 Romani WA, Gieck JH, Perrin DH, Saliba EN, Kahler DM. Mechanisms and management of stress fractures in physically active persons. *J Athl Train* 2002; Jul;37(3):306-14.
- 14 Weind KL, Amendola A. Rare bilateral femoral shaft stress fractures in a female long-distance runner: a case report. *Iowa Orthop J* 2005;25:157-9.
- 15 Ross K, Fahey M. Bilateral femoral supracondylar stress fractures in a cross country runner. *Orthopedics* 2008; Aug;31(8):803. Written informed consent was obtained from the patient for publication of this Case report and any accompanying images.

Peer reviewer: Sun, Wei MD, Associate Professor, Department of Orthopedic, China-Japan Friendship Hospital, 2 Yinghuadong Road, Chaoyang District, Beijing, China.