

## Surgical Outcomes of Two Portal Percutaneous Endoscopic Decompression for Adjacent Segment Disease: Preliminary Case Series of 21 Patients

Torudom Yingyong, Dilokhuttakarn T

Torudom Yingyong, Dilokhuttakarn T, Department of Orthopedic Surgery, HRH Maha Chakra Sirindhorn Medical center, Faculty of Medicine, Srinaharindwirot University, Nakorn, Thailand

Correspondence to: Torudom Yingyong, MD, Department of Orthopaedic Surgery, HRH Maha Chakri Sirindhorn Medical center, 62 Moo 7 Rangsit-Nakorn Nayok Road, Ong-karuk Subdistrict, Ong-karuk District, Nakorn Nayok Province 26120, Thailand.

Email: [torudom@hotmail.com](mailto:torudom@hotmail.com)

Telephone: +66-3739-5085 ext 11408

Received: July 12, 2015 Revised: August 17, 2015

Accepted: August 23, 2015

Published online: October 23, 2015

### ABSTRACT

**AIM:** Adjacent segment disease (ASD) is a complication following lumbar spine decompression and fusion surgery. Whether it is a new degenerative process or iatrogenic from biomechanically altering motion segments that create additional foreign stressors. There are two problems in ASD that may not come together, new compression segment adjacent to previous operative level or spinal instability following previous operation. Appropriate treatment is spinal decompression alone or spinal decompression and fusion. There are only few reports on endoscopic surgery for ASD. This study aimed to show surgical outcomes of two portal percutaneous endoscopic decompression without fusion for ASD.

**METHODS:** Twenty one patients who underwent two portal percutaneous endoscopic decompression for ASD were retrospectively investigated (follow-up at least two years). Operative complications, VAS-back pain, VAS-leg pain, ODI and Macnab criteria were used as outcome measures.

**RESULTS:** Mean VAS- leg pain improved from 7.9+2.1 just before operation to 1.9+1.1 at two years follow-up ( $P < 0.05$ ). VAS- back pain improved from 3.5+2.2 before operation to 2.9+1.4 at two years follow up difference was statistically insignificant. The ODI score was improved from 63.2+10.7 to 24.0+14.5 ( $P < 0.05$ ) at two years follow up. One patient was converted to open decompression

due to intraoperative endoscopic difficulty. One patient underwent pedicle screws fixation and fusion after percutaneous endoscopic decompression because of post-operative instability.

**CONCLUSION:** Two portal percutaneous endoscopic decompression is effective procedure for leg pain relief in ASD. This is a short term results. Long term follow up is required because decompression alone may lead to progressive instability and recurrent symptoms.

© 2015 The Authors. Published by ACT Publishing Group Ltd.

**Key words:** Endoscope; Decompression; Spinal stenosis; Adjacent segment degeneration

Torudom Y, Dilokhuttakarn T. Surgical Outcomes of Two Portal Percutaneous Endoscopic Decompression for Adjacent Segment Disease: Preliminary Case Series of 21 Patients. *International Journal of Orthopaedics* 2015; 2(5): 427-431 Available from: URL: <http://www.ghrnet.org/index.php/ijo/article/view/1353>

### INTRODUCTION

Adjacent segment disease (ASD) is one of the problematic complications following lumbar spine instrumentation and fusion<sup>[1]</sup>. ASD is the result of the normal progression of degenerative changes or biomechanical alteration caused by fusion remains controversial<sup>[2]</sup>. Pathologic processes observed at adjacent segments include new stenosis segment or additional spinal instability<sup>[3,4]</sup>. The clinical incidence of symptomatic ASD is reportedly 5.2-18.5%<sup>1</sup> and the incidence of re-operation for symptomatic ASD is reported 3.0-11.0 % of patients after spinal fusion<sup>[5,6]</sup>. A prospective randomized study reported that fusion accelerates degenerative changes at the adjacent segment of fused spine compared with naturally occurring changes<sup>[7]</sup>. Spinal fusion changes the biomechanics of spinal motion or the load on facet joints of the adjacent motion segment of the fused spine<sup>[1]</sup>. The surgical approach to symptomatic ASD remains controversial. Some surgeons reported treatment of patients of ASD

by decompression surgery while others recommend adjunctive fusion surgery<sup>[8-12]</sup>. In this study, we apply two portal percutaneous endoscopic decompression for symptomatic ASD without spinal instability. This procedure has the following principles: (1) the use of ordinary arthroscopic and spine instruments without need for special endoscopic sets (Figure 1), (2) free movement and angulation of the surgical tool and the endoscope independent of each other as they are not restricted by the confines of a common working portal which results in marked reduction in the technical difficulties, (3) the use of saline irrigation abolishes the problem of repeatedly cleaning the endoscopic lens of accumulated fog or blood. Few studies have dealt with surgical outcomes of symptomatic ASD<sup>[8,10,11,13]</sup>. In addition, few reports have discussed surgical outcomes of percutaneous endoscopic decompression for ASD. The purpose of this study was to report a series of patients who had undergone two portal endoscopic decompression for ASD without supplemental pedicle screw fixation.

## MATERIALS AND METHODS

This study was approved by our Institutional Review Board and informed consent was obtained from each patient. Totally 21 consecutive patients undergoing percutaneous endoscopic decompression for ASD between January 2012 and June 2013 were enrolled in this study. The inclusion criteria were as follows: (1) clinical and radiographic findings were consistent with progressive degeneration at the adjacent spinal level(s) with associated leg symptoms; (2) The patients were fail to conservative measures, including physical therapy, anti-inflammatory medications, low-dose narcotics, and physical therapy; (3) The follow up periods were at least two years. Patients were excluded from the study if they had undergone surgery for a non-degenerative etiology such as infection or trauma. They were also excluded if there were radiographic instability in flexion-extension radiographs.

### Surgical technique

The patients were positioned prone in kneeling position after general anesthesia. The operated level was identified with image intensifier. Endoscope portal and working portal were inserted through the two separated skin incision and docked onto the lamina. (Figure 2) The localization was reconfirmed with lateral view of fluoroscopy before the decompression. We performed unilateral laminotomy for decompression of the central canal and bilateral lateral recesses. Decompression of the ipsilateral lateral recess was achieved by partial facetectomy. In order to preserve integrity of the facet joint as much as possible, we used instruments such as high-speed pneumatic burr, Kerrison rongeur to undercut the facet joint. Then we tilted the endoscope to the central canal and contralateral lateral recess. This process was performed by gently moving the endoscope over the dural sac. After that the ligamentum flavum was excised and the lamina was undercut. The adequacy of decompression was determined by observing the dural sac and probing the traversing nerve roots to confirm the extent of decompression. The endpoint of decompression was the outer edges of the bilateral nerve roots. Case demonstration was shown with figure 3-5. After hemostasis, no drain was placed, and the incision was closed. Ambulation was allow immediately after the surgery with a lumbrosacral support.

The patients' preoperative and follow-up functions were evaluated using the Oswestry Disability Index (ODI), Macnab criteria and Visual analog score (VAS) that obtained separately for leg and back pain. Scoring was performed at routine postoperative clinic visits and determined using a 10-point scale, with 10 being the greatest

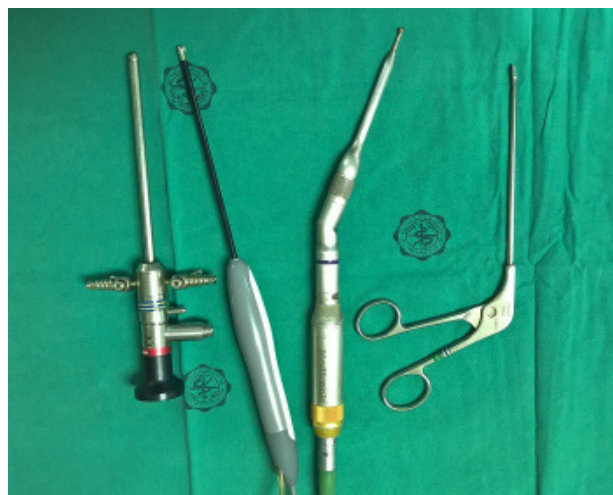

Figure 1 The instruments that were used in the operation.

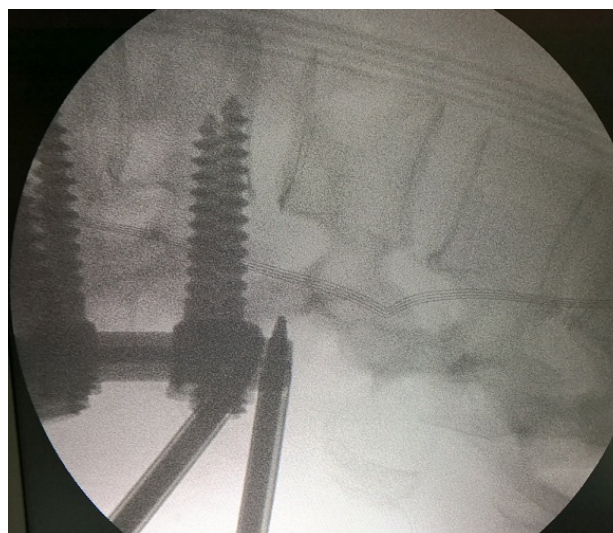


Figure 2 The endoscope was docking on lamina.

pain and 0 being the absence of pain. Patients were evaluated six month, one year, and two years post-operative visit. The data about the pre-operative comorbidities, intraoperative and post-operative complications were retrieved from medical chart review.

### Statistical Analysis

Continuous variables were presented as means  $\pm$  standard deviations. Categorical variables were presented as counts and percentages. Repeated analysis of variance (ANOVA) was performed to compare the differences of Oswestry Disability Index (ODI), and Visual Analogue Scale (VAS). The statistical analyses were performed with SPSS software version 15 (SPSS Inc, Chicago, IL, USA), and two-tailed  $p < 0.05$  indicated statistical significance.

## RESULTS

During the study period, 21 consecutive patients were treated with two portal percutaneous endoscopic decompression. The follow up was at least 24 months (30 $\pm$ 6). The mean patient age was 65.4 years (range 50-71 years), and 57% of the patients were female (12 from 21). The average duration from previous operation and second operation were 8.2 $\pm$ 3.4 years. The presenting symptoms were

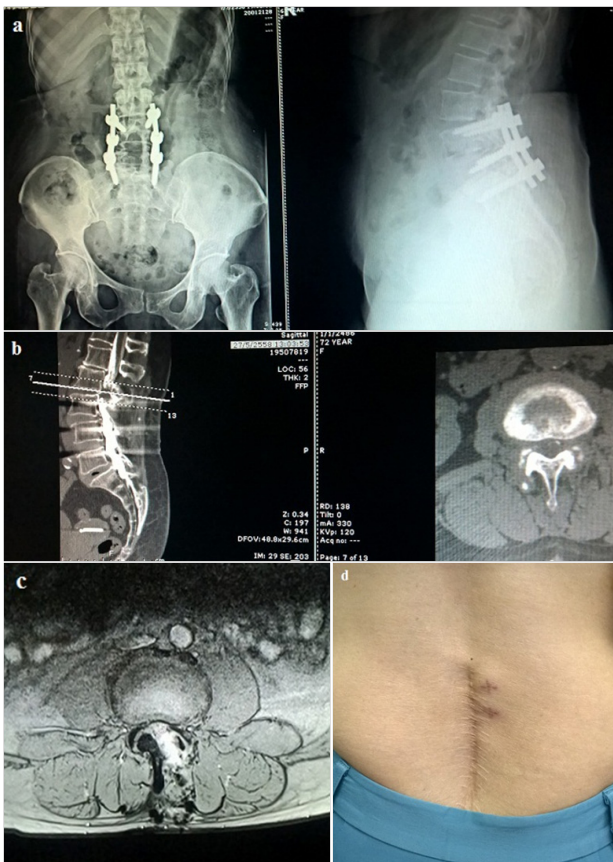radicular pain (100%) and back pain (38%). The previous surgery had been performed for a mean of 2.1 decompression and fusion levels (range 1-4 levels). Four of the patients (19%) had one-level fusion,

five (23.8%) had two-level fusion and the remainders had fusion of more than two levels. Endoscopic decompression was performed at the L1-2 level (1 case), the L2-3 level (10 cases), the L3-4 level (9 cases), and the L5-S1 level (1 case). The mean total operative time was 120.2±29.5 minutes (range 95-155 minutes). There was one conversion to open surgery because of intra-operative endoscopic difficulty. There was no case in which posterior pedicle screws had to be revised. The in-patient duration of stay averaged 2.8±1.2 days (range 2-4 days). All patients were discharged home.

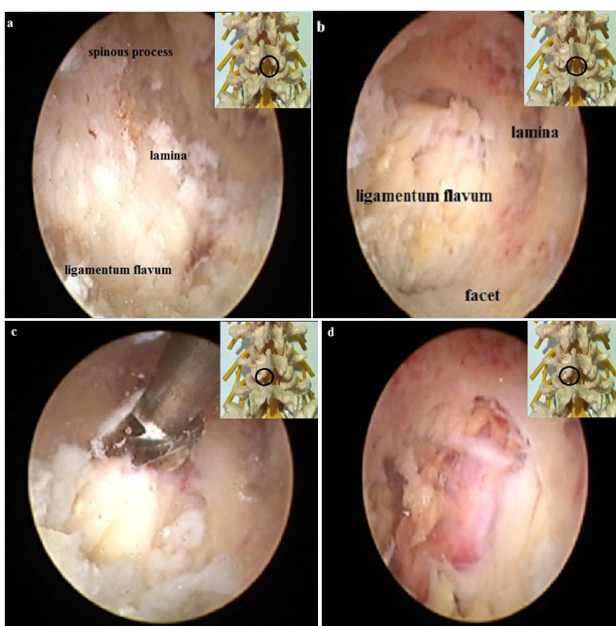
The leg pain VAS improved from a mean of 7.9±2.1 to 1.9±1.1 ( $P < 0.05$ ) at two years follow up (Graph 1), and the back pain VAS improved from a mean of 3.5±2.2 to 2.9±1.4 (statistical insignificance) at two years follow up (Graph 2). The mean preoperative ODI score was improved from 63.2±10.7 to 24.0±14.5 ( $P < 0.05$ ) at two years follow up. We obtained good results in 71.4% (15 patients) according to the Macnab criteria, fair results in 23.8% (5 patients) and poor result in one patient.

### Complications

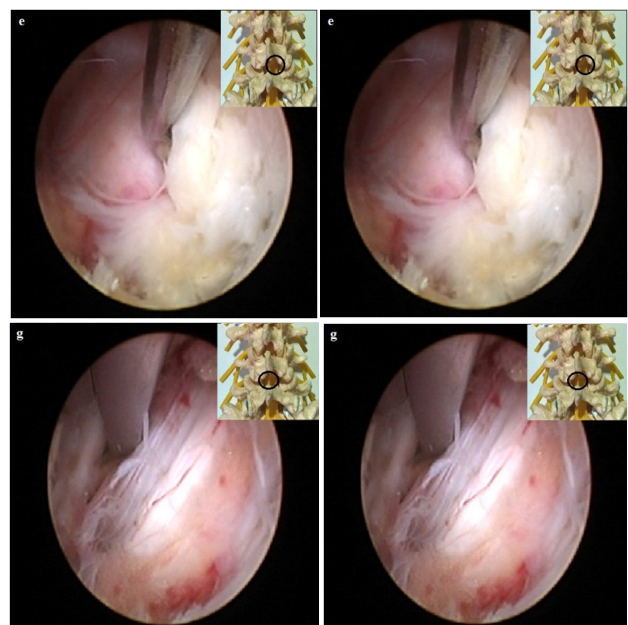
There were no major intraoperative or perioperative complications. Two patient had transient dysesthesia, which resolved at three-month follow-up. There are three case of post-operative cystitis that defined as minor complication. All of them were treated with oral antibiotics and recovered without complication. However, there were no cases of vascular insults, deep wound infections or cerebrospinal fluid leakage. According to Macnab criteria, there was one case with poor result.. This patient was defined as failure. The patient experienced mild post-operative clinical improvement. He had symptoms primarily of neurogenic claudication and back pain. Although the symptoms of leg pain improved, the patient continued to experience back pain. Flexion and extension X-rays showed instability. He later underwent pedicle screws fixation and fusion. After the fusion procedure, he experienced symptom relief. This patient demonstrated bridging bone on CT scanning at the last follow-up, indicating solid bony fusion.



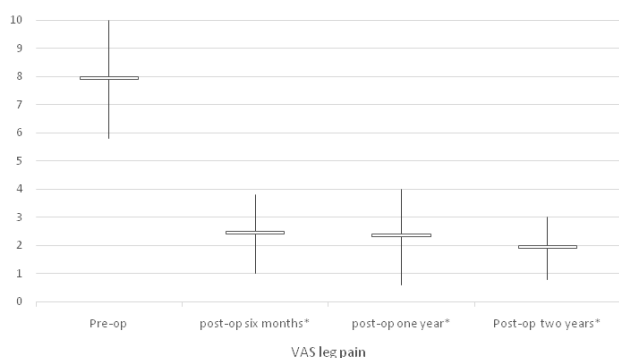
**Figure 3** a: Pre-operative X-ray revealed ASD following L3-5 laminectomy and fusion. b: Computer tomography with myelography show dural sac compression. c: Post-operative MRI of the same patient show complete decompression. d: Post-operative photograph.



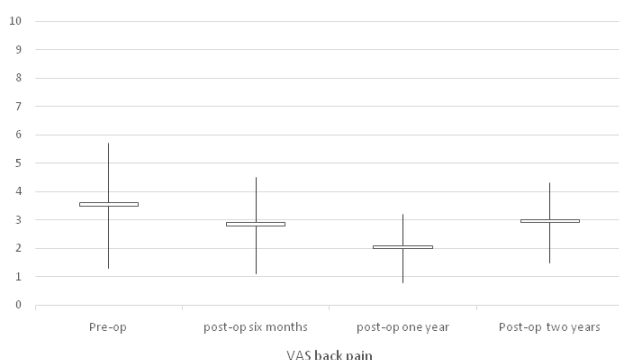
**Figure 4** a: Lamina and ligamentum flavum were seen from potential space. b: Ipsilateral lamina was remove with high speed burr. c: Contralateral lamina was removed. d: Contralateral ligamentum flavum was excised.



**Figure 5** Endoscopic views e. Ligamentum flavum was dissected from dural sac with Penfield dissector. f. Ipsilateral ligamentum flavum was excised with Kerrison rongeur g. Contralateral nerve root was probe with Penfield dissector h. Complete procedure, nerve root was free mobilization.



**Graph 1** Visual analog scale (VAS) leg pain score preoperatively, at 6 months, at 1 year, and at the two years follow up. (\*  $p < 0.05$ ).



**Graph 2** Visual analog scale (VAS) back pain score preoperatively, at 6 months, at 1 year, and at the two years follow up. (\*  $p < 0.05$ ).

**Table 1** Visual analog scale (VAS) pain score and Oswestry Disability Index (ODI) scores preoperatively, at 6 months, at 1 year, and at the two years follow up. (\*  $p < 0.05$ ).

	Pre-operative	Six month post-op	One year post-op	Two year post-op
VAS back pain	3.5 ± 2.2	2.8 ± 1.7*	2.0 ± 1.2*	2.9 ± 1.4*
VAS leg pain	7.9 ± 2.1	2.4 ± 1.4*	2.3 ± 1.7*	1.9 ± 1.1*
ODI	63.2 ± 10.7	24.3 ± 21.1*	23.3 ± 17.2*	24.0 ± 14.5*

## DISCUSSION

Adjacent-level degeneration has been reported to occur after lumbar fusion surgery<sup>[14]</sup>. In a recent literature review, the rate of symptomatic ASD after decompression and stabilization procedures was approximated to 2%-3% per year<sup>[15]</sup>. This high incidence, the surgeons are encountering a growing population of patients in need of treatment for ASD. In the previous study using classic open decompression for revision surgery, the reports identified improvement in clinical signs and symptoms of both back and leg pain<sup>[16,17]</sup>. These findings suggest that supplemental posterior instrumentation does not always need to be performed for all cases of ASD treated surgically. This case series, two portal percutaneous endoscopic decompression had the mean hospital stay of 2.8 days and no major intra-operative complication. This technique, is likely to cause less morbidity than the open approach to the spine. The advantage of the two portal percutaneous endoscopic decompression relates to the fact that the posterior spinal elements, including the facet joint capsules and para-spinal muscle, are minimally disrupted through an endoscopic technique. Thus additional degeneration at the supra-adjacent level may also be less likely to occur. There are several limitations to this study. The first is the difficult surgical technique. The surgeon must familiar with both arthroscopic

and minimal invasive spinal decompression technique. During percutaneous endoscopic decompression, triangulation techniques were used to assess and remove the pathologic tissue. If the surgeons were not familiar with this technique, the operations are very difficult and time consuming. Another limitation relates to the ability to generalize the results. With regard to the relief of neurological symptoms of stenosis, the two portal percutaneous endoscopic decompression relies entirely on direct decompression of the spinal canal. While we found excellent clinical results, one might expect this technique to be occasionally inadequate in cases of the ASD patients who have the instability more than the neural element compression. A larger study with a long term follow up would be helpful to validate this technique across the broad spectrum of ASD. Other major limitation of this study relates to our ability to ascertain post-operative instability because post-operative flexion-extension radiographs were not taken routinely. Longer follow up period with dynamic films are required for instability detection.

## CONCLUSION

The two portal percutaneous endoscopic decompression was safe and effective for the treatment of ASD. Leg pain relief was statistical significant more than back pain relief. Post-operative spinal instability may preclude this technique. Long-term prospective analyses with dynamic radiograph are warranted to determine the longevity of the two portal percutaneous endoscopic decompression in the treatment of ASD.

## CONFLICT OF INTERESTS

There are no conflicts of interest with regard to the present study.

## REFERENCES

- 1 Park P, Garton HJ, Gala VC, Hoff JT, McGillicuddy JE. Adjacent segment disease after lumbar or lumbosacral fusion: review of the literature. *Spine* 2004; 29:1938–1944.
- 2 Lawrence BD, Wang J, Arnold PM, Hermsmeyer J, Norvell DC, Brodke DS, et al. Predicting the risk of adjacent segment pathology after lumbar fusion: a systematic review. *Spine* 2012; 37(22 Suppl):S123–S132.
- 3 Hambly MF, Wiltse LL, Raghavan N, et al. The transition zone above a lumbosacral fusion. *Spine* 1998; 23:1785–1792.
- 4 Ishihara H, Osada R, Kanamori M, et al. Minimum 10-year follow-up study of anterior lumbar interbody fusion for isthmic spondylolisthesis. *J Spinal Disord* 2001; 14:91–99.
- 5 Cho KS, Kang SG, Yoo DS, Huh PW, Kim DS, Lee SB. Risk factors and surgical treatment for symptomatic adjacent segment degeneration after lumbar spine fusion. *J Korean Neurosurg Soc* 2009; 46:425–430.
- 6 Sears WR, Sergides IG, Kazemi N, Smith M, White GJ, Osburg B. Incidence and prevalence of surgery at segments adjacent to a previous posterior lumbar arthrodesis. *Spine J* 2011; 11:11–20.
- 7 Ekman P, Moller H, Shalabi A, Yu YX, Hedlund R. A prospective randomized study on the long-term effect of lumbar fusion on adjacent disc degeneration. *Eur Spine J* 2009; 18:1175–1186.
- 8 Chen WJ, Lai PL, Niu CC, Chen LH, Fu TS, Wong CB. Surgical treatment of adjacent instability after lumbar spine fusion. *Spine* 2001; 26:E519–E524.
- 9 Gillet P. The fate of the adjacent motion segment after lumbar fusion. *J Spinal Disord Tech* 2003; 16:338–345.
- 10 Schlegel JD, Smith JA, Schlessener RL. Lumbar motion segment pathology adjacent to thoracolumbar, lumbar, and lumbosacral fusions. *Spine* 1996; 21:970–981.
- 11 Whitecloud TS, Davis JM, Olive PM. Operative treatment of the

- degenerated segment adjacent to a lumbar fusion. *Spine* 1994; 19:531–536.
- 12 Chou D, Dekutoski M, Hermsmeyer J, Norvell DC. The treatment of lumbar adjacent segment pathology after a previous lumbar surgery: a systematic review. *Spine* 2012; 37:S180–S188.
  - 13 Phillips FM, Carlson GD, Bohlman HH, Hughes SS. Results of surgery for spinal stenosis adjacent to previous lumbar fusion. *J Spinal Disord* 2000; 13:432–437.
  - 14 Xia XP, Chen HL, Cheng HB. Prevalence of adjacent segment degeneration after spine surgery: a systematic review and meta-analysis. *Spine* 2013; 38(7):597–608.
  - 15 Radcliff KE, Kepler CK, Jakoi A, Sidhu GS, Rihn J, Vaccaro AR, et al. Adjacent segment disease in the lumbar spine following different treatment interventions. *Spine J* 2013; 13(10):1339–1349.
  - 16 Schlegel JD, Smith JA, Schleusener RL. Lumbar motion segment pathology adjacent to thoracolumbar, lumbar, and lumbosacral fusions. *Spine* 1996; 21 (8):970–81.
  - 17 Phillips FM, Carlson GD, Bohlman HH, Hughes SS. Results of surgery for spinal stenosis adjacent to previous lumbar fusion. *J Spinal Disord* 2000; 13(5):432–437.

**Peer reviewers:** Charles-Henri Flouzat Lachaniette, Hôpital Henri Mondor (AP-HP / UPEC), Institut du Rachis, Service de chirurgie orthopédique et traumatologique, 51, avenue du Maréchal de Lattre de Tassigny, 94010 Créteil Cedex, France; Mohamed El-Sayed Abdel-Wanis, Professor, Orthopedic Department, Sohag Faculty of Medicine, Sohag University, Sohag, Egypt.