

## Isolated Rupture of the Pronator Teres in an Amateur Golfer: A Case Report

Brooks William Ficke, Matthew Carl Larrison, Brent Allen Ponce

Brooks William Ficke, Brent Allen Ponce, Division of Orthopaedic Surgery, University of Alabama at Birmingham, AL, the United States

Matthew Carl Larrison, Department of Radiology, University of Alabama at Birmingham, AL, the United States

Correspondence to: Brent Ponce, MD, Assistant Professor, Orthopaedic Specialties Building, 1313 13th Street South, Suite 203, Birmingham, AL, 35205-5327, the United States.

Email: [bponce@uabmc.edu](mailto:bponce@uabmc.edu)

Telephone: +1-205-930-8339 Fax: 1-205-930-8568

Received: October 20, 2015 Revised: November 16, 2015

Accepted: November 20, 2015

Published online: December 23, 2015

### ABSTRACT

We report a case of isolated rupture of the muscle belly of the pronator teres in an amateur golfer. This 59 year old male sustained an injury to his dominant arm while hitting a shot with his driver. He had no history of medial elbow pain. Physical exam revealed no instability, and no injury to the ulnar collateral ligament was seen on MRI. MRI demonstrated grade 3 strain of the pronator teres musculature without avulsion from the medial epicondyle. He was treated conservatively with rest and physical therapy, and he returned to play 4 weeks after injury. The pronator teres is often injured in cases of medial epicondylitis or ulnar collateral ligament tear, but ruptures without associated prodromal symptoms or ligamentous injury have rarely been described. We review the literature on injuries to the pronator teres and describe conservative management of this injury.

© 2015 ACT. All rights reserved.

**Key words:** Golf; Pronator Teres

Ficke BW, Larrison MC, Ponce BA. Isolated Rupture of the Pronator Teres in an Amateur Golfer: A Case Report. *International Journal of Orthopaedics* 2015; 2(6): 481-483 Available from: URL: <http://www.ghrnet.org/index.php/ijo/article/view/1382>

### INTRODUCTION

Injuries to the medial elbow are often found in golfers and overhead athletes. In addition to flexing and pronating the wrist, the flexor-pronator muscle mass is a dynamic stabilizer of the elbow during throwing or swing<sup>[1]</sup>. The pronator teres originates in two separate heads, the larger arising from the medial supracondylar ridge of the distal humerus and the smaller from the medial coronoid process of the ulna. It inserts on the lateral proximal radius just distal to the supinator. It is innervated by the median nerve, which passes between its two heads. It functions primarily to pronate the forearm and is also a weak elbow flexor. During throwing, the pronator teres provides dynamic support to the static stabilizers of the medial elbow<sup>[2]</sup>. While medial epicondylitis with associated pronator teres injury and ulnar collateral ligament rupture with pronator teres injury are well-described in the literature, isolated injury to the muscle belly of the pronator teres has seldom been reported<sup>[3,4,5]</sup>. In this report, we describe isolated rupture of the muscle belly of the pronator teres in an amateur golfer. The literature is reviewed, physical exam and imaging findings are discussed, and non-surgical treatment is recommended.

### CASE REPORT

A 59 year old right hand dominant male amateur golfer presented to the orthopedic sports medicine clinic complaining of 8 days of right medial elbow pain that worsened with activity and did not radiate. He was otherwise healthy and took an 81 mg aspirin daily for heart health. He denied ever experiencing right elbow pain prior to recent events. He noted that he had adjusted his golf swing approximately

6 weeks prior to injury. In an effort to learn to draw the ball, he was focusing on pronating his right (trailing) hand during contact and follow-through. In particular, he had been exaggerating this motion during the latter half of his swing to emphasize his form.

8 days prior to presentation, he experienced his first instance of medial elbow pain. He reported that while hitting his driver on the 3rd hole, he felt sudden sharp right medial elbow pain. He reported a good shot with a slight draw, and he did not take a divot. He was unable to continue play that day. Over the course of the evening he developed ecchymosis and swelling in his right medial proximal forearm. He initially self-treated with ice, anti-inflammatories, and elevation.

After 1 week of rest, his swelling had resolved and he returned to golf at the driving range. He was initially painless with short clubs, but had progressive return of pain with the use of longer clubs. That evening, he again developed severe bruising and swelling.

He presented to clinic the next day. On physical exam, he had marked ecchymosis and swelling throughout the volar side of the arm from mid-biceps to wrist. He was tender to palpation over the flexor-pronator muscle mass. Pain and swelling restricted him from achieving the last 10-15 degrees of both flexion and extension. There was no instability of the elbow to varus or valgus stress testing. He was neurologically intact distally. Differential diagnosis included fracture of the distal humerus, ulnar collateral ligament injury, medial epicondylitis, and injury to the flexor carpi radialis or the pronator teres. Radiographs revealed no fractures and no osteophyte formation. Magnetic resonance imaging revealed significant edema and hemorrhage in the belly of the pronator teres musculature consistent with grade 3 strain with hematoma, with edema extending to the level of the medial epicondyle but no avulsion from the medial epicondyle (Figure 1). No injury was seen in the ulnar collateral ligament.

He was treated with conservative measures including ice, compression, rest from sport, and physical therapy. Due to his extensive ecchymosis, aspirin and anti-inflammatories were held for 4 days before resumption. He was not immobilized but was instructed to avoid heavy use of the involved extremity. After 1 week

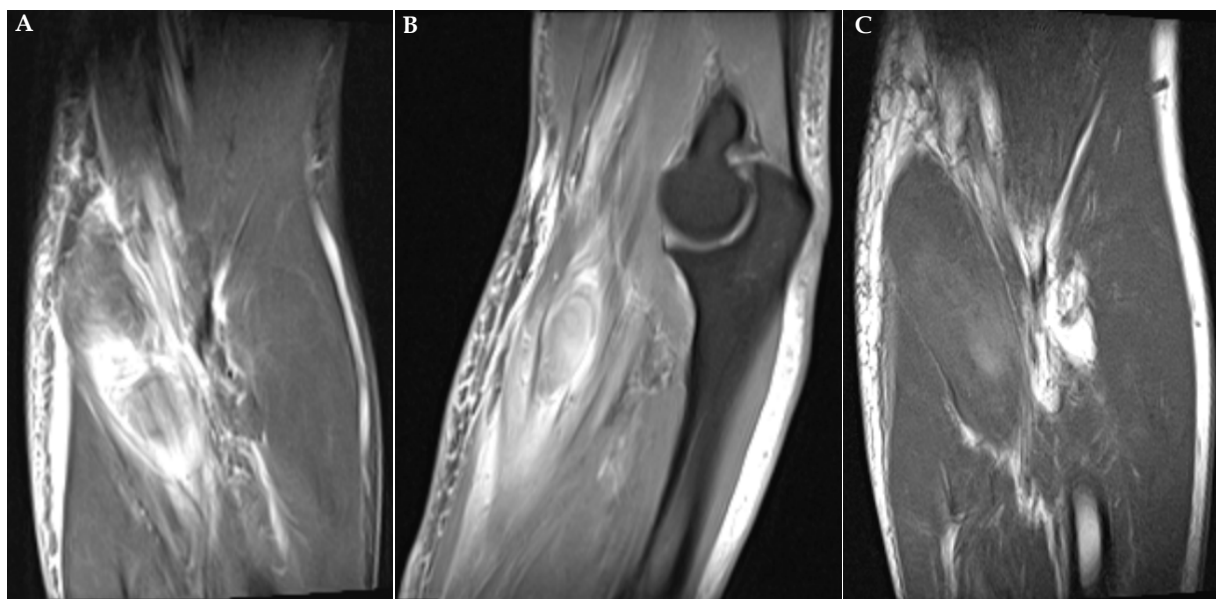
of rest, he started physical therapy, which included isometric wrist and elbow exercises along with pronator teres eccentric lowering with 5 pounds. By 2 weeks after presentation, he was pain-free with those exercises and progressed to resisted pronation/supination with a 5 pound weight. These exercises were pain-free by the 3rd week, and he started gentle swings with the golf club in the therapy office. By 4 weeks after presentation, he had pain-free full range of motion and no tenderness to palpation or pain with resisted pronation. At that point, he was released to return to golf. At 4 month follow-up, he has not had any return of symptoms and has continued to play.

The authors obtained the patient's written informed consent for print and electronic publication of the case report before submission.

## DISCUSSION

Golf is often considered a low-impact sport, and so the potential for injury can be overlooked. The medial elbow is a common source of pain in golfers, but rupture of the pronator teres has rarely been reported. This description of a pronator teres rupture in a golfer is the first such report in the English literature.

The differential diagnosis for medial elbow pain in athletes includes muscular strain or tear, medial epicondylitis, valgus extension overload with osteophyte formation, posteromedial impingement, ulnar collateral ligament injury, medial triceps injury, pronator teres syndrome, exertional compartment syndrome, and fracture. Injury to the pronator teres typically occurs in conjunction with trauma to the ulnar collateral ligament or as a degenerative tear with a history of medial epicondylitis<sup>[3,6,7]</sup>. Isolated injuries to the pronator teres are rarely reported in the literature. A high-grade muscle tear in a cricket batsman was reported in the Radiology literature, which was also treated conservatively<sup>[8]</sup>. Similar to the present case, that patient was participating in a sport with repetitive forearm pronation and rapid acceleration of the arm. Unlike in our case, that patient had medial elbow pain for over a month before his acute muscle tear. Our patient presented with medial elbow pain without any history of medial epicondylitis symptoms and without any elbow instability.



**Figure 1** Rupture of the pronator teres muscle belly. (A) coronal short tau inversion recovery, (B) sagittal proton density fat saturation, and (C) coronal T1 magnetic resonance images of the right elbow demonstrate disruption of muscle fibers and hematoma formation within the pronator teres. There is extensive surrounding edema throughout the mid-portion of the muscle.

While rates of injury per hour of participation in golf are lower than for some other sports such as tennis and badminton, one report identified that nearly one out of six of golfers sustained an injury over the course of 1 year<sup>[9]</sup>. Of these injuries, 17% involved the elbow or forearm, making it the 2nd most commonly injured area after the low back<sup>[9]</sup>. In another survey, change in grip or swing was cited as the mechanism of injury in 4% of injuries in amateur golfers, but was not noted to be a source of injury in professional golfers<sup>[10]</sup>. Electromyographic analysis of professional and amateur golfers found that amateur golfers demonstrated significantly greater muscle activity in the pronator teres of the trail arm (right arm in a right-handed golfer) during the forward swing phase and a trend towards greater muscle activity during the acceleration phase<sup>[11]</sup>. In amateur golfers, this muscle activation even exceeded the maximum muscle activation found during manual muscle testing<sup>[11]</sup>. Frequent adjustments in swing or grip and over-exertion of the trailing pronator teres in an effort to push the club through the swing rather than pulling it through with the lead arm are the likely mechanism behind the increased rate of elbow injuries in amateur golfers<sup>[10]</sup>. In this case, the change in grip and deliberate over-activation of the flexor-pronator muscles likely combined to create the injury.

Diagnosis of a pronator teres tear relies on physical exam and magnetic resonance imaging. Exam reveals swelling and tenderness in the flexor-pronator mass below the medial epicondyle. Pain may be exacerbated by maintaining resisted wrist flexion during passive elbow extension. Since the median nerve passes between the two heads of the pronator teres, swelling may lead to symptoms of a compressive neuropathy. These may include weakness in the thenar muscles and dysesthesias in the median nerve distribution and the "palmar triangle," the distribution of the palmar cutaneous branch. Radiographs typically reveal only medial elbow soft tissue swelling. Presence of a spur on the posteromedial elbow would be indicative of repetitive strain as is commonly seen in baseball pitchers<sup>[1]</sup>. With MR imaging, the axial and coronal images offer the best assessment of the medial elbow and the flexor/pronator musculature<sup>[12]</sup>. Inversion recovery (STIR) or fast spin-echo T2 weighted sequences are fluid sensitive and will show soft tissue edema in the pronator teres muscle belly, with focal fluid intensity indicating a tear<sup>[13]</sup>. Fat suppressed T1 weighted images will show high signal hemorrhage in the region of the tear, with relative brightening of the hematoma as compared to adjacent normal muscle and fatty marrow on T2-weight imaging<sup>[12]</sup>.

Conservative measures are recommended for treatment of pronator teres muscle belly tears. Barnes noted that among baseball players treated operatively for medial elbow injuries, the 2 players with musculotendinous tears who had primary repair were unable to return to asymptomatic throwing despite lengthy post-operative rehabilitation and suggested that muscle injuries should be treated non-operatively<sup>[6]</sup>. They note that elbow soft tissue lesions respond rapidly to non-operative measures. In addition to symptomatic measures such as ice and anti-inflammatories, we consider graduated use and stretching to be important parts of the rehab protocol in order to minimize scarring and fibrosis. We allowed return to play after the patient demonstrated full elbow range of motion in all planes and was able to participate in physical therapy and resisted pronation without

pain.

## CONCLUSION

Isolated rupture of the pronator teres is an unusual injury. To our knowledge, this is the first description of this injury in a golfer in the English literature. Amateur golfers may change their swing more often than professionals and have been shown to activate the trail-arm pronator teres more than professional golfers, potentially leading to an increased risk of injury to the pronator teres. Physical exam and MRI can assist in diagnosis and exclusion of other pathologic processes. Conservative treatment with rest, symptomatic measures, and physical therapy is effective at relieving pain and allowing return to play.

## CONFLICT OF INTEREST

There are no conflicts of interest with regard to the present study.

## REFERENCES

- 1 Slocum, D. Classification of elbow injuries from baseball pitching. *Texas Medicine*. 1968; 64: 48-53.
- 2 Miller DM, Savoie FH. Valgus extension injuries of the elbow in the throwing athlete. *J Am Acad Orthop Surg*. 1994; 2: 261-269.
- 3 Van Hofwegen C, Baker III CL, Baker Jr CL. Epicondylitis in the Athlete's Elbow. *Clin Sports Med*. 2010; 29: 577-597.
- 4 Chen FS, Rokito AS, Jobe FW. Medial elbow problems in the overhead-throwing athlete. *J Am Acad Orthop Surg*. 2001; 9: 99-113.
- 5 Richard MJ, Aldridge JM, Wiesler ER, Ruch DS. Traumatic valgus instability of the elbow: pathoanatomy and results of direct repair. *J Bone Joint Surg Am*. 2008; 90: 2416-2422.
- 6 Barnes DA, Tullos HS. An analysis of 100 symptomatic baseball players. *Am J Sports Med*. 1978; 6: 62-67.
- 7 King JW, Brelsford HJ, Tullos HS. Analysis of the pitching arm of the professional baseball pitcher. *Clin Orthop Relat Res*. 1969; 67: 116-123.
- 8 Nieburski HZ, Richardson ML. High-grade pronator teres tear in a cricket batsman. *Radiology Case Reports*. 2011; 6: 540.
- 9 McHardy A, Pollard H, Luo K. One year follow-up study on golf injuries in Australian amateur golfers. *Am J Sports Med*. 2007; 35: 1354-1360.
- 10 McCarroll JR. The frequency of golf injuries. *Clinics Sports Med*. 1996; 15: 1-7.
- 11 Farber AJ, Smith JS, Kvitne RS, Mohr KJ, Shin SS. Electromyographic analysis of forearm muscles in professional and amateur golfers. *Am J Sports Med*. 2009; 37: 396-401.
- 12 Ho, C. Sports and occupational injuries of the elbow: MR imaging findings. *Am J Roentgenol*. 1995; 164: 1465-1471.
- 13 Frick MA, Murthy NS. Imaging of the elbow: muscle and tendon injuries. *Semin Musculoskelet Radiol*. 2010; 14: 430-437.

**Peer reviewer:** Karthik Karuppaiah, Consultant upper limb surgeon (Locum), Department Trauma and Orthopaedics, King's College Hospital, Denmark Hill, London, United Kingdom.