

Management of Metatarsus Adductus, Bean-Shaped Foot, Residual Clubfoot Adduction and Z-shaped Foot in Children, with Conservative Treatment and Double Column Osteotomy of the First Cuneiform and the Cuboid

Hassan Najdi, Roger Jawish

Hassan Najdi, Department of Orthopaedic Surgery- Sacré Coeur Hospital, Beirut, Lebanon

Roger Jawish, Head Department of Orthopaedic Surgery- Sacré Coeur Hospital, Beirut, Lebanon

Correspondence to: Hassan Najdi, Department of Orthopaedic Surgery- Sacré Coeur Hospital, P.O. Box 116 Hazmieh, Lebanon.

Email: najdihassan@hotmail.com

Telephone: +961-3-852012

Received: July 11, 2015 Revised: September 25, 2015

Accepted: September 30, 2015

Published online: December 23, 2015

ABSTRACT

Metatarsus adductus is a deformity located at Lisfranc's joint in a pure transverse plane. It is spontaneously corrected for the majority of newborns. In rare toddler cases, it demonstrates a clinical stiffness and results in Z-shaped foot, where valgus of the heel creates equilibration of resistant metatarsus adductus. Although, recurrent metatarsus adductus varus is observed in treated idiopathic clubfeet, usually in children over three years, but presence of heel's valgus is related to the surgical overcorrection of the heel's varus. Conservative treatment is advocated in flexible metatarsus adductus. Surgery is performed after conservative treatment fail, and in walking patient. Soft tissue releases, osteotomies of metatarsals and lateral epiphysiodesis of the metatarsal base gave good results on short term, but deformity recurrence and foot growth disturbance couldn't be avoided. Although, osteotomies carried out proximal to the Lisfranc's joint: opening wedge osteotomy of medial cuneiform, calcaneo-cuboid fusion and the anterior resection of calcaneus, gave permanent correction, but they act only on one of the sides of deformity. Therefore, the theory of elongated lateral column associated with a shortened medial column is crucial in dealing with this deformity: combining opening wedge osteotomy of cuneiform with closing wedge osteotomy of cuboid described by Jawish et al. in children after 4 years allows in all causes of metatarsus adductus stiffness a

lateral shifting of forefoot. Concerning the associated heel's valgus, it is corrected in Z-shaped foot after the double osteotomy cuneiform/cuboid. However, in complicated treated clubfoot a particular treatment for the posterior tarsal is necessary.

© 2015 ACT. All rights reserved.

Key words: Metatarsus Adductus Varus; Skewfoot; Z-shaped; Clubfoot; Cuneiform Osteotomy; Cuboid Osteotomy

Najdi H, Jawish R. Management of Metatarsus Adductus, Bean-Shaped Foot, Residual Clubfoot Adduction and Z-shaped Foot in Children, with Conservative Treatment and Double Column Osteotomy of the First Cuneiform and the Cuboid. *International Journal of Orthopaedics* 2015; 2(6): 438-444 Available from: URL: <http://www.ghrnet.org/index.php/IJO/article/view/1453>

Historically, metatarsus adductus, metatarsus varus^[1,2], metatarsus adducto-varus^[3], pes adductus^[4], metatarsus supinatus^[5], forefoot adductus^[6], and hooked forefoot^[7] are names given to medial deviation of the forefoot. In all these synonyms, the deformity is located at Lisfranc's joint in a pure transverse plan, the metatarsals are regularly adducted, and the rearfoot is normally positioned under the ankle joint and the leg (Figure 1). Therefore, the pure transverse plane deformity at Lisfranc's joint without other abnormalities of the foot is called metatarsus adductus^[8]. However, the adduction of the forefoot could be associated to valgus of the hind foot for many reasons, and promote the aspect of skewfoot or Z-shaped foot. Berg^[9] extended the radiographic study of 124 feet with metatarsus adductus and devised the simple metatarsus adductus (51 feet), the complex metatarsus adductus, when the midfoot is laterally translated (42 feet), the simple skewfoot when the hindfoot is valgus (16 feet) and the complex skewfoot when the midfoot is translated laterally and the hindfoot is in valgus (15 feet). Simple metatarsus adductus could be considered as the third deformity in clubfoot, since clubfoot exhibit two other abnormalities with significant varus of the rearfoot and equinus at the ankle.

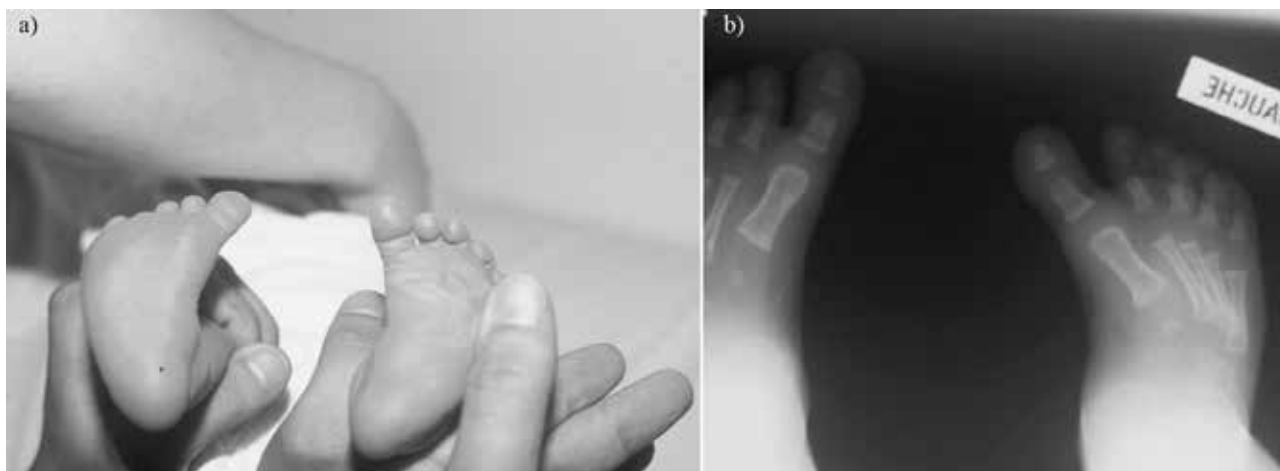


Figure 1: a) Clinical Metatarsus adductus varus (bean-shaped foot) in newborn infant. b) Radiological aspect with adduction at tarsal-metatarsal joints.

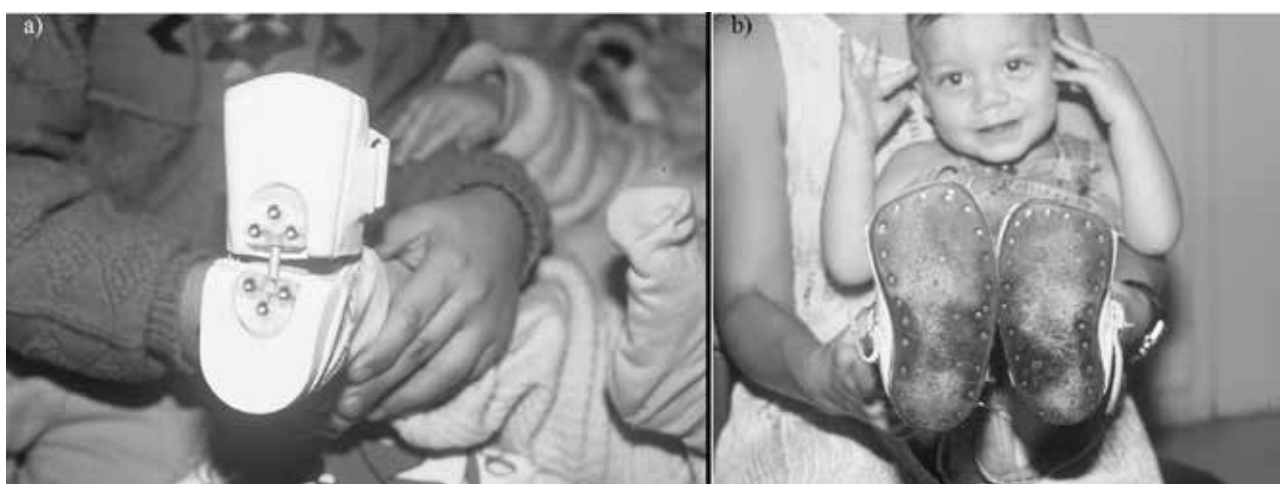

Figure 2: Shoes for resistant metatarsus adductus, shifting the metatarsals Lisfranc joint laterally. a) Before walking age. b) Walking age

The incidence of metatarsus adductus is variable, Cornwall *et al*^[10] reported 8.8% to 15% of the population, but others had suggested much higher levels^[11, 12]. Heredity has been shown to account for only two to four percent of all cases of metatarsus adductus^[2]. Abnormal intrauterine position^[13, 14] is one of the most widely accepted theories of the etiology of metatarsus adductus, this is supported by studies which show a disproportionate number of affected infants in prima gravida mothers^[15]. A slight male preponderance does exist with an approximately 1.3:1 ratio reported by most authors. Many classifications have been reported to define the severity of the deviation (mild, moderate, and severe), the criteria could be clinical with the evaluation of the range of flexibility and correction of the adduction, or radiographically according to the angle of deviation of metatarsals.

The majority of the functional deformity is corrected spontaneously in the short time after birth, it could be help with manipulation of the foot by the parents (Figure 2), but 5% of metatarsus adductus are stiff and remain up to the age of walk. In young children up to the age of 6 or 7 years, the treatment was corrective shoes and cast and soft tissue release. In elder children whose conservative treatment failed or missed, surgery with osseous procedure become necessary. Several surgical techniques were described in the literature, going from different types of metatarsal ostotomies, lateral epiphysiodesis, osteotomies proximal to Lisfranc's joint and external fixator. However, the complications after all these procedures were not rare, they were related to the fixation using screws and pins, and the deformities related to growth disturbance were also significant.

METATARSUS VARUS

The term metatarsus varus (MTV) was popularized by Kite in the 1950s as a term for the same entity as metatarsus adductus, he noted that in the non weight-bearing examination the foot was supinated as well as adducted^[16]. He did state that with weight bearing, there was only a pure transverse plane deformity as a metatarsus adductus. For this reason the term of metatarsus adductus was confused with metatarsus varus and metatarsus adductus varus. Metatarsus varus presents somewhat differently in that the forefoot is inverted in relation to the rearfoot. Adduction at Lisfranc's joint is present and usually is a severe component of this deformity. Contracture of the tibialis anterior may also be present^[17]. Kite mentioned that muscle imbalance was the cause of metatarsus varus with tibialis anterior and tibialis posterior overpowering the weaker peroneal muscles^[2]. This theory was disputed by Reimann and Werner who showed that metatarsus varus could only be reproduced in the normal infant foot by extensive capsulotomy even with extreme tension placed on the tibialis anterior tendon^[18]. They concluded that metatarsus varus was the result of primary subluxation of LisFranc's joint with soft tissue adaptation occurring secondarily.

Other theories of causal relationship which have been proposed include abnormal tendon insertion of tibialis anterior^[4, 19], tibialis posterior^[20], and abductor hallucis muscles^[21]. Osseous malformations include absence of the medial cuneiform^[4]. Combinations of the above factors have also been suggested^[22].

Ponseti and Becker (1966) found that when congenital metatarsus varus occurred as an isolated deformity only 11.6 per cent needed definitive treatment.

SKEWFOOT, Z-SHAPED FOOT

The deformity characterized by forefoot adduction and hindfoot valgus is named Skewfoot (Figure 3). In 1863, Henke^[23] gave the initial description of this deformity, Peabody and Muro^[24] in 1933, reported the first review of the literature and labeled the deformity "congenital metatarsus varus" to differentiate it from the common metatarsus adductus. The term skewfoot proposed in 1949 by McCormick and Blount^[25] was used as a generic term to resume the following deformities, metatarsus varus, metatarsus adductus, metatarsus adductovarus, and metatarsus adductocavovarus. Other investigators have had a share in adding the confusion between the terms metatarsus adductus, serpentine metatarsus adductus, and S-shaped foot.

Jawish *et al*^[26] in 1990 defined the Z-shaped foot as varus of the forefoot and valgus of the heel, a deformity which is advisable to separate from metatarsus varus. They considered metatarsus adductus the initial deformity resistant to usual treatment. However, the rear foot takes in weight-bearing an opposite valgus position. Four grades of deformities were defined according to the severity of the tarsal deformity

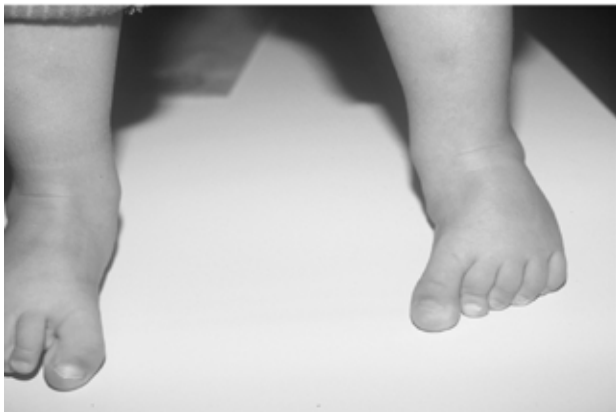

Figure 3 Skewfoot or Z-shaped foot, adduction of the forefoot and valgus of the hind foot, secondary to resistant metatarsus adductus varus.

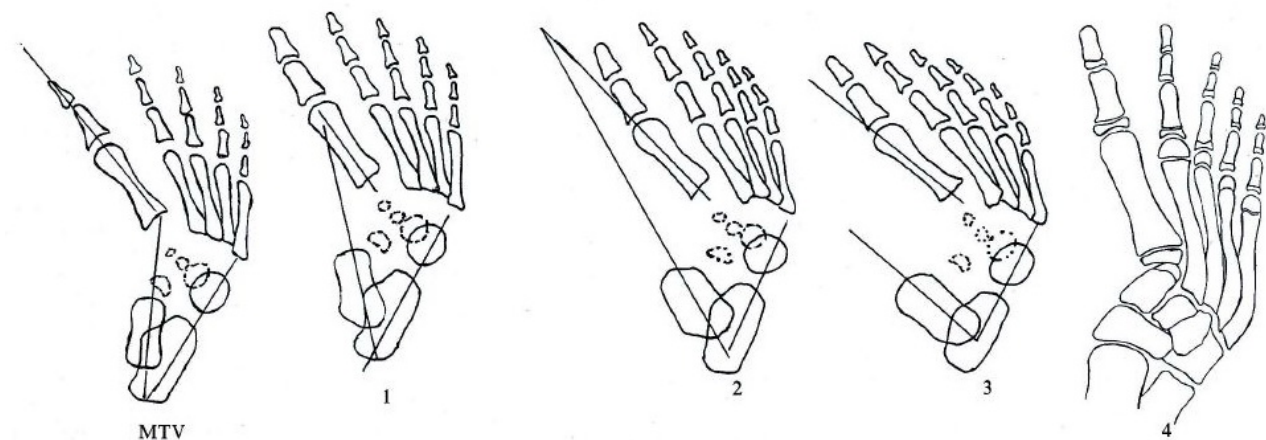


Figure 4: Schematic representation of the foot in charge, MTV: an isolated metatarsus varus where the axis of the talus meets the first metatarsal at its base; the talo - calcaneal divergence is normal. Grade 1, 2, 3 : Z-shaped foot of increasing severity in young age , where the axis of the talus crosses the shaft of first metatarsal (1) , beyond the shaft of first metatarsal (2) or parallel to it (3); the talo - calcaneal divergence is even more exaggerated when the "serpentine" foot is accentuated. Grade 4: a "serpentine" foot in elder child: an abduction of the anterior tarsal, a developmental disorders of the tarsal - metatarsal skeleton, and a normal or exaggerated talo - calcaneal divergence where added to the fixed metatarsus adductus, all giving the foot the appearance of a "Z". Jawish *et al*^[26].

(Figure 4), going from normal talo calcaneal angle to severe valgus of the heel, more the adduction is stiff more the valgus is important and the Z-shaped pronounced. When describing a foot deformity that matches the criteria for forefoot adduction and hindfoot valgus, Lynn T. Staheli (1993)^[27] recommended using terms such as skewfoot, serpentine foot, or Z-shaped foot that clearly discriminate this deformity from metatarsus adductus. The treatment of this deformity has known many procedures, all focused on the anterior metatarsal deformity and posterior valgus deviation. The different results demonstrated that osteotomy of the metatarsals has created growth disturbance and the intervention on the posterior foot was useless, creating instability of the tarsal bone, because the valgus is functional and related to the stiffness of the fore foot adduction. Jawish *et al*^[26] have recommended in 1990 the correction of the resistant fore foot adduction carrying out an opening wedge osteotomy of the first cuneiform and closing wedge osteotomy of the cuboid. Therefore, the simple bean-shaped foot, which is isolated metatarsus adductus, or complicated with Z-shaped foot, are thoroughly corrected with the double cuneiforme/cuboid osteotomy.

RESIDUAL FOREFOOT ADDUCTUS IN CLUB FEET

Recurrent adductus of the forefoot is commonly seen in treated idiopathic club feet (Figure 5A), usually in children over three years of age^[28]. Tarraf and Carroll^[29] in an analysis of residual deformity in a series of 159 club feet found adduction in 81.1% at the first revision and in 47.5% at the second revision. Undercorrection at the time of the initial surgery and medial displacement of the anterior part of the calcaneus and the navicular around the talus were considered to be etiological factors. Muscular imbalances between the abductors and adductors of the foot and abnormal attachments of the tendon of tibialis anterior have been found in these feet^[2]. Although, in all our operative observations in hallux valgus and metatarsus adductus, the tibialis anterior was clearly inserted on the plantar aspect of the first metatarsal but not on the first cuneiform. Capsulotomies of the tarsometatarsal joints have been advocated after failed conservative treatment but an incidence of degenerative joint disease of 68% has been reported^[30]. Soft-tissue revision surgery is more difficult because of scarring from previous operations and does not take into account deformation of the tarsal bones which occurs with time^[2]. The valgus of the heel, when it exists, is related to the overcorrection

of varus after surgery for clubfoot. Therefore, we have to distinguish the Z-Shaped foot complicating a surgery for clubfoot from that equilibrating resistant metatarsus adductus. The first aspect advocates correction at the forefoot and hindfoot, the latter necessitates correction on the forefoot only.

SURGICAL REVIEW

Metatarsus adductus deformity can be effectively treated conservatively when recognized early in development, preferably from birth to the time the child takes his or her first steps^[25]. Unfortunately, the treatment of resistant metatarsus adductus is often delayed because it is not evaluated seriously until the child is walking and coordination and shoe-fitting problems occur. Also, there is a misguided notion by many physicians that metatarsus adductus will be "outgrown." As the child grows and the deformity persists, conservative measures fail because osseous adaptation has already occurred.

According to the relation between forefoot and hindfoot in resistant metatarsus varus, Z-shaped foot, the metatarsal heads is supinated in relation to the hindfoot, during foot stance this position increase the pronation of subtalar and mid-tarsal joints, in order to allow the medial metatarsals to contact the floor^[31]. This may cause a drop of most of the structures of the foot towards its medial side, increasing the talo-calcaneal angle. Instead of a rigid lever, the forefoot may become a mobile structure during push-off, producing larger compressive and shear forces transmitted to the surrounding soft tissues^[32, 33-35]. All these changes may have negative effects on the rest of the foot, the more proximal joints of the lower limb and the spine, which will all have to adapt to these modifications. Thus, problems at the foot, ankle, knee, pelvis and the spine, have been reported in resistant metatarsus adductus^[34, 36, 37]. Common problems derived from this deformity may include pain, swelling, tiredness as well as problems of balance and coordination^[38].

The indications for surgery are the same as they would be for traditional metatarsus adductus correction, failure to respond to conservative therapy with residual pain and difficulty wearing shoes comfortably. Also, residual deformity of the forefoot after treatment of the rearfoot component of talipes equinovarus, pes planus, skewfoot, cavaoadductus, or residual adductus post subtalar arthrodesis. Contraindications include infection, extremely small cuneiforms, and an architectural configuration of the midfoot preventing the geometry of the step-down osteotomies

Many different surgical procedures have been described for the treatment of metatarsus adductus. Thompson *et al*^[39]. excised the abductor hallucis muscle, relieving the medial soft tissue contracture. Lichtblau^[21] found that a transverse sectioning of the abductor hallucis tendon near its insertion was effective early on in those cases in which a tight abductor hallucis is found. Heyman *et al*^[40]. and Kendrick *et al*^[41]. described a transection of the dorsal, plantar and interosseous ligaments and joint capsules of Lisfranc's joint to mobilize the soft tissues, allowing manual correction of the forefoot deformity.

Although the previously described soft tissue releases can be helpful procedures early on in the recognition of metatarsus adductus deformities, osseous procedures become necessary in resistant cases and those that go untreated into adolescence. Jawish *et al*^[26]. in "The Z-shaped or serpentine foot in children and adolescents" insisted on early radiographic diagnosis and treatment which is orthopaedic before first year of age, then surgical when first failed or missed. Peabody and Muro^[24] described an osseous procedure

in which an abductory osteotomy was performed on the fifth metatarsal base with an excision of the central three metatarsal bases and a medial mobilization with reduction of the first metatarsal cuneiform articulation. Steyler and Van der Walt^[42] described a V-shaped metatarsal osteotomy of metatarsals 1 through 5 in which the "V" was made obliquely with the apex toward the hindfoot. By making the medial arm almost vertical and the lateral arm more horizontal, they felt they could translate the osteotomy with more stability because no fixation was used. A lateral epiphysiodesis of the metatarsal base was proposed by Ellis^[43]. Berman and Gartland^[44] described a crescentic metatarsal osteotomy of metatarsals 1 through 5 with lateral translation and fixation of metatarsals 1 and 5 only, with risk of impact on the metatarsal's bone growth. These different osteotomies give a good result in short term, but they cannot avoid the recurrence of the deformity, since the varus deviation of the tarso-metatarsal joint was not corrected.

Surgical procedures for metatarsus adductus proximal to Lisfranc's joint have rarely been described. Fowler *et al*^[45]. described an opening wedge osteotomy of the medial cuneiform with the insertion of bone graft into the medial wedge. In 1958, Johanning^[46] described wedge resection and enucleation of the cuboid to shorten the lateral column, followed by manipulation and casting as treatment of resistant clubfoot. In 1961, Evans^[47] posed that an elongated lateral column associated with a shortened medial column is crucial in dealing with forefoot adduction, but he proposed a calcaneo-cuboid fusion for re-establishing the balance between the two columns. In 1973, Lichtblau^[48] suggested a resection of the anterior end of the calcaneus. However, this acts on only one of the sides of the deformity, as happens with procedures that lengthen the medial column, such as the one described by Hoffman *et al*^[40] in 1984, but the medial column lengthening does not easily address the supination deformity, and has an additional problem because it requires harvesting a bone graft from another site. Napiontek *et al*^[49]. in their series on opening wedge osteotomy of the medial cuneiform in the treatment of forefoot adduction reported 14 % overcorrection (forefoot abduction), and in one-quarter of the operated feet, the ceramic porous graft had to be removed.

In 1990, Jawish R *et al*^[26, 50] mentioned the principle of combining the opening wedge osteotomy of cuneiform with the closing wedge osteotomy of cuboid, and what is removed from the cuboid is filled in the opening wedge of first cuneiform (Figure 5B). The study was addressed to the correction of the Z-shaped foot in resistant metatarsus adductus, after failure of the conservative treatment in children over 4 years old. Therefore, the forefoot is completely shifted laterally avoiding recurrence. Similarly, McHale and Lenhart^[51] in 1991 talked about combination of a shortening osteotomy of the cuboid and lengthening osteotomy of the cuneiform. A semicircular tarsal osteotomy has been described by Gupta and Kumar^[52] in 1993, they didn't address to the imbalance between the long lateral and short medial columns characteristic of the deformed foot. In 1994, Jawish^[53], in a next study, reported the application of the double osteotomy of cuneiform/cuboid in a series of children with multiple causes of forefoot deformities, resistant metatarsus adductus, Z-shaped foot, and resistant clubfoot (Figure 6). Many Authors, Schaefer *et al*^[54], Lourenco AF^[55], Pohl M *et al*^[56] and Gordon *et al*^[57] have published about the results of this technique and advocated that surgery should be reserved for children over 4 years of age, when the medial cuneiform ossification nucleus is well developed. In 2009, for children younger than 5 years old, Mahadev *et al*^[58] described a corrective procedure for treatment of the residual forefoot adduction combining a closing wedge cuboidal osteotomy and trans-midfoot

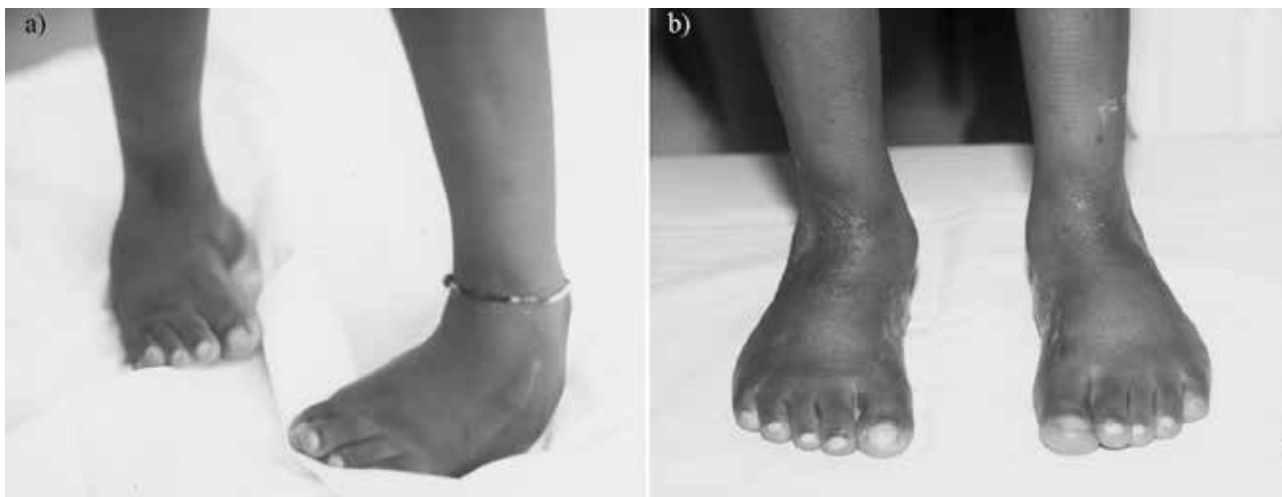

Figure 5 (A) Residual forefoot adductus in clubfoot after failed surgery; (B) Clinical result after opening wedge osteotomy of the first cuneiform and closing wedge osteotomy of the cuboid

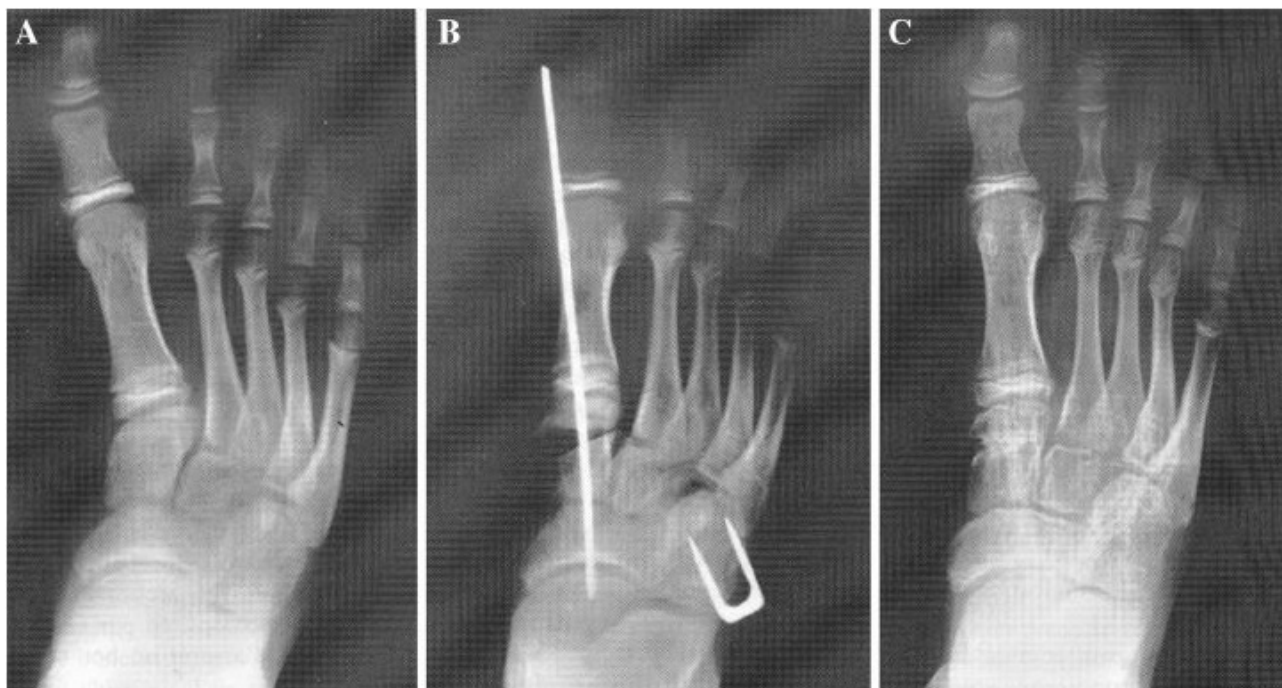


Figure 6: (Boy DEL...Ste'phane) (a): At 12 years old, the patient had a Z-shaped foot grade 4 with no initial treatment. He has metatarsus adductus and lateral deviation of the anterior tarse, with deformities of the first cuneiform and the cuboid. (b): we performed a closing wedge osteotomy of the cuboid and opening wedge osteotomy of the first cuneiform allowing good alignment of the first ray. The pins are removed after 2 months, the cast after 3 months (c). After one-year follow-up, the clinical correction and radiological aspect remained excellent. This procedure is recommended for the treatment of the Z-shaped foot after the age of 4–6 years. Jawish et al^[26].

rotation procedure without a medial opening wedge osteotomy. They believed the medial cuneiform osteotomy should be performed once the ossific nucleus has become well defined. However, as mentioned above, a significant difference should be considered between the causes of valgus of the heel. The valgus deformity could be corrected spontaneously after de double osteotomy of the medial and lateral column, but in other cases it requests a particular treatment. The first condition corresponds to resistant metatarsus adductus with Z-shaped foot. The second is observed in complicated clubfoot, when a posterior subtalar imbalance is created after operative correction of the varus of the heel. In this condition the repositioning of the rearfoot needs particular correction.

The Ilizarov technique is very interesting, it has been recommended

for difficult club foot. Grill and Fanke^[59] advocated this method in 1987 for neglected club feet, but the only arthrogryptic foot in their series had a complete relapse of the deformity. Brunner, Hefti and Tgetgel^[60] treated 16 arthrogryptic feet with a circular frame, between them 11 had a severe adductus deformity. In six patients, who had an osteotomy of the first metatarsal, correction was maintained, whereas in five without an osteotomy a significant loss of correction was observed. This suggests that the combination of an osteotomy with continuous soft-tissue distraction may be necessary to maintain the correction. The Ilizarov technique seems to give the best results in severe deformities, but the treatment is complex and request particular experience, she also involves fixation of the lower leg for several months^[61].

CONCLUSION

Isolated metatarsus adductus, Z shaped foot, simple residual clubfoot and complicated residual clubfoot have forefoot adduction in common, but they are differentiated by the hindfoot positioning. If no hindfoot deformity was present as in case of isolated metatarsus adductus and simple residual clubfoot, the main deformity is located at Lisfranc's joint. On the other hand, In case of hindfoot deformity, it is either functional hindfoot valgus as in Z shaped foot or constitutional hindfoot valgus as in complicated residual clubfoot.

The theory of elongated lateral column associated with a shortened medial column is crucial in dealing with all these types. Combining opening wedge osteotomy of cuneiform with closing wedge osteotomy of cuboid in children after 4 years of age allows, in all causes of metatarsus adductus stiffness, a correction of forefoot adduction without any growth disturbance.

However, concerning the associated hindfoot valgus, after the double osteotomy cuneiform/cuboid, it is thoroughly corrected in Z-shaped foot where the hindfoot valgus is considered as a transient deformity and due to the stiffness of metatarsal adductus when the foot is in weight bearing. But in complicated residual clubfoot, where the hindfoot valgus resulted from overcorrection in previous surgeries, a particular treatment for the posterior tarsal is necessary because valgus is considered a constitutional deformity and related to imbalance at the rearfoot.

CONFLICT OF INTEREST

The authors declare that they have no conflict of interest.

REFERENCES

- Cramer, K. Metatarsus varus congenitus. *Archiv fur Orthopadie, Mechanotherapie und Unfallchirurgie* 1921; 2:5370-5374.
- Kite, JH. Congenital metatarsus varus. / *J Bone Joint Surg [Am]* 1967; 49-A: 388-97.
- Lloyd-Roberts C, Clark C. Ball and socket ankle joint in metatarsus adductus varus. *J Bone Joint Surg* 1973; 55B:193-196
- Bankart AS. Metatarsus varus. *Br I Med J* 1921; 2: 685-687.
- Rothbart, BA. Metatarsus adductus and its clinical significance. *J Am Podiatry Assoc* 1972; 62:187-191.
- Mittleman C. Transverse plane abnormalities of the lower extremities: intoe and outtoe gait. *J Am Podiatry Assoc* 1971; 61:1-5.
- Rushforth C. The natural history of hooked forefoot. *J Bone Joint Surg* 1978; 608:530-532.
- Bradley D, Castellano, D.P.M. Thomas F. Smith, D.P.M: METATARSUS ADDUCTUS.214-218
- Berg E E. A reappraisal of metatarsus adductus and skewfoot. *J.Bone Joint Surg.* 1986; 68A:1185-1196.
- Cornwall MW, McPoil TG, Fisco WD, Hunt L, Lane C, ODonnell D. The relationship between forefoot alignment and rearfoot motion during walking. *Australas J Podiatric Med* 2004; 38(2):35-40.
- Michaud TC. The forefoot varus deformity 9 or 90 percent prevalence? *Biomechanics* 1997; IV: 5.
- Garbalosa JC, McClure MH, Catlin PA, Wooden M. The frontal plane relationship of the forefoot to the rearfoot in an asymptomatic population. *J Orthop Sports Phys Ther* 1994; 20(4):200-6.
- Wynne-Davies R. Family studies and the cause of congenital clubfoot, talipes equinovarus, talipes calcaneovalgus, and metatarsus varus. / *Bone Joint Surg,* 1964; 468:M5.
- Chapple C, Davidson D. A study of the relationship between fetal position and certain congenital deformities. *J Pediatr* 1941;181:483-493.
- Berg E. A reappraisal of metatarsus adductus and skewfoot. *J Bone Joint Surg* 1986; 68A:1185-1196.
- Kite JH. Congenital metatarsus varus. A report of 300 cases. *J. Bone Joint Surg* 1950; 32A:500-506.
- Ghali NN, Abberton M, Silk F: The management of metatarsus adductus et supinatus. *J Bone Joint Surg*1984; 668:376-380.
- Reimann I, Werner HH. Congenital metatarsus varus. *Clin Orthop* 1975;110:223-226.
- Peabody C, Muro F. Congenital Metatarsus Varus. *J Bone Joint Surg* 1933; 15:171-189.
- Browne RS, Paton DF. Anomalous insertion of the tibialis posterior tendon in congenital metatarsus varus. *J Bone Joint Surg* 1979; 618:7476.
- Lichtblau S. Section of the abductor hallucis tendon for correction of metatarsus varus deformity. *Clin Orthop* 1975; 110:227 -232.
- Yu C, Wallace C, In McGlamry ED (ed). *Comprehensive Textbook of Foot Surgery* 1987; vol 1. Baltimore, Williams & Wilkins, p 334.
- Sebastien Hagmann, Thomas Dreher, Wolfram Wenz. skewfoot, *Foot Ankle Clin N Am* 2009; 14, 409-434.
- Peabody CW, Muro F. Congenital metatarsus varus. *J. Bone Joint Surg.* 1933; 15:171-189.
- Mccormick DW, Blount WP. Metatarsus adductovarus: skewfoot. *J Am Med Assoc.* 1949; Oct 15; 141(7):449-53.
- Jawish R, Rigault P, Padovani JP, Klizowski PH, Finidori G, Touzet P, Chaumien JP. The Z-shaped or serpentine foot in children and adolescents. *Chir Pediatr* 1990; 31(6):314-21. French.
- Lynn T. Stahli. Rotational Problems in Children *J Bone Joint Surg Am,* 1993; Jun, 75 (6): 939 -949.
- Kling TF Surgical complications: adduction/ supination. In: Simons GW, ed. *The clubfoot: the present and a view of the future* 1993. New York, Springer Verlag: 404-12.
- Tarraf YN, Carroll NC. Analysis of the components of residual deformity in clubfeet presenting for reoperation. *J Pediatr Orthop* 1992, 12:207-16.
- Stark JG, Johanson JE, Winter RB. The Heyman-Herndon tarsometatarsal capsulotomy for metatarsus adductus: results in 48 feet. *J Pediatr Orthop* 1987; 7:305-10.
- Root ML. Normal and abnormal function of the foot: clinical biomechanics. 1977; Los Angeles: Clinical Biomechanics Corp.
- Lawley MG. The pathomechanics of forefoot varus. *Chiropracist* November 1983; 416-21.
- Jones LJ, Todd WF. Abnormal biomechanics of flatfoot deformities and related theories of biomechanical development. *Clin Podiatr Med Surg* 1989; 6(3): 511-21.
- Tiberio D. Pathomechanics of structural foot deformities. *Phys Ther* 1988; 68 (12):1840-9.
- Donatelli RA. Abnormal biomechanics of the foot and ankle. *J Orthop Sports Phys Ther* 1987; 9:11-6.
- Cobb SC, Tis LL, Johnson BF, Higbie EJ. The effect of forefoot varus on postural stability. *J Orthop Sports Phys Ther* 2004; 34(2):79-85.
- Bird AR, Payne CB. Foot function and low back pain. *Foot* 1999; 9:175-80.
- Alonso-Vázquez A, Villarroya MA, Franco MA, Asín J, Calvo B. Kinematic assessment of paediatric forefoot varus, *Gait & Posture* 2009; 29, 214-219.
- Thompson GH, Richardson AB, Westin GW. Surgical management of resistant congenital talipes equino varus deformities. *J. Bone Joint Surg* 1982; 64A:652-665.
- Heyman Ch, Herndon Ch, Strong Jm. Mobilization of the tarsometatarsal and intermetatarsal joints for the correction of resistant adductus of the fore part of the foot in congenital metatarsus varus. *J. Bone Joint Surg* 1958; 40A:299-309.
- Kendrick RE, Sharma NK, Hassler WL, Herndon CH. Tarsometatarsal mobilization for resistant adduction of the fore part of the foot. *J. Bone Joint Surg*1970; 52A:61-70.
- Steytler JC. S., Van Der Walt, ID. Correction of resistant adduc-

- tion of the forefoot in congenital clubfoot and congenital metatarsus varus by metatarsal osteotomy. *Br. J. Surg.* 1966; 53:558-560.
- 43 ELLIS VH. A method of correction for metatarsus Varus Primus. *J Bone Joint Surg (Br)* 1951; 33, 415-417.
- 44 Berman A, Gartland JJ. Metatarsal osteotomy for the correction of adduction of the fore part of the foot in children. *J. Bone Joint Surg.* 53A:498-506.
- 45 Fowler. The cavovarus foot. *J. Bone Joint Surg.* 1959; 41A:757.
- 46 Johanning K. Excochleatio ossis cuboidei in the treatment of pos equino-varus. *Acta Orthop Scand.* 1958; 27:310-319
- 47 Evans D. Relapsed clubfoot. *J Bone Joint Surg B* 1961; 43: 722.
- 48 Lichtblau S. A medial and lateral release operation for clubfoot. *J Bone Jt Surg Am* 1973; 55:1377-1384.
- 49 Napiontek M, Kotwicki T, Tomaszewski M Opening wedge osteotomy of the medial cuneiform before age 4 years in the treatment of forefoot adduction. *J Pediatr Orthop* 2003; 23(1):65-69.
- 50 Jawish R. letter to editor: Combined double tarsal wedge osteotomy and transcuneiform osteotomy for correction of resistant club foot deformity (the bean-shaped foot). *J Child Orthop* 2015; 9:169-170.
- 51 McHale KA, Lenhart M. Treatment of residual clubfoot deformity—the ‘bean-shaped’ foot—by opening wedge medial cuneiform osteotomy and closing wedge cuboid osteotomy: clinical review and cadaver correlations. *J Pediatr Orthop* 1991; 11: 374-81.
- 52 Gupta AK, Kumar R. Treatment of residual club-foot deformity—the bean-shaped foot—by open wedge medial cuneiform osteotomy and closing wedge cuboid osteotomy, clinical review and cadaver correlations. *J Pediatr Orthop* 1993; 13:408-410.
- 53 JAWISH R. Ostéotomie d’ouverture du premier cunéiforme dans le traitement du varus tarso-métatarsien chez l’enfant. *Rev. Chir. Orthop.* 1994; 80:131-134.
- 54 Dirk Schaefer, Fritz Hefti. Combined cuboid/cuneiform osteotomy for correction of residual adductus deformity in idiopathic and secondary club feet *J Bone Joint Surg [Br]* 2000; 82-B: 881-4.
- 55 Lourenco AF, Dias LS, Zoellick DM, Sodre H. Treatment of residual adduction deformity in clubfoot: the double osteotomy. *J Pediatr Orthop* 2001; 21: 713-8.
- 56 Pohl M, Nicol RO. Transcuneiform and opening wedge medial cuneiform osteotomy with closing wedge cuboid osteotomy in relapsed clubfoot. *J Pediatr Orthop* 2003; 23: 70-3.
- 57 Gordon JE, Luhmann SJ, Dobbs MB, Szymanski DA, Rich MM, Anderson DJ, Schoenecker PL. Combined midfoot osteotomy for severe forefoot adductus. *J Pediatr Orthop* 2003; 23:74-78.
- 58 Mahadev A, Munajat I, Mansor A, Hui JH. Combined lateral and transcuneiform without medial osteotomy for residual clubfoot for children. *Clin Orthop Relat Res* 2009; 467:1319-1325.
- 59 Grill F, Fanke J. The Ilizarov distractor for the correction of relapsed or neglected clubfoot. *J Bone Joint Surg [Br]* 1987; 69-B: 593-7.
- 60 Brunner R, Hefti F, Tgetgel JD. Arthrogryptic joint contracture at the knee and the foot: correction with a circular frame. *J Pediatr Orthop B* 1997; 6:192-7.
- 61 Grant AD, Atar D, Lehman WB. The Ilizarov technique in correction of complex foot deformities. *Clin Orthop* 1992; 280: 94-103.

Peer reviewers: Manuel Bondi, Department of Orthopaedic and Traumatology, Carlo Poma Hospital, Mantova, Italy; Edvin Selmani, Department of Orthopaedic, University Hospital Center Mother Theresa, Tirana, Albania.