

CASE REPORT

Intramuscular Hemangioma of the Subscapularis Muscle Presenting with Isolated Loss of External Rotation of the Shoulder

Heng-Tai Lin, Chih-Kai Hong, I-Ming Jou, Hung-Wen Tsai, Wei-Ren Su

Heng-Tai Lin, I-Ming Jou, Wei-Ren Su, Department of Orthopaedic Surgery, National Cheng Kung University Hospital, College of Medicine, National Cheng Kung University, Tainan, Taiwan

Chih-Kai Hong, Department of Medicine, National Cheng Kung University College of Medicine, Tainan, Taiwan

I-Ming Jou, Wei-Ren Su, Medical Device Innovation Center, National Cheng Kung University, Tainan, Taiwan

Hung-Wen Tsai, Department of Pathology, National Cheng Kung University Hospital, College of Medicine, National Cheng Kung University, Tainan, Taiwan

Correspondence to: Wei-Ren Su, M.D., MSc, Department of Orthopaedic Surgery, National Cheng Kung University Hospital, No.138, Sheng-Li Road, Tainan City, Taiwan 70428.

Email: suwr@ms28.hinet.net

Telephone: + 886-6-2766689 Fax: + 886-6-2766189

Received: July 11, 2015 Revised: September 25, 2015

Accepted: September 30, 2015

Published online: February 26, 2015

Lin HT, Hong CK, Jou IM, Tsai HW, Su WR. Intramuscular Hemangioma of the Subscapularis Muscle Presenting with Isolated Loss of External Rotation of the Shoulder. *International Journal of Orthopaedics* 2016; 3(1): 512-514 Available from: URL: <http://www.ghrnet.org/index.php/IJO/article/view/1488>

INTRODUCTION

Hemangiomas are common benign soft tissue tumors; however, intramuscular hemangiomas are uncommon, constituting only about 0.8% of all hemangiomas, with approximately half of all cases localized in the lower extremities, particularly the thigh^[1-3]. Intramuscular hemangioma located in the rotator cuff muscles is extremely rare. To our knowledge only few cases have been published^[2, 4]. Isolated loss of external rotation of the shoulder with the arm resting at the side is a rare clinical finding in patients presenting with a shoulder problem. Most patients with shoulder stiffness are usually manifested with a loss of motion involving forward elevation or abduction that often results from primary or secondary adhesive capsulitis^[5]. In response, we report the case of a hemangioma that arose from the subscapularis muscle and presenting with isolated loss of external rotation of the shoulder.

CASE REPORT

A 21-year-old male suffered from right shoulder pain, resting soreness, and limited external rotation for more than ten years. The symptoms progressed in the recent two years. Physical examination showed that the degree of the active and passive external rotation was less than five in the right shoulder with the arms resting at his sides, but all other ranges of motion were full (Figure 1A). The special test revealed a positive lift-off test, the initial tentative diagnosis of which was contracture of the anterior capsule of the glenohumeral joint. A lesion revealed via magnetic resonance image (MRI) was diagnosed as a hemangioma in the subscapularis muscle of the right

ABSTRACT

Intramuscular hemangioma located in the rotator cuff muscles is extremely rare and only few cases have been published. Isolated loss of external rotation of the shoulder with the arm resting at the side is a rare clinical finding in patients presenting with a shoulder problem. In response, we report a case of intramuscular hemangioma of the subscapularis muscle in a 21-year-old male, presented with right shoulder pain and isolated loss of external rotation of the shoulder, and treated with surgical excision.

© 2016 ACT. All rights reserved.

Key words: Intramuscular Hemangioma; Rotator Cuff Muscle; Subscapularis Muscle; External Rotation Limitation; Benign Soft Tissue Tumors

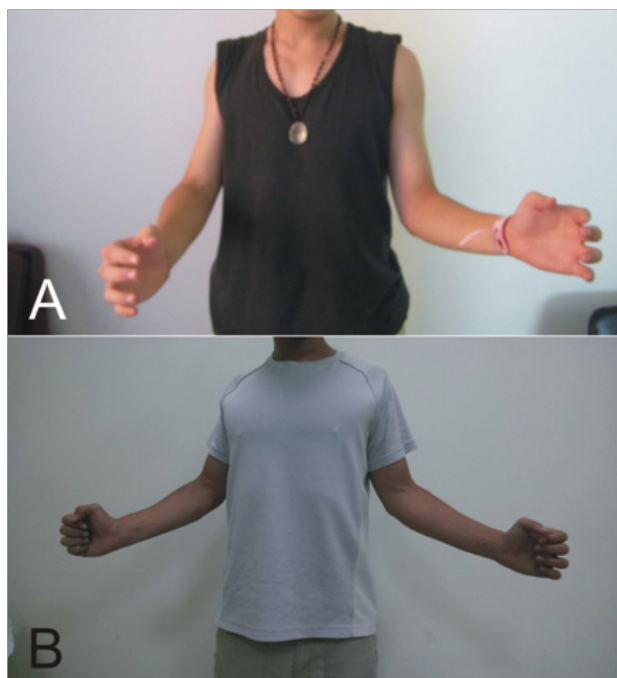

Figure 1 A. Clinical examination of the right shoulder showed evident external rotation limitation. B. Improved external rotation of the shoulder 6 months after surgical excision.

shoulder (Figure 2). There was no evidence of a rotator cuff tear, osteochondral lesion, or labral lesion.

Consequently, tumor excision was indicated. A 5-cm skin incision was made starting at the tip of the coracoid process and extending inferiorly. To access the entire subscapularis muscle, osteotomy of the right coracoid process was conducted. At this point, an anterior shoulder capsule contracture with fibrotic band was noted. The subscapular intramuscular hemangioma was then identified and widely excised. Reattachment of the coracoid process was then performed. The pathologic report confirmed the clinical diagnosis of intramuscular cavernous hemangioma (Figure 3). A clinical examination 6 months after the surgery showed improved external rotation of the glenohumeral joint and absence of soreness over the range of motion (Figure 1B). After 1 year follow-up, there were no clinical or radiological signs of recurrence.

DISCUSSION

Most intramuscular hemangiomas are usually seen before the age of 30 and typically present with a palpable mass that can be either asymptomatic or can present with symptoms including pain, swelling and impaired extremity function, such as decreased range of motion^[1,6-8]. Though infrequent, pulsation, bruit and thrill found in physical examinations help the diagnosis^[2,9]. Diagnoses are mainly based on MRI and confirmed by the histological examination of the excised tumor. The choice of treatment includes surgical excision or sclerotherapy^[6].

Intramuscular hemangioma arising from the rotator cuff muscles is extremely rare, with only a few case reports having been published^[2,4]. La Sorte *et al.* reported a 26-year-old female who had hemangioma that involved portions of the supraspinatus and infraspinatus muscles^[2]. The initial complaints of the patient were pain and the discovery of a mass. Bendeck *et al.* reported a 9-year-old girl who had hemangioma, involving the infraspinatus and subscapularis. An 8-cm round, soft and non-tender mass over the left scapula was found^[4].

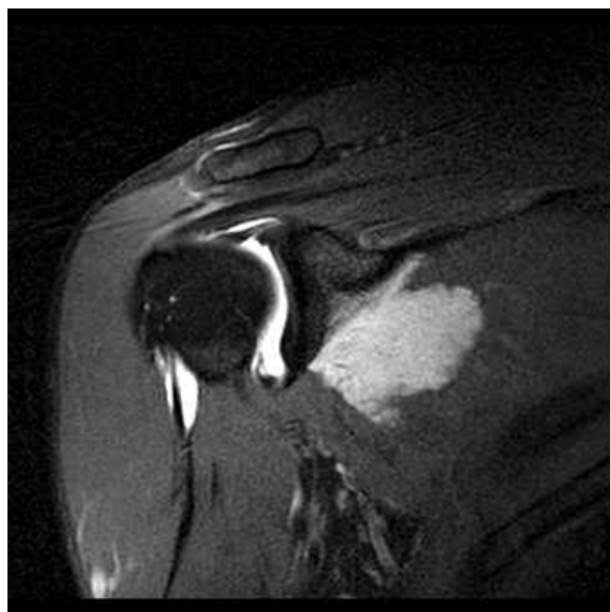


Figure 2 The MRI study showed soft tissue lesions in the subscapularis muscle. The lesions were of prominently high signal in the long TR images with fat suppression.

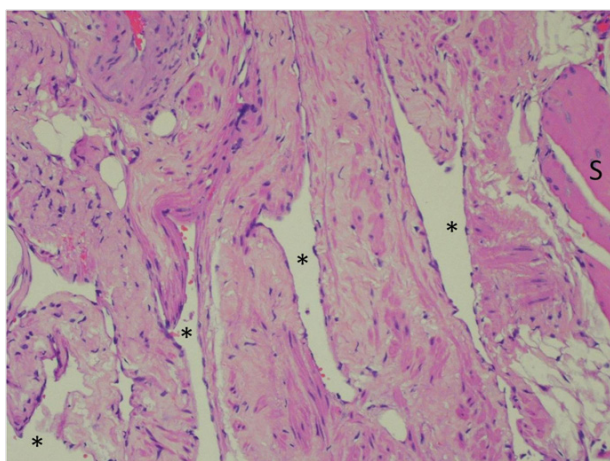


Figure 3 Pathological examination demonstrated that the cavernous hemangioma composed of dilated vascular spaces (*) were lined by flattened endothelial cells. S, subscapularis muscle bundles.

A palpable mass could be found in almost all the patients^[2,9,10]. For example, the above-mentioned hemangioma case involving infraspinatus and subscapularis muscles had a palpable lesion found on the left side of the interscapular region^[4]. However, our patient did not have any mass-like presentation. The lesion in our patient was limited to a single muscle, the deep subscapularis muscle layer, and so palpability was difficult despite a tumor having developed.

Isolated loss of external rotation of the shoulder is rare in patients with shoulder problems^[11]. In our patient, articular capsule contracture with a fibrotic band underlying the subscapularis was found, which was deemed the cause of the limited external rotation. Some studies have reported that fibrosis tissues could be found around the intramuscular hemangioma in image studies and during surgical interventions^[10,12-14], though no studies have confirmed the formation mechanism of the fibrosis tissues so far. Sikka *et al.*^[11] found similar findings in two patients with desmoid tumors in subscapularis muscles. They suggested that although it is rare, a tumor involving the subscapularis should always be considered if a patient has isolated loss of external rotation of the shoulder.

CONCLUSION

Despite its rarity, a tumor involving the subscapularis should be considered for any young patients presenting with an isolated loss of external rotation of the glenohumeral joint. A high index of suspicion based on clinical examination and MRI study may contribute to earlier diagnosis of these tumors.

CONFLICT OF INTERESTS

There are no conflicts of interest with regard to the present study.

REFERENCES

1. Brown RA, Crichton K, Malouf GM. Intramuscular haemangioma of the thigh in a basketball player. *Br J Sports Med* 2004;38:346-348.
2. La Sorte AF. Cavernous hemangioma of striated muscle. Review of the literature and report of one case. *Am J Surg* 1960;100:593-596.
3. Rushin JM, Flick MW. Pathologic quiz case 1. Intramuscular hemangioma, small vessel type, masseter muscle (also known as infiltrating angioliipoma). *Arch Otolaryngol Head Neck Surg* 1989;115:878-881.
4. Bendeck TE, Lichtenberg F. Cavernous hemangioma of striated muscle: review of the literature and report of two cases. *Ann Surg*. 1957;146:1011-1015.
5. Chen CY, Hu CC, Weng PW, Huang YM, Chiang CJ, Chen CH, Tsuang YH, Yang RS, Sun JS, Cheng CK. Extracorporeal shock-wave therapy improves short-term functional outcomes of shoulder adhesive capsulitis. *J Shoulder Elbow Surg* 2014;23:1843-1851.
6. Mitsionis GI, Pakos EE, Kosta P, Batistatou A, Beris A. Intramuscular hemangioma of the foot: A case report and review of the literature. *Foot Ankle Surg* 2010;16:e27-29.
7. Palumbo B, Henderson E, Marulanda G, Cheong D, Letson G. Intramuscular hemangioma causing periosteal reaction and cortical hypertrophy: A frequently missed radiological diagnosis. *The Internet Journal of Orthopedic Surgery* 2008;11.
8. Wani IH, Bhat MS, Basit S, Khursheed O, Jan M, Kawoosa AA. Intramuscular haemangioma of vastus lateralis presenting as stiffness of knee in an adolescent patient. *OA Orthopaedics* 2014;2.
9. Desai SC, Gopal M, Narayan A. A rare intramuscular hemangioma - case report. *Indian J Surg* 2008;70:250-251.
10. Choi WH, Lee CJ, Oh SH, Chung BS, Rhim JK, Kwon KW. Cavernous Hemangioma Occurred Between the Trapezius and Splenius Capitis Muscle. *Korean Journal of Spine* 2012;9:118-121.
11. Sikka RS, Vora M, Edwards B, Szabo I, Walch G. Desmoid tumor of the subscapularis presenting as isolated loss of external rotation of the shoulder. *Journal of Bone and Joint Surgery-American Volume* 2004;86A:159-164.
12. Conley JJ, Clairmont AA. Intramuscular hemangioma of the masseter muscle. *Plast Reconstr Surg* 1977;60:121-124.
13. Kanaya H, Saito Y, Gama N, Konno W, Hirabayashi H, Haruna S. Intramuscular hemangioma of masseter muscle with prominent formation of phleboliths: a case report. *Auris Nasus Larynx* 2008;35:587-591.
14. Wolf GT, Daniel F, Krause CJ, Kaufman RS. Intramuscular hemangioma of the head and neck. *Laryngoscope* 1985;95:210-213.

Peer reviewer: Adrianus Cornelis den Hertog, Orthopedic surgeon, Orthopedic Department, Paracelsusklink Bremen, In der Vahr 65, D- 28329 Bremen Germany.