

An Overall Look for Temporomandibular Joint Pathologies and Imaging

Hakan Eren, Mehmet Eray Kolsuz, Kaan Orhan

Hakan Eren, Mehmet Eray Kolsuz, Kaan Orhan, Department of Dentomaxillofacial Radiology, Faculty of Dentistry, Ankara University, Turkey

Correspondence to: Prof. Dr. Kaan ORHAN, Ankara Department of Dentomaxillofacial Radiology, Faculty of Dentistry, Ankara University, 06510 Besevler, Ankara, Turkey.

Email: call53@yahoo.com

Telephone: +90-31-22965633 Fax: +90-31-22123954

Received: July 11, 2015 Revised: September 25, 2015

Accepted: September 30, 2015

Published online: December 23, 2015

© 2015 ACT. All rights reserved.

Key words: Temporomandibular joint; Anatomy; TMJ Disorders, TMJ Imaging

Eren H, Kolsuz ME, Orhan K. An Overall Look for Temporomandibular Joint Pathologies and Imaging. *International Journal of Orthopaedics* 2015; 2(6): 452-461 Available from: URL: <http://www.ghrnet.org/index.php/ijo/article/view/1539>

ABSTRACT

Temporomandibular joint (TMJ) complex is one of the most complex joint which connects the mandible to the skull. This kind of joint system has ability to perform complex and bilateral movements. Because, TMJ has a complicated anatomy, there is a need for a thorough investigation to find the correct cause of TMJ disorders, as well as knowing the TMJ anatomy. Anatomical structures of TMJ contain hard tissues and soft tissues. Soft tissues consist of joint capsule, ligaments, articular disc, muscles and tendons. A healthy joint is connected to proper and compatible function of all these anatomical structures. Temporomandibular disorder (TMD) is a term used for any problems that affecting the temporomandibular joint. Possible causes for TMD are injury to the TMJ or related anatomical structures, clenching the teeth or bruxism, dislocation of the disc, presence of osteoarthritis or rheumatoid arthritis in the TMJ, emotional stress, aging, etc. The most common TMJ disorders are pain dysfunction syndrome, internal derangement, arthritis, and traumas. Radiographic imaging is an important element in the correct diagnosis. Because of the anatomic complexity of the temporomandibular joint and its proximity to the temporal bone, mastoid air cells, and auditory structures, imaging of the joint structures should also be investigated. Therefore, careful clinical and radiological examinations are essential in the evaluation of TMJ. In this review, TMJ anatomy, Imaging methods, the classification of various pathologies and radiological techniques, are discussed.

INTRODUCTION TEMPOROMANDIBULAR JOINT ANATOMY

Temporomandibular joint (TMJ) is one of the most complex, delicate and highly used joint which connects the mandible to the skull^[1]. It is generated by parts of mandible and temporal bone, separated by an intra-articular disc made of fibrocartilage^[2]. The articular disc absorbs stress and allows the condyle to move easily during the mouth movements^[3,4]. Mastication and speech are the most important functions of TMJ, and has ability of rotation and translatory movements^[2]. Structural components of TMJ are hard tissues (bones), joint capsule, ligaments, intra-articular meniscus, muscles and tendons.

(1)Bones

Mandible and temporal bone are hard tissue components of TMJ. The mandible, is the largest and the strongest bone of the face, has two parts including horizontal (the body) and vertical (the ramus). The ramus of the mandible includes the hard tissue component of TMJ consisting of the condylar process that rests within the glenoid fossa of temporal bone. Head of the condyle has a shape of convex in all directions^[5].

The squamous portion of the temporal bone contains the articular surface with a concave glenoid fossa posteriorly and a convex articular tubercle anteriorly. The articular surface of the glenoid fossa is smooth and oval, containing the articular disc or meniscus. The articular tubercle is convex in an anteroposterior direction and concave mediolaterally. This shape is compatible with the slope of

the condyle which allows a harmonic condylar movement.

The articular surfaces of the condyle and the glenoid fossa are covered with cartilage^[4]. The left and right mandibular bodies are adherent that provides a connection between the two temporomandibular joints, so that mandibular movement always occurs with both bilateral temporomandibular joints.

Joint Capsule And Ligaments

The capsule of the temporomandibular joint is thin and loose, but it becomes tight below the disc as it attaches disc to the neck of the mandible^[6]. But, its looseness prevents ruptures by excessive force of the mandibular movement. It attaches to the articular tubercle superiorly and anteriorly, to a bony fissure posteriorly (the squamotympanic fissure) and along the circumference of the mandibular fossa^[6].

The temporomandibular ligament and capsule are classified as collateral ligament that surrounds the joint space laterally and medially. This ligament widely attaches from the tubercle on the root of the zygomatic process above to a narrow attachment of the mandibular neck below, providing a fan shape of fibers being horizontal to vertical. Lateral temporomandibular ligament is the strongest ligament and it is attached above to the zygoma, and below, the ligament is attached to the lateral surfaces and posterior border of the neck of the mandible. The fan-shaped fibers limit the backward movement of the mandible (retrusion) and prevents compressive forces on tissues behind the condyle^[5]. At its posterior aspect, it is in close relation to the joint capsule and prevents the joint from opening widely^[2].

There are 2 accessory ligaments associated with the TMJ. These extracapsular ligaments are the sphenomandibular (between the spine of the sphenoid bone and the lingula of the mandible) and the stylomandibular (from the styloid process of the temporal bone to the mandibular angle). The sphenomandibular and stylomandibular ligaments act as a guide limitation to keep the condyle, disc, and temporal bone tightly mutual. The stylomandibular ligament is a specialized band of deep cerebral fascia with thickening of the parotid fascia.

Other ligaments are called as oto-mandibular ligaments. These ligaments connect middle ear (malleus) with temporomandibular joint: (1) Discomalleolar (or disco-malleolar) ligament; (2) Malleomandibular (or malleolar-mandibular) ligament.

(2) Intra-Articular Meniscus

The intra-articular meniscus is also named as articular disc, and its entire surroundings is attached along to the capsule. The articular disc is an oval fibrous plate, and concave on its inferior surface. Articular cartilages are generally composed of hyaline cartilage, conversely this disc is composed of fibrocartilage; so, there is a much higher percentage of collagen in the structure of the disc, increasing its strength and resistance.

There are three zones of the disc and a thinner intermediate zone separates the anterior band from the posterior band. The posterior band continues posteriorly with a thick layer of the loose connective tissue, the retrodiscal pad. Vascularization and innervation of the retrodiscal pad supplies the articular disc. This loose connection allows anterior movement of the disc^[5].

The disc divides the joint cavity into two compartments - superior and inferior^[4,7]. Gliding, translation, or sliding movement occurs in the superior compartment, whereas rotation or hinge movement occurs in the inferior compartment^[8]. The two compartments of the joint are filled with synovial fluid which provides lubrication and

nutrition to the joint structures^[7]. Articular disc is also inferiorly attached to medial and lateral poles of condyle as joint capsule. This connection provides disc moving together with condyle during mandibular movement.

(3) Muscles And Tendons

The most important muscular components of temporomandibular complex are temporal, masseter, lateral and medial pterygoid muscles.

The temporal muscle originates from the temporal fossa and at the temporal fascia. It lies deep to the zygomatic arch and adheres to the coronoid process of the mandible. Contraction of this muscle closes the mouth.

The masseter muscle has superficial and deep parts. The superficial part originates at the lower edge and deep aspect of the zygomatic arch and the deep part originates at the temporal fascia. Both parts settle superficially from the mandibular ramus towards the mandibular angle. They have extensive insertions into the tuberosity. Contraction of the masseter muscle closes the mouth.

The medial pterygoid originates in the pterygoid fossa at the base of skull and inserts into the deep aspect of the mandibular angle at the pterygoid tuberosity. Its movement is associated with the masseter and temporalis muscles.

The lateral pterygoid muscle lies on the deep aspect of the mandibular neck and it has two parts. One part originates at the major wing of the sphenoid bone, the other part originates at the lateral aspect of the pterygoid process. The two parts course laterally and posteriorly, combine with each other and insert into the pterygoid fovea of the mandibular condyle, the joint capsule and the meniscus. Due to the course of the muscle in an anteromedial to posterolateral direction, bilateral action of both lateral pterygoids opens the mouth. Unilateral contraction provokes a contralateral deviation of the chin. The medial and lateral pterygoid muscles are too deep to be palpated. The suprahyoid muscles (digastric and stylohyoid) and the muscles of the floor of the mouth (mylohyoid and geniohyoid) has a mission in opening of the mouth. But, they are of little clinical importance^[2].

TEMPOROMANDIBULAR DISORDERS

Temporomandibular disorder (TMD) is a term used for any problems that affecting the temporomandibular joint. TMDs can be divided into two main groups as articular (joint) and nonarticular (myogenic) disorders, due to clinical presentation^[9]. Possible causes for TMD include injury to the TMJ or related anatomical structures, clenching the teeth or bruxism, dislocation of the disc, presence of osteoarthritis or rheumatoid arthritis in the TMJ, emotional stress, aging, etc^[10-13]. The most common TMJ disorders are pain dysfunction syndrome, internal derangement, arthritis, and traumas^[11,14]. People between the ages of 20 and 40 years are the most affected age group, and females are affected more than males^[11,14].

(1) Myogenic Disorders

Disorders of myofascial pain (MFP) and myofascial pain and dysfunction (MPD) are frequently encountered as myogenic origin. Other TMJ disorders which originate from the muscles are myositis, fibrosis, tendonitis, whiplash injury and fibromyalgia^[9]. If positive signs of tenderness to palpation in two or more muscle sites, than patients can be initially diagnosed as MFP. But if there is a concomitant limitation in jaw opening, MFP escalates to myofascial pain and dysfunction. There are few theories trying to explain the relation between myogenic disorders and TMDs. One is that

structural abnormalities (dental malocclusion, condylar malposition, etc.) led to muscular dysfunction and pain^[15,16]. Pain and muscular hyperactivity potentiate each other and emotional stress is thought to have an additive effect^[15,16]. After a while, it was seen that there is not enough scientific evidence to support this theory. But, it has been reported that approximately 50% of all patients with TMJ disorders have also masticatory myalgias or painful masticatory muscle disorders^[17].

MFP is often induced by stress-related factors such as parafunctional habits and rarely by mechanical factors such as high dental restorations. This type of disorders (MFP or MPD) are thought to lead degenerative diseases of the TMJ^[12].

TMJ pain related to an articular disorder may also lead to MFP. It can be explained by reflex muscle contractions in the muscles of mastication^[15,16]. This is encountered as a self-protective reflex. Patients will present with tenderness and hyperalgesia at sites distant to the joint that mimic MFP. They may also have tenderness to palpation in various trigger points.

(2) Articular Disorders

Simultaneous action of condyle and disc is very important to avoid damage to the disc. Disc displacement or internal derangement is the most common TMJ disorder. It is described as an abnormal relationship between the articular disc and condyle^[13,18]. The disc is displaced from the correct position and there is often a direct contact between condyle and articular fossa which creates additional degeneration on the joint, this condition causes the TMD to get worse^[13,19]. Disc displacement generates a sound called clicking when the disc is displaced or returns back to its normal position during the movement of the mandible. Clinically, this clicking sound can be identified as an initial symptom of the disc displacement of temporomandibular joint^[13]. The anterior disc displacement has different degrees of severity. Staging classifications has been represented for the TMJ related disc displacements^[20,22]. In addition disc displacements can progress to degenerative joint disease. These stages were defined based on clinical, radiological or pathological findings of the jaw. The stages ranged from the early stage included slight displacement with clicking, and no pain or dysfunction to the last stage included degenerative changes to the disc with possible perforation, flattening of bones, pain, and restricted motion^[20,22]. If the displaced disc returns to its normal position during the mouth opening movement with or without a simultaneous clicking sound, it is defined as disc displacement with reduction^[23-25]. If the displaced disc does not return to the normal position during the mouth opening movement, this time it is defined as disc displacement without reduction^[23-25]. The condyle's forward translation is limited by the disc's anterior position and is unable to reduce onto the disc, allowing only for rotational and not translational movement in the disc displacement without reduction. Thus, clinically limited mouth opening can be seen in the patients with disc displacement without reduction. Approximately 70% of TMD patients also have disc displacement^[14,18]. The disc displacement frequently precedes the onset of TMJ osteoarthritis^[7].

(3) Other Factors Causing TMD

The other etiological factors of articular disorders may be infectious, immunologic, metabolic, neoplastic, congenital, or developmental.

Clinically, inflammation of capsular ligament may come up as swelling and continuous pain localized to the joint and is defined as capsulitis. Jaw movements that tighten up the capsular ligament cause pain with limitation of the movement. Progressively, inflammation

may increase joint fluid volume. As a result, ipsilateral posterior open bite may be seen as a clinical finding secondary to inferior displacement of the condyle^[16]. Similarly, the retrodiscal tissue may be inflamed due to trauma or abnormal function. Thus, Edema in the retrodiscal pad may cause anterior displacement of the condyle and an acute malocclusion with painful limitation of mandibular movements^[9].

The highly innervated and vascularized synovial membrane is a highly innervated and vascularized tissue that plays a role in digestion of debris and pain mediators released from cartilage degradation. When this ability is broken down, inflammation of acute synovitis results. Acute synovitis is an early sign of degenerative joint disease^[26].

Another joint disease is arthritis. Some etiological factors of TMJ arthritis are mostly degenerative joint disease and rheumatoid arthritis and less often infectious, metabolic (gout), or immunologic (ankylosing spondylitis, lupus). So, arthritis of TMJ has a multifactorial pathogenesis including biomechanical, biochemical, inflammatory, and immunologic insults. Excessive and repetitive mechanical stress has been implicated^[27]. Inflammation may cause changes in the viscosity of synovial fluid, which changes its ability to nourish the articular cartilage. As a result, cartilage metabolism changes. TMJ arthritis is classified as primary (no known predisposing factors) or secondary (associated with known abnormalities or injuries). Symptoms of primary arthritis begin in the fifth to sixth decade, while, Secondary arthritis produces symptoms at an earlier age. In contrast to the arthritides of other joints, symptoms of TMJ arthritis is not necessarily be present in other joints. Patients with TMJ arthritis have complaints of increasing pain during increased function and feeling a kind of load on the jaw all day long. Joints have tenderness to palpation and decrease of movement in mouth opening. Crepitation may exist that indicate loss of articular cartilage. Patients may have referred pain to head and neck regions. In the osteoarthritic joint, progressive softening and loss of cartilage may occur which is called as chondromalacia (softening of the articular cartilage) of the TMJ^[26,28]. Joint noise may occur due to disc displacement or disc perforation. This condition progresses to the later stages, and crepitation may be developed secondary to bone exposure. Pain and adhesion formation result in limitation of mouth opening.

IMAGING OF TMJ

The correct diagnosis for treatment of TMJ pathology has an important place. Radiographic imaging is an important element in the diagnosis. Because of the anatomic complexity of the temporomandibular joint and its proximity to the temporal bone, mastoid air cells, and auditory structures, imaging of the joint structures can be problematic. With respect to the TMJ this involves assessment of the integrity and relationships of the hard and soft tissues, including the mandibular condyle, the glenoid fossa and articular eminence of the temporal bone, and the articular disk and its attachments^[29].

The petrous and tympanic parts of the bone lie in close proximity to the joint. To avoid superimposition of these parts, various projection techniques have been applied in the quest for usable images. Over the years, when radiologists were limited to the use of conventional radiographic imaging, different oblique projections were used each of them with shortcoming in their depiction of the joint^[30]. Many imaging techniques is used for TMJ viewing conventional radiography, plain and panoramic radiography, computerized tomography (CT) scan, cone beam tomography

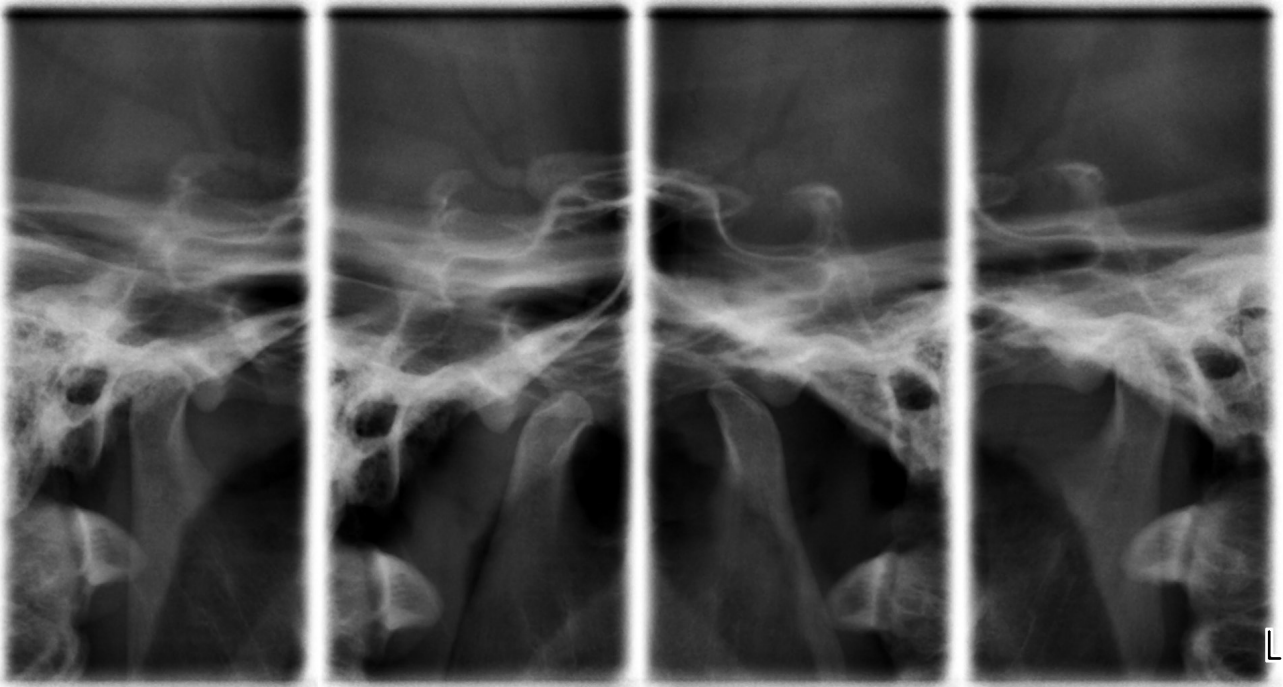


Figure 1: Mouth opened and closed oblique lateral transcranial projection imaging of TMJ in the same plane. Note that flattening in the anterior border of right condyle and erosion in the left condyle are seen.

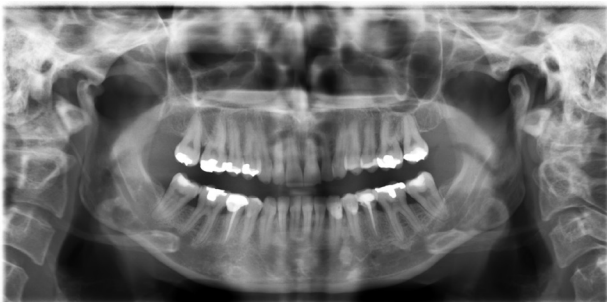

Figure 2: Panoramic radiographic imaging of TMJ demonstrated very well the osseous structures of TMJ and dentomaxillary region. Note that "bird beak" appearance in the right condyle which was indicative of an osteophyte and/or osteoarthritic change is seen.

(CBCT), arthrography, magnetic resonance (MRI), axiography and also ultrasonography^[31-39].

(1) Conventional Radiography

First diagnostic radiological method for bone analysis was conventional x-ray technique with different angulation and rotation of patient head towards x-ray beam, to avoid superposition of opposite joint. Inadequate x-ray positioning, due to anatomic variations of bony structures of the joint, often resulted in image distortion. Various techniques is used in conventional radiography.

(a) Oblique lateral transcranial projection: As transcranial oblique projection X-ray to prevent superposition of the temporal bone petrous implies that the inclined portion of caudally. In addition, the x-ray beam is inclined anteriorly to align with the long axis of the condyle being depicted. The standart examination using this techniques includes one view at mouth closure and at maximum mouth opening (Figure 1). This viewing techniques can show only lateral part of joint, central and medial parts are not visualized^[30].

(b) Postero-anterior projection: In this techniques X-ray beam inclined in a cranial and medial direction, while expose patient's mouth open and mandible protruded. The projection reduces

superimposition of adjacent structures such as the articular tubercle, tympanic part of the temporal bone, and the mastoid process. In this techniques the superior contour of the condyle and ascending ramus can seen^[29,30].

(c) Submento-vertex projection: The beam passes parallel to posterior border of ascending ramus. This projection is used to determine the individual inclination of long axes of the condyles, in order to correct the oblique lateral transcranial projection and sagittal tomography^[29,30].

(2) Panoramic Radiography

Orthopantomography (OPT) is the most widespread radiographic investigation carried out today. It represents an extraoral study technique in which both revelation system and radiogenic source are external to the oral cavity. The other name of OPT is panoramic. Panoramic radiograph is advocated by some Clinicians as an appropriate imaging technique due to that TMJ area displays, TMJ evaluation and to give additional information about teeth and other regions of the jaw^[29]. Panoramic imaging technique demonstrated very well the osseous structures of TMJ and is screening method for internal joint derangement (Figure 2). The panoramic radiograph of the temporomandibular joint serves only to reveal advanced degenerative changes of the condyle and primary joint problems such as fractures, joint involvements with syndromes, tumors, cysts, osteomyelitis, hyperplasias, hypoplasias, and aplasias^[40-42] (Figures 3, 4). In some cases TMJ evaluation can not be done correctly because of superposition. TMJ anatomy can be misdiagnosed as pathological change and condylar positional changes are not conclusive for the same reason. There are some programmes especially designed for TMJ imaging. These images are more reliable with regard to bony changes and positional variation in the joint but small pathologic changes in TMJ can't be diagnosed with these programmes^[43].

(3) Computerized Tomography

Computed tomography (CT) as a diagnostic tool has been indispensable routine in medicine for many years, its application in

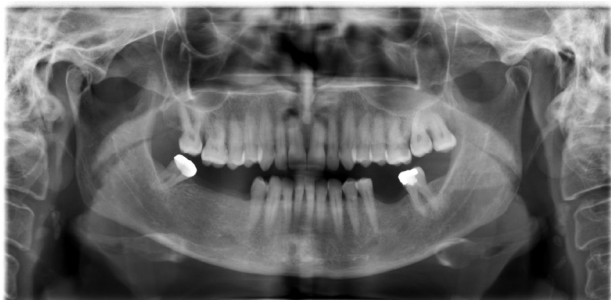

Figure 3: Panoramic radiograph shows bifid mandibular condyle in the both side.

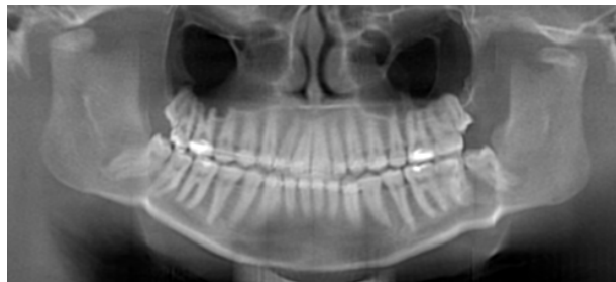

Figure 4: Reconstructed panoramic view taken by CBCT shows condylar fracture in the both side.

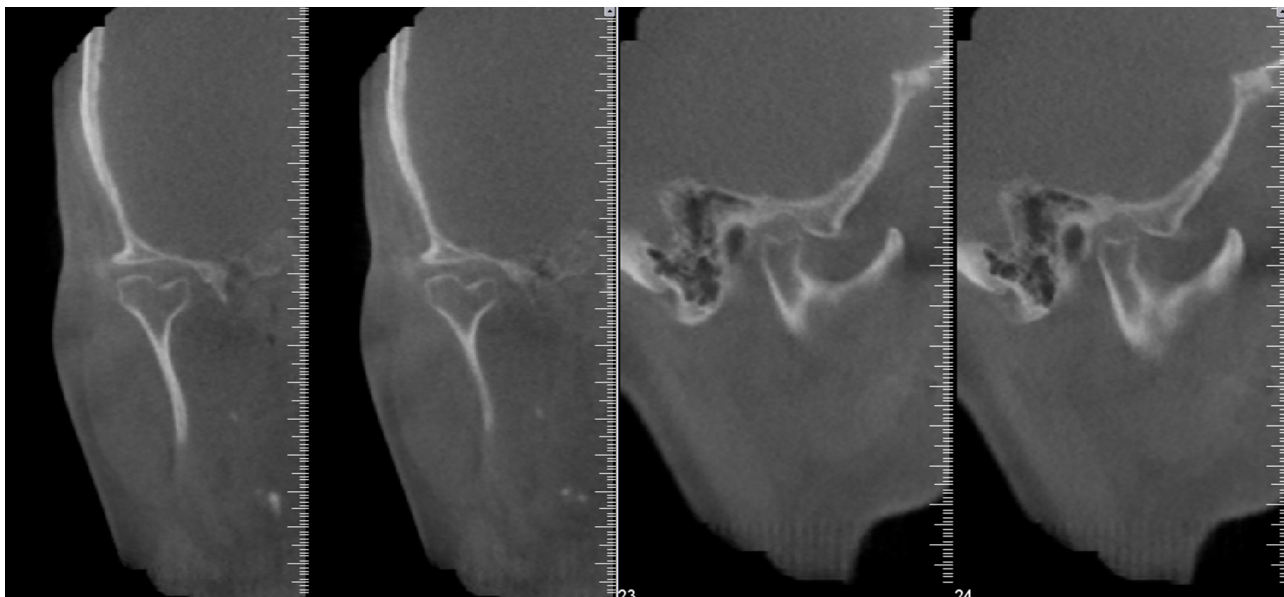


Figure 5: Para-coronal and para-sagittal sectional images of TMJ show bifid mandibular condyle in different planes.

dentistry has taken slower steps^[44]. CT scans are now widely used for the examination of pathological conditions and trauma in the maxillofacial region, in pre-surgical implant treatment planning and the assessment of the temporomandibular joint^[45,46]. Computed tomography (CT) thin sections of the structures of interest can be made in several planes and viewed under varying conditions that highlight either hard or soft tissue (bone or soft tissue windows). The ability to differentiate between soft tissues on CT images has been evaluated in several studies of the TMJ disc to improve the projection geometry at CT examinations, a corrected sagittal projection has been performed. The findings regarding disc position are often, however not conclusive^[29,30].

Eliminating image distortion and superposition although computed tomography shows that CT the advantages and bone structure shows excellent acceptable, CT can provide three-dimensional images from the original data again^[29]. CT arthrography which implicated injection of contrast media in the joint the disk can be demonstrated^[47,48].

(4) Cone-Beam Computed Tomography

Cone-Beam Computed Tomography (CBCT) is a medical imaging technique in which a cone-shaped X-ray beam centered on a two dimensional (2D) detector produces a series of 2D images. The reconstruction of these images in a 3 dimensional (3D) data set is done using the modified Feldkamp algorithm^[49,50]. Hence data can be reformatted in a volume rather than a slice, thereby giving 3D information CBCT also allows multiplanar reformation i.e., 2D images in axial, coronal, sagittal and even oblique or curved image

planes. There are potential advantages of CBCT over CT in the imaging of the maxillofacial region. The dedicated head and neck CBCT systems can be adjusted to scan small regions for specific diagnostic tasks by efficient collimation of the primary x-ray beam. Thereby the size of the irradiated area is significantly reduced^[51,52]. Several authors have reported high dimensional accuracy of maxillofacial CBCT in measuring facial structures^[53,54], including the TMJ^[44-55]. Tsiklakis et al described a protocol for examining TMJ articulation including transaxial images obtained para-sagittally and para-coronally ie, in planes parallel or perpendicular to the long axis of the condyle instead of the true anatomic coronal and sagittal planes (Figure 5).

Many in vitro cadaver study to assess bone defects and osteophytes have explored the role of CBCT. Erosive changes in the TMJ are most effectively diagnosed using CBCT in the 6 inch FOV as compared to the 12 inch FOV^[56,57]. and also CBCT plays an significant role in diagnosing early stages of juvenile idiopathic arthritis (JIA) in children which, when undetected, can damage facial development and cause growth alterations^[57]. Alkhader, et al. performed a comparative study between CBCT and MRI. According to them CBCT is better than MRI in detecting changes in shape (flattening, osteophyte formation or erosion) rather than changes in size (Figure 6). They executed that this was possible because MRI had narrow spatial resolution and increased slice thickness (>3mm)

Several radiographic methods are used to assess the TMJ, an area that is difficult to be imaged due to factors like superimposition of adjacent structures and morphological variations. CBCT maintain

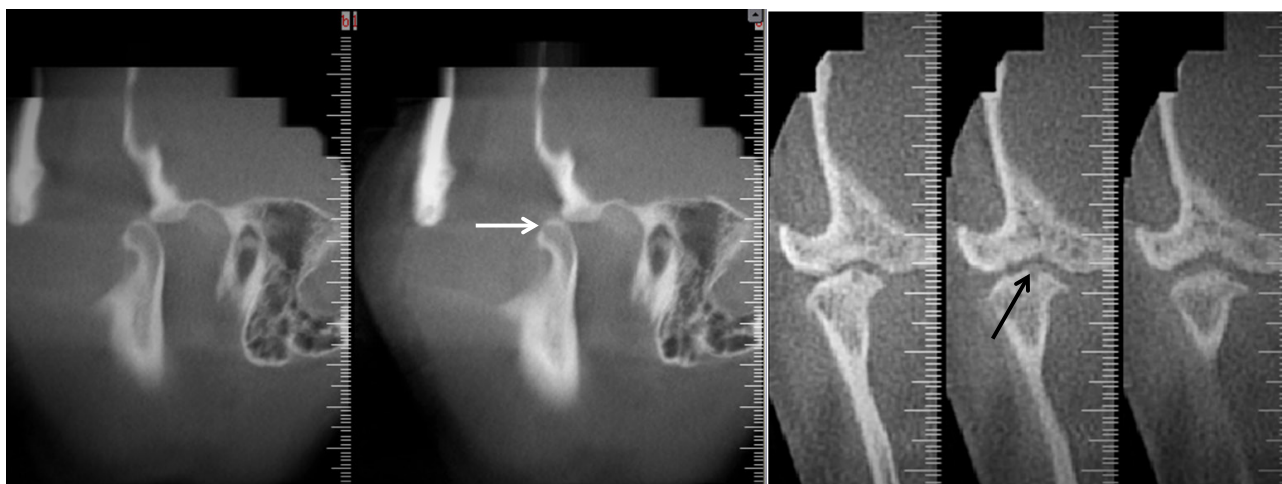


Figure 6: Para-sagittal sectional images show flattening in the anterior border of condyle (white arrow), and para-coronal sectional images show surface erosion with osteophyte (black arrow).

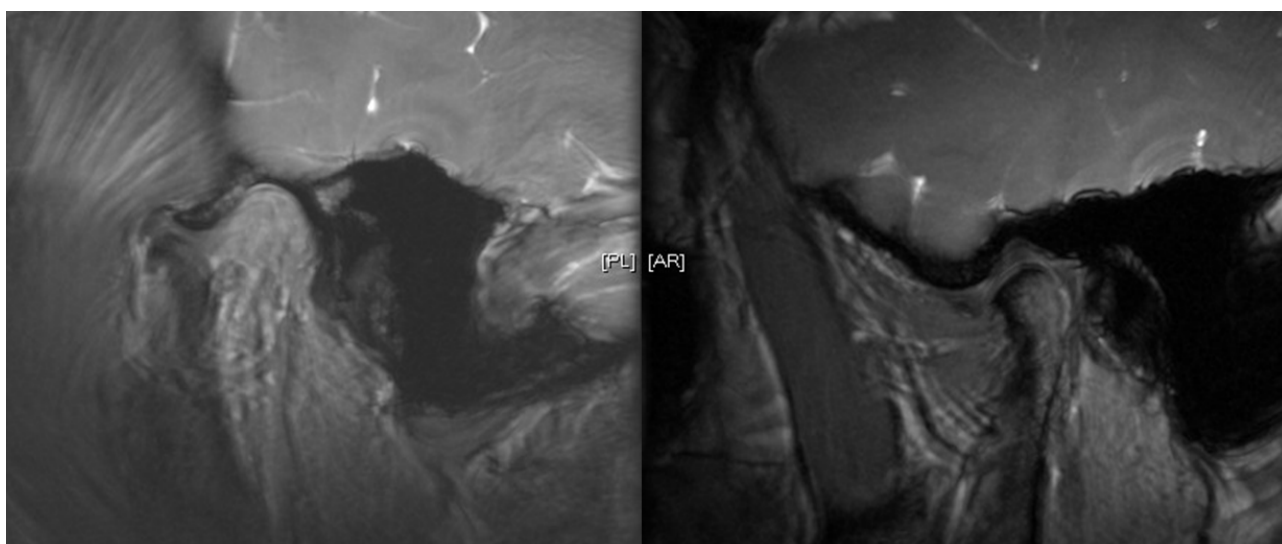


Figure 7: Mouth-opened and mouth-closed sagittal views of TMJ on T2-weighted MRI show the normal relation of articular disc and hard tissue components of TMJ.

a definite advantage, over other techniques because its low radiation dose to patient, smaller equipment and capacity to provide multiplanar reformation and 3D images^[51].

(5) Magnetic Resonance

Magnetic resonance imaging is a noninvasive technique that uses a magnetic field and radiofrequency pulses instead of ionizing radiation to produce the images. MRI is a more expensive examination than CBCT because of the cost of the equipment, facilities, staffing, and replacement part. In order to use correctly this method one should know the MR anatomy of temporomandibular joint^[57,58]. Primarily in MR imaging of the TMJ is to assess the articular disk, or meniscus, in terms of its morphologic features and its location relative to the condyle in both closed- and open-mouth positions (Figure 7). At sagittal MR imaging, the meniscus appears as a biconcave structure with homogeneous low signal intensity that is attached posteriorly to the bilaminar zone, which demonstrates intermediate signal intensity. The posterior band and retrodiskal tissue are best pictured in the open-mouth position^[59,60]. Typically, the anterior band and the intermediate zone are hypointense and the posterior band is slightly hyperintense, although the posterior band is more frequently hypointense in patients with disk disease^[61]. Disk injuries are the

most common cause of TMJ dysfunction. MR imaging is currently the standard imaging technique for diagnosing disk injuries, which can show as intrinsic disk lesions (eg, changes in shape and signal intensity) or disk displacement^[62]. Disk location has been significance because the presence of a displaced disk is a critical sign of TMJ dysfunction (Figure 8).

MRI may assist the clinician in determining whether primary or delayed treatment is indicated in cases of trauma to the TMJ. The saggital and coronal MRI of TMJ articulation are flattering, and is important for a full assessment of joint dysfunction. Using high-field strength surface coil MRI particular changes associated with disc derangement, trauma and previous surgery can be illustrated. Moreover, the existence of soft tissue ingrowths, fibrosis and joint effusions can be determined^[63] (Figure 9).

(6) Ultrasonography

The principle of ultrasonography is based on the fact that ultrasonic sound waves emitted by a device (transducer), proceed through the tissue against which they are aimed, and are partly reflected on transiting through different anatomical structures. The reflected sound waves are then read by the same emitting device, and translated into images^[64].

Ultrasonography (US) may represent a useful option in

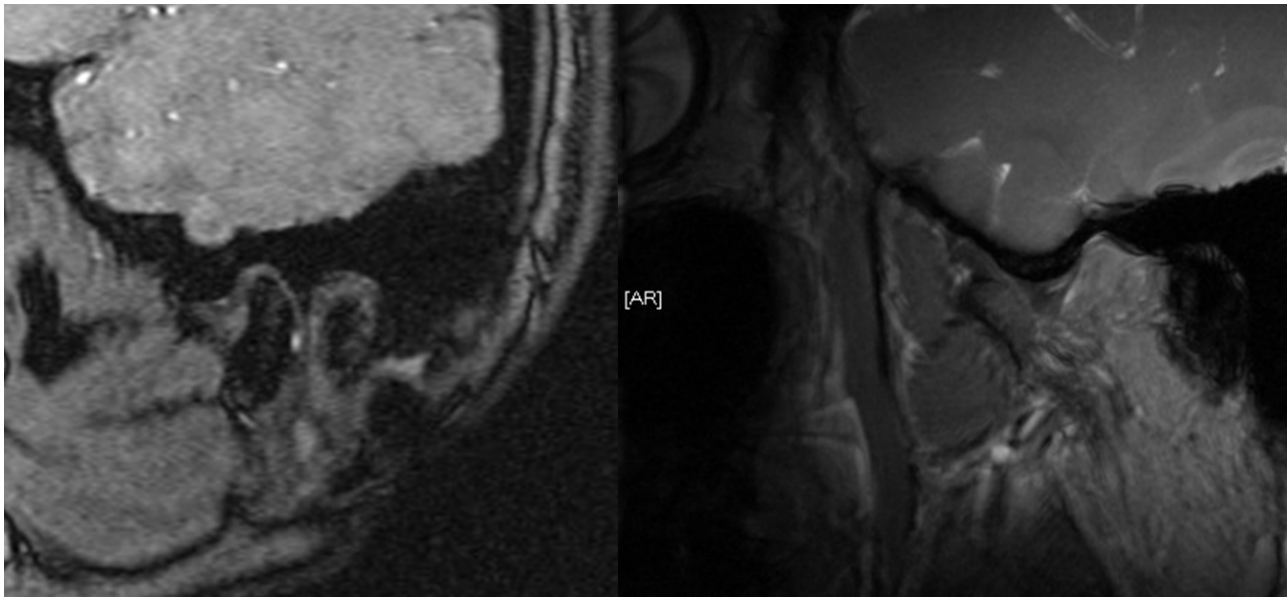


Figure 8 Sagittal sectional views of TMJ on mouth-closed T1-weighted and mouth opened T2-weighted MRI show anterior disc displacement without reduction (white arrows).

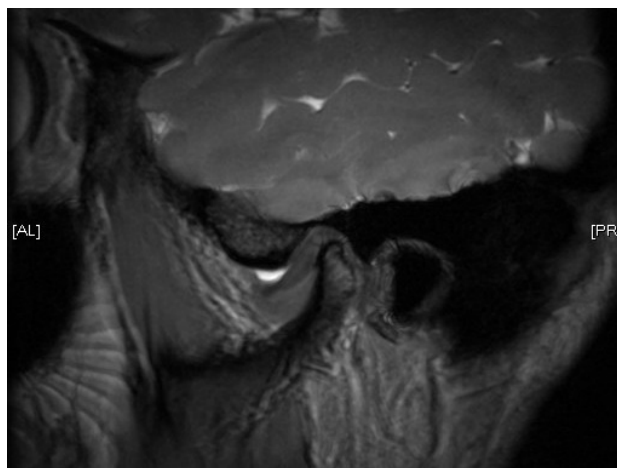


Figure 9 Sagittal sectional view of mouth-closed T2-weighted MRI shows anterior disc displacement with hyperintense joint effusion in superior synovial cavity.

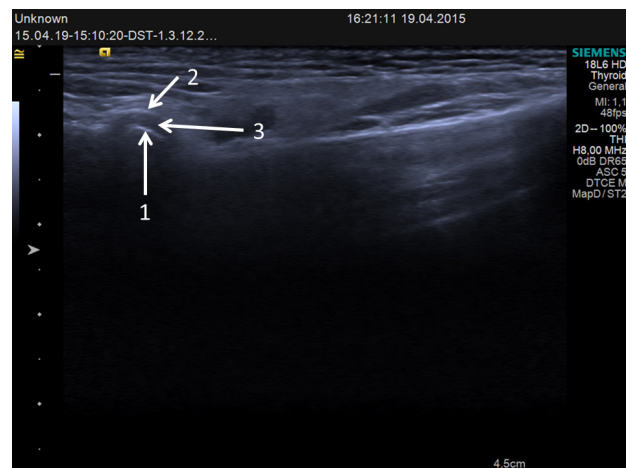


Figure 10 Ultrasonographic view of TMJ shows condyle (arrow 1), articular eminence (arrow 2) and articular disc (arrow 3).

cases of internal TMJ disorders and in the cases of patients with contraindications for MRI, such as those presenting with claustrophobia or with pacemakers^[65].

The TMJ region consists of varied structures that reflect sound waves differently. Bone tissue, represented by the head of the condyle and the articular eminence, is generally hypoechoic (low reflection of sound waves) and appears black in ultrasonography images, nonetheless the margin of the bone is hyperechoic (high reflection of sound waves) and appears white in ultrasonography images (Figure 10). Connective tissue, represented by the joint capsule and the retrodiscal tissue, and muscular tissue, represented by the lateral pterygoid and masseter muscles, are isoechoic (intermediate reflection of sound waves) and appear heterogeneously grey in ultrasonography images. though the surface of the joint capsule, as well as the surface of the muscles, highly reflect the sound waves generating a hyper-echoic (white) line. Empty space and water, like the superior and inferior joint spaces, are hypoechoic and appear black in ultrasonography images, however, these anatomic cavities are virtual because the contrary surfaces are in contact, and usually not detectable, unless effusion is present^[66].

The articular disc, similarly to all major ligaments, consists of dense fibrous tissue, but its visual aspect in ultrasonography images is controversial. It has been reported to be hyperechoic^[67-70], hypoechoic^[71-75], isoechoic^[76], and hypoechoic to isoechoic^[77], probably for the presence of different structural, morphological and positional abnormalities in the patients examined. By ultrasonography it is also conceivable to identify sites of inflammation by detecting the presence of articular effusion.

Ultrasonography as a quite sensitive diagnostic aid in the diagnosis of TMJ disorders. It has become one of the most recommended methods in recent decades because of its non-invasiveness, inexpensiveness, and ability in evaluating the integrity and correlation of the hard and soft tissues of the TMJ through static and dynamic assessments^[76,77].

On the other hand there are some disadvantages using ultrasonography, US images highly depends on the operator, as the images can be foggy and not clear. The difficulty in visualizing articular disc is one of the limitations of ultrasonography. The disc visualized only through the small gap between the zygomatic process of the temporal bone and the head of condyle. It becomes difficult to

acquire satisfactory images, especially when the condyle rotates and translates from the mouth-closed position to the mouth-open position. Therefore only the lateral part of the TMJ can be reached, while the medial part remains hidden by the mentioned structures^[77].

(7) Arthrography

Arthrography is a medical imaging technique to evaluate conditions of joints. It can either be indirect or direct.

Indirect arthrography is a medical imaging technique in which contrast material is injected into the blood stream, which will eventually absorb into the joint. With direct arthrography, the contrast material is injected directly into the joint. Direct arthrography is the preferred method because it is better for distending or enlarging the joint and imaging small internal structures to allow for better evaluation of diseases or conditions within the joint. It, however, is often performed only if a non-arthrographic exam is felt to be inadequate. Conventional direct arthrography of a joint uses a special form of x-ray called fluoroscopy after an injection of contrast material containing iodine is administered directly into the joint space. The space occupied by the disc can then be visualised lying between the layers of contrast material^[78].

Arthrography provides information regarding the soft tissue components, specifically the shape and position of the articular disc^[79]. It has been demonstrated that with the addition of tomography, the diagnosis of abnormalities in the position and shape of the disc is accurate^[80].

Fluoroscopic observation of the injection may reveal the presence of adhesions, perforations and discontinuities in the capsule and provides a dynamic study of disc movements, also any abnormal accumulation of joint fluid may be evident. An arthrogram can clearly distinguish the synovial changes of an inflammatory arthritis from an internal derangement resulting from meniscal dysfunction^[81].

Temporomandibular joint arthrography has gained acceptance as the "gold standard" for the diagnosis of internal derangements of the temporo-mandibular joint. The dynamics meniscal derangements especially in the clicking jaw, remains an invaluable aspect of this modality in contrast to the static images obtained with CT and MRI^[82].

CONCLUSION

TMJ is one of the complex joint in the entire body. Because of this complexity of the temporomandibular joint, the pathologies as well as normal anatomical patterns must be known before any diagnosis. The pathologies related to temporal bone, mastoid air cells, and auditory structures, imaging of the joint structures should also be investigated. Therefore, clinicians should have careful clinical and radiological examinations before having a definite TMD. In this review, TMJ anatomy, Imaging methods, the classification of various pathologies and radiological techniques are discussed.

CONFLICT OF INTERESTS

There are no conflicts of interest with regard to the present study.

REFERENCES

- Alomar, X., Medrano, J., Cabratosa, J., Clavero, J., Lorente, M., Serra, I., Monill, J., Salvador, A., Anatomy of the temporomandibular joint. *Seminars in Ultrasound, CT, and MRI* 2007; 28:170-183.
- Ombregt L. A system of orthopaedic medicine-section 9: Applied anatomy of the temporomandibular joint. 3th Ed. Elsevier Ltd. *Churchill, Livingstone* 2013; 198-201.
- American Association of Oral and Maxillofacial Surgeons (AAOMS), 2007. *The temporomandibular joint (TMJ)* Retrieved on 10/14/2007, from <http://www.aaoms.org/tmj.php>, 1.
- Ide, Y., Nakazawa, K., Garcia, L. T., Anatomical atlas of the temporomandibular joint. *Quintessence Publ. Co., Chicago* 1991; 116.
- Helland MM. Anatomy and Function of the Temporomandibular Joint. *JOSPT* 1980; 1(3):145-152.
- Warwick R. Williams PL: *Gray's Anatomy*. 35th Ed. *WB Saunders and Co, Philadelphia* 1973.
- Tanaka, E, Detamore, M. S., Tanimoto, K., Kawai, N, Lubrication of the temporomandibular joint *Annals of Biomedical Engineering* 2008; 36:14-29.
- Fehrenbach MJ, Herring SW. *Illustrated anatomy of the head and neck-chapter 4: Temporomandibular Joint*. 4th Ed. *Elsevier Ltd* 2011; 224-240.
- Herb K, Sung Cho S, Stiles MA. Temporomandibular Joint Pain and Dysfunction. *Current Pain and Headache Reports* 2006; 10:408-414.
- Bakke, M., Zak, M., Jensen, B. L., Pedersen, F. K., Kreiborg, S., Orofacial pain, jaw function, and temporomandibular disorders in women with a history of juvenile chronic arthritis or persistent juvenile chronic arthritis *Oral Surgery, Oral Medicine, Oral Pathology, Oral Radiology, and Endodontics* 2001; 92:406-414.
- Detamore, M. S., Athanasiou, K. A., Mao, J., A call to action for bioengineers and dental professionals: directives for the future of TMJ bioengineering *Annals of Biomedical Engineering* 2007; 35:1301-1311.
- Ingawalé, S., Goswami, T. Temporomandibular joint: disorders, treatments, and biomechanics. *Annals of Biomedical Engineering* 2009; 37:976-996.
- Tanaka, E., Rodrigo, D. P., Miyawaki, Y., Lee, K., Yamaguchi, K., Tanne, K. Stress distribution in the temporomandibular joint affected by anterior disc displacement: a three-dimensional analytic approach with the finite-element method. *Journal of Oral Rehabilitation* 2000; 27:754-759.
- Detamore, M. S., Athanasiou, K. A. Structure and function of the temporomandibular joint disc: implications for tissue engineering. *Journal of Oral and Maxillofacial Surgery* 2003; 61:494-506.
- Ogle OE, Hertz MB: Myofascial pain. *Oral Maxillofac Surg Clin North Am* 2000; 12:217-231.
- Okeson JP, ed: *Fundamentals of Occlusion and Temporomandibular Disorders*. *St. Louis: C.V. Mosby*; 1985.
- Stohler CS: Masticatory myalgias. In *Oral and Maxillofacial Surgery*. Temporomandibular Disorders. *Edited by Fonseca RJ, et al.: Philadelphia: WB Saunders*; 2000:38-45.
- Farrar, W. B., and W. L. McCarty, Jr. The TMJ dilemma. *J. Ala. Dent. Assoc* 1979; 63:19.
- Chase, D. C., J. W. Hudson, D. A. Gerard, R. Russell, K. Chambers, J. R. Curry, J. E. Latta, and R. W. Christensen. The Christensen prosthesis: a retrospective clinical study. *Oral Surg. Oral Med. Oral Pathol* 1995; 80:273-278.
- Gadd, A., and T. Goswami. Temporomandibular disorder and joint replacement. *Biomed. Mater., Paper No. BM-WRANL-7PJR/W3*, 2009.
- Wilkes, C. H. Arthrography of the temporomandibular joint in patients with the TMJ pain dysfunction syndrome. *Minn. Med* 1978; 61:645-652.
- Wilkes, C. H. Internal derangements of the temporomandibular joint. *Arch. Otolaryngol. Head Neck Surg* 1989; 115:469-477.
- Molinari, F., P. F. Manicone, L. Raffaelli, R. Raffaelli, T. Pirronti, and L. Bonomo. Temporomandibular joint soft-tissue pathology. I: Disc abnormalities. *Semin. Ultrasound CT MRI*

- 2007; 28(3):192-204.
24. Pe´rez-Palomar, A., and M. Doblare´. An accurate simulation model of anteriorly displaced TMJ discs with and without reduction. *Med. Eng. Phys* 2007; 29:216-226.
 25. Schwartz, H. C., and R. W. Kendrick. Internal derangement of the temporomandibular joint: description of clinical syndromes. *Oral Surg. Oral Med. Oral Pathol* 1984; 58(1):24-29.
 26. Quinn JH: Pathogenesis of temporomandibular joint chondromalacia and arthralgia. *Oral Maxillofac Surg Clin North Am* 1989; 1:47-57.
 27. Israel HA, Langevin CJ, Singer MD, Behrman DA: The relationship between temporomandibular joint synovitis and adhesions: pathogenic mechanisms and clinical implications for surgical management. *J Oral Maxillofac Surg* 2006; 64:1066-1074.
 28. Quinn JH: Pain mediators and chondromalacia in internally deranged temporomandibular joints. In *Modern Practice in Orthognathic and Reconstructive Surgery*. Edited by Bell WH. Philadelphia: WB Saunders; 1992; 471-481.
 29. Brooks SL, Brand JW, Gibbs SJ, Hollender L, Lurie AG, Omnell KA, Westesson PL, White SC. Imaging of the temporomandibular joint: A position paper of the American Academy of Oral and Maxillofacial Radiology Review, *Oral Surg Oral Med Oral Pathol Oral Radiol Endod*. 1997; 83(5):609-618.
 30. Isberg A Temporomandibular Joint Dysfunction: A Practitioner's Guide,. *Martin Dunitz Publishers; 1st ed.* 2002; 173-196.
 31. Okeson JP. Assessment of orofacial pain disorders. In: Okeson JP. Orofacial pain: Guidelines for assessment, diagnosis, and management. *Chicago: Quintessence*, 1996; 19-44.
 32. Dworkin SF, LeResche L. Research diagnostic criteria for temporomandibular disorders: Review, examinations and specifications, critique. *JCraniomandib Disord* 1992; 6:301-355.
 33. Okeson JP. History and examination for temporomandibular disorders. In: Okeson JP. Management of temporomandibular disorders and occlusion. 4th Ed. St. Louis: Mosby, 1998; 234-309.
 34. Kaplan AS. Plain, tomographic, and panoramic radiography and radionuclide imaging. In: Kaplan AS, Assael LA. Temporomandibular disorders, diagnosis and treatment. Philadelphia: W.B. Saunders, 1991; 312-336.
 35. Danielson PA. Arthrography. In: Kaplan AS, Assael LA. Temporomandibular disorders, diagnosis and treatment. Philadelphia: W.B. Saunders, 1991; 337-352.
 36. Milbauer DL. Magnetic resonance imaging and computerized tomography. In: Kaplan AS, Assael LA. Temporomandibular disorders, diagnosis and treatment. Philadelphia: W.B. Saunders, 1991; 353-370.
 37. Christiansen EL, Thompson JR. Radiographic evaluation of the TMJ. In: Pertes RA, Gross SG. Clinical management of temporomandibular disorders and orofacial pain. *Chicago: Quintessence*, 1995; 161-174.
 38. Westesson PL. Magnetic resonance imaging of the temporomandibular joint. In: Pertes RA, Gross SG. Clinical management of temporomandibular disorders and orofacial pain. *Chicago: Quintessence*, 1995; 175-196.
 39. Pharoah MJ. The prescription of diagnostic images for temporomandibular joint disorders. *J Orofac Pain* 1999; 13:251-254.
 40. Dixon, D. C.: Radiographic diagnosis of temporomandibular disorders. *Semin Orthod* 1995; 1:207-221.
 41. Greenan, R. W.: Panoramics for the temporomandibular joint? *Funct Orthod* 1997; 14:26-28.
 42. Wilson, B. B.: Panoramic and transcranial radiology in orthodontics and craniomandibular disorders. *J Gen Orthod* 1996; 7:12-20.
 43. Hallikainen D. history of panoramic radiography. *Acta Radiol* 1996; 37:441-445.
 44. Tsiklakis K, Syriopoulos K, Stamatakis HC. Radiographic examination of the temporomandibular joint using cone beam computed tomography. *Dentomaxillofac Radiol*. 2004 May; 33(3):196-201.
 45. Parks ET. Computed tomography applications for dentistry. *Dent Clin North Am* 2000; 44:371-394.
 46. Ylikontiola L, Moberg K, Huumonen S, Soikkonen K, Oikarinen K. Comparison of three radiographic methods used to locate the mandibular canal in the buccolingual direction before bilateral sagittal split osteotomy. *Oral Surg Oral Med Oral Pathol Oral Radiol Endod* 2002; 93:736-742.
 47. Mafee MF, Heffez L, Campos M, et al. Temporomandibular joint: role of direct sagittal CT air-contrast arthrogram and MRI. *Otolaryngol Clin North Am*. 1988; 21:575.
 48. Heffez L, Mafee MF, Rosenberg HM, et al. Double-contrast arthrography of the TMJ: Role of direct sagittal CT Imaging. *Oral Surg Oral Med Oral Pathol*. 1988; 65:511-514.
 49. Gupta R, Grasruck M, Suess C, Bartling SH, Schmidt B, Stierstorfer K, et al. Ultra-high resolution flat-panel volume CT: Fundamental principles, design architecture and system characterization. *Eur Radiol* 2006; 16:1191-2005.
 50. Miracle AC, Mukherji SK. Conebeam CT of the head and neck, part 1: Physical principles *Am J Neuroradiol* 2009; 30:1088-1095.
 51. Krishnamoorthy B, Mamatha N, Kumar VA. TMJ imaging by CBCT: Current scenario *Ann Maxillofac Surg*. 2013 Jan;3(1):80-3. doi: 10.4103/2231-0746.110069.
 52. Kobayashi K, Shimoda S, Nakagawa Y, Yamamoto A. Accuracy in measurement of distance using limited cone-beam computerized tomography. *Int J Oral Maxillofac Implants* 2004; 19:228-231.
 53. Lascala CA, Panella J, Marques MM. Analysis of the accuracy of linear measurements obtained by cone beam computed tomography (CBCT-NewTom). *Dentomaxillofac Radiol* 2004; 33:291-294.
 54. Marmulla R, Wortche R, Muhling J, Hassfeld S. Geometric accuracy of the NewTom 9000 Cone Beam CT. *Dentomaxillofac Radiol* 2005; 34:28-31.
 55. Hilgers ML, Scarfe WC, Scheetz JP, Farman AG. Accuracy of linear temporomandibular joint measurements with cone beam computed tomography and digital cephalometric radiography. *Am J Orthod Dentofacial Orthop* 2005; 128:803-811.
 56. dos Anjos Pontual ML, Freire JS, Barbosa JM, Frazao MA, dos Anjos Pontual A. Evaluation of bone changes in the temporomandibular joint using cone beam CT. *Dentomaxillofac Radiol* 2012; 41:24-29.
 57. Librizzi ZT, Tadinada AS, Valiyaparambil JV, Lurie AG, Mallya SM. Cone-beam computed tomography to detect erosions of the temporomandibular joint: Effect of field of view and voxel size on diagnostic efficacy and effective dose. *Am J Orthod Dentofacial Orthop* 2011; 140:25-30.
 58. Alkhader M, Ohbayashi N, Tetsumura A, Nakamura S, Okochi K, Momin MA, et al. Diagnostic performance of magnetic resonance imaging for detecting osseous abnormalities of the temporomandibular joint and its correlation with cone beam computed tomography. *Dentomaxillofac Radiol* 2010; 39:270-276.
 59. Tomas X, Pomes J, Berenguer J, Quinto L, Nicolau C, Mercader JM, Castro V. MR imaging of temporomandibular joint dysfunction: a pictorial review. *Radiographics*. 2006 May-Jun; 26(3):765-781.
 60. Helms CA, Kaban LB, McNeill C, Dodson T. Temporomandibular joint: morphology and signal intensity characteristics of the disk at MR imaging. *Radiology* 1989; 172:817-820.
 61. Drace JE, Young SW, Enzmann DR. TMJ meniscus and

- bilaminar zone: MR imaging of the substructure diagnostic landmarks and pitfalls of interpretation. *Radiology* 1990; 177:73-76.
62. DaSilva AF, Shaefer J, Keith DA. The temporomandibular joint: clinical and surgical aspects. *Neuroimaging Clin N Am* 2003; 13:573-582.
 63. Sinha VP, Pradhan H, Gupta H, Mohammad S, Singh RK, et al. Efficacy of plain radiographs, CT scan, MRI and ultra sonography in temporo mandibular joint disorders. *Natl J Maxillofac Surg* 2012; 3:2-9.
 64. Merritt CRB. Physics of ultrasound. In: Rumack CM, Wilson SR, Charboneau JW. *Diagnostic ultrasound*. St. Louis: Mosby, 1998; 3-55.
 65. de Mello Junior CF,, de Cassio Saito O, Guimarães Filho HA, Sonographic evaluation of temporomandibular joint internal disorders, *Radiol Bras.* 2011; 44(6):326-334.
 66. Middleton WD, Kurtz AB, Hertzberg BS. Extremities. In: Middleton WD, Kurtz AB, Hertzberg BS. *Ultrasound: The requisites*. St. Louis: Mosby, 2004; 278-301.
 67. Emshoff R, Bertram S, Rudisch A, Gassner R. The diagnostic value of ultrasonography to determine the temporomandibular joint disk position. *Oral Surg Oral Med Oral Pathol* 1997; 84:688-696.
 68. Tognini F, Manfredini D, Melchiorre D, Zampa V, Bosco M. Ultrasonographic vs magnetic resonance imaging findings of temporo-mandibular joint effusion. *Minerva Stomatol* 2003; 52:365-370.
 69. Tognini F, Manfredini D, Melchiorre D, Bosco M. Comparison of ultra-sonography and magnetic resonance imaging in the evaluation of temporo-mandibular joint disc displacement. *J Oral Rehabil* 2005; 32:248-253
 70. Manfredini D, Tognini F, Melchiorre D, Bazzichi L, Bosco M. Ultra-sonography of the temporomandibular joint: Comparison of findings in patients with rheumatic diseases and temporomandibular disorders. A preliminary report. *Oral Surg Oral Med Oral Pathol* 2005; 100:481-485.
 71. Landes C, Walendzik H, Klein C. Sonography of the temporomandibular joint from 60 examinations and comparison with MRI and axiography. *JCraniomaxillofac Surg* 2000; 28:352-361.
 72. Jank S, Rudisch A, Bodner G, Brandlmaier I, Gerhard S, Emshoff R. High-resolution ultrasonography of the TMJ: helpful diagnostic approach for patients with TMJ disorders? *J Craniomaxillofac Surg* 2001; 29:366-371.
 73. Emshoff R, Jank S, Rudisch A, Bodner G. Are high-resolution ultra-sonographic signs of disc displacement valid? *J Oral Maxillofac Surg* 2002; 60:623-628.
 74. Melchiorre D, Calderazzi A, Maddali Bongi S, Cristofani R, Bazzichi L, Eligi C, Maresca M, Ciompi M. A comparison of ultrasonography and magnetic resonance imaging in the evaluation of temporomandibular joint involvement in rheumatoid arthritis and psoriatic arthritis. *Rheumatology* 2003; 42:673-676.
 75. Jank S, Emshoff R, Norer B, Missmann M, Nicasi A, Strobl H, Gassner R, Rudisch A, Bodner G. Diagnostic quality of dynamic high-resolution ultrasonography of the TMJ. *A pilot study. Int J Oral Maxillofac Surg* 2005; 34:132-137.
 76. Emshoff R, Jank S, Rudisch A, Walch C, Bodner G. Error patterns and observer variations in the high-resolution ultrasonography imaging evaluation of the disk position of the temporomandibular joint. *Oral Surg Oral Med Oral Pathol* 2002; 93:369-375.
 77. Emshoff R, Jank S, Bertram S, Rudisch A, Bodner G. Disk displacement of the temporomandibular joint: Sonography versus MR imaging. *Am J Roentgenol* 2002; 178:1557-1562.
 78. Ongole R., Panjrath N., Ahsan A. Pai MK., Temporomandibular joint arthrography an overview, *Pakistan Oral & Dent. Jr* 2002; 22(1):67-69.
 79. Liedberg, Westesson P, Kurita K: sideways and rotational displacement of the temporomandibular joint disk: diagnosis by arthrography and Correlation to cryosectional morphology: *Oral Surg Oral Med Oral Pathol* 1990; 69:757-763.
 80. Westesson P., Bronstein S.: Temporomandibular joint: comparison of single and double contrast arthrography. *Radiology* 1987; 164:65-70.
 81. Pharaoh MJ, *Temporomandibular Joint Imaging*, 1993; 37(4):627-628.
 82. David E. Keith, *Surgery of the Temporomandibular Joint*, second edition, Blackwell Scientific publications. James V. Manzione Jr and Richard W. Katzberg, chapter 2, *diagnostic imaging of the Temporomandibular Joint* 1992; 16-25.

Peer reviewers: Wing P Chan, Professor, Department of Radiology, Wan Fang Hospital, Taipei Medical University, Taipei, Taiwan; Mona Hassan Mohammed Ali, Associate professor, Human Anatomy and Embryology, Faculty of Medicine, Suez Canal University, Ismailia, Egypt.