

Less Invasive Reconstruction of Chronic Achilles Tendon Rupture with free Semitendinosus Tendon Autograft - A case Series

Ayman M Ebied, Adel Abdel Azim Foda

Ayman M Ebied, Orthopaedic Surgery Faculty of Medicine Menofia University, Egypt

Adel Abdel Azim Foda, Lecturer of Orthopaedic Surgery Faculty of Medicine Zagazig University, Egypt

Correspondence to: Adel Abdel Azim Foda, Lectures of Orthopaedic Surgery Faculty of Medicine Zagazig University, Egypt

Email: Afoda77@gmail.com

Telephone: +00201206007522

Received: January 3, 2016 Revised: April 2, 2016

Accepted: April 6, 2016

Published online: April 13, 2016

© 2016 The Authors. Published by ACT Publishing Group Ltd.

Key words: Chronic Achilles tendon ruptures; Minimally invasive hamstring graft

Ebied AM, Foda AAA. Less Invasive Reconstruction of Chronic Achilles Tendon Rupture with free Semitendinosus Tendon Autograft-A case Series. *International Journal of Orthopaedics* 2016; 3(2): 539-543 Available from: URL: <http://www.ghrnet.org/index.php/ijo/article/view/1569>

ABSTRACT

BACKGROUND: Management of chronic Achilles Tendon (AT) ruptures is a challenge, especially in the presence of large gaps. Different methods have been described to overcome tendinous defects, however, no consensus has been reached.

MATERIALS AND METHODS: Between August 2010 and January 2013, 12 patients with chronic Achilles tendon ruptures with a gap between the ruptures ends more than 5 cm were treated with free Semitendinosus Tendon (ST) autograft through a small incision centered over the proximal stump of the Achilles tendon. The mean follow up period was 20 months. Range (14-25 months). Patients were prospectively evaluated using AOFAS score and SPSS software for statistical analysis.

RESULTS: The overall results were excellent according to the American orthopaedic foot and ankle society (AOFAS) hind foot score. There were no wound complications and all patients had better functional improvement than the pre operative condition.

CONCLUSION: Less invasive AT reconstruction with free ST autograft is successful in restoring the functional integrity of chronic AT ruptures with good functional improvement and without notable wound complications.

INTRODUCTION

Management of chronic AT rupture is controversial. Direct repair or approximation of the tendon ends is usually difficult if not impossible in many situations. Various techniques were described for reconstruction of chronic AT ruptures. To overcome the gap between the ruptured ends many techniques were described: V-Y advancement of the gastrocnemius soleus, turndown flaps, local tendon transfer as peroneus brevis or flexor hallucis tendon transfer^[1], as well as biological grafts^[2] and synthetic grafts^[3]. The commonly encountered complications of these techniques are related to wound dehiscence, weakness of the ankle plantar flexion and limited ankle dorsiflexion^[4].

In this article a technique for less invasive reconstruction using autogenous free ST graft is described and the results are reported.

MATERIAL AND METHODS

In the period between August 2010 and January 2013, 12 male patients with chronic AT ruptures had less invasive reconstruction of the AT using free autogenous ST. The mean patients' age was 39 years old, range (18 to 46). The underlying etiologies for AT rupture varied. Six patients had spontaneous AT rupture; they had a past history of previous local steroid injection. Five patients had AT

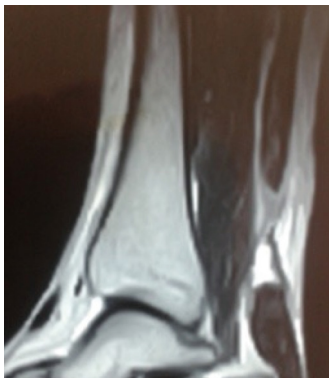

Figure 1 Pre operative MRI of one case.

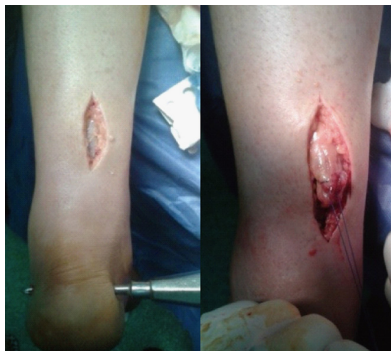

Figure 4 The tendon graft passing through the calcanean tunnel.

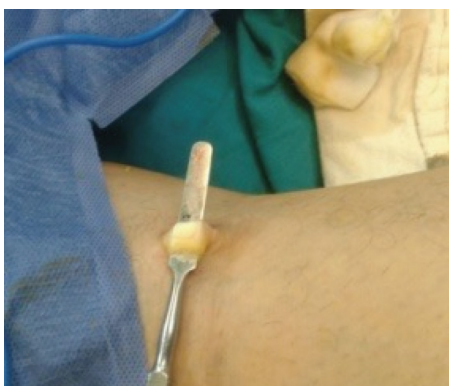

Figure 2 Semitendinosus tendon graft delivered from a mini incision.

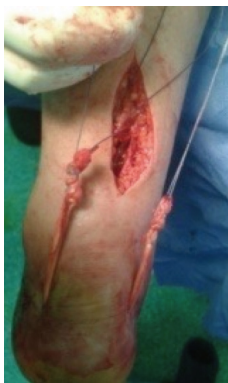

Figure 3 Incision over the proximal stump of Achilles tendon.

rupture due to direct blow to the posterior aspect to the distal part of the leg. One patient had open tendon cut by a sharp instrument and was missed for 5 months.

All patients included in this study presented after a mean period of 17 weeks from the time of AT rupture (Range 6-23 weeks). Patients included in this study had a gap at the site of AT rupture > 5 cm between the tendon ends and 4 patients were diabetic.

All patients had an abnormal gait. Weak or no foot propulsion during mid stance phase of the gait cycle, reduced planter flexion power and inability to stand on the tips of the toes with single leg heel rise were observed in all patients preoperatively. These functional deficits compromised patients' daily life activities.

The gap was felt at the site of rupture. There was a lack of ankle planterflexion when the calf was squeezed in all cases (Positive Thompson test). Measurement of calf muscle circumference was

referenced by the healthy side. The circumference of calf muscle of the healthy side at its maximum diameter was measured and the distance from this site till the head of fibula was estimated. On the injured side, calf circumference was measured at the same distance from the head of the fibula. the difference between calf circumference in both sides was considered a measure of calf muscle atrophy^[5].

MRI examination of the ruptured tendon was performed for all patients to clarify the magnitude of the defect in the tendon (Figure 1). Patients' ankle function was prospectively evaluated using the American Orthopaedic Foot and Ankle Society ankle-hindfoot score^[6] (AOFAS). Statistical analysis was performed with SPSS statistical software . Paired t test and spearman's correlation were used.

All procedures were performed under spinal anaesthesia in the prone position with tourniquet applied to the upper thigh. ST was harvested through a small transverse incision made directly over the tendon at the back of the knee^[7]. After skin incision the tendon sheath was opened longitudinally and the tendon was delivered from the wound (Figure 2). Using an open stripper the tendon was harvested then the stripper was introduced again but in reversed direction to detach the tendon from its insertion at the upper medial surface of the tibia after splitting the fascial connections between the tendon and the gastrocnmeius fascia. Fleshy muscle fibers were removed and preparation of both ends of the tendon by applying web stitches using No. 2 Ethibond sutures was performed.

A straight longitudinal incision was made slightly medial to the midline centered at the proximal stump of the AT, the end of the proximal stump was freed from adhesions and scar tissues and tied with stay sutures to facilitate approximation and traction on the tendon ends (Figure 3).

A transverse tunnel was prepared across the calcaneus close to the original AT insertion and parallel to the ankle joint line using 5 mm drill bit. The ST graft was passed through this tunnel (Figure 3, 4).

The two ends of the ST graft were then passed under the skin to run parallel to the AT and delivered proximally medial and lateral to the AT. Both ends of the ST graft were weaved through the proximal stump of the TA in opposite directions, then fixed to the AT using non-absorbable sutures (Ethibond No. 2). Each band of the ST graft was re-sutured to itself and the to the other end of the graft (Figure 5). Sutures were tied while the ankle joint was in 10 degrees of plantar flexion and slight tension of the tendon was accepted. Having fixed the ST graft the ankle joint was taken through full range of motion to ensure stability of the sutures and

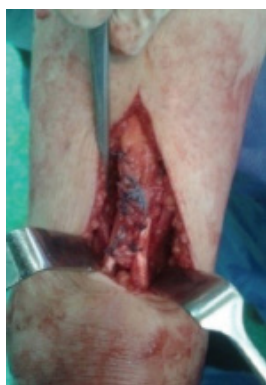

Figure 5 The graft is sutured to the proximal stump of Achilles tendon.

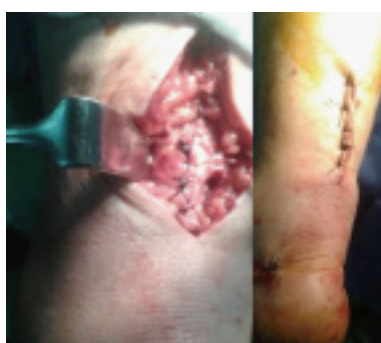

Figure 6 Achilles tendon sheath and skin is closed.

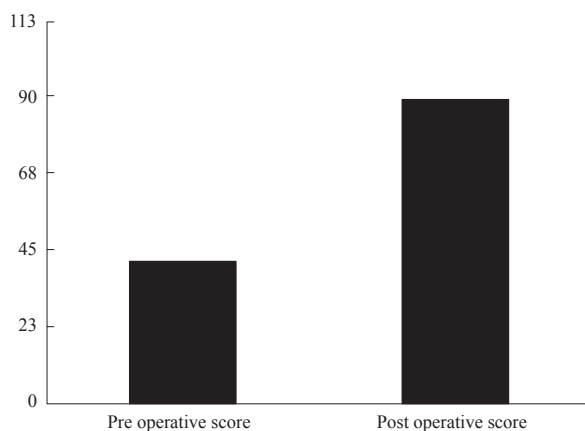


Figure 8 The mean pre and post AOFAS.

ability to regain ankle ROM postoperatively.

Soft tissues around the tendon were closed in layers from the tendon sheath to the skin (Figure 6). Below knee splint was applied with the ankle in 20 degrees of planter flexion for six weeks after that it was removed and gradual weight bearing was allowed with high heel orthosis for another 6 weeks. Prophylactic medications against venous thrombo- embolism were used in all patients. Following cast removal a rehabilitation program was carried out by specialized physical therapist for improving ROM of the ankle and leg muscle strengthening.

RESULTS

The mean follow up period was 20 months, (Range 14 - 25 months). None of the patients was lost from the follow up with a minimum follow up at 14 months postoperatively.

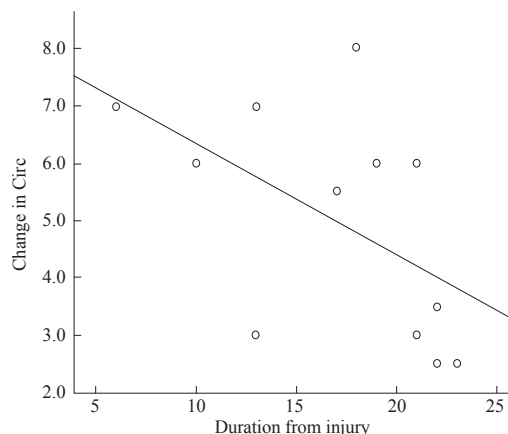


Figure 7 Relation between calf muscle circumference and duration of injury.

Table 1 Relationship between calf muscle circumference and the duration of injury.

Spearman's rho Correlation	Change in Circ		
	r	P	Sig
Duration from injury	-0.637	0.026	S

r: Correlation coefficient; P: P value; Sig: Significant.

Table 2 Comparison between pre and post calf muscle circumference.

	Calf muscle circumference		t	P value	Sig
	Pre	post			
Mean ± SD in Cm	37.5 ± 1.7	42.5 ± 3.3	-8.292	< 0.001	HS

P ≤ 0.05 = significant. P < 0.001 = highly significant.

Table 3 Comparison between pre and post AOFAS scores.

	AOFAS Score		t	P value	Sig
	pre	post			
Mean ± SD	42 ± 5.6	89 ± 5.2	-28.539	< 0.001	HS

P ≤ 0.05 = significant. P < 0.001 = highly significant.

There were considerable improvement in pain and walking distance in all patients. After six months no walking aid was used by all patients, After nine months tip toe standing with single leg heel rise on the operated side was possible in all patients.

There were still some limitations in function . Two patients (16.6%) had failed to achieve normal gait due to persistent limitation of ankle doriflexion. These two cases had less than 10° of dorsiflexion beyond the neutral position while the knee is in 90° flexion. Three patients (25%) were unable to return to original career.

Persistent calf muscle atrophy was noted in four cases (33%). The mean pre operative calf diameter was 37.5 cm (Range 35.5 - 41). The degree of atrophy was proportional to the time elapsed from the initial injury (Table 1 and Figure 7). The mean post operative calf muscle diameter was 42.5 cm (Range 38 - 47) (Table 2).

Despite of these functional limitations there was better functional improvement in all cases as compared with the pre operative condition.

The AOFAS had markedly improved as compared to the pre operative values (Table 3) . The mean Pre op score was 42 (Range: 38- 57) while the mean post operative score one year after surgery

was 89 (Range 75 - 94). (Figure 8).

There were no recorded complications related to the surgical wounds of both the graft harvesting site or over the Achilles tendon. There were no tendon re-ruptures throughout the follow up period.

DISCUSSION

The AT is the strongest tendon across the musculoskeletal system, meanwhile, the most frequently ruptured one^[8]. It is not uncommon for patients to present with chronic or neglected rupture of the AT that results in retraction or a gap between the degenerated tendon ends which makes direct repair impossible or may be achieved with an unacceptable tension at the suture line interfering with proper healing of the tendon^[9].

There is controversy in the literature on the most efficient way for reconstruction of the AT and overcoming the defect between the tendon ends. Some techniques depend on lengthening of the proximal stump to approximate the ends for direct repair with or without augmentation^[10,11] while others depend on bridging the gap between the ruptured ends^[12-14].

Open surgery with sliding V-Y flaps of the gastrocnemius soleus has been suggested. It usually results in weakness of ankle plantar flexion in addition to many other complications related to delayed wound healing or necrosis of the skin edges^[15,16]. The permanent change in the ratio between the tendon and muscle length is a major disadvantage of that technique^[17].

The tendon of flexor hallucis longus is used to bridge a large AT defect^[7] but loss of push off from the big toe is the major disadvantage of that technique^[12], other local tendon transfer techniques were described as peroneus brevis transfer^[14] however the potential weakness of eversion was observed with that technique^[15].

Similarly, turn down flap is used to reconstruct or augment repair in cases of chronic AT tendon ruptures. Many authors had successful results with that technique^[19,20], however the long incision and the extensive dissection increase the rate of postoperative wound complications^[21].

In this series a technique for less invasive reconstruction of the tendon has been presented. The advantages of this technique are the minimal soft tissue affection and the biologic reconstruction of the AT using autogenous graft. This has been reflected on the functional recovery and the minimized incidence of complication comparative to other techniques.

Less invasive approaches are particularly encouraged in presence of certain disorders that jeopardize the peripheral circulation and consequently wound healing in the lower limb like diabetes mellitus, varicose veins and peripheral ischemia. In these conditions the incidence of wound complications is higher than cases done with a less invasive approach^[22]. The less invasive technique preserves the skin integrity over the area most liable to wound breakdown so it is recommended in these conditions.

In this series the autogenous ST graft has been employed to provide a biologic filler and aid in the repair of the AT. Additionally, harvesting this tendon leads to negligible donor site morbidity^[4].

The use of ST free graft to connect the proximal AT stump with the calcaneus bypassing the Achilles tendon defect has special importance in some conditions. In cases of AT injuries close to its insertion (zone I) the distal stump would be short for direct repair. In cases of Achilles tendon rupture with pre existing tendon pathology as tendinosis where the ruptured tendon ends become unhealthy for direct repair, in this case bridging the defect and bypassing the distal stump with ST becomes more suitable.

Another preferred situation for the use of less invasive free semitendinosus grafting technique is tendon rerupture after direct repair. It is better not to re-incise the same long scar and use a less invasive approach, also the AT ends will be scarred and fibrosed and a large gap will be created after debridement interfering with direct repair.

CONCLUSION

Less invasive Achilles tendon reconstruction with free ST autograft is successful in restoring the functional integrity of the tendon in cases of chronic Achilles tendon ruptures with large defect. It can be done without wound complications and negligible donor site morbidity. This technique is particularly useful in cases of tendon re-ruptures and cases with high risk of post operative wound problems.

CONFLICT OF INTERESTS

This study was approved from the local ethical committee. The authors did not receive any outside funding or grants in support of their research for or preparation of this work. Neither they nor a member of their immediate families received payments or other benefits or a commitment or agreement to provide such benefits from a commercial entity. No commercial entity paid or directed, or agreed to pay or direct, any benefits to any research fund, foundation, division, center, clinical practice, or other charitable or nonprofit organization with which the authors, or a member of their immediate families, are affiliated or associated.

REFERENCES

1. Wong J, Barrass V, Maffulli N. Quantitative review of operative and nonoperative management of Achilles tendon ruptures. *Am J Sports Med* 2002; **30**: 565-575.
2. Sarzaeem MM, Lemraski MMB, Safdari F. Chronic Achilles tendon rupture reconstruction using a free semitendinosus tendon graft transfer. *Knee Surg Sports Traumatol Arthrosc* 2012; **20**: 1386-1391.
3. Basigliani L, Iorio R, Vadalà A, Conteduca F, Ferretti A. Achilles tendon surgical revision with synthetic augmentation. *Knee Surg Sports Traumatol Arthrosc* 2010; **18**: 644-647.
4. Molloy A, Wood EV. Complications of the treatment of Achilles tendon ruptures. *Foot Ankle Clin* 2009; **14**: 745-759.
5. Ross M, Teddy W. Thigh and Calf Girth Following Knee Injury and Surgery. *Journal of Orthopaedic & Sports Physical Therapy* 1998; **27**: 9-15.
6. Madeley NJ, Wing KJ, Topliss C, Penner MJ, Glazebrook MA, Younger AS. Responsiveness and validity of the SF-36, Ankle Osteoarthritis Scale, AOFAS Ankle Hindfoot Score, and Foot Function Index in end stage ankle arthritis. *Foot Ankle Int* 2012; **33**: 57-63.
7. Trent J, Wilson and James H. Lubowitz: Minimally Invasive Posterior Hamstring Harvest. *Arthrosc Tech* 2013; **2**: e299-e301.
8. Maffulli N, Oliva F, Ronga M; Percutaneous Repair of Acute Achilles Tendon Ruptures. The Maffulli Procedure ; Minimally Invasive Surgery for Achilles Tendon Disorders in Clinical Practice 2013. London: Springer-Verlag, 2013.
9. Takao M, Ochi M, Naito K, Uchio Y, Matsusaki M, Oae K. Repair of neglected Achilles tendon rupture using gastrocnemius fascial flaps. *Arch Orthop Trauma Surg* 2003; **123**: 471-474.
10. Elias I, Besser M, Nazarian LN, Raikin SM. Reconstruction for missed or neglected Achilles tendon rupture with V-Y lengthening and flexor hallucis longus tendon transfer through one incision.

- Foot Ankle Int* 2007; **28**: 1238-1248.
11. Bevilacqua NJ. Treatment of the neglected Achilles tendon rupture. *Clin Podiatr Med Surg* 2012; **29**: 291-299
 12. Wapner KL, Hecht PJ, Mills RH Jr. Reconstruction of neglected Achilles tendon injury. *Orthop Clin North Am* 1995; **26**: 249-263.
 13. Maffulli N. The clinical diagnosis of subcutaneous tear of the Achilles tendon: A prospective study in 174 patients. *Am J Sports Med* 1998; **26**: 266-270.
 14. Perez-Teuffer A. Traumatic rupture of the Achilles tendon: Reconstruction by transplant and graft using the lateral peroneus brevis. *Orthop Clin North Am* 1974; **5**: 89-93.
 15. Kissel C; Blackledge D, Crowley D. Repair of neglected Achilles tendon ruptures , procedure and functional results. *J Foot Ankle Surg* 1994; **3**: 46-52.
 16. Maffulli N, Ajis A. Management of chronic ruptures of the Achilles tendon. *J Bone Joint Surg Am* 2008; **90**: 1348-1360.
 17. Leitner A, Voigt C, Rahmzadeh R: Treatment of extensive aseptic defects in old Achilles tendon ruptures: methods and case reports. *Foot Ankle* 1992; **13**: 176-180.
 18. Pintore E, Barra V, Pintore R, Maffulli N. Peroneus brevis tendon transfer in neglected tears of the Achilles tendon. *J Trauma* 2001; **50**: 71-78.
 19. Christensen I. Rupture of the Achilles tendon: Analysis of 57 cases. *Acta Chir Scand* 1953; **106**: 50-60.
 20. Rush JH. Operative repair of neglected rupture of the tendoachillis. *Aust NZ J Surg* 1980; **50**: 420-422.
 21. Garabito A, Miranda JM, Sotelo JS. Augmented repair of acute Achilles tendon ruptures using gastrosoleus-soleus fascia. *Int Orthop* 2005; **29**: 42-46.
 22. Maffulli N, Loppiniz M, Longo UG, Gayle D, Maffulli BA, Denaro V. Minimally Invasive Reconstruction of Chronic Achilles tendon Ruptures Using the Ipsilateral Free Semitendinosus Tendon Graft and Interference Screw Fixation. *The American Journal of Sports Medicine* 2013; **41**: 5.
- Peer reviewer:** Heinz Lohrer, Sportmedizinisches Institut Frankfurt am Main, Otto-Fleck-Schneise 10, D-60528 Frankfurt, Germany.