

Modern Techniques in Knee Arthrodesis

Kelvin Kim, Nimrod Snir, Ran Schwarzkopf

Kelvin Kim, Penn State College of Medicine, Hershey, PA, United States

Nimrod Snir, Division of Orthopaedic Surgery, Tel-Aviv Sourasky Medical Center, Tel-Aviv University, Tel-Aviv, Israel

Ran Schwarzkopf, Department of Orthopaedic Surgery, Division of Adult Reconstruction, NYU Hospital for Joint Diseases, NYU Langon Medical Center, New York, NY, United States

Correspondence to: Ran Schwarzkopf, Assistant Professor, Division of Adult Reconstruction, NYU Hospital for Joint Diseases, NYU Langon Medical Center, New York, NY, 212-5987200, United States

Email: schwarzk@gmail.com

Telephone: +1-212-513-7711 Fax: +1-212-598-6000

Received: July 16, 2015 Revised: January 1, 2016

Accepted: January 9, 2016

Published online: February 23, 2016

Kim K, Snir N, Schwarzkopf R. Modern Techniques in Knee Arthrodesis. *International Journal of Orthopaedics* 2016; 3(1): 487-496 Available from: URL: <http://www.ghrnet.org/index.php/ijo/article/view/1620>

INTRODUCTION

In the circumstances that revision arthroplasty can no longer serve as a viable option to treat complications of total knee arthroplasty (TKA), knee arthrodesis serves as an acceptable option for salvage treatment. Once used as the main option for treatment of septic arthritis, tuberculosis, and poliomyelitis back when the procedure was introduced in the late 19th and early 20th century^[1,2], today, the most common indications for knee arthrodesis are failed TKAs - mainly in cases of knee extensor mechanism loss, persistent infection, an immune compromised patient, poor soft tissue coverage of the knee, or severe bone loss and instability^[1,3-5]. Due to data suggesting that the need for revision TKA will increase substantially in the decades to come, an increase in knee arthrodesis procedures is likely to follow^[6].

As a whole, when compared to above the knee amputations, which serves as the other major, alternative salvage treatment option for a failed TKA, arthrodesis is the preferred procedure^[5]. Knee arthrodesis is known to have its advantages, namely in regards to improved pain relief, decreased need for future surgery, preferred cosmetic appearance, and improved ambulation and energy efficiency, compared to above the knee amputation^[7,8]. When comparing between the various arthrodesis techniques available, each presents with its own set of advantages and disadvantages, as well as technique-specifics that cater to the unique condition of each patient. The most common methods of arthrodesis today include use of intramedullary nails (IM nails), external fixation, and compression plates^[1,3,4]. Intramedullary nails include two forms, long or short, while external fixation involves one of the following: a monoplanar fixation device, a biplanar fixation device, or the use of circular frames^[1,3]. This article is aimed to review recent findings of the outcomes, indications, and complications of these different techniques of knee arthrodesis as a salvage procedure for failed TKA, as well as its technical aspects, advantages, and disadvantages.

ABSTRACT

Knee arthrodesis serves as an option of salvage treatment for failed total knee arthroplasty procedures. Multiple different arthrodesis techniques exist that cater to the specific presentation of the failed total knee arthroplasty, the three most common techniques being intramedullary nails, external fixation, and compression plates. This review aims to present recent findings of knee arthrodesis procedures regarding the indications, outcomes, and prognostic factors as well as a general description of the technical aspects, advantages, and disadvantages of each specific knee arthrodesis technique. Data was collected and compared between the individual techniques based on fusion rate, average time to fusion, average complication rate, types of complications, average postoperative recurrent infection rate, and average leg length discrepancy. Finally, the author's preferred technique based on clinical experience is presented.

© 2016 ACT. All rights reserved.

Key words: Knee arthrodesis; Total knee arthroplasty; Periprosthetic joint infection; Adult reconstructive surgery; Geriatric medicine; Salvage procedure; Revision total knee arthroplasty

INDICATIONS FOR EACH TECHNIQUE

Deciding which specific arthrodesis technique to use, whether IM nail, external fixation, or compression plates, can be based on three main variables: infection state, condition of the soft tissue envelope, and preoperative bone loss^[8,9]. No definitive indications for treatment have been established, and much of the decision-making process as to which technique to treat a patient lies in the judgment of the surgeon. However, a review of the recent literature provides some direction in determining which specific technique should be considered given a patient's presentation in regards to the three variables mentioned above.

Of the three main techniques, the majority of recent studies have looked into the use of external fixation devices and IM nails when recurrent infection was the main indication for the procedure. Results have generally showed favorable outcomes for these two main techniques, although, there has been a wide range of variance (Table 1). The lesser studied of the three, compression plates, have shown to have comparable, if not better, fusion rates compared to external fixators as well as increased structural comfort. However, data surrounding the efficacy of compression plates is sparse relative to external fixation devices and IM nails in the presence of infection. In addition, typical to internal fixation devices in general, higher rates of deep infection have been reported. For these reasons, external fixation and IM nails may be more reliable options in cases involving an infectious state^[5].

The condition of the soft tissue envelope at the time of arthrodesis serves as another factor that can help determine which technique is indicated. In general, with increasing soft tissue compromise around the knee, the use of external fixation over IM nails seems to be a favorable option, which, in general, helps avoid hardware exposure and decreases risk of deep infection. As Kuchinad *et al* points out, external fixation, specifically through Ilizarov circular frames, provides the option to gradually shorten the femorotibial gap. This gradual process allows for better wound closure in the presence of

severe soft tissue defects that may inhibit acute wound approximation and primary closure. The ability to gradually shorten the bone-to-bone gap is an important advantage of external fixation over IM nails and compression plates^[9].

In regards to patients who present with severe bony defects, IM nailing serves as a reliable treatment option. As evidenced in a recent study by Van Rensch *et al* assessing the effects that the severity of bony defects has on arthrodesis outcomes, IM nailing showed comparable fusion rates (compared to previously published series) despite the majority of patients presenting with type III bony defects (according to the Anderson classification)^[8]. Different variations of treatment have been proposed to overcome extensive bone loss including the possibility of lengthening the bone using a circular frame, the use of bone grafts with IM nails, or newer modular IM nail techniques that do not require bone-to-bone contact^[1,9,10]. All of these stand as possible options when dealing with severe bony defects and are techniques that certainly should be further evaluated. Presently, there are only a few other studies in the literature specifically evaluating the effects that bony defects have on knee fusion outcomes between the different arthrodesis techniques.

A simple algorithm is presented to provide guidance in choosing an arthrodesis technique based on the advantages and challenges of each technique mentioned above (Figure 1).

PROGNOSTIC FACTORS

A successful knee arthrodesis procedure is commonly evaluated based on a number of factors including: high rate of union, a straightforward surgical technique, low rate of complications, minimal inpatient stay, the allowance of ambulation and weight-bearing, minimal post-operative follow-up treatment, and need for reoperation^[4,11-13]. The individualized condition of the knee that a patient initially presents with, as well as specific aspects of pre-, intra-, and postoperative stages, have been studied in their relationship to the rate of success, as measured by different variations of the aforementioned criteria.

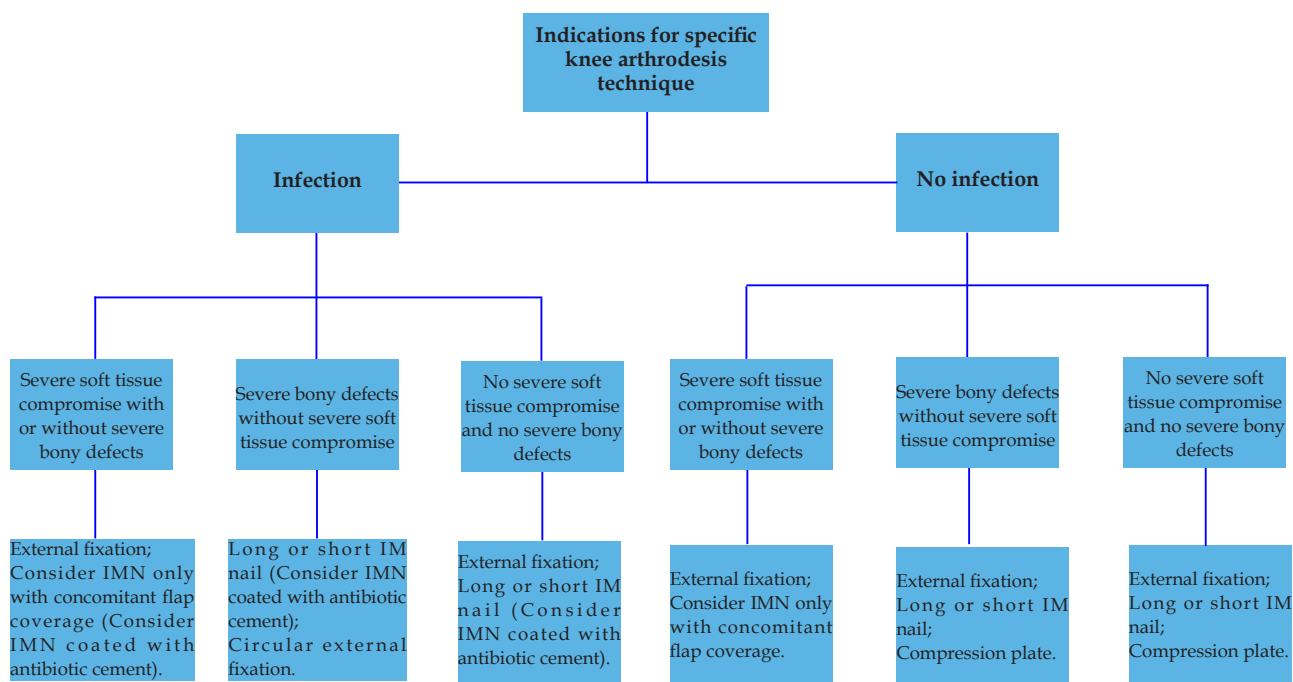


Figure 1 Decision tree for specific knee arthrodesis techniques in different clinical indications.

Schwarzkopf *et al* examined 43 consecutive arthrodesis procedures and found that the key factors predicting a successful surgical outcome included reduced wound healing complications, reduced number of days to discharge after arthrodesis (6.57 vs 10 days), and lower final inflammatory marker values (for patients with a history of periprosthetic infection) before arthrodesis (ESR of 49.4 vs 70.1). In the study, success was defined as a lack of further surgery, successful bony fusion, and successful eradication of infection (for patients with a history of periprosthetic infection) while a failed procedure was defined as one that required further surgery, chronic antibiotics, or unsuccessful bony fusion. Other significant variables that did not have any influence on success rates included gender, wound healing complications, history of other replaced joints, history of other periprosthetic joint infections, presence of other joints with osteoarthritis at the time of knee fusion, knee joint infection at time of arthrodesis, whether a bone graft was used, patients with at least partial weight-bearing at discharge, and an intact extensor mechanism at time of arthrodesis^[4].

Lee *et al* found that in patients who underwent arthrodesis procedures using both short and long Huckstep (Downs Surgical, Sheffield, UK) modular IM nails, there was no correlation between the time to union and certain preoperative and intraoperative variables including: initial diagnosis, number of co-morbid medical diseases, number of surgical procedures prior to arthrodesis, total duration from the time the infection was diagnosed to arthrodesis, interval from last prior surgery to arthrodesis, type of prosthesis, and the shortest length of bone defect^[4].

Finally, evidence suggests that increased bony defects are correlated with lower fusion rates^[8,15]. Parcel *et al* observed that in patients with type III AORI classified bony deficiency in both the femoral and tibial aspects, lower fusion rates occurred when treated with modular nails^[16]. Similarly, Van Rensch reported a decrease in fusion rates among multiple techniques of arthrodesis when there was only $\frac{3}{4}$ - $\frac{1}{4}$ femorotibial surface contact immediately following arthrodesis versus surface contact of greater than $\frac{3}{4}$ ^[8].

INTRAMEDULLARY NAILS

Long Intramedullary Nail

The long intramedullary nail arthrodesis procedure is performed from a standard knee arthroplasty approach. In the case of a current periprosthetic TKA infection a 2-stage procedure is recommended. The first stage should include complete debridement of all infected tissue, irrigation, and explantation of implants when present, followed by antibiotic spacer placement and appropriate IV antibiotic treatment. After eradication of the infection (when possible) a second stage procedure with arthrodesis should be performed. Refreshing the distal femur and proximal tibia surfaces is recommended in order to increase the contact area and rotational stability at the site of arthrodesis, as a stable osseous contact area plays an important role in achieving fusion^[1,17,18] (Figure 2a-c). Typically, the femoral and tibial surfaces are recut to create a more parallel plane of contact, however, reaming the surfaces to create a ball-and-socket contact surface has also been supported in order to increase stability at the fusion site^[18]. The IM nail is inserted in an anterograde fashion through the piriformis fossa, similar to a femoral nail, while the distal aspect of the nail should sit close to the tibial plafond, similar to a tibial intramedullary nail^[1,18,19]. When bony defects are severe, allograft and autograft bone grafts or a metal or polyethylene spacer are different options available to help minimize leg length discrepancy (LLD) with both short and long IM

nails^[1,4,14,20]. The disadvantage of this option is a decrease in rate and strength of the bony fusion site.

The long IM nail has shown to have higher rates of fusion and better functionality based on Lequesne Algofunctional Score (LAS) values versus external fixation devices, while Knee Society functional scores were similar for both techniques^[3,4,7,10,21]. Additionally for long IMNs, when compared to modular shorter nails, extraction, when needed, was proven to be easier, faster, and cause less bone damage, and did not require taking down the fusion site like in modular nails^[22,23]. However, higher rates of persistent infection have been identified in this technique and other intramedullary procedures^[4,18,20].

Recently, Schwarzkopf *et al*, demonstrated an 81.5% (22 of 27 patients) fusion rate using a long IM nail, which was comparable to fusion rates reported in recent studies (88.9%-100%)^[4,10,17,18,21,24] (Table 1). The 40% complication rate recorded was in line with these studies as well and included 4 cases of infection, 1 with chronic pain, and 1 needing repeat arthrodesis due to nonunion using another IM nail^[4,17,21].

Leroux *et al* retrospectively evaluated 17 patients who underwent a unilateral two-stage knee arthrodesis with a long titanium intramedullary nail and autologous bone grafting. Fusion was achieved in 16 (94.1%) patients and the mean fusion time of 5 months was comparable to past studies^[18,24] (Table 1). 15 out of the 17 patients were satisfied with the procedure, all of which were consistent with similar values in modular nail studies. One or more complications were seen in 7 patients and mean limb shortening was measured at 27.6 mm^[17].

In another recent study by Iacono *et al*, 22 consecutive patients were treated and followed up for a mean of 34.4 months. 3 patients were noted for reinfection during this time and an average leg length discrepancy was reported at 8 mm, which was much shorter than past LLD findings (28-55 mm)^[10,17,18,21,24] (Table 1). The LAS index was 11.2 while 12 patients (66.7%) were very satisfied with the outcome, 5 patients (27.7%) were fairly satisfied, and 1 patient (5.6%) was very unsatisfied^[10].

Short Intramedullary Nail

An arthrodesis procedure, using the short modular nail method, consists of two shorter nails that insert at the isthmuses of the femur and tibia in a retrograde and anterograde fashion respectively. Prior to insertion, in the case that the knee has a history of infection, the knee is debrided and treated with antibiotics in a similar fashion to the long intramedullary procedure, as explained in the previous section. For patients with failed TKA, opposing surfaces of the femur and tibia are recut to provide parallel surfaces, in order to increase potential surface area for fusion, before the nail components are inserted. Following insertion, the two nails are then joined using one of a number of interlocking mechanisms, depending on the specific manufacturer and type of nail used^[25].

The advantages of this procedure include minimization of leg length discrepancy, the ability to immediately bear weight on the leg despite severe bone loss, avoidance of pin-track infections, and the use of multiple interlocking screws, which may enhance the vertical and rotational stability of the knee and ultimately improve fusion rate^[13,14,20,22,26-28]. Carrying out a knee arthrodesis, using a modular nail, is not a demanding procedure and in one study, which analyzed the effects of a Wichita Fusion Nail (Stryker Orthopedics, Mahwah, New Jersey, USA) there were no differences in fusion rates between surgeons who were performing the surgery for the first time and those who were more experienced^[29]. However, it has been noted that there have been higher levels of blood loss during modular nail procedures as well as a longer operating time compared to other methods^[30,31].

Table 1 Outcomes of various arthrodesis techniques.								
Technique	Study	# of cases	Fusion rate	Mean time to fusion	Complication rate	Complication	Postop persistent/recurrent infection rate	Avg. postop ILLD
Long IM nail								
	Schwarzkopf et al, 2014[4]	27	22/27 (81.5%)	-	12/30 (40%)	infection (8); soft tissue compromise (3); intermittent knee swelling (1); pulmonary embolism (1); pseudoarthrosis (1);	8/30 (26.7%)	-
	B. Leroux et al, 2013[17]	17	16/17 (94.1%)	5 months	7/17 (41.2%)	intra-operative factors (2); fibular nerve palsy (2); post-operative hematoma (6); recurrent infection (1)	1/17 (5.9%)	27.6 mm
	Iacono et al, 2013[10]	22	-	-	-	-	3/22 (13.6%)	8 mm
	Bargiotas et al, 2006[18]	12	12/12 (100%)	5.5 months	-	-	1/7 (14.3%)	55 mm
	Panagiotopoulos et al, 2006[24]	9	8/9 (88.9%)	6.5 months	-	-	-	30 mm
	Crockarell and Mihalko, 2005[21]	14	14/14 (100%)	-	6/14 (42.9%)	painful hardware (4); trochanteric bursitis (1); deep infection (1)	1/14 (7.7%)	37 mm
Short IM nail								
	Rohner et al, 2014[13]	16	-	-	-	-	4/16 (25%)	-
	Van Rensch et al, 2014[8]	10	8/10 (80%)	-	-	-	-	-
	Parcel et al, 2013[16]	28	23/28 (82.1%)	4.8 months	-	infection with hardware failure (1); liposarcoma (1); failed free flap revision (1); dissociation of the central compression screw (2); arterial injury necessitating emergent vascular bypass (1); temporary peroneal nerve palsy following revision of a dissociated compression screw (1)	-	-
	Putman et al, 2012[20]	31	21/31 (67.7%) 19/23 (82.6%) with grafting	-	-	-	6/31 (19.4%)	10 mm
	Neuerburg et al, 2012[22]	22	-	-	5/22 (22.7%)	recurrent infection (3); soft tissue-related (2)	3/22 (13.6%)	15 mm
	Bartlett et al, 2011[33]	10	-	-	3/10 (30%)	prosthetic fracture (1); persistent discharge sinus (1); recurrent infection (1); wound dehiscence (1); revision (1)	1/10 (10%)	-
	Letartre et al, 2009[28]	19	13/19 (68.4%)	5.2 months	5/19 (26.3%)	break of the proximal end of femoral nail (1); excessive external tibial rotation secondary to technical error (1); delayed healing, 1 required medial gastrocnemius flap (2); severe residual pain leading to revision (1)	0/19 (0%)	12 mm
	Yeoh et al, 2008[12]	11	10/11 (90.9%)	4.4 months	9/11 (81.8%)	post-op infection (5); chronic ulcers related to infection (3); bleeding post-op (2); cellulitis (1); revision (1)	5/11 (45.5%)	-
	McQueen et al, 2006[29]	44	44/44 (100%)	3.6 months	5/44 (11.4%)	deep infection (3); periimplant fracture (2); delayed unions (6)	-	-
	Christie et al, 2003[32]	53	51/53 (96.2%)	3.1 months	-	-	-	-
Unspecified IM method (Short and/or long)								
	Rohner et al, 2015[34]	26	-	-	-	-	13/26 (50%)	-
	Kuchinad et al, 2014[9]	5	5/5 (100%)	-	-	-	0%	60 mm
	Lee S et al, 2012[14]	8	8/8 (100%)	9.9 months	0/8 (0%)	-	0%	10.9 mm
	De Vil et al, 2008[27]	19	14/19 (73.7%)	-	8/19 (42.1%)	inadequate soft tissue coverage (3) chronic infection (4); aseptic nonunion (1)	4/19 (21.1%)	-
	Mabry et al, 2007[51]	24	23/24 (95.8%)	5.7 months	9/24 (37.5%)	delayed unions (6); recurrent infection at arthrodesis site (2); infection at distal locking screw site (1)	2/24 (8.3%)	-
Monoplanar external fixation								
	Corona et al, 2013[35]	21	17/21 (81.0%)	10.3 months	-	-	3/21 (14.3%)	47 mm
	Watanabe et al, 2013[38]	8	7/8 (87.5%)	-	-	-	1/8 (12.5%)	54 mm
	Van Rensch et al, 2014[8]	10	3/10 (30%)	-	-	-	-	-
	Yeoh et al, 2008[12]	7	2/7 (28.6%)	4.3 months	7/7 (100%)	continuing infections (4); postop hemorrhage (1); recurrent cellulitis (1); malunion (1)	4/7 (57.1%)	-
Biplanar external fixation								
	Iacono et al, 2013[10]	12	9/10 (90%)	5.6 months	-	-	0%	45 mm
	Riouallon et al, 2009[40]	6	6/6 (100%)	3.5 months	3/6 (50%)	hematoma (1); supracondylar fracture (1); osteitis (1)	0%	-
	Parratte et al, 2007[41]	18	16/18 (88.9%)	5 months	-	-	0%	-
Circular frames								
	Kuchinad et al, 2014[9]	16	15/16 (93.8%)	-	-	-	3/16 (18.8%)	38.8 mm
	Raskolnikov et al, 2013[42]	7	5/7 (71.4%)	8.4 months	5/7 (71.4%)	infection at site of pin tracks (5); antibiotics induced acute renal failure (1); wound breakdown requiring flap closure (1)	0%	-
	Reddy et al, 2011[44]	16	15/16 (93.8%)	6.5 months	1/16 (6.25%)	nonunion (1)	1/16 (6.25%)	45.3 mm
	Spina M et al, 2010[43]	17	13/17 (76.5%)	9.3 months	4/17 (23.5%)	intolerance to external fixation device that led to removal (2); septic intra-articular nonunion (2)	2/17 (11.8%)	28 mm
	Oostenbroek and van Roermund, 2001[47]	15	14/15 (93.3%)	11.7 months	8/15 (53.3%)	-	0%	40 mm
Combination of Different External Fixation Techniques								
	Mabry et al, 2007[51]	61	41/61 (67.2%)	5.2 months	25/61 (41.0%)	pin site infection (13); delayed unions (6); fracture through pin sites (5); deep infections (3)	3/61 (4.9%)	-
	Schwarzkopf et al, 2014[4]	9	7/9 (77.8%)	-	40%	-	-	-
	Van Rensch et al, 2014[8]	6	3/6 (50%)	-	-	-	-	-
	Kuo et al, 2005[50]	3	3/3 (100%)	-	-	-	-	-
	Pritchett et al, 1988[48]	26	26/26 (100%)	-	-	-	-	-

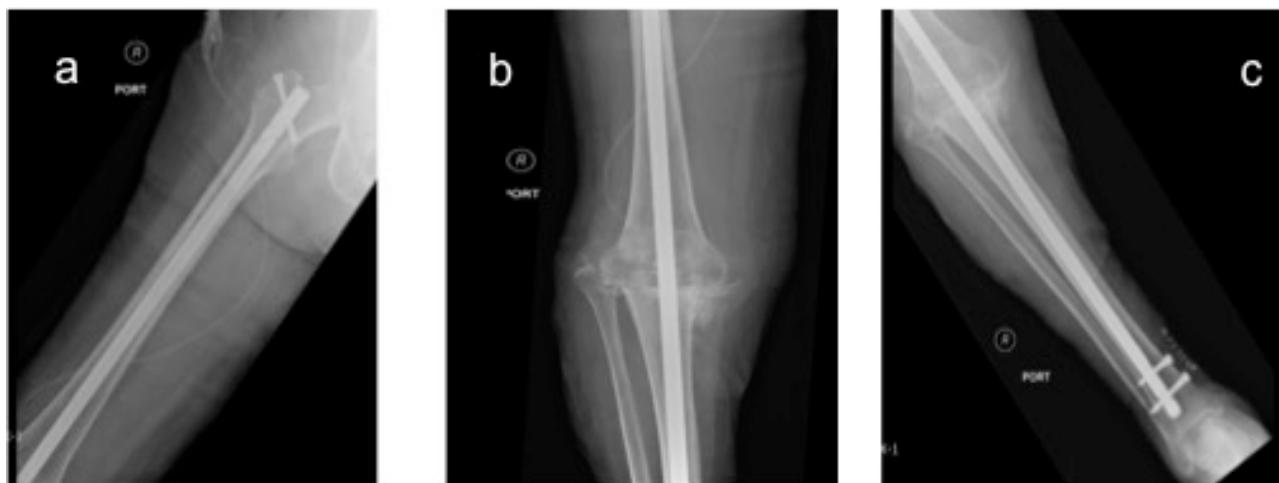


Figure 2 Long intramedullary nail technique for knee fusion following failed TKA.

In one recent study by Parcel TW *et al*, 28 patients who underwent arthrodesis using a Wichita Fusion Nail (Stryker Orthopaedics, Runnemede, New Jersey, USA), achieved fusion at a rate of 82% in a mean of 4.8 months, similar to reported rates from other recent studies (67.7%-100%; 3.1 months – 5.2 months)^[8,12,16,28,29,32] (Table 1). In 2012, Neuerburg *et al* reported outcomes of 22 patients with an average of 3.4 year follow-up who underwent arthrodesis using a cemented IM nail (Implantcast, Buxtehude, Germany). They noted an average leg length discrepancy of 15 mm (+/- 15 mm), 3 recurrent cases of infection, and 2 minor complications. The average SF-36 score for physical function was 21.8, an inferior score when compared to other arthrodesis procedures as well as TKA and transfemoral amputation^[22].

Bartlett *et al* retrospectively analyzed 10 patients who underwent a custom-made cemented Stanmore (Stanmore Implants Worldwide, Middlesex, UK) arthrodesis procedure, 9 of 10 having undergone previous yet unsuccessful attempts to eradicate their knee infection. They found that the average operative time for the procedure lasted 141 minutes and the mean estimated blood loss was 753 mL, which was comparable to revision TKA. Over a mean follow-up period of 56.4 months, a 30% complication rate was noted (range of 11.4%-81.8% from past studies) (Table 1) and a 90% (9 of 10 patients) survivorship of the arthrodesis was recorded with no evidence of residual infection or prosthesis failure^[12,22,28,29,33]. One out of the ten patients experienced a recurrent infection which fell in the range of persistent or recurrent infection rates (0-45.5%) seen in past studies^[12,13,20,22,28,33] (Table 1).

Putman S. *et al* studied 31 patients with an infected TKA who underwent a customized dual-component arthrodesis (Link Endo-Model, Boves, France), 6 of whom underwent a single-stage procedure and 25 who underwent a two-stage. Over a mean follow-up of 50 months, no reports of mechanical failure were made, while 6 failures due to infection were reported. The fusion rate was 67% (21 of 31 patients) overall, with 19 (82.6%) of those who underwent additional grafting achieving fusion. One objective of the study was to determine satisfaction rates following the arthrodesis. The main sources of patient dissatisfaction were attributed to leg length discrepancy from the procedure as well as stiffness in the knee^[20].

Other recent works, using IM devices, have looked into the utility of the Huckstep IM nails (Downs Surgical, Sheffield, UK), which come in both a short and long nail form. Analysis of 8 patients who

were managed by either a short or long Huckstep nail arthrodesis, by Lee *et al*, found that union was achieved in all patients within an average of 9.9 months and mean postoperative limb shortening was 11mm when compared to the contralateral knee. After an average of 52.1 months of follow-up, no additional revisions were required, and no recurrent infections, wound issues, or irritation at the site of the proximal end of the long nail was noted^[14].

A study by Rohner *et al* found that out of 26 patients who had undergone a two-stage intramedullary nail arthrodesis due to septic failure of several revision TKAs, 13 patients (50%) developed recurrent infections. This was the highest rate of all the studies investigating intramedullary nails reported in this review^[34].

EXTERNAL FIXATION

Monoplanar fixation

This procedure uses compression at the site of arthrodesis through an external frame along a singular plane and is secured by multiple pins along the frame. The frame is placed based on the position of the skin incision, which is done either anterolaterally or anteromedially^[3,35]. Although compression and bending stiffness is adequate along these planes, there have been reports of reduced stability along the mediolateral aspect^[3,36,37].

Corona *et al* retrospectively evaluated 21 patients who underwent a monolateral external fixation (EF) procedure due to failed septic TKA, and noted a fusion rate of 81.0% (17 of 21 patients) over a mean of 10.3 months, and an average leg length discrepancy of 47 mm. Although LLD was comparable to another recent study, the wide range of fusion rates reported in the literature, regarding the use of a monolateral external fixator, makes it difficult to accurately assess how this study compares, to other techniques, in this aspect (range of 28.6%-87.5%)^[8,12,38] (Table 1). Those who did and did not achieve fusion differed significantly in regards to their pain score as well as their satisfaction rates (82% vs 75% respectively)^[35]. Watanabe *et al* found a similar fusion rate of 87.5% in 8 patients who underwent monolateral external fixation following an infected TKA. Of note was that based on the Japanese Knee Osteoarthritis Measurement score (JKOM), which measures patient outcomes and quality of life, results were comparable to scores of patients who underwent a primary TKA^[38].

Biplanar fixators

Biplanar fixators add the mediolateral support that is not present in monoplanar frames. This is achieved by providing additional support through the use of fixation in two planes, which are secured by transfixation pins in the tibia and femur along with Schanz pins that secure the arthrodesis anteriorly (Figure 3a, b)^[3,39].

Riouallon *et al* reported on 6 patients, who underwent arthrodesis with cross-pinning by two Steinman pins followed by a sagittal external fixator frame, and showed 100% fusion rate at a mean of 3.5 months. None of the cases required reintervention and there was no evidence of recurrent infection over an 8.2-year follow-up. 3 of 6 patients experienced complications including a hematoma, a supracondylar femur fracture, which was treated surgically, and one patient with osteitis. Neither deep infection nor recurrent infection were noted in any of the patients, which was on par with other past studies^[10,40,41] (Table 1).

In Iacono *et al*'s study comparing IM nailing and external fixation using a Hoffmann II (Stryker, Selzach, Switzerland) frame, 9 of 10 patients achieved fusion at an average of 5.6 months, and a 45 mm leg length discrepancy was observed among those treated with external fixation. LAS scores improved in both the IM and EF groups although a substantial increase was noted in the IM group. There was no evidence of reinfection in any of the EF subjects^[10] (Table 1).

Circular frames

Two examples of circular frames include the Taylor Spatial Frame (TSF) (Smith & Nephew, Memphis, TN, USA) and the Ilizarov frame. In the TSF model, two carbon fiber rings are placed at the distal end of the femur and at the proximal aspect of the tibia. The rings are stabilized to the bone by pins while multiple telescoping struts anchor the frames to each other^[42]. The Ilizarov external

fixator uses a slightly different approach with the use of both rings and arches to stabilize the femur and tibia. The rings and arches are anchored to the bone using multiple pins and Ilizarov wires and rods are used between the rings and arches^[43] (Figure 4a, b).

The advantage of the circular frames include cost effectiveness, versatility, the ability to restore severe leg length discrepancy, lower deep infection rates, and the ability to make spatial adjustments without any additional surgical procedures, such as changing the axis of compression. However, the labor of maintaining the frame, cosmetic discomfort, less predictable fusion rates, frequent pin-site infections, and long treatment times, stand as a few of the procedure's shortcomings^[42-46].

Kuchinad *et al*, in their study of 16 patients who underwent a knee arthrodesis using an Ilizarov frame, achieved fusion at a rate of 93.8% (15 of 16 patients) with an average leg length discrepancy of 38.8 mm, both values being consistent with previous studies (71.4%-93.8%; 28-45.3 mm respectively)^[42-44, 47] (Table 1). 3 patients developed post-fusion infection, 2 patients underwent amputations secondary to an intractable wound issue, and 1 patient developed an acute vascular emboli. Almost all patients developed a well-controlled superficial pin-site infection during the course of treatment. It was also noted that compared to other techniques, shortening the gap caused by massive bone loss, after removal of a previous knee revision system, was best achieved with the Ilizarov external fixation method^[9].

In another study, by Spina *et al*, which assessed the utility of Ilizarov external fixators, 13 of 17 patients achieved fusion in an average time of 9.3 months. This study noted that over a mean 30-month follow-up, four complications were observed (23.5%) including two patients who experienced early removal of the external fixation device due to intolerance and the other two patients who had a septic intraarticular nonunion^[43].

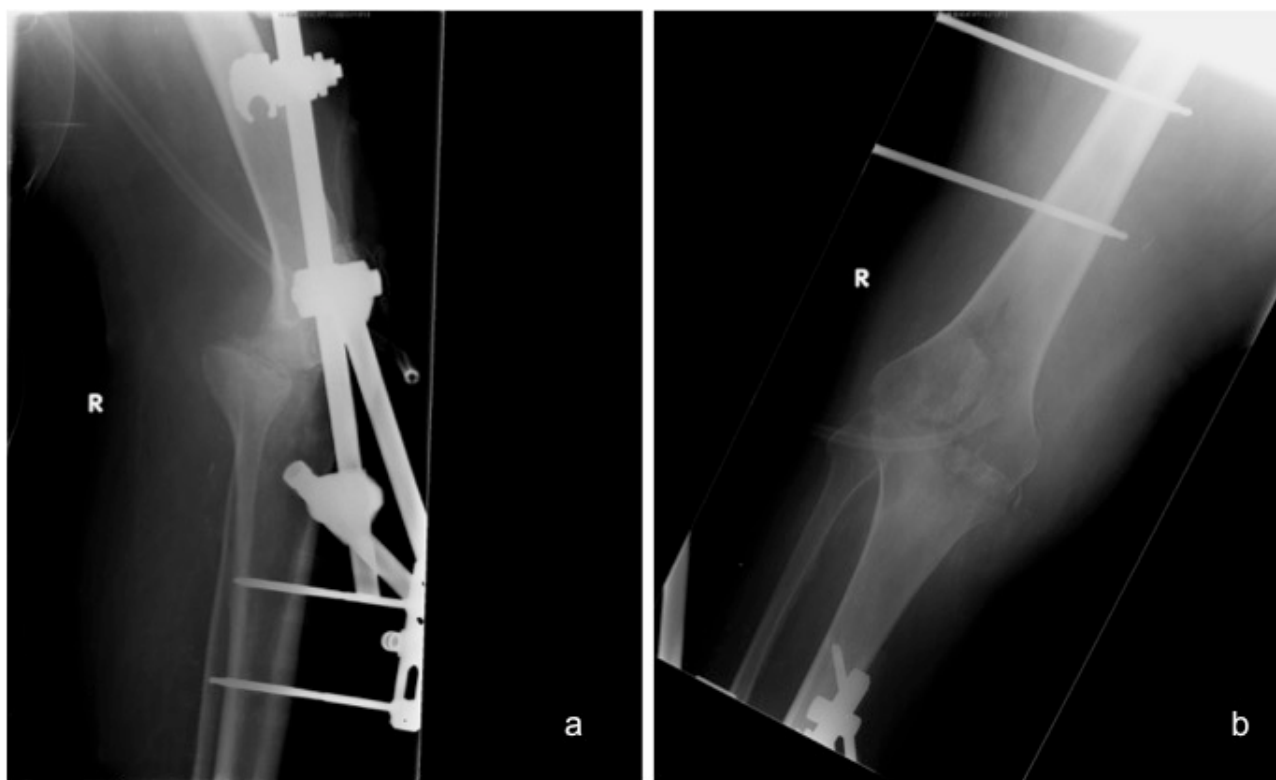


Figure 3 Uniplanar external fixation technique for knee fusion after failed TKA.

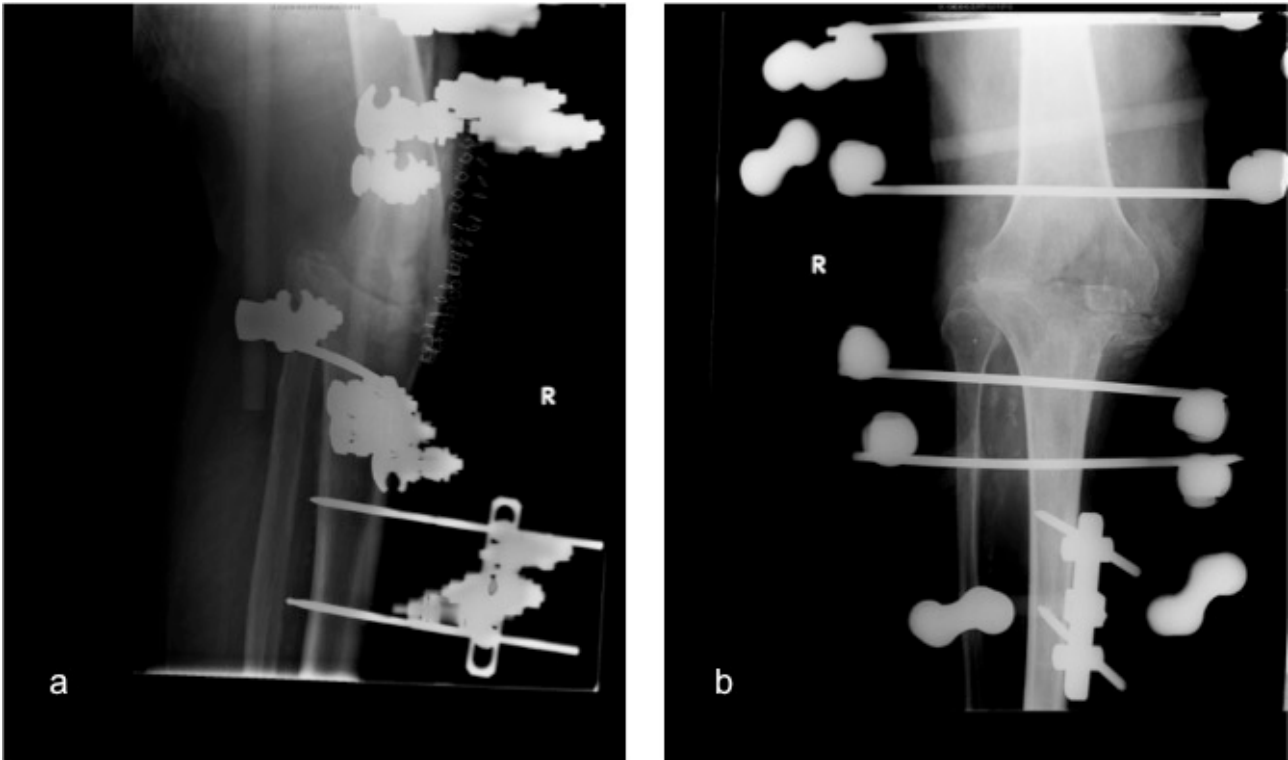


Figure 4 Ilizarov external fixation technique for knee fusion after failed TKA.

Raskolnikov D *et al* retrospectively evaluated the outcomes of patients who had a 6-axis circular external TSF (Smith & Nephew, Memphis, TN) used for knee fusion. Surgical time was reported at an average of 222 minutes per procedure. 5 of 7 patients (71%) achieved union at an average of 8.4 months after surgery. Over a 20.8-month follow-up, complications occurred in 5 of 7 (71%) patients including pin track infection in 5 patients, antibiotic-induced acute renal failure, wound breakdown requiring flap closure, and femur fracture secondary to a fall^[42].

COMPRESSION PLATES

Compression plates involve using single or dual plating devices as an internal fixation method with multiple screws securing the plate along the axis of the femur and tibia. The plates are placed at either the anterior, lateral, and/or medial aspect of the fusion site (Figure 5a, b)^[31,48]. Compared to external fixators, better fusion rates and patient comfort have been observed as well as rigid fixation in large defects (Figure 6a, b)^[8,31,48-50]. Furthermore, only a single incision is necessary for debridement, removal of previous implants, preparation of the fusion site, and implantation of the plates^[1]. However, like other internal fixation devices, increased infection rates have been observed in addition to the inability to immediately fully bear weight after the procedure and an increased surgical dissection compared to IM nails^[3,31,48].

In a recent arthrodesis comparison study by Schwarzkopf *et al*, a 77.8% (7 of 9) rate of fusion was observed when compression plating was utilized with a complication rate of 40%^[4]. In a similar comparison study, Van Rensch *et al* observed a fusion rate of 50% (3 of 6 patients) in patients who underwent a dual plate fixation procedure^[8].

AUTHOR'S PREFERRED TECHNIQUE

The long intramedullary nail (Trident, Smith and Nephew Richards, Inc., Memphis, USA), is our preferred knee arthrodesis technique. This is a single, long IM nail that is inserted in an anterograde fashion through the piriformis fossa until the nail reaches the tibial plafond distally. Fusion site preparation as well as intramedullary reaming is performed from the knee arthrotomy. The nail is secured proximally and distally with cross-locking screws, and bone graft may be used to manage severe bony defects (Figure 2a, b, c). In our experience, we have noticed complication rates comparable to those found in the literature as well as favorable fusion rates in patients who present with failed TKA when compared to other techniques.

SUMMARY

Knee arthrodesis has proved to be an acceptable alternative to knee amputation as a salvage option for treating failed TKA. A number of different techniques exist which include their own specific indications, advantages, and disadvantages. It is vital that the surgeon is familiar with these procedures and their different attributes in regards to the unique conditions that the patient may present with from both a general health standpoint as well as from the status of the knee. Data collected from this review of recent knee arthrodesis studies confirms many of the findings from older studies, namely, the higher rates of fusion of long IM nails compared to all other techniques, lower overall complication rates in IM nails compared to external fixation, lower rates of recurrent/persistent infection in external fixation compared to IM nails, and faster time to fusion for IM nails as a whole compared to external fixation (Table 2).

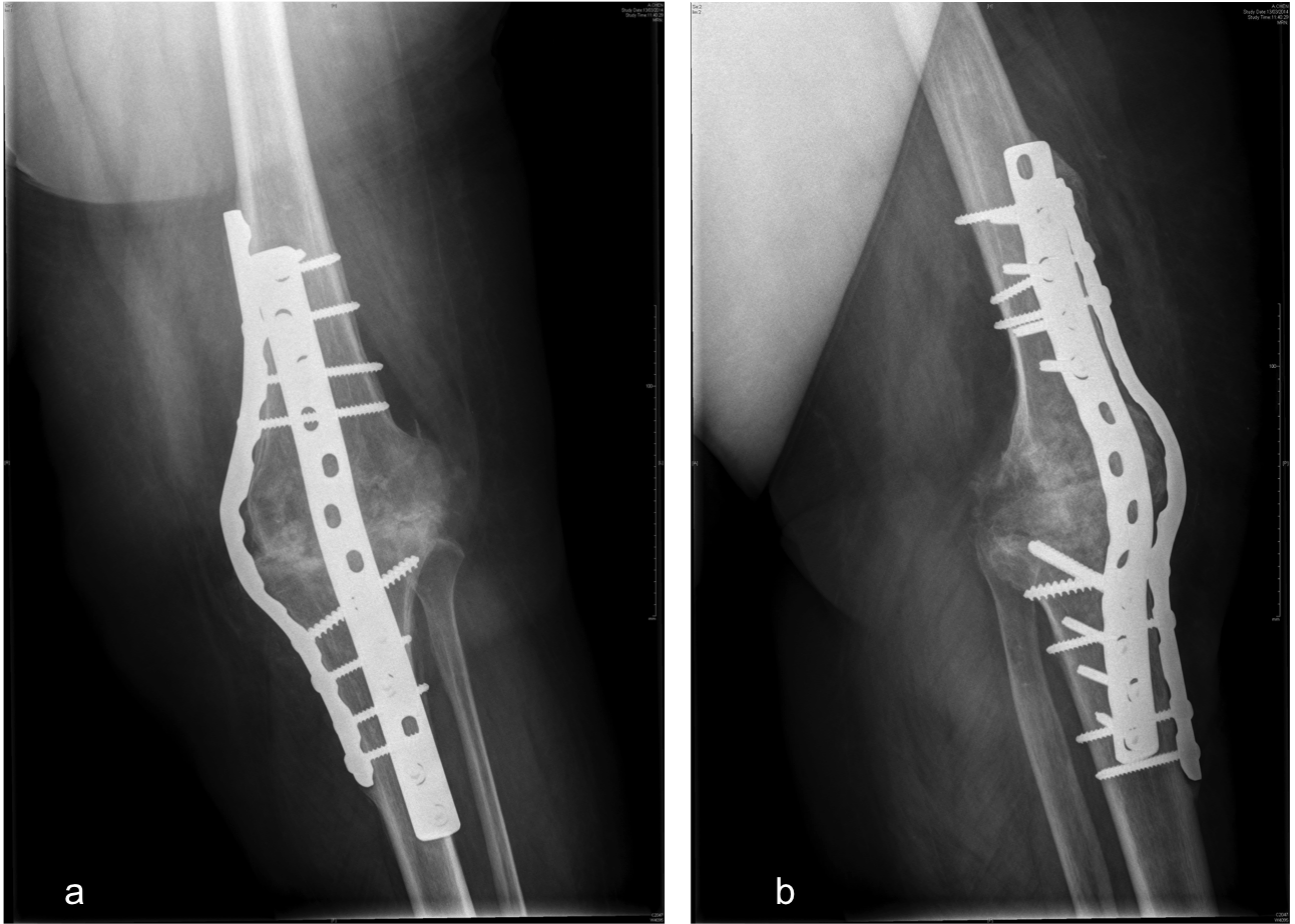


Figure 5 Knee fusion with compression plate technique after failed TKA.

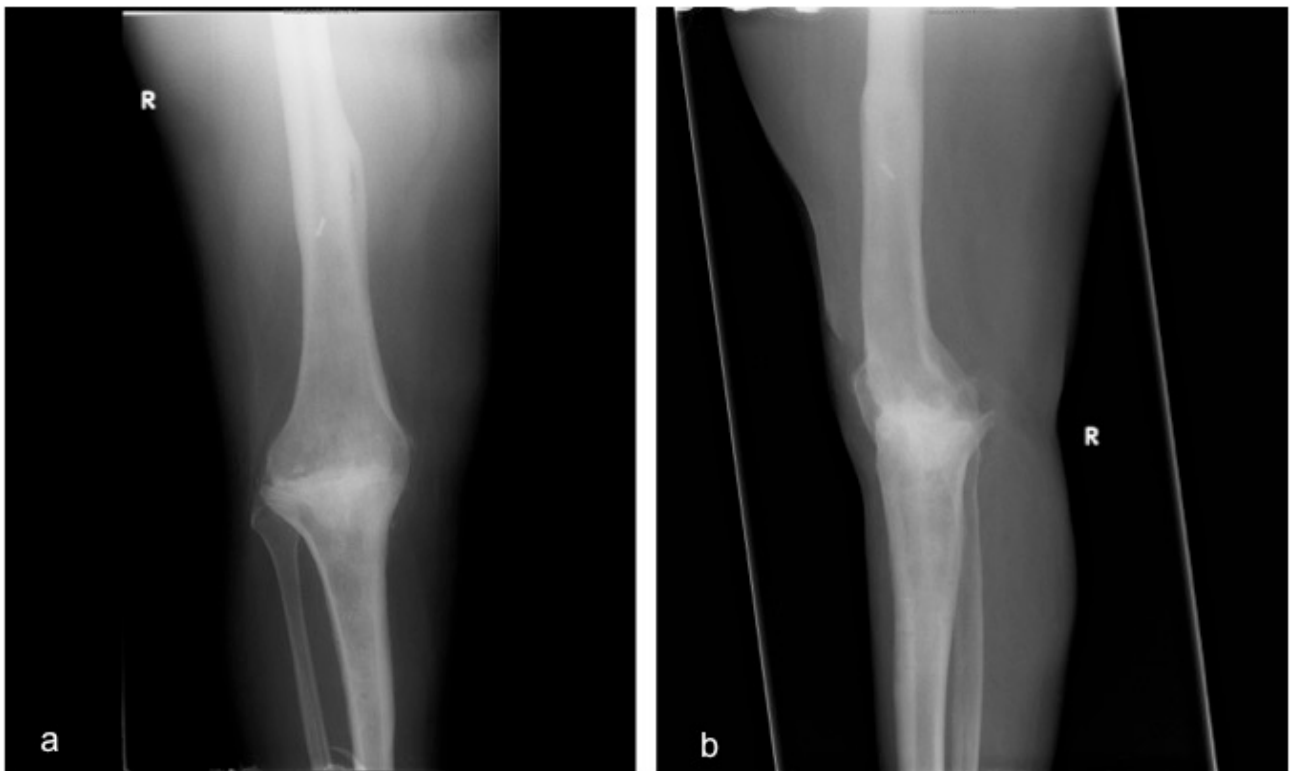


Figure 6 Successful knee arthrodesis, with compression plate technique, after removal of hardware.

Table 2 Average values of outcomes from all studies reviewed.

General arthrodesis technique	Specific technique	Avg. fusion rate (range)	Avg. time to fusion (range)	Avg. complication rate (range)	Avg. postop persistent or recurrent infection rate (range)	Avg. postop LLD (range)
Intramedullary nail	Overall - IM nail	88.2%; n=331	4.6 months; n=208	31.7%; n=218	18.5%; n=281	21.1 mm; n=159
	Long IM nail	91.1% (81.5-100%); n=79	5.5 months (5-6.5 months); n = 36	41.0% (40-42.9%); n=61	15.6% (5.9-26.7%); n=90	28.3 mm (8-55mm); n=74
	Short modular nail	86.7% (67.7-100%); n=170	3.8 months (3.1-5.2 months); n=141	25.5% (11.4-81.8%); n=106	17.4% (0-45.5%); n=109	12.1 mm (10-15 mm); n=72
External Fixation	Overall - EF	76.2%; n=214	7.0 months; n=138	41.1%; n=129	10.1%; n=168	36.6 mm; n=105
	Monoplanar external fixation	63.0% (28.6-87.5%); n=46	9.7 months (4.3-10.3 months); n=19	-	22.2% (12.5-57.1%); n=36	48.9 mm (47-54mm); n=29
	Biplanar external fixation	86.1% (88.9-90%); n=36	4.9 months (3.5-5.6 months); n=31	-	0%; n=36	45 mm; n=12
	Circular frame	87.3% (71.4-93.8%); n=71	9 months (6.5-11.7 months); n=47	32.7% (6.25-71.4%); n=55	8.5% (0-18.8%); n=71	37.8 mm (28-45.3 mm); n=64
Compression plate	Compression plate	88.6 (50-100%); n=44	-	-	-	-

CONFLICT OF INTEREST

There are no conflicts of interest with regard to the present study.

REFERENCES

- Somayaji HS, Tsaggerides P, Ware HE, Dowd GS. Knee arthrodesis--a review. *Knee* 2008; 15: 247-54.
- Charnley J LH. A study of the end-results of compression arthrodesis of the knee. *J Bone Joint Surg Br* 1958; 40-B(4): 633-5.
- MacDonald JH, Agarwal S, Lorei MP, Johanson NA, Freiberg AA. Knee arthrodesis. *J Am Acad Orthop Surg* 2006; 14: 154-63.
- Schwarzkopf R, Kahn TL, Succar J, Ready JE. Success of different knee arthrodesis techniques after failed total knee arthroplasty: is there a preferred technique? *J Arthroplasty* 2014; 29: 982-8.
- Conway JD, Mont MA, Bezwada HP. Arthrodesis of the knee. *J Bone Joint Surg Am* 2004; 86-a: 835-48.
- Archibeck MJ, White RE, Jr. What's new in adult reconstructive knee surgery. *J Bone Joint Surg Am* 2006; 88: 1677-86.
- Damron TA, McBeath AA. Arthrodesis following failed total knee arthroplasty: comprehensive review and meta-analysis of recent literature. *Orthopedics* 1995; 18: 361-8.
- Van Rensch PJ, Van de Pol GJ, Goosen JH, Wymenga AB, De Man FH. Arthrodesis of the knee following failed arthroplasty. *Knee Surg Sports Traumatol Arthrosc* 2014; 22: 1940-8.
- Kuchinad R, Fourman MS, Fragomen AT, Rozbruch SR. Knee arthrodesis as limb salvage for complex failures of total knee arthroplasty. *J Arthroplasty* 2014; 29: 2150-5.
- Iacono F, Raspugli GF, Bruni D, *et al* Arthrodesis After Infected Revision TKA: Retrospective Comparison of Intramedullary Nailing and External Fixation. *HSS J* 2013; 9: 229-35.
- White SP, Porteous AJ, Newman JH, Mintowt-Czyz W, Barr V. Arthrodesis of the knee using a custom-made intramedullary coupled device. *J Bone Joint Surg Br* 2003; 85: 57-61.
- Yeoh D, Goddard R, Macnamara P, *et al* A comparison of two techniques for knee arthrodesis: the custom made intramedullary Mayday nail versus a monoaxial external fixator. *Knee* 2008; 15: 263-7.
- Rohner E, Pfitzner T, Preininger B, Zippelius T, Perka C. Temporary arthrodesis using fixator rods in two-stage revision of septic knee prosthesis with severe bone and tissue defects. *Knee Surg Sports Traumatol Arthrosc* 2014.
- Lee S, Jang J, Seong SC, Lee MC. Distraction arthrodesis with intramedullary nail and mixed bone grafting after failed infected total knee arthroplasty. *Knee Surg Sports Traumatol Arthrosc* 2012; 20: 346-55.
- Rand JA, Bryan RS, Chao EY. Failed total knee arthroplasty treated by arthrodesis of the knee using the Ace-Fischer apparatus. *J Bone Joint Surg Am* 1987; 69: 39-45.
- Parcel TW, Levering M, Polikandriotis JA, Gustke KA, Bernasek TL. Failure analysis of knee arthrodesis with the WichitaFusion Nail. *Orthopedics* 2013; 36: e1336-9.
- Leroux B, Aparicio G, Fontanin N, *et al* Arthrodesis in septic knees using a long intramedullary nail: 17 consecutive cases. *Orthop Traumatol Surg Res* 2013; 99: 399-404.
- Bargiotas K, Wohlrab D, Sewecke JJ, Lavinge G, DeMeo PJ, Sotereanos NG. Arthrodesis of the knee with a long intramedullary nail following the failure of a total knee arthroplasty as the result of infection. Surgical technique. *J Bone Joint Surg Am* 2007; 89 Suppl 2 Pt. 1: 103-10.
- Thonse R, Conway J. Antibiotic cement-coated interlocking nail for the treatment of infected nonunions and segmental bone defects. *J Orthop Trauma* 2007; 21: 258-68.
- Putman S, Kern G, Senneville E, Beltrand E, Migaud H. Knee arthrodesis using a customised modular intramedullary nail in failed infected total knee arthroplasty. *Orthop Traumatol Surg Res* 2013; 99: 391-8.
- Crockarell JR, Jr., Mihalko MJ. Knee arthrodesis using an intramedullary nail. *J Arthroplasty* 2005; 20: 703-8.
- Neuerburg C, Bieger R, Jung S, Kappe T, Reichel H, Decking R. Bridging knee arthrodesis for limb salvage using an intramedullary cemented nail: a retrospective outcome analysis of a case series. *Arch Orthop Trauma Surg* 2012; 132: 1183-9.
- Incavo SJ, Lilly JW, Bartlett CS, Churchill DL. Arthrodesis of the knee: experience with intramedullary nailing. *J Arthroplasty* 2000; 15: 871-6.
- Panagiotopoulos E, Kouzelis A, Matzaroglou C, Saridis A, Lambiris E. Intramedullary knee arthrodesis as a salvage procedure after failed total knee replacement. *Int Orthop* 2006; 30: 545-9.
- Arroyo JS, Garvin KL, Neff JR. Arthrodesis of the knee with a modular titanium intramedullary nail. *J Bone Joint Surg Am* 1997; 79: 26-35.
- Colin J Senior REDAÃo, Ian W Barlow. Knee arthrodesis for limb salvage with an intramedullary coupled nail. *Archives of orthopaedic and trauma surgery* 2008; 128.
- De Vil J, Almqvist KF, Vanheeren P, Boone B, Verdonk R. Knee arthrodesis with an intramedullary nail: a retrospective study. *Knee Surg Sports Traumatol Arthrosc* 2008; 16: 645-50.
- Letartre R, Combes A, Autissier G, Bonneville N, Gougeon F. Knee arthrodesis using a modular customized intramedullary nail. *Orthop Traumatol Surg Res* 2009; 95: 520-8.
- McQueen DA, Cooke FW, Hahn DL. Knee arthrodesis with the Wichita Fusion Nail: an outcome comparison. *Clin Orthop Relat Res* 2006; 446: 132-9.
- Wilde AH, Stearns KL. Intramedullary fixation for arthrodesis of the knee after infected total knee arthroplasty. *Clin Orthop Relat Res* 2006; 446: 132-9.

- Res 1989; 87-92.
31. Nichols SJ, Landon GC, Tullos HS. Arthrodesis with dual plates after failed total knee arthroplasty. *J Bone Joint Surg Am* 1991; 73: 1020-4.
 32. Michael J Christie DKD, David A McQueen, Francis W Cooke, D L Hahn. Salvage procedures for failed total knee arthroplasty. *The Journal of Bone and Joint Surgery (American)* volume 2003; 85-A Suppl 1.
 33. Bartlett W, Vijayan S, Pollock R, *et al* The Stanmore knee arthrodesis prosthesis. *J Arthroplasty* 2011; 26: 903-8.
 34. Rohner E, Windisch C, Nuetzmann K, Rau M, Arnhold M, Matziolis G. Unsatisfactory outcome of arthrodesis performed after septic failure of revision total knee arthroplasty. *J Bone Joint Surg Am* 2015; 97: 298-301.
 35. Corona PS, Hernandez A, Reverte-Vinaixa MM, Amat C, Flores X. Outcome after knee arthrodesis for failed septic total knee replacement using a monolateral external fixator. *J Orthop Surg (Hong Kong)* 2013; 21: 275-80.
 36. Garcia-Lopez I, Aguayo MA, Cuevas A, Navarro P, Prieto C, Carpintero P. Knee arthrodesis with the Vari-Wall nail for treatment of infected total knee arthroplasty. *Acta Orthop Belg* 2008; 74: 809-15.
 37. Eralp L, Kocaoglu M, Tuncay I, Bilen FE, Samir SE. Knee arthrodesis using a unilateral external fixator for the treatment of infectious sequelae. *Acta Orthop Traumatol Turc* 2008; 42: 84-9.
 38. Watanabe K, Minowa T, Takeda S, *et al* Outcomes of knee arthrodesis following infected total knee arthroplasty: a retrospective analysis of 8 cases. *Mod Rheumatol* 2014; 24: 243-9.
 39. Bose WJ, Gearen PF, Randall JC, Petty W. Long-term outcome of 42 knees with chronic infection after total knee arthroplasty. *Clin Orthop Relat Res* 1995; 285-96.
 40. Riouallon G, Molina V, Mansour C, Court C, Nordin JY. An original knee arthrodesis technique combining external fixator with Steinman pins direct fixation. *Orthop Traumatol Surg Res* 2009; 95: 272-7.
 41. Parratte S, Madougou S, Villaba M, Stein A, Rochwerger A, Curvale G. Knee arthrodesis with a double mono-bar external fixators to salvage infected knee arthroplasty: retrospective analysis of 18 knees with mean seven-year follow-up. *Rev Chir Orthop Reparatrice Appar Mot* 2007; 93: 373-80.
 42. Raskolnikov D, Slover JD, Egol KA. The use of a multiplanar, multi-axis external fixator to achieve knee arthrodesis in a worst case scenario: a case series. *Iowa Orthop J* 2013; 33: 19-24.
 43. Spina M, Gualdrini G, Fosco M, Giunti A. Knee arthrodesis with the Ilizarov external fixator as treatment for septic failure of knee arthroplasty. *J Orthop Traumatol* 2010; 11: 81-8.
 44. Reddy VG, Kumar RV, Mootha AK, Thayi C, Kantesaria P, Reddy D. Salvage of infected total knee arthroplasty with Ilizarov external fixator. *Indian J Orthop* 2011; 45: 541-7.
 45. Ganger R, Radler C, Speigner B, Grill F. Correction of post-traumatic lower limb deformities using the Taylor spatial frame. *Int Orthop* 2010; 34: 723-30.
 46. Sala F, Albisetti W, Capitani D. Versatility of Taylor Spatial Frame in Gustilo-Anderson III C femoral fractures: report of three cases. *Musculoskelet Surg* 2010; 94: 103-8.
 47. Oostenbroek HJ, van Roermund PM. Arthrodesis of the knee after an infected arthroplasty using the Ilizarov method. *J Bone Joint Surg Br* 2001; 83: 50-4.
 48. Pritchett JW, Mallin BA, Matthews AC. Knee arthrodesis with a tension-band plate. *J Bone Joint Surg Am* 1988; 70: 285-8.
 49. Hak DJ, Lieberman JR, Finerman GA. Single plane and biplane external fixators for knee arthrodesis. *Clin Orthop Relat Res* 1995; 134-44.
 50. Kuo AC, Meehan JP, Lee M. Knee fusion using dual platings with the locking compression plate. *J Arthroplasty* 2005; 20: 772-6.
 51. Mabry TM, Jacofsky DJ, Haidukewych GJ, Hanssen AD. Comparison of intramedullary nailing and external fixation knee arthrodesis for the infected knee replacement. *Clin Orthop Relat Res* 2007; 464: 11-5.