

Case Report & Review of Literature – the Unusual Case of Osteomyelitis of the Acromion

Luke Hughes, Alistair Pace

Luke Hughes, MBBS, MRCS, Specialist Registrar, Scarborough Hospital, York Teaching Hospital, Woodlands Drive, Scarborough, the United Kingdom

Alistair Pace, MD, MSc, FRCS, Consultant Orthopaedic Surgeon, Scarborough Hospital, York Teaching Hospital, Woodlands Drive, Scarborough, the United Kingdom

Correspondence to: Alistair Pace, MD, MSc, FRCS, Consultant Orthopaedic Surgeon, Scarborough Hospital, York Teaching Hospital, Woodlands Drive, Scarborough, the United Kingdom.

Email: alistairpace@hotmail.com

Telephone: +447905014976

Received: February 25, 2016

Revised: April 9, 2016

Accepted: April 13, 2016

Published online: June 23, 2016

ABSTRACT

Localised acute osteomyelitis of the acromion has not been previously reported in the literature. We present a case report of a 15 year old male who presented with a 4 day history of shoulder tip pain and symptoms of SIRS. Investigation revealed localised osteomyelitis of the acromion with positive blood culture for staphylococcus. He was treated successfully with intravenous and oral antibiotics. In this article is discussed the aetiology, radiological appearances and treatment of osteomyelitis. This case report highlights the potential association of osteomyelitis with acne, the importance of its early recognition and treatment to avoid complications.

Key words: Osteomyelitis; Acromion; Acne; MRI

© 2016 The Authors. Published by ACT Publishing Group Ltd.

Pace A, Hughes L. Case Report & Review of Literature – the Unusual Case of Osteomyelitis of the Acromion. *International Journal of Orthopaedics* 2016; 3(3): 577-580 Available from: URL: <http://www.ghrnet.org/index.php/ijo/article/view/1625>

INTRODUCTION

Osteomyelitis is infection of the bone. It typically develops by direct extension or haematological spread. An atypical presentation may result in diagnostic uncertainty with implications for management. In this case report we discuss the case of acute osteomyelitis that developed in the context of acne.

CASE REPORT

A 15 year old autistic adolescent male presented with a four day history of right sided insidious severe shoulder pain associated with constitutional symptoms, including fever and loss of appetite. No precipitating event or trauma was reported. He was otherwise fit and well although he suffered from widespread acne particularly on the superior aspects of both shoulders and face. He was not on any treatment for this condition.

Examination identified pustular acne and mild erythema over the right shoulder. There was ill-defined tenderness over the acromion. There were no associated masses. Movements of the right shoulder were generally painful but he demonstrated a full range of movement. Initial blood tests demonstrated raised inflammatory markers and a high white cell count (CRP 98, WCC 13.1). Preliminary imaging included Anteroposterior and Lateral radiographs views of the right shoulder and scapula. These were reported as normal (Figures 1 and 2).

Subsequent investigation included an ultrasound scan (Figure 3). This revealed inflammatory soft tissue in the subacromial bursa with minimal fluid in the subdeltoid bursa. These appearances are consistent with acute inflammatory bursitis. There was no evidence of a joint effusion or septic arthritis.

An urgent MRI was organised (Figure 4). The shoulder and AC joints appeared unremarkable. There was some high signal in the acromion and the periosteum surrounding the acromion, some subperiosteal fluid, findings highly suggestive of osteomyelitis. This was associated with a small amount of fluid in the sub acromial bursa. There was extensive soft tissue oedema spread medially

along the upper border of the scapula and along the supraspinatus muscle. There was no abscess visible.

The patient was commenced on high dose antibiotics on the recommendation of the microbiologist. These included a combination of intravenous Benzyl penicillin and Flucloxacillin. The result of blood cultures and sensitivities, obtained upon admission demonstrated a gram positive cocci – *Staphylococcus aureus*. In view of this, the Benzylpenicillin antibiotic was stopped and he was continued on intravenous Flucloxacillin. Treatment included 4 weeks of intravenous antibiotics and his condition improved clinically. He was then switched to oral Flucloxacillin for a further 2 weeks. Repeat blood investigations, including white blood cell count and CRP, also improved week after week such that they normalised 6 weeks after commencing treatment. The MRI scan was not repeated as he responded to treatment and it was not felt necessary to biopsy the acromion.

DISCUSSION

Osteomyelitis or bone infection in adolescents is a serious disease. Signs and symptoms of osteomyelitis, although well known, are not specific and vary according to age. Microbial invasion of the bone typically results from hematogenous seeding however it can also occur by direct extension e.g through a wound or open fracture. Hematogenous osteomyelitis is an invasive bacterial disease currently

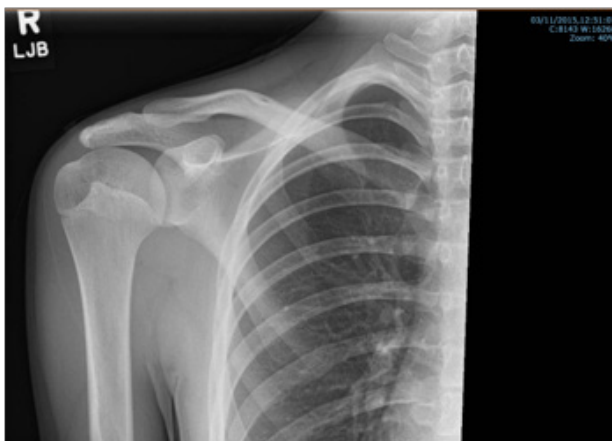


Figure 1 Plain AP radiograph of right shoulder obtained at initial presentation.

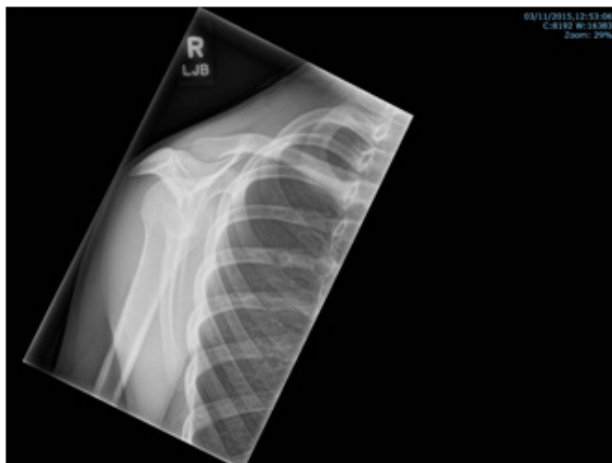

Figure 2 Plain lateral radiograph of right shoulder obtained at initial presentation.

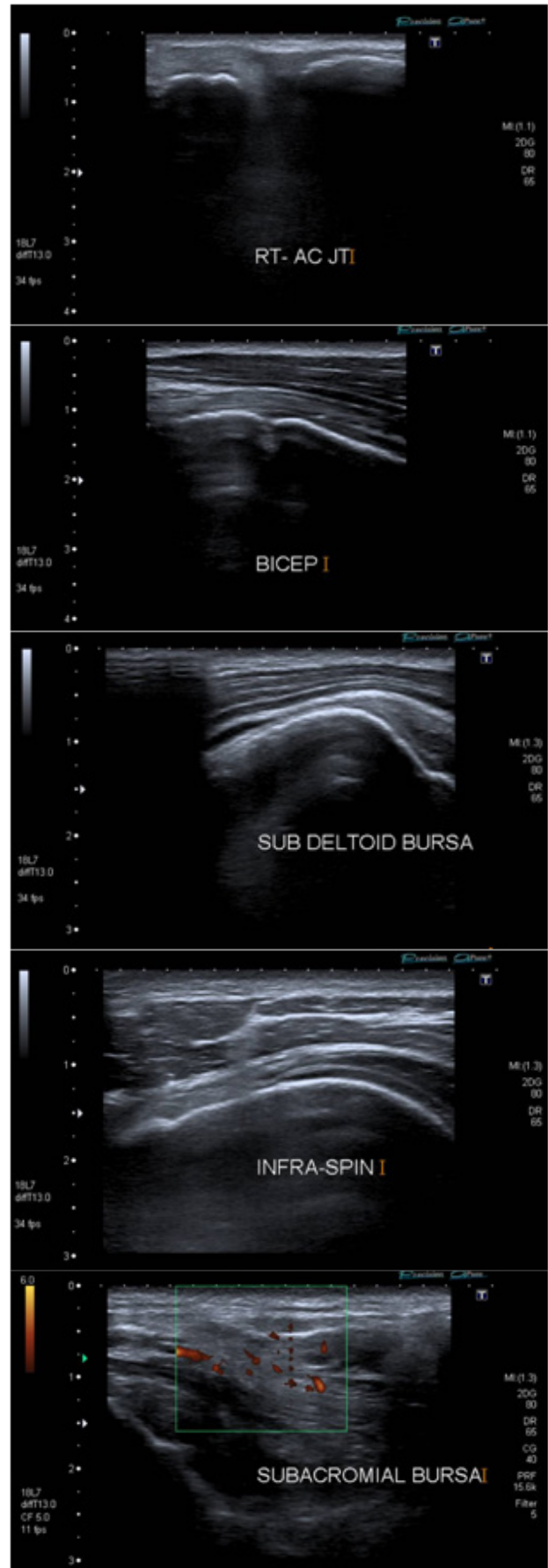


Figure 3 Ultrasound images of right AC joint, biceps, subdeltoid bursa, infraspinatus, subacromial bursa.

classified as an important cause of morbidity in childhood. Its annual incidence has remained unchanged in the last decades and ranges from 1: 5,000 to 1: 10,000 children and is two times higher among boys^[1,2]. The pathogens most commonly isolated vary according to the patient's age. *Staphylococcus aureus* is the most commonly isolated organism in adults^[3]. In infants, the pathogens most frequently isolated include *Staphylococcus aureus*, *Streptococcus agalactiae*, and *Escherichia coli*. In children more than 1 year of age *Staphylococcus aureus*, *Streptococcus pyogenes*, and *Haemophilus influenzae* are the most commonly isolated^[4]. After age 4, the incidence of *Haemophilus influenzae* infection decreases. The overall incidence of *H. influenzae*, as a cause of osteomyelitis has dramatically decreased with development of the *H. influenzae* vaccine^[5,6]. In the case we describe the patient was of adolescent age and cultures grew *Staphylococcus aureus*. The source of the infection was either haematogenous spread from the pustular acne or by direct contiguous spread from the acne over his shoulder. Clinical examination had revealed no other source of bacteraemia or infection.

The diagnosis of osteomyelitis is dependant upon a high index of clinical suspicion primarily. Routine bloods will demonstrate raised inflammatory markers. Plain radiographic changes tend to lag at least two weeks behind the infection evolution. Typical early bony changes include periosteal thickening, lytic lesions, endosteal scalloping, osteopenia, loss of trabecular architecture, and new bone apposition^[7]. Obtaining plain radiographs is often the first port of radiological evaluation. They may suggest the underlying diagnosis, excluding other diagnostic possibilities and hint as to underlying pathologic conditions. Evaluation with ultrasound (US) has many advantages. It is often readily available, and is quick, simple and non-invasive test. It does not involve exposure to radiation, offers real time evaluation and may be used in patients where orthopaedic instrumentation precludes the use of computed tomography (CT) or magnetic resonance imaging (MRI)^[8]. US may demonstrate features of osteomyelitis several days earlier than plain radiographs. Features of acute osteomyelitis on US include elevation of the periosteum by a hypochoic layer of purulent material. In chronic osteomyelitis, ultrasound can also be used to assess the adjacent soft tissues. Soft tissue abscesses related to chronic osteomyelitis are identified as hypochoic or anechoic fluid collections, which may extend around the bony contours. Finally, cortical erosions can become apparent^[9]. CT is used to provide multi-planar reconstructions permitting delineation of subtle osseous changes much earlier than both plain radiographs and US. It is highly sensitive and specific^[10]. However, image resolution may be affected by orthopaedic instrumentation with a loss of image resolution secondary to a beam-hardening artifact^[11,12]. Despite these distinct advantages CT is less desirable than MRI. With MRI there is much improved soft tissue contrast and no exposure to ionizing radiation. MRI can detect osteomyelitis as early as 3-5 days after the onset of infection^[13]. It is considered the most useful imaging modality, providing excellent structural definition and spatial resolution^[14]. This facilitates pre-operative planning, with modification of management to avoid morbidity^[15]. However, as with CT, metal implants can affect image quality.

In light of known common isolates antibiotic treatment should target *Staphylococcus aureus* including community-acquired methicillin-resistant strains. In some cases, surgical debridement is indicated, especially in cases of chronic osteomyelitis or osteomyelitis associated with septic arthritis. This was not the case in our patient. He responded to treatment and there was no collection identified.

Left untreated osteomyelitis can result in complications including

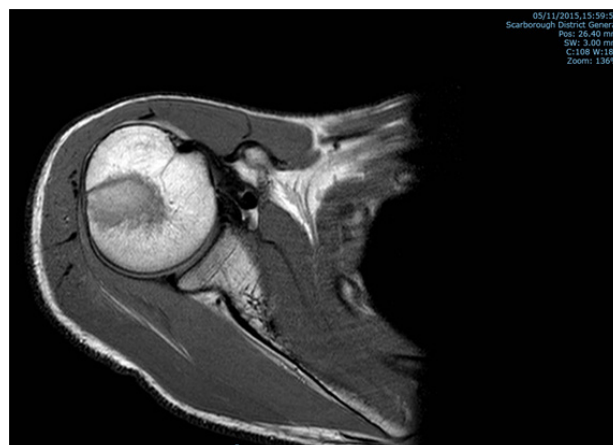


Figure 4 MRI of right shoulder joint.

tissue necrosis, progression to chronic osteomyelitis, pathological fracture, joint instability and changes in the epiphyseal plate^[16]. A high index of clinical suspicion and early instigation of treatment leads to good outcomes for most patients, with complication rates of about 5% and mortality close to zero^[17,18].

Acne vulgaris particularly if it develops into acne fulminans is known to be associated with aseptic osteolytic lesions^[19,20]. These tend to affect bones lying superficially, including: the clavicle, sternum and long bones^[21]. It may also be part of the SAPHO syndrome – synovitis, acne, pustulosis, hyperostitis and osteitis^[22]. These lesions are not infective in nature but are thought to be immunologically mediated. Acute osteomyelitis of the acromion developing as a result of overlying acne has not been previously described in the English literature. This case report highlights the importance of its early recognition and treatment to avoid complications.

ETHICAL STANDARDS

The patient gave the informed consent to the publication of the case study. There are no conflicts of interest.

REFERENCES

- Weichert S, Sharland M, Clarke NM, Faust SN. Acute haematogenous osteomyelitis in children: is there any evidence for how long we should treat? *Curr Opin Infect Dis* 2008; **21**: 258-62
- Kaplan SL. Osteomyelitis in children. *Infect Dis Clin North Am* 2005; **19**: 787-97.
- Lew D P, Waldvogel F A. Osteomyelitis. *N Engl J Med*. 1997; **336**: 999-1007.
- Song K M, Sloboda J F. Acute hematogenous osteomyelitis in children. *J Am Acad Orthop Surg*. 2001; **9**: 166-175
- Blyth M J, Kincaid R, Craigen M A, Bennet G C. The changing epidemiology of acute and subacute haematogenous osteomyelitis in children. *J Bone Joint Surg Br*. 2001; **83**: 99-102.
- De Jonghe M, Glaesener G. Type B *Haemophilus influenzae* infections. Experience at the Pediatric Hospital of Luxembourg. *Bull SocSci Med Grand Ducheluxemb*. 1995; **132**: 17-20.
- Kothari N A, Pelchovitz D P, Meyer P J. Imaging of musculoskeletal infections. *Radiol Clin North Am*. 2001; **39**: 653-671
- Cardinal E, Bureau N, Aubin B. Role of the ultrasound in musculoskeletal infections. *Radiol Clin North Am*. 2001; **39**: 191-201.
- Pineda C, Vargas A, Vargas-Rodriguez A. Imaging of osteomyelitis: current concepts. *Infect Dis Clin North Am*. 2006; **20**: 789-825
- Termaat M F, Raijmakers P G, Scholte H J, *et al.* The accuracy

- of diagnostic imaging for the assessment of chronic osteomyelitis: a systematic review and meta-analysis. *J Bone Joint Surg Am.* 2005; **87**: 2464-2471
- 11 Bohndorf K. Infection of the appendicular skeleton. *EurRadiol.* 2004; **14(Suppl 3)**: E53-E63.
 - 12 Cierny G, III, Mader J T, Pennick J J. A clinical staging system for adult osteomyelitis. *Clin Orthop Relat Res.* 2003; **414**: 7-24
 - 13 Kocher M S, Lee B, Dolan M, Weinberg J, Shulman S T. Pediatric orthopedic infections; early detection and treatment. *Pediatr Ann.* 2006; **35**: 112-122.
 - 14 Meyers S P, Wiener S N. Diagnosis of hematogenous pyogenic vertebral osteomyelitis by magnetic resonance imaging. *Arch Intern Med.* 1991; **151**: 683-687.
 - 15 Towers J D. The use of intravenous contrast in MRI of extremity infection. *Semin Ultrasound CTMR.* 1997; **18**: 269-275
 - 16 Staniski CL. Changes in pediatric acute hematogenous osteomyelitis management. *J Pediatr Orthop* 2004; **24**: 444-5
 - 17 Darville T, Jacobs R, Richard F. Management of acute hematogenous osteomyelitis in children. *Pediatr Infect Dis J* 2004; **23**: 255-7.
 - 18 Gutierrez K. Bone and joint infections in children. *Pediatr Clin North Am* 2005; **52**: 779-94.
 - 19 Karvonen SL. Acne fulminans: report of clinical findings and treatment of 24 patients. *J Am Acad Dermatol* 1993; **28**: 572-579
 - 20 O'Malley BP, Anderson I, Aoesenthal FD. Bone lesions in systemic acne (acne fulminans). *Br J Dermatol* 1979; **100**: 703-705
 - 21 Jemec GBE, Rasmussen I. Bone lesions of acne fulminans. *J Am Acad Dermatol* 1989; **20**: 353-357
 - 22 Swei Y, Taguchi A, Tanimoto K. Diagnostic points and possible origin of osteomyelitis in synovitis, acne, pustulosis, hyperostosis and osteitis (SAPHO) syndrome: A radiographic study of 77 mandibular osteomyelitis cases. *Rheumatology (Oxford)* 2003; **42**: 1398-403.

Peer reviewer: Alexandru Draghici, Foisor Hospital of Orthopaedics, Trauma and Osteoarticular TB, Bucharest, Romania.