

Outcome of Knee Joint Arthrodesis as a Salvage Procedure after Periprosthetic Infection: An Analysis of 41 Patients

Helge Hasselberg, Franz Müller, Michael Zellner, Bernd Krieg, Christian Bäuml, Bernd Füchtmeier

Helge Hasselberg, Franz Müller, Michael Zellner, Bernd Krieg, Christian Bäuml, Bernd Füchtmeier, Clinic for Trauma, Orthopaedic and Sports Medicine, Hospital Barmherzige Brüder, Prüfeninger Str. 86, 93042 Regensburg, Germany

Correspondence to: Franz Müller, Clinic for Trauma, Orthopaedic and Sports Medicine, Hospital Barmherzige Brüder, Prüfeninger Str. 86, 93042 Regensburg, Germany.

Email: mueller@barmherzige-regensburg.de

Telephone: +49-941-369-2251

Fax: +40-941-369-2255

Received: March 18, 2016

Revised: June 1, 2016

Accepted: June 3, 2016

Published online: June 23, 2016

ABSTRACT

AIM: There has been little scientific evidence regarding knee joint arthrodesis as a salvage procedure in patients with periprosthetic infections.

METHODS: We performed a retrospective clinical and radiological follow-up at least 1-year post-surgery in patients who had received knee joint arthrodesis between 2007 and 2012. Clinical follow-up was conducted using the WOMAC and SF-36 questionnaires.

RESULTS: A total of 41 consecutive patients were included with an average age of 69 years (range 36-90). In 24/41 patients (59%), arthrodesis was conducted using a modular prosthesis. In 14 patients (34%) bilateral double-plate osteosynthesis was used, and in 3 patients (7%) an external fixator. During the further course, 15/41 patients (37%) experienced complications that required revision, including subsequent above knee amputation (total 4 patients; 10%). Finally, radiological and clinical follow-up was possible in 18/41 patients (44%) after an average of 42 months (range 12-65) post-surgery. Clinical follow-up was conducted using the WOMAC and SF-36 questionnaires, and there was demonstrated a significant impairment of physical function, which was independent from the type of arthrodesis and leg length differences. Compared to a

healthy reference population, the social function and psychological subscore were not impaired.

CONCLUSION: Knee joint arthrodesis is a suitable salvage procedure in patients with chronic periprosthetic knee joint infections. We recommend the use of a double-plate osteosynthesis in patients with lesser bone loss and a modular prosthesis in larger defects. Both methods are prone to complications, and it is not always possible to prevent amputation during the further course of events.

Key words: Revision; Arthrodesis; Total knee arthroplasty; Prosthetic infection; Outcome

© 2016 The Authors. Published by ACT Publishing Group Ltd.

Hasselberg H, Müller F, Zellner M, Krieg B, Bäuml C, Füchtmeier B. Outcome of Knee Joint Arthrodesis as a Salvage Procedure after Periprosthetic Infection: An Analysis of 41 Patients. *International Journal of Orthopaedics* 2016; 3(3): 571-576 Available from: URL: <http://www.ghrnet.org/index.php/ijo/article/view/1641>

INTRODUCTION

Controlling periprosthetic knee infections undoubtedly presents a challenge for patients and the treating physicians, both from a therapeutic and a socioeconomic perspective^[1-3]. Treatment options include the administration of antibiotics, including one- or two-stage reimplantation^[4-6]. A systemic review suggested an infection control success rate for the first two-stage reimplantation of only 79%^[7]; and Mortazavi *et al* found that 28% of 117 infected total knee arthroplasties (TKAs) required reoperation for infection after an average of only 3.4 years^[8]. After a failed second two-stage reimplantation procedure, the reported success rates and knee function were even worse^[9,10]. Therefore, when repeated knee revision fails – in association with patellar tendon disintegration and further bone loss – the only three remaining options to control infections are knee arthrodesis, resection arthroplasty, or above the

knee amputation^[1-3].

When the extremity should be preserved and arthrodesis is performed, one must decide which surgical method to use. Generally, there are four available options: a modular implant arthrodesis, intramedullary rod, plate-screw-osteosynthesis, or external fixator^[11-16]. It is fairly common that a soft tissue cover is required to achieve wound closure after multiple or radical debridement^[11].

Scientific data on knee joint arthrodesis – all based on small case series – generally demonstrate the following: arthrodesis provides a stable, painless extremity with the facility to ambulate, and the function is superior to that after above the knee amputation^[2,11,16-18]. We wanted to verify these statements regarding arthrodesis as a salvage procedure after a chronic periprosthetic knee joint infection in our own consecutive case series.

MATERIAL AND METHODS

Between 1 January 2007 and 31 December 2012 we performed knee joint arthrodesis in a total of 41 patients. Chronic periprosthetic knee joint infection with loss of the extensor mechanism was the only indication. Patients had an average of 6 previous surgical procedures (range 2-13) of the affected knee joint, including primary implantation. Three different surgical techniques were used for definitive knee joint arthrodesis. In 24/41 patients (59%), the procedures were performed using a modular prosthesis (Peter Brehm, Weisendorf, Germany). The indication for that was a bony defect area of at least 4 cm up to a maximum of 30 cm (Figure 1).

In 14 patients (34%) with a bony defect area of less than 4 cm, osteosynthesis was performed using double-plates (LCP 4.5 mm; Synthes, Umkirch, Germany) that were fixed in a medial and lateral position (Figure 2).

Furthermore, biplanar external fixators (Synthes, Umkirch, Germany) were exclusively used in 3 other patients (7%) due to critical soft tissue conditions.

Surgical technique

The approach used for arthrodesis was identical to that of a bilateral septic knee arthroplasty replacement: At first, the existing total knee prosthesis was explanted, followed by radical debridement and antiseptic lavage. On this occasion, at least 5 microbiological tissue samples were collected and incubated for 14 days. During the same surgical session, temporary transfixation and arthrodesis were performed using Palacos cement filling and two intramedullary fixation rods (tibial and femoral); centrally fixed with a connector at a knee flexion of 20 degrees). A calculated 6-week antibiotic therapy was initiated at the time of sample collection and adjusted/extended (if applicable) after the antibiogram became available. Following a 2-week interval without antibiotics, a diagnostic arthrocentesis was conducted, and the samples were again incubated for a period of 14 days. Finally, definitive knee joint arthrodesis was performed when the following criteria were met: negative cultures, normal lab results of inflammatory parameters (CRP, leukocytes), and absence of clinical signs of infection (redness, warmth, fistulae). If these criteria were not met, another debridement with spacer replacement and sample collection was performed. As early as during the explantation procedure, the principal decision regarding the indication for two stage arthroplasty or knee joint arthrodesis was made.

All of the three arthrodesis methods can provide a high level of primary stability. Care must be taken to achieve an appropriate mechanical leg axis, flexion, and rotation.

Prior to using modular arthrodesis systems, the intramedullary

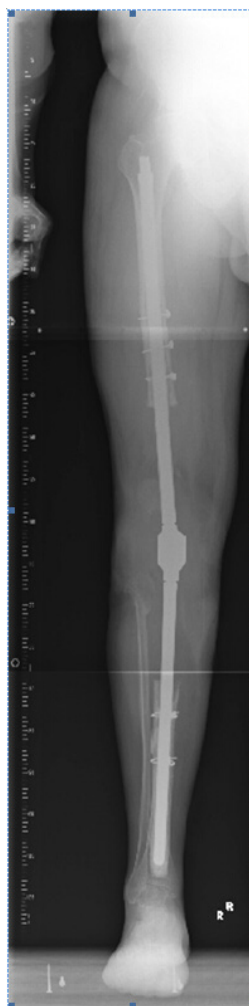

Figure 1 X-ray leg axis after implant arthrodesis for defect bridging (> 30 cm)

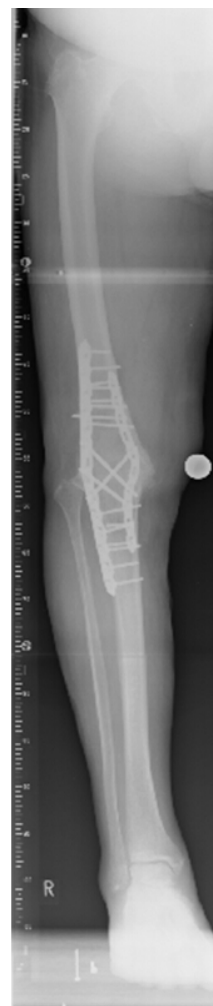

Figure 2 X-ray leg axis after double-plate arthrodesis (LCP 4.5).

cavities are prepared with drills and reamers, followed by jet lavage. Tibial and femoral sample implants are available during surgery. The appropriate leg length can be adjusted by means of sample coupling elements. The coupling elements have a valgus angle of 0 or 6 degrees. Flexion is 7 degrees. Coupling is performed following rotation control. As soon as the size has been identified, the definitive implants are used. The shaft can be implanted with or without using cement.

In patients where double-plate arthrodesis was performed, 4.5-mm LCP plates were used in a lateral and medial position. Caution must be exercised with regard to the Nervus peroneus in the lateral position. The ends of the plates must be situated at different height levels to prevent the formation of breaking points of potential bone fractures.

Fixator arthrodesis was performed in biplanar alignment due to a critical soft tissue condition.

Evaluation

After collecting the electronically stored demographic data (age, sex, ASA classification, duration of the surgical procedure, blood loss, detected pathogens, surgical revisions, length of hospital stay) of all 41 consecutive patients, a clinical and radiological follow-up (FU) was performed at least 1 year post-surgery in an outpatient environment, inviting the patients by phone call or letter.

As a first measure of the clinical and radiological FU, the leg length difference was determined. Bony consolidation and the length of the bony defect were measured radiologically. X-ray images of the affected knee joint were made in anterior-posterior and lateral views as well as along the leg axis with scaling and with the patient in a standing position.

Functionality, experience of pain, and quality of life were assessed using the Western Ontario and McMaster Universities Osteoarthritis (WOMAC) index^[19] and the Short-Form-36^[20] questionnaire. The questionnaires were completed by the patients and evaluated by an independent reviewer who was not involved in the treatment of the patients. All followed-up patients provided informed consent, and the retrospective follow-up was approved by our institutional review board.

Statistics

Statistical analyses were performed using SPSS for Windows, Version 22.0 (SPSS Inc., USA). Metric variables were presented as mean values, while the ranges were specified as standard deviations. Categorical and/or nominal data were specified as absolute and relative frequencies. The normal distribution of metric variables was assessed using the Shapiro-Wilk test. While some of the tested variables did not show a normal distribution (Shapiro-Wilk test: $p < 0.05$), other variables showed a normal distribution (Shapiro-Wilk test: $p \geq 0.05$). Therefore, tests for samples with a normal distribution and non-parametric tests for samples without a normal distribution were used when comparing the samples. When comparing 2 independent samples with a normal distribution, the *t*-test was used. Prior to this, the Levene test was used to evaluate the homogeneity of the variances. When the homogeneity of the variances had been confirmed, Student's *t*-test was conducted, while the Welch test, as a modification of the *t*-test, was used in the absence of variance homogeneity. When comparing samples without a normal distribution, the Mann-Whitney-U test (as a non-parametric method) was used. Correlation between 2 parameters was calculated using the correlation coefficient according to Pearson and according to Spearman-Roe. Categorical data were analysed using the Chi square test and Fisher's exact test. A two-sided significance test was performed for all of the tests, and a *p*-value < 0.05 was considered to be statistically significant for all of the statistical tests. The resulting physical and psychological subscores of the SF-36 questionnaire were compared to sample reference populations with regard to significant differences using the *t*-test for single samples. Reference values were retrieved from a general population and from patient population data^[20].

RESULTS

A retrospective analysis was performed after a mean period of 42 months post-surgery (range 12-66). The mean average age of the total population ($n = 41$) at the time of arthrodesis was 69 years (range 36-90). Out of the 41 enrolled patients, 24 were male and 17 were female, and 85% had an ASA 3 classification. The mean duration of surgery was 137 minutes (range 50-230), and the intraoperative blood loss was 1,200 mL (range 300-4,000). The mean length of hospital stay was 25 days (range 7-136; including days of admission and discharge); factors contributing to an extended length of stay were revision procedures and soft tissue procedures.

The most commonly detected pathogen was *Staphylococcus aureus* ($n = 14$; 34%), with coagulase-negative staphylococci being

the second most common ($n = 13$; 32%). Methicillin-resistant *Staphylococcus aureus* (MRSA) was found in 5 patients (12%).

Revision rate

One or multiple surgical revisions (due to complications) were required in 15/41 patients (37%) throughout the entire observation period. However, statistical analysis did not show significant differences in terms of the complication rates or surgical methods.

Nevertheless, patients with modular prosthesis showed the highest surgical revision rate (9/24; 38%). Three patients ultimately had to undergo above the knee amputation due to reinfection (4, 14, and 57 months post-surgery). A total of 4 cases of impaired wound healing were observed, and flap surgery (Gastrocnemius muscle flap) was required in 2 of those cases. Two other patients experienced a fall resulting in periprosthetic fractures (one tibial fracture and one femoral fracture). The femoral fracture was treated by performing femoral replacement, while the tibial fracture was treated by means of osteosynthesis.

Following plate arthrodesis, 5/14 patients (36%) had to undergo an additional surgery during the further course: A total of 2 patients experienced postoperative peri-implant femoral fractures (27 and 45 months post-surgery) and were successfully treated by means of re-osteosynthesis. Flap surgery had to be performed in another 2 patients with impaired wound healing. Due to non-union, re-osteosynthesis had to be performed in an additional patient 8 months post-surgery.

Following arthrodesis using an external fixator ($n=3$), one patient had to undergo above knee amputation 4 months post-surgery due to recurring infection.

Follow-up evaluation

Radiological and clinical follow-up was possible in a total of 18/41 patients (44%) after a mean period of 42 months post-surgery (range 12-66). Clinical follow-up was conducted using the WOMAC and SF-36 questionnaires:

At the time of the retrospective FU, 11 patients were already deceased (after a mean period of 35 months post-surgery; range 1-72), 3 patients were not suitable for FU due to dementia, and another 5 patients had unknown addresses and could not be contacted. Another 4 patients were excluded from the FU due to previously conducted above knee amputation (range 4-57 months).

At the time of follow-up, 11 patients presented without a walking aid, and 7 other patients required one or two walking crutches or a walker-roller.

Those 18 patients who underwent follow-up (mean age 74 years; range 59-93) presented with a reduction of leg length of -3 cm (range 0-5.5, Table 1). The differences in leg length reduction had no significant impact on the WOMAC and SF-36 outcomes ($p > 0.05$).

Patients had an average WOMAC physical subscore of 50 points (range 24-94) (Table 1). The mean SF-36 physical subscore was 30 (12-51), and the mean psychological subscore was 51 (22-69). Furthermore, a score of 52 (10-100) was reported to be in the "physical pain" dimension.

When compared to a male reference population (RP) of an age of 71-75 years, the SF-36 physical subscore was clearly reduced (RP 43 versus 30), while the psychological subscore was almost identical (RP 54 versus 51).

There was a high correlation between the WOMAC and the SF-36 physical subscore (Figure 3), but only a moderate correlation between the WOMAC and the psychological subscore.

Table 1 Demographic data and functional results at the time of FU (*n* = 18).

Nr	Age/sex	Follow-up/ months	Infection/organism	Arthrodesis technique	WOMAC	SF-36 PHFS	SF-36 PSS	LLD (cm)
1	51/m	64	staphylococcus epidermidis	double plating	90	51	63	-1.5
2	75/w	75	coagulase negative staphylococcus	double plating	41	30	46	- 2
3	67/w	36	coagulase negative staphylococcus	double plating	26	23	70	- 6
4	53/m	59	streptococcus	double plating	25	31	39	- 4
5	77/w	53	enterococcus	modular prosthesis	47	29	58	0
6	75/w	66	staphylococcus aureus	modular prosthesis	27	22	22	- 3
7	61/m	54	staphylococcus aureus	external fixator	72	39	54	- 1.5
8	66/m	65	coagulase negative staphylococcus	modular prosthesis	94	42	52	- 2
9	69/w	37	staphylococcus epidermidis	double plating	29	20	31	- 3
10	56/m	61	coagulase negative staphylococcus	double plating	41	15	73	- 3
11	74/m	15	staphylococcus aureus	modular prosthesis	24	28	42	- 3
12	73/w	56	staphylococcus aureus	modular prosthesis	37	25	40	- 2
13	74/w	35	β-hemolytic streptococcus	modular prosthesis	72	46	57	- 5.5
14	73/w	12	staphylococcus aureus	Modular prosthesis	28	25	43	- 3
15	90/m	30	no organism, but pus	double plating	82	43	61	- 5
16	67/m	53	staphylococcus aureus	modular prosthesis	75	41	53	- 5.5
17	69/m	12	coagulase negative staphylococcus	modular prosthesis	63	28	65	- 3
18	82/w	27	escherichia coli	modular prosthesis	29	12	49	0

WOMAC-C: Physical functionality domain of the WOMAC questionnaire; PHFS: Physical Function Subscore (SF-36); PSS: Psychological Subscore (SF-36); LLD: Leg Length Difference.

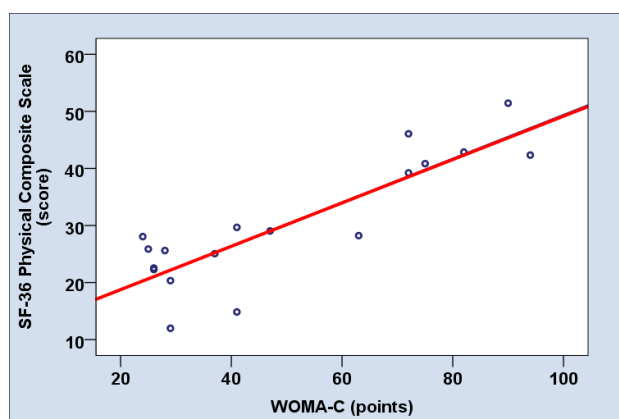


Figure 3 Correlation of the WOMAC Score with the physical composite scale of SF-36.

Furthermore, statistical analyses did not show significant differences between the clinical outcome and arthrodesis using modular prosthesis or plate osteosynthesis (Mann-Whitney-U test; $p = 0.894$).

DISCUSSION

Periprosthetic knee joint infections require long-term and sophisticated treatment. They mainly occur in morbid patients with underlying diseases, which impair quality of life. This also applied to our patient population that – as in similar studies – mainly encompassed morbid patients with advanced age and higher ASA scores.

The definitive treatment options that are available after multiple revision failures (with loss of the extensor apparatus) are the rarely used resection arthroplasty, knee joint arthrodesis, or ablation. With regard to ablation, it must be taken into account that particularly elderly and obese patients cannot be treated with prostheses because they are not strong enough to lift the femoral prosthesis for walking^[21–23]. According to Pring *et al*^[22], only 7 out of 21 patients were able to walk after ablation; in the study of Isiklar *et al*^[22] this applied to only 2 out of 8 patients. Therefore, both of these studies recommend avoiding this treatment in patients who were able to walk. In addition to being bedridden, those patients may experience

additional complications, such as pneumonia, urinary tract infections, and bedsores.

By contrast, knee joint arthrodesis should allow for improved functional outcomes and better mobility compared to ablation and its above mentioned disadvantages^[2,7,11]. But all of the studies on knee joint arthrodesis following periprosthetic infection are characterised by small patient populations (from 12 up to 20 patients) or by a high percentage of patients who were lost to follow-up^[1,16–18,24–26].

Similarly, it was possible to recruit only 18 patients for FU despite a high initial number of cases in our study. This clearly results in a false-positive bias, and the positive results of those studies in terms of outcome and infection control following arthrodesis must, therefore, be challenged and not adopted in their entirety^[1,2,7].

Based on the inconsistent outcomes with one-stage replacement procedures, the authors – in line with many other authors – prefer a two-stage technique^[16,26,27]. Success rates of up to 90% after a two-stage knee prosthesis replacement due to infection have been repeatedly confirmed in the past^[28,29].

A total of three surgical options are widely accepted for knee joint arthrodesis^[11,16,17,26]. In patients with minor bone defects – less than 4 cm in our population – arthrodesis by means of plate osteosynthesis or intramedullary techniques is possible and useful. We prefer fixed-angle plate arthrodesis (LCP 4.5 mm) performed as a so-called dual-plate technique, where the plates are fixed to the knee joint in lateral and medial positions (Figure 2). In this context, we explicitly do not recommend anterior plate fixation to prevent possible soft tissue irritation, a complication that was described in the literature very early on^[30]. Generally, we think that soft tissue irritation can be safely prevented by means of “trimming” or partial resection of both femoral condyles, respectively, prior to plate fixation or by adjuvant patellectomy. Nichols *et al*^[31] reported a fusion rate of 100% for the dual-plate technique in a small population of 11 patients.

In larger bony defects – more than 4 cm in our population – we think that intramedullary implant arthrodesis is the method of choice. The literature shows a consistent tendency to perform intramedullary procedures using different nails or devices^[11,16,18,25,26,32]. In our patient population, we exclusively used a modular arthrodesis prosthesis. In patients with large defects, this technique results in a favourable outcome in terms of functional leg length and in the postoperative availability of an extremity that is principally weight-bearing. On the other hand, there is an increased risk of reinfection and of

infection transfers into the medullary cavity. Accordingly, we had to perform an ablation procedure in 3/24 patients due to reinfection over the course of time. The worst-case scenario for such patients – particularly in cases with large femoral defects – would be that only a high above knee amputation or even a hip joint exarticulation could help to achieve infection control. However, this was not the case in our population. In the literature, the consolidation rates after knee arthrodesis using different intramedullary devices range from 83% to 100%^[11,14,18]. However, no long-term evaluations on intramedullary systems were available until now; therefore, no statements on the actual survival times or loosening rates can be made. It must be clarified as to whether silver-coated or other innovative implants and coatings are capable of reducing the risk of reinfection^[33].

Arthrodesis may be performed by means of external fixators in patients with desolate soft tissue conditions^[16]. However, some authors have demonstrated the reduced biomechanical stability of external fixators, resulting in lower union rates^[24,34]. Furthermore, soft tissue irritation and pintract infections are regularly observed, and the lack of comfort may eventually lead to treatment discontinuation^[16,24,34]. On the other hand, Klinger *et al*^[16] demonstrated that this procedure offers both infection control and reliable bony reconstruction, and only 3 out of 18 arthrodesis patients suffered a failure when treated with external fixators.

The surgical revision rate and complication rate in our total population was 37% (15/41 patients) at the time of follow-up, 4 patients of which had to undergo ablation as a last resort following reinfection/development of sepsis. The complication of recurrent infection with subsequent ablation as a last resort is not unusual in the literature^[11,14]. Therefore, it must be emphasised that only long-term results will show whether still living patients will have to undergo additional revisions up to amputation. Therefore, we think that knee joint arthrodesis does not provide definitive infection remediation in the long-term but serves as a measure for the temporary control or calming of the condition – although it may be efficient over a period of several years, similar to cases of chronic osteitis.

Compared to the general population, the quality of life of patients with knee joint arthrodesis is usually impaired due to comorbidities, and most of the patients present with ASA 3 classifications due to their advanced age and comorbidities^[2,16]. Our clinical results demonstrate that arthrodesis enables patients to climb stairs without support and to be pain-free. On the other hand, physical functionality remained clearly and significantly impaired due to the immobility of the knee joint compared to a healthy reference population with a similar age distribution^[20]. Our SF-36 results are comparable with data from previous studies^[16-18,26]: The mean SF-36 physical subscore was 30, and the mean psychological subscore was 51. This means that physical function in patients following arthrodesis was impaired in line with expectations, while the psychological status was similar to a reference population. Furthermore, a sub-analysis showed a relatively high score (52 points) for the item “pain”.

The mean WOMAC score in our patient population was 50 (out of a maximum of 100 points). This means that the results were clearly better, similar or worse compared to other follow-up studies with similar patient populations – with mean scores ranging from a minimum of 32 up to a maximum of 64^[25,26,29,33].

Studies comparing the different procedures in terms of functional outcomes and quality of life are rare. Chen *et al*^[1] described a clinical outcome in favour of arthrodesis compared to amputation (using the SF-12 questionnaire), with a small number of cases and a high loss to follow-up. Wu *et al*^[7] conducted an analysis of a systemic review and also recommended arthrodesis as the procedure of choice in patients with reinfection following two-stage knee prosthesis replacement.

Other studies focused on the leg length differences (mean values between 1.2 and 55 mm) when discussing their clinical outcomes^[14,16,25,34]. We did not find statistical evidence for this approach in our patient population: Both the leg length differences and the implanted device had no significant impact on the WOMAC and SF-36 outcomes.

Finally, the limitations of the study must be discussed: The evidence level of the retrospective case study is low (Level 4), and only 18/41 patients were available for clinical and radiological follow-up. The low follow-up rate is due to a high level of morbidity and mortality and is, therefore, not unusual. Other studies in this field were also characterised by a high “loss to follow-up”^[11,11].

Finally, the comparison between intramedullary and plate arthrodesis has limited validity due to their different indications for use. It would be desirable in the future to have substantially higher case numbers for prospective observations. A randomised study design with arthrodesis versus amputation is not acceptable from an ethical point of view. Finally, it must be emphasised that our data do not represent long-term results, and the rate of late amputations may further increase during the further course due to reinfections with implants in situ.

CONCLUSIONS

Knee joint arthrodesis is a suitable salvage procedure in patients with periprosthetic knee joint infections with loss of the extensor mechanism because it allows for the maintenance of a fully weight-bearing extremity and independent mobility without therapeutic appliances. We recommend the use of a so-called double-plate osteosynthesis in patients with minor bone loss and the use of a modular intramedullary prosthesis in larger defects. Both methods allow the achievement of a physically impaired but generally acceptable quality of life. The arthrodesis is prone to complications, and it is not always possible to prevent amputation during the further course.

CONFLICT OF INTEREST

The authors declare that they have no conflicts of interest.

REFERENCES

- 1 Chen AF, Kinback NC, Heyl AE, McClain EJ, Klatt BA. Better function for fusions versus above-the-knee amputations for recurrent periprosthetic knee infection. *Clin Orthop Relat Res* 2012; **470**: 2737-2745.
- 2 Conway JD, Mont MA, Bezwada HP. Arthrodesis of the knee. *J Bone Joint Surg Am* 2004; **86**: 835-848.
- 3 Maheshwari AV, Gioe TJ, Kalore NV, Cheng EY. Reinfection after prior staged reimplantation for septic total knee arthroplasty: is salvage still possible? *J Arthroplasty* 2010; **25 (Suppl)**: 92-97.
- 4 Göksan SB, Freeman MA. One-stage reimplantation for infected total knee arthroplasty. *J Bone Joint Surg Br* 1992; **74**: 78-82.
- 5 Haleem AA, Berry DJ, Hanssen AD. Mid-term to long-term followup of two-stage reimplantation for infected total knee arthroplasty. *Clin Orthop Relat Res* 2004; **428**: 35-39.
- 6 Hirakawa K, Stulberg BN, Wilde AH, Bauer TW, Secic M. Results of 2-stage reimplantation for infected total knee arthroplasty. *J Arthroplasty* 1998; **13**: 22-28.
- 7 Wu CH, Gray CF, Lee GC. Arthrodesis should be strongly considered after failed two-stage reimplantation TKA. *Clin Orthop Relat Res* 2014; **472**: 3295-3304.
- 8 Mortazavi SM, Vegari D, Ho A, Zmistowski B, Parvizi J. Two stage exchange arthroplasty for infected total knee arthroplasty:

- predictors of failure. *Clin Orthop Relat Res* 2011; 469: 3049-3054.
- 9 Hanssen AD, Trousdale RT, Osmon DR. Patient outcome with reinfection following reimplantation for the infected total knee arthroplasty. *Clin Orthop Relat Res* 1995; **321**: 55-67.
 - 10 Kim TW, Makani A, Choudhury R, Kamath AF, Lee GC. Patient-reported activity levels after successful treatment of infected total knee arthroplasty. *J Arthroplasty* 2012; **27**: 81-85.
 - 11 De Vil J, Almqvist KF, Vanheeren P, Boone B, Verdonk R. Knee arthrodesis with an intramedullary nail: a retrospective study. *Knee Surg Sports Traumatol Arthrosc* 2008; **16**: 645-650.
 - 12 David R, Shtarker H, Horesh Z, Tsur A, Soundry M. Arthrodesis with the Ilizarov device after failed knee arthroplasty. *Orthopedics* 2001; **24**: 33-36.
 - 13 Hak DJ, Liebermann JR, Finerman GA. Single plane and biplane external fixators for knee arthrodesis. *Clin Orthop Relat Res* 1995; **316**: 134-144.
 - 14 Bargiotas K, Wohlrab D, Sewecke JJ, Lavinge G, DeMeo PJ. Arthrodesis of the knee with a long intramedullary nail following the failure of a total knee arthroplasty as the result of infection. *J Bone Joint Surg Am* 2006; **88**: 553-558.
 - 15 Kuo AC, Meehan JP, Lee M. Knee fusion using dual platings with the locking compression plate. *J Arthroplasty* 2005; **20**: 772-776.
 - 16 Klinger HM, Spahn G, Schultz W, Baums MH. Arthrodesis of the knee after failed infected total knee arthroplasty. *Knee Surg Sports Traumatol Arthrosc* 2006; **14**: 447-453.
 - 17 Fuchs S, Mersmann A. Results of arthrodesis after knee prosthesis infection. Special reference to quality of life. *Unfallchirurg* 2000; **103**: 626-631.
 - 18 Crockarell JR, Mihalko MJ. Knee arthrodesis using an intramedullary nail. *J Arthroplasty* 2005; **20**: 703-708.
 - 19 Bellamy N, Buchanan WW, Goldsmith CH, Campbell J, Stitt LW. Validation study of WOMAC: a health status instrument for measuring clinically important patient relevant outcomes to anti-rheumatic drug therapy in patients with osteoarthritis of the hip or knee. *J Rheumatol* 1988; **15**: 1833-1840.
 - 20 Morfeld M, Kirchberger I, Bullinger M. SF-36 Fragebogen zum Gesundheitszustand. Deutsche Version des Short Form-36 Health Survey 2, ergänzte und überarbeitete Version. Manual Hogrefe Verlag, Göttingen, 2011.
 - 21 Sierra RJ, Trousdale RT, Pagnano MW. Above-the-knee amputation after a total knee replacement: prevalence, etiology, and functional outcome. *J Bone Joint Surg Am* 2003; **85**: 1000-1004.
 - 22 Pring DJ, Marks L, Angel JC. Mobility after amputation for failed knee replacement. *J Bone Joint Surg Br* 1988; **70**: 770-771.
 - 23 Isiklar ZU, Landon GC, Tullos HS. Amputation after failed total knee arthroplasty. *Clin Orthop Relat Res* 1994; **299**: 173-178.
 - 24 Spina M, Gualdrini G, Fosco M, Giunti A. Knee arthrodesis with the Ilizarov external fixator as treatment for septic failure of knee arthroplasty. *J Orthop Traumatol* 2010; **11**: 81-88.
 - 25 Garcia-Lopez I, Aguayo MA, Cuevas A, Navarro P, Prieto C, Carpintero P. Knee arthrodesis with the Vari-Wall nail for treatment of infected total knee arthroplasty. *Acta Orthop Belg* 2008; **74**: 809-815.
 - 26 Bargiotas K, Wohlrab D, Sewecke JJ, Lavinge G, Demeo PJ, Sotereanos NG. Arthrodesis of the knee with a long intramedullary nail following the failure of a total knee arthroplasty as the result of infection. *J Bone Joint Surg Am* 2006; **88**: 553-558.
 - 27 Waldman BJ, Mont MA, Payman KR, Freiberg AA, Windsor RE, Sculco TP, Hungerford DS. Infected total knee arthroplasty treated with arthrodesis using a modular nail. *Clin Orthop Relat Res* 1999; **367**: 230-237.
 - 28 Insall JN, Thompson FM, Brause BD. Two-stage reimplantation for the salvage of infected knee arthroplasty. *J Bone Joint Surg Am* 1983; **65**: 1087-1098.
 - 29 Mahmud T, Lyons MC, Naudie DD, Macdonald SJ, McCalden RW. Assessing the gold standard: a review of 253 two-stage revisions for infected TKA. *Clin Orthop Relat Res* 2012; **470**: 2730-2736.
 - 30 Lucas DB, Murray WR. Arthrodesis of the knee by double-plating. *J Bone Joint Surg Am* 1961; **43**: 795-808.
 - 31 Nichols SJ, Landon GC, Tullos HS. Arthrodesis with dual plates after failed total knee arthroplasty. *J Bone Joint Surg Am* 1991; **73**: 1020-1024.
 - 32 Harges J, von Eiff C, Streitbuenger A, Balke M, Budny T, Henrichs MP, Hauschild G, Ahrens H. Reduction of periprosthetic infection with silver-coated megaprotheses in patients with bone sarcoma. *J Surg Oncol* 2010; **101**: 389-395.
 - 33 Mabry TM, Jacofsky DJ, Haidukewych GJ, Hanssen AD. Comparison of intramedullary nailing and external fixation knee arthrodesis for the infected knee replacement. *Clin Orthop Relat Res* 2007; **464**: 11-15.
 - 34 Letartre R, Combes A, Autissier G, Bonneville N, Gougeon F. Knee arthrodesis using a modular customized intramedullary nail. *Orthop Traumatol Surg Res* 2009; **95**: 520-528.

Peer reviewer: Yale Fillingham, MD, Rush University Medical Center, Department of Orthopaedics, 1611 W. Harrison St., Suite 300, Chicago, IL 60657 USA.