

Natural History of Lumbar Spondylolysis-Advances and Concerns

Baogan Peng

Baogan Peng, Department of Spinal Surgery, General Hospital of Armed Police Force, Beijing 100039, China

Correspondence to: Baogan Peng, MD, PhD, Professor, Department of Spinal Surgery, Institute of Spinal Surgery, General Hospital of Armed Police Force, 69 Yongding Road, Beijing 100039, China.

Email: pengbaogan@163.com

Telephone: +86-10-57976611

Fax: +86-10-57976937

Received: April 17, 2016

Revised: June 8, 2016

Accepted: June 10, 2016

Published online: August 23, 2016

ABSTRACT

Lumbar spondylolysis is a common cause of low back pain in adolescents and young adults. Due to a lack of understanding to the natural history, its treatment is often chaotic and controversial. Lumbar spondylolisthesis is a common complication of spondylolysis, but slip progression was commonly small and slow according to long-term follow-up studies. Many predisposing risk factors have been identified as associated with a great chance of slip progression. However, the widely accepted mechanism leading to adult slip progression is related to disc degeneration at the slip level. Clinical decision made for patients presenting with spondylolysis and spondylolisthesis principally include concerns for future progression of the spondylolisthesis and issues concerning pain. Most patients with spondylolysis and/or spondylolisthesis respond to conservative treatment. Surgical treatment is generally thought for patients who fail to respond to conservative treatment.

Key words: Lumbar spondylolysis, Natural history, Epidemiology, Pathogenesis, Diagnosis, Treatment

© 2016 The Authors. Published by ACT Publishing Group Ltd.

Peng B. Natural History of Lumbar Spondylolysis-Advances and Concerns. *International Journal of Orthopaedics* 2016; 3(4): 591-594
Available from: URL: <http://www.ghrnet.org/index.php/ijo/article/view/1664>

INTRODUCTION

Lumbar spondylolysis is a defect in the pars interarticularis, and primarily involves the L5 vertebra, accounting for 85-95% of all cases (Figure 1). L4 vertebra is the next most commonly affected level, accounting for 5-15%, and more proximal lumbar levels are affected much less often^[1]. Lumbar spondylolysis almost always occurs bilaterally, thus dividing the vertebra into two parts. The anterosuperior part consists of the vertebral body with pedicles, transverse processes, and superior articular processes. The posteroinferior part consists of the inferior articular processes, laminae, and spinous process.

EPIDEMIOLOGY

The incidence of lumbar spondylolysis is amazing and has been estimated to be approximately 6% in the general population^[2]. However, the incidence varies considerably according to ethnicity and

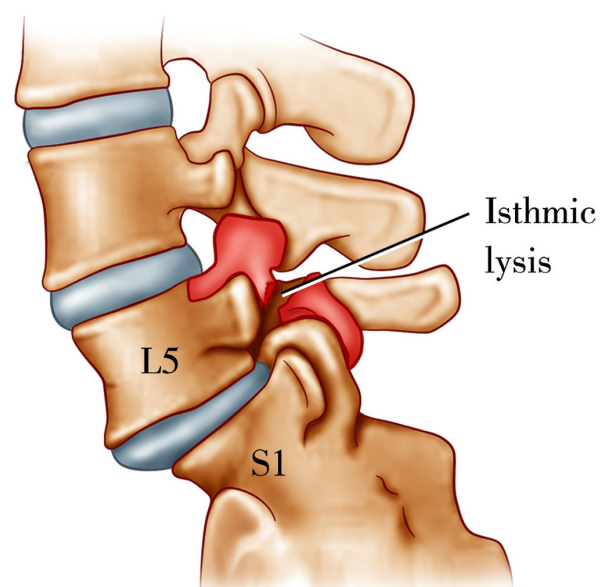


Figure 1 Diagram of L5 spondylolysis.

sex. A 2009 study by Kalichman *et al*^[3] utilizing CT imaging in an unselected community-based population demonstrated a prevalence of 11.5% in the United States. Also in the United States, Belfi *et al*^[4] found a 5.7% incidence of spondylolysis in 510 asymptomatic patients using abdominal and pelvic CT scans. The incidence of spondylolysis in the general Japanese population was 5.9%^[2]. Spondylolysis is more common in the Eskimo population with a high incidence of 50%^[5]. Most studies reported that the incidence is higher in male than in female. The incidence increased in young athletes, especially in those involved in sports requiring repetitive flexion/extension and/or hyperextension. Harvey *et al*^[6] reported an incidence of spondylolysis in the general population ranging from 4 to 8% that increased to 23-63% in those engaging in certain sporting activities.

PATHOGENESIS

The pathogenesis of lumbar spondylolysis remains controversial. The most probable mechanism of lumbar spondylolysis is multifactorial with a stress fracture occurring through a congenitally weak or dysplastic pars interarticularis^[6]. Originally, its pathology was considered to be congenital failure of fusion of two ossification centers or a hyperflexion injury at birth, but spondylolysis had never been founded in embryos, fetus and at birth^[7]. Several authors have reported a hereditary predisposition, citing a high rate of occurrence among family members, with an incidence of up to 69%^[8,9] as well as a strong association with spina bifida occulta^[10]. These reports lend credence to the theory of an underlying dysplasia, which may be characterized by hypoplasia and elongation or sclerosis of the pars interarticularis. Several authors have looked at the effects of mechanical loading on the pars interarticularis. The likely initiating event occurs when the patient engages in repeated extension and/or axial rotation maneuvers. Dysplasia would represent a factor that predisposes the patient to the occurrence of lysis, the actual onset of which would be triggered by the mechanical trauma^[9]. This pathogenetic sequence of events is supported by the fact that spondylolysis is most common at L5 level, which is the vertebra subjected to the greatest amount of stress associated with daily activities^[10].

NATURAL HISTORY

Lumbar spondylolysis may either occur asymptotically or be associated with significant low back pain. Symptomatic pars lesions appear to be particularly a clinical problem in adolescents, especially adolescent athletes^[11]. Treatment of spondylolysis has not been consistent^[12]. To accurately assess the effect of any therapy for treating spondylolysis, its natural history should be known beforehand. However, until now, no pathological characteristic could be used to predict the disease course. In an important study of 500 first grade children, the prevalence of spondylolysis was 4.4%. When the subjects were followed to adulthood, the incidence rose to 6%^[13]. Therefore, two-thirds of adults with spondylolysis developed it prior to reaching school age. The remaining third acquired the defect at some point during childhood or adolescence.

Spondylolysis diminishes the stabilizing ability of the posterior elements in the spinal motion segment and may lead to isthmic spondylolisthesis. Spondylolisthesis is a common complication of spondylolysis. Approximately 25% of radiographically detected spondylolysis is accompanied by spondylolisthesis^[13]. About 70% of patients finally occur spondylolisthesis^[4]. Under Meyerding's classification system, the grade of spondylolisthesis is determined by the degree of slippage^[14]. A grade 5 lesion (in which there is 100%

displacement) has been characterized more recently, and is referred to as spondyloptosis^[15]. The degree of slippage is calculated by the ratio between the anterosuperior diameter of the sacrum and the distance of previous slippage of vertebra L5. Thus, it can be considered: grade I - 25% or less, grade II between 25% and 50%, grade III - between 50% and 75%, and grade IV - greater than 75%. The degree V, as spondyloptosis, does not belong to the original description (Figure 2).

When discussing the natural history of spondylolysis and spondylolisthesis, two important questions need to be concerned: how frequently does the slippage in spondylolisthesis progress? How often is pain a problem? Beutler *et al*^[16] carried out a 45-year follow-up evaluation for the natural history of spondylolysis and spondylolisthesis in a population unselected for pain. They found that progression of spondylolisthesis slowed with each decade, and no subject has reached a 40% slip. Ohmori *et al*^[17] studies 22 adult patients with spondylolysis. When comparing the initial presentation with follow-up approximately 12 years later, they found that of 18 patients without a listhesis initially, 13 still had no slip, and 5 had progressed to an average of 16.6% slip. There was only an average of 6% increase in slip among those patients who had anterolisthesis initially. Saraste^[18] in a study of at least 20 years in 255 patients with spondylolysis and spondylolisthesis found that the slip progression was small and not correlated to age at diagnosis and initial degree of slip. The mean slip was 7.0 mm initially, and the average progression over the observation period was only 4.0 mm.

The progression of spondylolysis to spondylolisthesis is most likely to occur in adolescents younger than 16 years of age and exhibits a marked tendency to slow down with age^[13]. However, the mechanism of slippage in the immature lumbar spine is still unclear. Farfan *et al*^[19] suggested that the mechanically weakest site

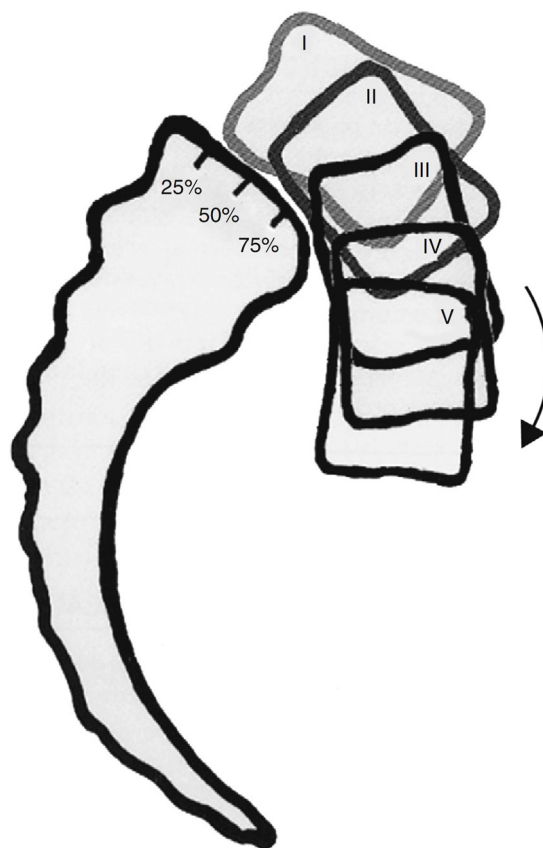


Figure 2 Meyerding's classification system.

is the growth zone in the vertebral endplate. They hypothesized that pediatric spondylolisthesis may occur after epiphyseal separation. Also, Sairyo *et al*^[20] suggested that spondylolysis changes the spine kinematics leading to stress concentration at the growth plate during lumbar motion. Over time, the accumulation of the stresses may lead to physis stress fracture at the vertebral body and eventually spondylolisthesis. The literature appears that slippage progression is usually minimal after skeletal maturity^[16].

Many predisposing risk factors have been identified as associated with a great chance of progression. Two commonly seen radiographic parameters originally thought to increase the risk of slip are dome-shaped sacrum and trapezoidal L5. These morphological changes are frequently seen in association with spondylolysis and spondylolisthesis, but they have no predictive value. They seem to be the result of spondylolysis and spondylolisthesis rather its cause^[21]. Recent studies elucidate that epiphyseal injury in the juvenile spine is a determining factor for progression and a cause for abnormal morphology^[21]. The amount of lumbosacral kyphosis, or the slippage angle, especially when severe, is associated with progression in the growing child^[22]. According to Boxal *et al*^[23] the best parameter to predict progression is a great slippage angle (> 55°). This angle is formed by the intersection of a line drawn parallel to the inferior face of L5 and a perpendicular to the posterior face of the body of S1. The widely accepted mechanism leading to adult slip progression is related to disc degeneration at the slip level. It seems that disc degeneration is a key aspect in the conversion of stable spondylolisthesis to a symptomatic unstable progressive slip^[9].

However, we need bear in mind that the data derived from the above-mentioned studies of natural history of spondylolysis using only plain radiography need to be interpreted with caution, as clearly many cases of spondylolysis identified by some of the newer imaging techniques are not noted concurrently on plain films. This difference may alter the way we view the natural history and treatment of spondylolysis.

Pain is the most common initial symptom. Symptoms were correlated to radiographic pathology. Risk factors for severe low back pain and need for treatment were great than 25% slipping, low lumbar index in L5 spondylolysis, spondylolysis at the L4, increased lumbar lordosis, early disc degeneration and early beginning of symptoms^[18]. In the absence of one of these factors the risk of low back pain in adulthood is not greater than in the normal population.

DIAGNOSIS AND TREATMENT

How can spondylolysis be correlated to low back pain? An active pars lesion that can be either an impending stress fracture or a newly completed one may indicate a painful spondylolysis. Early spondylolysis has been described as a stress reaction evidenced by increased signal intensity on T2 weighted images, indicating bone marrow edema secondary to pars microfractures. Acute fracture also may demonstrate bone marrow edema along with disruption of the cortex^[24]. Single photon emission computed tomography (SPECT) has consistently been showed to be more sensitive than plain radiography and planar bone scan alone. Studies have found that a positive bone scan or SPECT correlates with a painful pars lesion^[10]. Impending stress fractures are negative on plain radiography or CT scan but show high radionuclide uptake on bone scintigraphy. A new stress fracture would be seen on radiography and would be hot on bone scintigraphy. Asymptomatic pars lesions are not likely to be undergoing high levels of osteoblastic activity at the defect area, so the ability to achieve osseous healing is unlikely. Early diagnosis of

lumbar spondylolysis is important regarding management decisions since stress reactions, incomplete, or complete acute fractures can respond to conservative treatment. Conversely, delayed diagnosis and treatment may progress to a non-union. A pars defect develops into a chronic non-union, and becomes bridged by tissue composed of a combination of fibrous, cartilaginous, or osseous material. In this circumstance, the origin of chronic low back pain could be in the scar and connective tissue rich in nociceptive nerve endings that bridge the gap of the pars defect^[25]. Extra load exerted on the motion segment may cause disc degeneration, which is therefore an accompanying disorder of spondylolysis. The prevalence of progressive disc degeneration in the involved level is markedly increased in the adult spondylolytic patients who often appear low back pain later in life, after an asymptomatic childhood.

Clinical decision made for patients presenting with spondylolysis and spondylolisthesis principally include concerns for future progression of the spondylolisthesis and issues concerning pain. Most patients with spondylolysis and/or spondylolisthesis respond to conservative treatment. Management will differ depending on the clinical presentation of the patient. In an asymptomatic spondylolytic patient, treatment of any sort will not be necessary. Cessation of aggravating sporting activities and a spinal brace are necessary for promoting osseous healing for the patients with stress reactions, incomplete, or complete acute fractures in the area of the pars. It is estimated that between 75 and 100% of acute lesions heal, all unilateral acute lesions heal, 50% of acute bilateral lesions heal, and no chronic lesions heal^[26]. Conservative treatment for adults with symptomatic spondylolysis and/or spondylolisthesis may have benefit. However, osseous healing is impossible, because the evidence from histological specimens showed that the spondylolytic gap is filled with fibrofatty tissue and dense collagenous scar which is consistent with a pars pseudoarthrosis^[25]. The surgical treatment for spondylolysis and/or spondylolisthesis is generally thought for patients who fail to respond to conservative treatment. The methods of surgical treatment are varied and multiple. Evaluation of which surgical methods yield the best results is beyond the scope of this paper. Clearly, further clinical study of spondylolysis is needed, particularly longitudinal studies to enhance our understanding of the natural history of this disorder and controlled clinical trials to study the type and extent of treatment necessary to optimize patient outcomes.

ACKNOWLEDGMENTS

No conflict of interest or financial interest was declared.

REFERENCES

- 1 Saraste H. Spondylolysis and spondylolisthesis. *Acta Orthop Scand Suppl* 1993; **251**: 84-86
- 2 Sakai T, Sairyo K, Suzue N, Kosaka H, Yasui N. Incidence and etiology of lumbar spondylolysis: review of the literature. *J Orthop Sci* 2010; **15**: 281-288
- 3 Kalichman L, Kim DH, Li L, Guermazi A, Berkin V, Hunter DJ. Spondylolysis and spondylolisthesis: Prevalence and association with low back pain in the adult community-based population. *Spine* 2009; **34**: 199-205
- 4 Belfi LM, Ortiz AO, Katz DS. Computed tomography evaluation of spondylolysis and spondylolisthesis in asymptomatic patients. *Spine* 2006; **31**: E907-E910
- 5 Simper LB. Spondylolysis in Eskimo skeletons. *Acta Orthop Scand* 1986; **57**: 78-80

Peng B. Natural history of lumbar spondylolysis

- 6 Harvey CJ, Richenberg JL, Saifuddin A, Wolman RL. The radiological investigation of lumbar spondylolysis. *Clin Radiol* 1998; **53**: 723-728
- 7 Saraste H. Long-term clinical and radiological follow-up of spondylolysis and spondylolisthesis. *J Pediatr Orthop* 1987; **7**: 631-638
- 8 Wiltse LL. Etiology of spondylolisthesis. *Clin Orthop* 1957; **10**: 48-60
- 9 Albanese M, Pizzutillo PD. Family study of spondylolysis and spondylolisthesis. *J Pediatr Orthop* 1982; **2**: 496-499
- 10 Lenone A, Cianfoni A, Cerase A, Magarcelli N, Bonomo. Lumbar spondylolysis: a review. *Skeletal Radiol* 2011; **40**: 683-700
- 11 Foreman P, Griessenauer CJ, Watanabe K, et al L5 spondylolysis/spondylolisthesis: a comprehensive review with an anatomic focus. *Childs Nerv Syst* 2013; **29**: 209-216
- 12 Rassi GE, Takemitsu M, Glutting J, Ahah SA. Effect of sports modification on clinical outcome in children and adolescent athletes with symptomatic lumbar spondylolysis. *Am J Phys Med Rehabil* 2013; **92**: 1070-1074
- 13 Standaert CJ, Herring SA. Expert opinion and controversies in sports and musculoskeletal medicine: the diagnosis and treatment of spondylolysis in adolescent athletes. *Arch Phys Med Rehabil* 2007; **88**: 537-540
- 14 Fredrickson BE, Baker D, McHolick WJ, Yuan HA, Lubicky JP. The natural history of spondylolysis and spondylolisthesis. *J Bone Joint Surg Am* 1984; **66**: 699-707
- 15 Meyerding HW. Spondylolisthesis. *Bone Joint Surg* 1931; **13**: 39-48
- 16 Sairyo K, Goel VK, Masuda A, et al. Three dimensional finite element analysis of the pediatric lumbar spine. Part II: biomechanical change as the initiating factor for pediatric isthmic spondylolisthesis at the growth plate. *Eur Spine J* 2006; **15**: 930-935
- 17 Ohmori K, Ishida Y, Takatsu T, Inoue H, Suzuki K. Vertebral slip in lumbar spondylolysis and spondylolisthesis. Long-term follow-up of 22 adult patients. *J Bone Joint Surg Br* 1995; **77**: 771-773
- 18 Saraste H. Long-term clinical and radiological follow-up of spondylolysis and spondylolisthesis. *J Pediatr Orthop* 1987; **7**: 631-638
- 19 Farfan HF, Osteria V, Lamy C. The mechanical etiology of spondylolysis and spondylolisthesis. *Clin Orthop* 1976; **117**: 40-55
- 20 Beutler WJ, Fredrickson BE, Murtland A, Sweeney CA, Grant WD, Baker D. The natural history of spondylolysis and spondylolisthesis: 45-year follow-up evaluation. *Spine* 2003; **28**: 1072-1035
- 21 Haun DW, Kettner NW. Spondylolysis and spondylolisthesis: a narrative review of etiology, diagnosis, and conservative management. *J Chiropr Med* 2005; **4**: 206-217
- 22 Lonstein JE. Spondylolisthesis in children: cause, natural history, and management. *Spine* 1999; **24**: 2640-2648
- 23 Boxall D, Bradford DS, Winter RB, Moe JH. Management of severe spondylolisthesis in children and adolescents. *J Bone Joint Surg Am* 1979; **61(4)**: 479-495
- 24 Goda Y, Sakai T, Sakamaki T, Takata Y, Higashino K, Sairyo K. Analysis of MRI signal changes in the adjacent pedicle of adolescent patients with fresh lumbar spondylolysis. *Eur Spine J* 2014; **23**: 1892-1895
- 25 Schneiderman GA, McLain RF, Hambly MF, Nielsen SL. The pars defect as a pain source. A histologic study. *Spine* 1995; **20**: 1761-1764
- 26 Hu SS, Tribus CB, Diab M, Ghanayem AJ. Spondylolisthesis and spondylolysis. *J Bone Joint Surg Am* 2008; **90**: 656-671

Peer reviewers: Andrei Fernandes Joaquim, MD, PhD, Department of Neurology, Campus Universitário Zeferino Vaz, Barão Geraldo, Campinas - SP, Brazil; Chi Heon Kim, Associate Professor, MD, PhD, Department of Neurosurgery, Seoul National University Hospital, 101 Daehak-Ro, Jongno-Gu, Seoul, South Korea.