

## Fatty Infiltration of Rotator Muscles: A Comparison of Cuff Tear Arthropathy and Glenohumeral Osteoarthritis

Nathan L. Scott, MD, MPP, Julie Glowacki, PhD, Laurence D. Higgins, MD, MBA

Nathan L. Scott, Julie Glowacki, Laurence D. Higgins, Department of Orthopedic Surgery, Brigham and Women's Hospital, Harvard Medical School, Boston, MA, the United States

Correspondence to: Laurence D. Higgins, Department of Orthopedic Surgery, Brigham and Women's Hospital, Harvard Medical School, Boston, MA, the United States.

Email: LDHiggins@partners.org

Telephone: +1-617-735-9273

Fax: +1-617-730-2810

Received: May 12, 2016

Revised: July 18, 2016

Accepted: July 21, 2016

Published online: August 23, 2016

### ABSTRACT

**BACKGROUND:** Rotator cuff tear arthropathy (CTA) and glenohumeral osteoarthritis (OA) are age-related chronic diseases of the shoulder representing debilitating, painful conditions with functional loss. Surgical intervention provides the most reliable treatment, but studies have shown that prognosis is contingent upon a variety of factors, one of the most reliable of which is fatty infiltration of the rotator cuff muscles. This study tests the hypothesis that fatty infiltration (FI) is increased in CTA subjects compared with OA subjects.

**METHODS:** CTA subjects ( $n = 22$ , age  $71.9 \pm 7.8$  years) and OA subjects ( $n = 22$ , age  $62.9 \pm 9.6$  years) were evaluated for extent of fatty infiltration by Magnetic Resonance Imaging (MRI) and Computed Tomography (CT) imaging using Goutallier's classification system and a novel scoring system of % FI.

**RESULTS:** Goutallier classification showed that FI of the supraspinatus and infraspinatus rotator cuff muscles in CTA subjects was greater than those in OA subjects ( $p = 0.0001$ ,  $p = 0.003$ , respectively). The % FI method revealed similar results ( $p = 0.003$ ,  $p = 0.0008$ , respectively). Neither classification system revealed significant differences in FI for the subscapularis or teres minor cuff muscles (Goutallier:  $p = 0.123$ ,  $p = 0.890$ ; % FI:  $p = 0.142$ ,  $p = 0.666$ , respectively). Analysis using age-matched controls revealed similar results. There was a strong correlation in scores for the two

classification systems (Spearman  $r = 0.96$ ,  $p < 0.0001$ ).

**CONCLUSION:** Extent of fatty infiltration of the rotator cuff muscles in subjects suffering from rotator cuff tear arthropathy is significantly greater than in subjects with osteoarthritis.

Level of evidence: Level IV, Case Controlled.

**Key words:** Cuff Tear Arthropathy, Fatty Infiltration, Glenohumeral Osteoarthritis, Goutallier Classification

© 2016 The Authors. Published by ACT Publishing Group Ltd.

Scott NL, Glowacki J, Higgins LD. Fatty Infiltration of Rotator Muscles: A Comparison of Cuff Tear Arthropathy and Glenohumeral Osteoarthritis. *International Journal of Orthopaedics* 2016; 3(4): 616-620 Available from: URL: <http://www.ghrnet.org/index.php/ijo/article/view/1726>

### INTRODUCTION

Rotator cuff tear arthropathy (CTA) and glenohumeral osteoarthritis (OA) are age-related chronic diseases of the shoulder that often leave patients in debilitating pain and at functional loss<sup>[1]</sup>. CTA was first described by Neer et al. in 1983 as a complex shoulder syndrome that occurs after a massive rotator cuff tear<sup>[2]</sup>. He postulated that the development of CTA involves both intrinsic ("nutritional") and extrinsic ("mechanical") pathologies, with only approximately 4% of tears eventually developing diagnostic CTA<sup>[2]</sup>. Radiographically, CTA is characterized by three essential features: rotator cuff insufficiency, degenerative changes of the glenohumeral joint, and superior migration of the humeral head<sup>[2]</sup>. Glenohumeral OA, which is not typically associated with tendon rupture, occurs secondary to chronic biomechanical stress on the articular cartilage<sup>[3]</sup>. It presents radiographically with glenohumeral joint-space narrowing and the formation of osteophytes on the humeral head<sup>[4]</sup>.

For each of these disorders, if conservative treatment fails, surgical intervention is the recommended treatment. Surgeons currently use prognostic indicators to predict patients' ability to tolerate surgery with respect to functional outcome, ability to heal, and patient satisfaction<sup>[5]</sup>. One of the best prognostic indicators currently used for

CTA is fatty infiltration of the muscle<sup>[5-7]</sup>.

Fatty infiltration is a progressive process in which fat accumulates throughout the muscle belly: intrafascicularly, extrafascicularly, and intratendinously<sup>[8]</sup>. It has been suggested that in CTA, retraction of the muscle belly after tendon rupture initiates biomechanical changes that creates space between muscle fibers and subsequent opportunity for adipogenesis<sup>[9]</sup>. There is also a significant relationship between suprascapular nerve compression and fatty infiltration<sup>[10]</sup>. For OA, Millett *et al.* report an association between the production of inferior humeral osteophytes and axillary nerve entrapment causing fatty infiltration<sup>[11]</sup>. Goutallier *et al.* were the first to quantify fatty infiltration with a classification system based on computed tomography (CT) imaging<sup>[12]</sup>. That system was later found to be reliable for magnetic resonance imaging (MRI)<sup>[13]</sup>.

Clinical studies have shown that the extent of FI is associated with poor prognosis and high failure rates in many shoulder pathologies<sup>[12,14-17]</sup>. It is an independent predictor of cuff tear severity, is correlated with patient age, is typically progressive, and is associated with poor healing and poor post-surgical outcome with anatomical prostheses<sup>[12,16,18-21]</sup>. Goutallier *et al.*<sup>[12]</sup> and Gladstone *et al.*<sup>[20]</sup> reported that increased fatty infiltration of the infraspinatus was correlated with poor pre- and post-operative function in patients with rotator cuff tears. Lapner *et al.* reported significantly increased extent of pre- vs. post-arthroplasty FI using Goutallier grade, as well as an association with lower strength in patients with OA<sup>[22]</sup>. There have been other studies that show correlations between FI severity and poor surgical outcome<sup>[6,7,16,18,19,23,24]</sup>.

Despite the advances in measuring FI infiltration and its relation to shoulder disease, it is not understood how it occurs in some but not all cuff tears. A literature search did not reveal studies that compare FI in CTA with OA or other chronic shoulder diseases particularly with respect to the teres minor and subscapularis. This study compares rotator cuff FI in patients with CTA and glenohumeral OA; it uses the Goutallier grading system and a novel measurement of % FI in each muscles.

## MATERIALS AND METHODS

### Study Design

This study was approved by the institution's IRB. Consecutive subjects were enrolled after diagnoses of rotator CTA or shoulder OA were made. Pre-surgical shoulder abduction strength was measured with a Lafayette Manual Muscle Tester Dynamometer (Lafayette, IN, USA). Testing was standardized by having the subject sit with both shoulders in approximately 90° abduction and 45° of

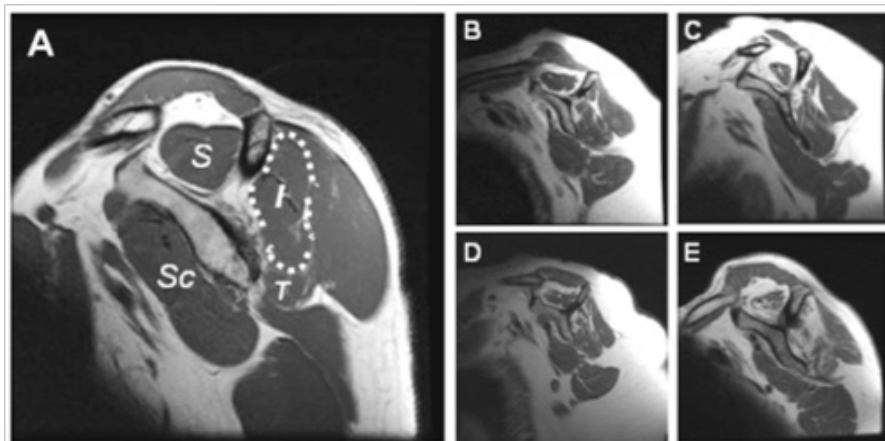
horizontal abduction (elbows fully extended and palms facing down). Dynamometers were placed on each distal arm at the lateral humeral epicondyle to measure force in kilograms upon abduction. The extent of fatty infiltration of the rotator cuff muscles (supraspinatus, infraspinatus, subscapularis, and teres minor) was evaluated with pre-surgical T-1 weighted magnetic resonance imaging (MRI,  $n = 28$ ) and computed tomography (CT,  $n = 16$ ) images. Images were obtained from the study institution's hospital records, affiliated institutions, or from referring institutions. In one case, MRI prints were used to evaluate the cuff muscles. For each subject, the sagittal cross section of the MRI that was most lateral (revealing the scapular spine and coracoid process in contact with the body of the scapula) was evaluated with the Picture Archiving and Communication System imaging database. Muscle atrophy of the supraspinatus was evaluated using the tangent sign technique<sup>[13]</sup>. Two methods of analysis were used to assess the extent of fatty infiltration of the four cuff muscles. Three trained observers made evaluations independently without knowledge of the diagnosis.

### Goutallier Classification

Extent of fatty infiltration was graded with either the MRI-based system<sup>[13]</sup> or the CT-based Goutallier Classification System<sup>[12]</sup>. These are ordinal ranking systems that have been validated to classify fatty infiltration: Grade 0: no fat; Grade 1: fatty streaks; Grade 2: more muscle than fat; Grade 3: equal muscle and fat; Grade 4: more fat than muscle. A grade of 0 to 4 was assigned from a cross section of the MRI or CT image that was determined by three observers to represent the relative fat and muscle content of each rotator cuff muscle individually (Figure 1). Intraobserver reliability was analyzed with the Wilcoxon matched pairs signed-ranks test. When one observer was not in agreement with the other two, that value was discarded. For the total dataset, there was agreement among the observers for the infraspinatus  $p = 0.235$ , subscapularis  $p = 0.821$ , and teres minor  $p = 0.365$ , but not for the supraspinatus  $p = 0.0054$ . The difference found in the supraspinatus is likely due to the extent of atrophy in this muscle, reducing its area and changing the area of fat relative to atrophic changes. In addition, CT images have less contrast for differentiating fat and atrophy. Intraobserver agreement for the supraspinatus was established when using only MRI data (supraspinatus  $p = 0.074$ ).

### % Fatty Infiltration

A continuous scale of percent fatty infiltration (% FI) was developed in order to expand statistical testing. The observers used the identical cross section of the MRI or CT that was used in the Goutallier system



**Figure 1** T1-weighted sagittal MRI images of the rotator cuff muscles. I = Infraspinatus, S = Supraspinatus, Sc = Subscapularis, T = Teres Minor. The infraspinatus is outlined (white dots). Fatty infiltration of the infraspinatus was evaluated with the Goutallier and percent classification systems for these representative images: A) Grade 0, 0%; B) Grade 1, 10%; C) Grade 2, 30%; D) Grade 3, 50%; E) Grade 4, 90%.

to estimate percentage of fatty infiltration to increments of 5 percent for each rotator cuff muscle individually (Figure 1). There was intraobserver agreement for the subscapularis and teres minor ( $p = 0.330$ ,  $p = 0.999$ , respectively). The supraspinatus and infraspinatus muscles, however, revealed difference among observers ( $p = 0.001$ ,  $p = 0.0007$ , respectively). This is likely due to extent of atrophy, as above. When one observer was not in agreement with the other two, that value was discarded.

**Statistical Analysis**

Group data are presented as mean values  $\pm$  SD when determined by the Kolmogorov and Smirnov Test to be parametric, and as median values with 25 to 75% confidence intervals when non-parametric. Unpaired t-tests and non-parametric analysis using the Mann-Whitney test and Spearman Correlation tests were conducted to determine statistical significance between OA and CTA subjects. A value of  $p < 0.05$  was considered significant. All data were analyzed using Graphpad InStat® (GraphPad Software, Inc., La Jolla, CA).

**RESULTS**

**Demographics**

There were 22 CTA subjects (6 males and 16 females) and 22 OA subjects (13 males and 9 females) (Table 1). The mean age of the CTA cohort was  $71.9 \pm 7.8$  years (Females:  $72.4 \pm 7.9$ ; Males:  $70.7 \pm 8.1$ ) and that of the OA cohort was  $62.9 \pm 9.6$  (F:  $62.6 \pm 9.1$ ; M:  $62.5 \pm 10.8$ ). The mean ages were significantly different ( $p < 0.001$ ) and attributable to the older females in the CTA group than in the OA group ( $p < 0.010$ ). Shoulder abduction strength was statistically similar for CTA and OA subjects (CTA:  $0.35 \text{ kg} \pm 0.31$ ; OA:  $0.63 \pm 0.22$ ,  $p = 0.072$ ). The presence of atrophy in the supraspinatus was significantly higher in the CTA cohort (%) compared with the OA cohort (%) ( $p < 0.0006$ ).

**Comparison of Fatty Infiltration of Rotator Cuff Muscles in CTA and OA Subjects**

Two systems, Goutallier’s classification and % FI, were used to evaluate the extent of fatty infiltration of the rotator cuff muscles with MRI/CT images from all CTA ( $n = 22$ ) and OA ( $n = 22$ ) subjects (Figure 2). The Goutallier classification system indicated that FI of the infraspinatus and supraspinatus rotator cuff muscles in CTA subjects was greater than those in OA subjects ( $p = 0.0027$ ,  $p = 0.0001$ , respectively). The % FI method also showed that FI of the infraspinatus and supraspinatus rotator cuff muscles in CTA subjects was greater than those in OA subjects ( $p = 0.0008$ ,  $p = 0.003$ , respectively).

Neither classification system revealed significant differences in FI for the subscapularis and teres minor muscles (Goutallier  $p = 0.123$ ,  $p = 0.890$ ; % FI  $p = 0.142$ ,  $p = 0.666$ , respectively). Although not significant, FI was greater in both of those muscles in CTA subjects compared with OA subjects according to each classification system. There was a strong correlation for scores with each classification system (Spearman  $r = 0.96$ ,  $p < 0.0001$ ). In the total dataset, however, there was a significant difference in average age of the CTA cohort ( $71.9 \pm 7.8$ ) and the OA cohort ( $62.9 \pm 9.6$ ,  $p < 0.001$ ) (Table 1).

**Age-Matched Analysis of Fatty Infiltration**

A subset of subjects was used to control for age (Figure 3). There was no significant difference between the age of the age-matched CTA subjects ( $n = 18$ ,  $69.4 \pm 6.1$ ) and OA subjects ( $n = 18$ ,  $65.6 \pm 8.3$ ,  $p = 0.119$ ). Results of statistical analysis for FI in age-matched subjects were similar to the results for the group not controlled

Table 1 Demographic and statistical analyses for Fatty Infiltration in CTA and OA cohorts†.

	CTA	OA	p-value
Total N	22	22	
Sex, N (%)			
Male	6 (27%)	13 (59%)	0.067‡
Female	16 (73%)	9 (41%)	
Age, Mean (SD)	71.9 (7.8)	62.9 (9.6)	0.001§
Male	70.7 (8.1)	62.5 (10.8)	0.117§
Female	72.4 (7.9)	62.6 (9.1)	0.010§
Shoulder Abduction Strength (kg)	0.35 (0.31)	0.63 (0.22)	0.072§
CTA, n=5; OA, n=9			
Atrophy			<0.0001‡
Yes	15 (83%)	4 (18%)	
No	3 (17%)	18 (82%)	
<b>Goutallier Classification Grade, Median (25,75 % CI)</b>			
Infraspinatus	3.5 (1,4)	1 (0,2)	0.003¶
Supraspinatus	2 (1,2)	0 (0,1)	0.0001¶
Subscapularis	1 (0,1)	0 (0,1)	0.123¶
Teres Minor	0 (0,0)	0 (0,1)	0.890¶
<b>% Fatty Infiltration, Median (25,75 % CI)</b>			
Infraspinatus	52.5 (10,75)	5 (0,20)	0.0008¶
Supraspinatus	25 (5,40)	0 (0,5)	0.003¶
Subscapularis	5 (0,15)	0 (0,5)	0.142¶
Teres Minor	0 (0,5)	0 (0,5)	0.666¶

† Abbreviations: FI: Fatty Infiltration, CTA=Cuff Tear Arthropathy, OA=Osteoarthritis, N=Number, SD=Standard Deviation, kg=kilogram, CI=Confidence Interval  
‡Fisher’s exact test  
§ T-test  
¶ Mann-Whitney test

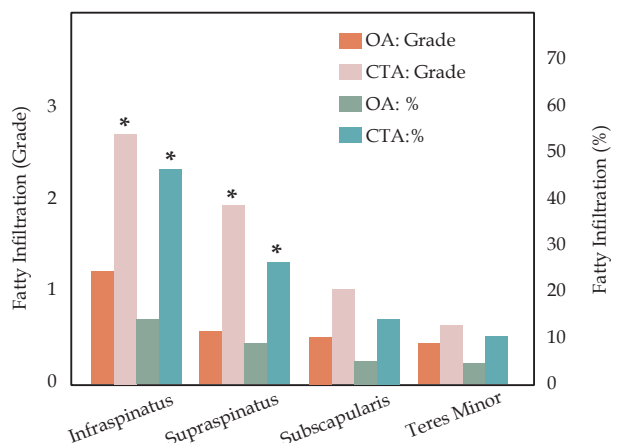


Figure 2 Median values of fatty infiltration of the rotator cuff muscles using the Goutallier and percent classification systems for all cuff tear arthropathy (CTA) and osteoarthritis (OA) subjects. \* denotes statistical significance between CTA and OA,  $p < 0.01$ .

for age. Infraspinatus and supraspinatus FI were greater in CTA subjects compared with OA subjects according to both classification methodologies (Goutallier  $p = 0.006$ ,  $p < 0.0001$ , respectively; % FI  $p = 0.002$ ,  $p < 0.0001$ , respectively). Comparison of Goutallier and % FI for the infraspinatus muscle (Figure 3A, B) revealed a range from 55% to 95% for those graded equally as Grade 4. Neither classification system revealed significant differences in FI for the subscapularis and teres minor (Goutallier  $p = 0.076$ ,  $p = 0.593$ , respectively; % FI  $p = 0.088$ ,  $p = 0.1772$ , respectively).

**DISCUSSION**

The results of this study indicate that fatty infiltration (FI) of the rotator cuff muscles in subjects diagnosed with CTA is greater than in subjects with OA. FI is a clinically-significant prognostic indicator for treatment decisions and outcomes<sup>[22,25-28]</sup>.

This study population matches that of previously studied CTA populations. Shoulder abduction strength was normal, and atrophy was most commonly associated with the supraspinatus muscle, as previously reported<sup>[29]</sup>.

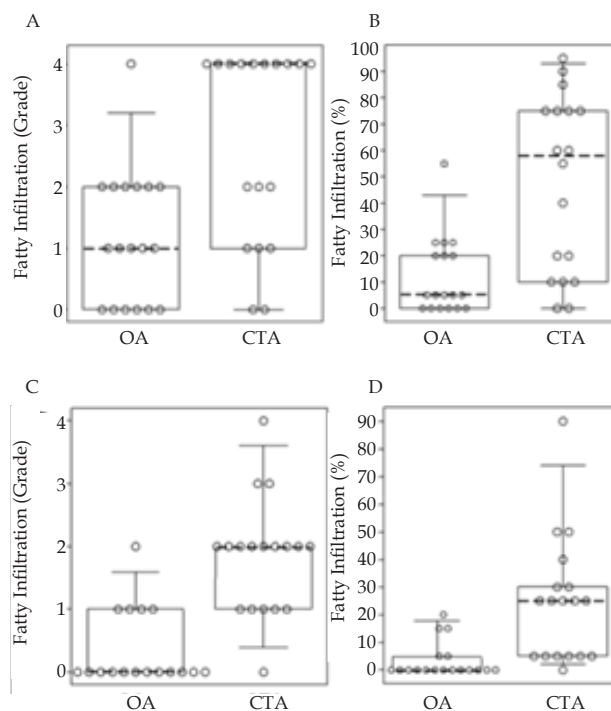
These data further demonstrate the specificity of FI in chronic shoulder disease. We demonstrated greater FI in subjects with CTA compared with OA when using the Goutallier classification method and FI as a percent of muscle cross-sectional area. Despite the clinical and radiographic distinctions between CTA and OA, FI can occur in any shoulder pathology and is correlated with negative functional and surgical outcome<sup>[22,25-28]</sup>. Our results agree with other studies in that FI most commonly affects the supraspinatus, followed by the infraspinatus<sup>[30]</sup>. The Goutallier and percentage fatty infiltration systems revealed significantly greater levels of fatty infiltration in each of these muscles for CTA subjects. When controlling for age, the conclusions remained consistent; age may not play an important factor in these cohorts.

Surgical repair, in the form of either conventional or reverse shoulder arthroplasty, is the traditional definitive treatment for both OA and CTA respectively. Studies have found that surgical repair improves not only functional outcome, but pain relief as well. Studies also indicate that positive surgical outcomes can be more reliably achieved in CTA patients with Goutallier FI grades less than 4, and the functional status of the teres minor is highly correlated with a positive clinical outcome<sup>[14,20,21,31]</sup>. Despite this largely accepted theory, Burkhart *et al.* showed that arthroscopic rotator cuff repair in patients with grade three or four may provide functional improvement for patients between 50-75% infiltration; this suggests the need for a more quantitative fatty infiltration classification system<sup>[30]</sup>.

This finding is relevant to our cohort because greater than 50% of our subjects with CTA had a Goutallier grade of 4, a large portion of which fell between 51-75% using the % FI grading system (median of 52.5). This observation suggests that further analysis may challenge whether grade 4 CTA subjects should be non-surgical candidates or candidates for reverse prostheses. Using this criterion may limit effective treatment for patients who may otherwise gain utility from arthroscopic surgical intervention. Finally, Shin *et al.* reported on a series of patients imaged 24 hours after rotator cuff repair with MRI<sup>[32]</sup>. That study demonstrated that there was a uniform improvement in the Goutallier score of at least one grade when detached tendons were repaired to the tuberosity. This further questions the currently employed system and should prompt a rigorous re-evaluation of the current recommendations for conservative, arthroscopic or reconstructive surgical management.

Limitations to this study include the size of the cohorts, which may have reduced the ability to reveal the true magnitude of differences between each variable studied in our assessment. Second, we did not include degree of tear, tear patterns, the muscles involved in injury, tendon retraction length, or time components in our analysis. The purpose of this study was to compare FI in subjects with a diagnosis of CTA or OA, regardless of those mechanisms. Further analysis of these variables may shed more light on treatment and prognostic differences.

To our knowledge, no studies have defined a relationship between fatty infiltration and CTA versus OA, including analysis of the subscapularis and teres minor. Because outcomes of shoulder arthroplasty, whether they are reverse or conventional, depend greatly on the status of the rotator cuff, a careful analysis of each muscle for integrity and fatty infiltration should be performed on a case by case basis. For example, grade 4 fatty infiltration of the subscapularis with clinical dysfunction will preclude conventional shoulder arthroplasty



**Figure 3** Comparison of fatty infiltration in shoulder muscles for age-matched subjects with osteoarthritis (OA) or cuff tear arthropathy (CTA). Box-plots show fatty infiltration values for the (A, B) infraspinatus and (C, D) supraspinatus muscles, evaluated by (A, C) Goutallier and (B, D) percent classification systems. Median values (dashed line), 25%-75% confidence intervals (box), and 5%-95% confidence intervals (whiskers) represent age-matched subjects [OA:  $n = 18$ ; CTA:  $n = 18$ ], with individual subject scores (circles). Each difference between OA and CTA was statistically significant,  $p < 0.01$ .

but not eliminate reverse shoulder arthroplasty. Key questions that remain include the pathogenesis, prevention and reversal of fatty infiltration, in order to support optimum clinical outcomes.

## CONCLUSIONS

This study shows that the extent of fatty infiltration in rotator cuff muscles (infraspinatus and supraspinatus) is higher in subjects with CTA than in those with glenohumeral OA within this study population of patients at a tertiary referral center. This information has the potential to direct molecular research in the characterization of mechanisms of fatty infiltration and their association with CTA. Given the well-established prognostic value of FI, complete understanding of the pathophysiological mechanisms of FI may ultimately lead to better diagnostic evaluation, treatment decisions, and outcomes for subjects with CTA.

## ACKNOWLEDGMENTS

This research was supported by a grant from the Orthopaedic Research and Education Foundation.

## CONFLICT OF INTEREST

The Authors declare that there is no conflict of interest.

## REFERENCES

- 1 Millett PJ, Wilcox RB, O'Holleran JD, Warner JJP. Rehabilitation of the rotator cuff: an evaluation-based approach. *J Am Acad Orthop*

- Surg* 2006; 14: 599-609.
2. Neer CS, Craig E V, Fukuda H. Cuff-tear arthropathy. *J Bone Joint Surg Am* 1983; 65: 1232-1244.
  3. Ray A, Ray BK. An inflammation-responsive transcription factor in the pathophysiology of osteoarthritis. *Biorheology* 2008; 45: 399-409.
  4. Braun H, Gold G. Diagnosis of osteoarthritis: Imaging. *Bone* 2012; 51: 278-288.
  5. Edwards TB, Boulahia A, Kempf J-F, Boileau P, Nemoz C, Walch G. The influence of rotator cuff disease on the results of shoulder arthroplasty for primary osteoarthritis: results of a multicenter study. *J Bone Joint Surg Am* 2002; 84: 2240-2248.
  6. Fuchs B, Weishaupt D, Zanetti M, Hodler J, Gerber C. Fatty degeneration of the muscles of the rotator cuff: assessment by computed tomography versus magnetic resonance imaging. *J Shoulder Elbow Surg* 1999; 8: 599-605.
  7. Gerber C, Schneeberger AG, Hoppeler H, Meyer DC. Correlation of atrophy and fatty infiltration on strength and integrity of rotator cuff repairs: A study in thirteen patients. *J Shoulder Elb Surg* 2007; 16: 691-696.
  8. Kang J, Gupta R. Mechanisms of fatty degeneration in massive rotator cuff tears. *J Shoulder Elb Surg* 2012; 21: 175-180.
  9. Meyer D, Hoppeler H, von Rechenberg B, Gerber C. A pathomechanical concept explains muscle loss and fatty muscular changes following surgical tendon release. *J Orthop Res* 2004; 22: 1004-1007.
  10. Nam D, Maak TG, Raphael BS, Kepler CK, Cross MB, Warren RF. Rotator cuff tear arthropathy: evaluation, diagnosis, and treatment: AAOS exhibit selection. *J Bone Joint Surg Am* 2012; 94: e34.
  11. Millett PJ, Schoenahl JY, Allen MJ, Motta T, Gaskill TR. An association between the inferior humeral head osteophyte and teres minor fatty infiltration: Evidence for axillary nerve entrapment in glenohumeral osteoarthritis. *J Shoulder Elb Surg* 2013; 22: 215-221.
  12. Goutallier D, Postel JM, Bernageau J, Lavau L, Voisin MC. Fatty muscle degeneration in cuff ruptures. Pre- and postoperative evaluation by CT scan. *Clin Orthop Relat Res* 1994; 304: 78-83.
  13. Zanetti M, Gerber C, Hodler J. Quantitative assessment of the muscles of the rotator cuff with magnetic resonance imaging. *Invest Radiol* 1998; 33: 163-170.
  14. DeFranco M, Bershadsky B, Ciccone J, Yum J, Iannotti J. Functional outcome of arthroscopic rotator cuff repairs: a correlation of anatomic and clinical results. *J Shoulder Elb Surg* 2007; 16: 759-765.
  15. Gazielly DF, Gleyze P, Montagnon C. Functional and anatomical results after rotator cuff repair. *Clin Orthop Relat Res* 1994; 304: 43-53.
  16. Gerber C, Fuchs B, Hodler J. The results of repair of massive tears of the rotator cuff. *J Bone Joint Surg Am* 2000; 82: 505-515.
  17. Mellado JM, Calmet J, Olona M, Esteve C, Camins A, Pérez Del Palomar L, Giné J, Sauri A. Surgically repaired massive rotator cuff tears: MRI of tendon integrity, muscle fatty degeneration, and muscle atrophy correlated with intraoperative and clinical findings. *Am J Roentgenol* 2005; 184: 1456-1463.
  18. Barry J, Lansdown D, Cheung S, Feeley B, MA C. The relationship between tear severity, fatty infiltration, and muscle atrophy in the supraspinatus. *J Shoulder Elb Surg* 2013; 22: 18-25.
  19. Cheung S, Dillon E, Tham S, Feeley BT, Link TM, Steinbach L, Ma CB. The presence of fatty infiltration in the infraspinatus: its relation with the condition of the supraspinatus tendon. *Arthroscopy* 2011; 27: 463-470.
  20. Gladstone JN, Bishop JY, Lo IKY, Flatow EL. Fatty infiltration and atrophy of the rotator cuff do not improve after rotator cuff repair and correlate with poor functional outcome. *Am J Sports Med* 2007; 35: 719-728.
  21. Melis B, DeFranco MJ, Chuinard C, Walch G. Natural history of fatty infiltration and atrophy of the supraspinatus muscle in rotator cuff tears. *Clin Orthop Relat Res* 2010; 468: 1498-1505.
  22. Lapner P, Sabri E, Rakhra K, Bell K, Athwal G. Healing rates and subscapularis fatty infiltration after lesser tuberosity osteotomy versus subscapularis peel for exposure during shoulder arthroplasty. *J Shoulder Elb Surg* 2013; 22: 396-402.
  23. Fuchs B, Gilbert MK, Hodler J, Gerber C. Clinical and structural results of open repair of an isolated one-tendon tear of the rotator cuff. *J Bone Joint Surg Am* 2006; 88: 309-316.
  24. Lapner PLC, Jiang L, Zhang T, Athwal GS. Rotator cuff fatty infiltration and atrophy are associated with functional outcomes in anatomic shoulder arthroplasty. *Clin Orthop Relat Res* 2015; 473: 674-682.
  25. Macaulay AA, Greiwe RM, Bigliani LU. Rotator cuff deficient arthritis of the glenohumeral joint. *Clin Orthop Surg* 2010; 2: 196-202.
  26. Laron D, Samagh S, Liu X, Kim H, Feeley B. Muscle degeneration in rotator cuff tears. *J Shoulder Elb Surg* 2012; 21: 164-174.
  27. Wildemann B, Klatt F. Biological aspects of rotator cuff healing. *Muscles Ligaments Tendons J* 2011; 1: 161-168.
  28. Zingg P, Jost B, Sukthankar A, Buhler M, Pfirrmann C, Gerber C. Clinical and structural outcomes of nonoperative management of massive rotator cuff tears. *J Bone Jt Surg Am* 2007; 89: 1328-1334.
  29. Vitosky J, Basamania C, Seebauer L, Rockwood C, Jensen K. Cuff tear arthropathy: pathogenesis, classification, and algorithm for treatment. *J Bone Jt Surgery Am* 2004; 86: 35-40.
  30. Burkhart S, Barth J, Richards D, Zlatkin M, Larsen M. Arthroscopic repair of massive rotator cuff tears with stage 3 and 4 fatty degeneration. *Arthroscopy* 2007; 23: 347-354.
  31. Simovitch R, Helmy N, Zumstein M, Gerber C. Impact of fatty infiltration of the teres minor muscle on the outcome of reverse total shoulder arthroplasty. *J Bone Jt Surg Am* 2007; 89: 934-939.
  32. Jo C, Shin J. Changes in appearance of fatty infiltration and muscle atrophy of rotator cuff muscles on magnetic resonance imaging after rotator cuff repair: establishing new time-zero traits. *Arthroscopy* 2013; 29: 449-458.
- Peer reviewers:** Maurice Balke, Department of Sports traumatology, Cologne Merheim Medical Center, University of Witten/Herdecke, Ostmerheimer Str. 200, 51109 Köln, Germany; Anestis Iossifidis, Consultant In Trauma & Orthopaedic surgery, Orthopaedic Surgery, Croydon University Hospital, 530 London Road, Croydon CR7 7YE, London, UK.