

An Alternative Technique for Repair of Patellar Ligament Ruptures with Associated Tibial Tuberosity Avulsion Fracture

Aniruddha Pendse, David Bruce, Ramesh Chennagiri, Raghubir Kankate

Aniruddha Pendse, David Bruce, Ramesh Chennagiri, Raghubir Kankate, Stoke Mandeville Hospital, Aylesbury, United Kingdom, HP21 8AL

Aniruddha Pendse, David Bruce, Ramesh Chennagiri, Raghubir Kankate, Wycombe General Hospital, High Wycombe, United Kingdom, HP11 2TT

Correspondence to: Aniruddha Pendse, Buckinghamshire Healthcare NHS Trust, Wycombe General Hospital and Stoke Mandeville Hospital, Buckinghamshire, 20, Braeside Naphill, High Wycombe, Buckinghamshire, HP14 4RY, United Kingdom.

Email: adpendse@gmail.com

Telephone: +0044-7824698014

Received: August 16, 2016

Revised: September 7, 2016

Accepted: September 9, 2016

Published online: October 27, 2016

ABSTRACT

We describe a case report of a patient who suffered dual injury to the patellar tendon insertion treated with an alternative technique for the repair of patellar ligament rupture with concomitant tibial tuberosity avulsion. These injuries are rare and there is no uniform technique, described to deal with this complex injury. In this report we describe an alternative technique which provides with secure fixation of the tendon allowing for early rehabilitation. It is simple and reproducible yet provides a robust fixation of the tendon injury allowing to restore the normal anatomical parameters. This technique avoids the need for neutralization box stitch to be passed through the quadriceps tendon, avoiding violation of intact tissue and large surgical wounds. To our knowledge, this method has not been previously described.

Key words: Tibial tuberosity fracture; Patellar tendon avulsion; Reconstruction technique

© 2016 The Authors. Published by ACT Publishing Group Ltd.

Pendse A, Bruce D, Chennagiri R, Kankate R. An Alternative Technique for Repair of Patellar Ligament Ruptures with Associated

Tibial Tuberosity Avulsion Fracture. *International Journal of Orthopaedics* 2016; 3(5): 647-649 Available from: URL: <http://www.ghrnet.org/index.php/ijo/article/view/1828>

Ethics

The patient and his mother gave written informed consent as per Trust guidelines on Ethics, for the publication of this work and there is no conflict of interest.

INTRODUCTION

Tibial tubercle avulsion fracture is an uncommon injury^[1]. Concomitant distal patellar tendon avulsions are even rarer and only 15 previous cases have been reported in the literature. These injuries can be described by the Ogden system^[2]. Frankl *et al*^[3] added a further modification, to include type C injury, which incorporated tibial tubercle avulsion fractures with associated patellar tendon ruptures. The injury pattern observed in our case report was a type IIC.

CASE REPORT

A sixteen year old boy sustained a sudden deceleration injury to his right knee, while playing football. Examination confirmed an extensor mechanism injury and radiographs revealed a high riding patella with a tibial tubercle fracture, rotated by 180 degrees (Figure 1). The dual injury of patella tendon rupture and tibial tubercle avulsion was confirmed intra operatively and he underwent surgical repair by AP (author). Following four weeks in a cylinder cast, he underwent accelerated physiotherapy, using a locked DonJoy brace (DJO Global Inc, CA USA). He was allowed unrestricted flexion at 8 weeks.

At nine months post-injury, isokinetic testing (Cybex Inc, NY, USA) showed that right knee extension at 60 degrees per second had 85% of peak torque compared with the left (129 Nm compared to 152 Nm). A similar reduction of peak torque was seen for knee flexion. Range of motion was 0 to 130 degrees on the right. He returned to sporting activities at 9 months, with ongoing programme for muscle strengthening. He had the screws removed 14 months after the original procedure, following full recovery. Sound healing

of the bone tendon interface was confirmed intra-operatively.

Surgical Technique

The procedure was performed under general anaesthesia and tourniquet control. The patient was positioned supine on a radiolucent table. A 8 cm midline incision was made over the tibial tuberosity. The intra-operative findings were of type IIC injury. The patellar tendon had completely avulsed from the tuberosity which was rotated by a 180 degrees (Figure 1). There were no intact periosteal remnants between the tendon and the bony insertion. It was observed that there were no retinacular tears or extension. The tibial tuberosity fragment measuring 3 × 4 cm, was anatomically fixed with two 4 mm Asnis cannulated screws (Stryker, MI, USA) under image intensifier.

The patellar tendon was then repaired with this technique of primary stabilization through a bone tunnel with reinforcement by a stop suture in neutralization mode (Figure 2A). The technique circumvented the need for the usual box stitch passed proximally though the quadriceps tendon or the patella itself. For the primary repair, number 2 fiber wire sutures, were used to place two Krakow whip sutures along medial and lateral thirds of the patella tendon. A 2 mm hole was drilled across the tibial spine 1 centimeter distal to the level of the avulsed fragment. Central most limb of each suture pair was passed through the drill hole from either side in preparation to be tied to the contralateral suture limb.

A third fiber wire whip suture was placed in the middle third of the patellar tendon. A unicortical 4 mm Asnis cannulated screw and washer was inserted in the midline 30 mm distal from the tuberosity fragment. It was seated incompletely to allow the central suture to be tied around it before final screw tightening.

Under image intensification control, the primary repair was accomplished by tying the contralateral suture limbs ensuring the patella tendon: patella length (LT: LP) ratio was restored as the contralateral uninjured side and Blumensaat's line touched the inferior patellar pole (Figure 2B). The repair augmentation was then completed by tying the central neutralization suture around the distal screw and the screw finally tightened down to lock the suture under the washer. This technique helped us in setting and then maintaining the tension in the repair. Three whip sutures provided uniform tension across the entire cross section of the patellar tendon and minimized the risk of repair failure and tendon lengthening.

The patient was placed in a cylinder cast for the first four weeks allowing full weight bearing. This was followed by a Don Joy brace and accelerated supervised physiotherapy. The brace was locked at 0-60° from 4-6 weeks and at 0-90° degrees from 6-8 weeks. He was allowed unrestricted flexion at the 8 week stage. He was regularly assessed in the clinics and underwent Cybex muscle strength testing prior to commencing unrestricted sporting activities.

DISCUSSION

Injury to the tibial tuberosity is well described in the adolescent athletes but concomitant rupture of the patellar ligament is much rarer, as in this case. The mechanism of injury occurs with quadriceps contraction, initially avulsing the apophysis of the tibial tubercle followed by distal patellar ligament avulsion from sustained contraction^[4]. This can occur in the context of knee flexion against a contracted quadriceps, or quadriceps contraction when the foot is fixed on the ground^[5]. The importance of repairing both injuries to maintain knee extension is emphasized^[4].

Combined tibial tuberosity avulsion and patellar ligament rupture

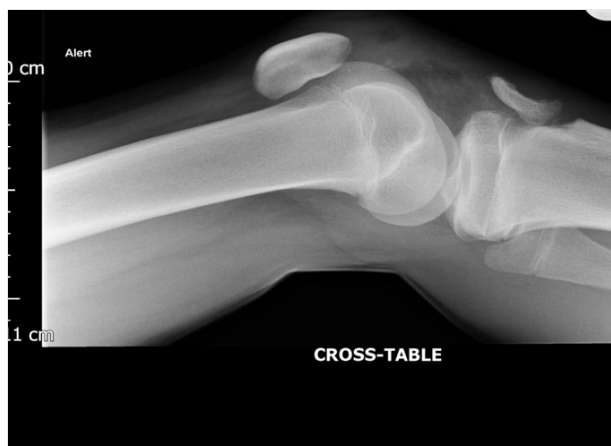

Figure 1 Trauma radiograph of the knee demonstrating tibial tuberosity avulsion with the fragment rotated 180° and patella alta.

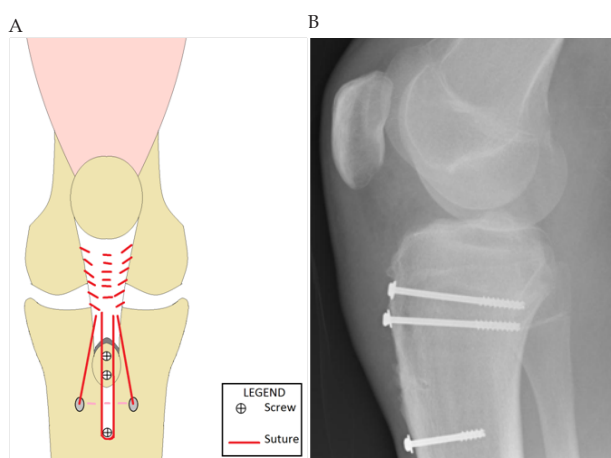


Figure 2 (A) Diagram of repair: the grey area of tendon represents the tendon rupture at its distal insertion. The tibial tuberosity fragment is held with two 4mmAsnis, screws. Two suture pairs along either edge of the tendon are tied, through a bone tunnel (pale dotted line) after passing one of the pair of suture limb (one closer to midline) to the contralateral side. The repair is reinforced with a central neutralization suture tied around a distal midline screw with washer, after achieving satisfactory patellar height, to maintain the tension of the repair. (B) Post-operative lateral radiograph of right knee showing fixation.

is rare^[6] and few operative techniques have been documented to reconstruct both of these structures simultaneously. The patellar tendon can be drawn over the anterior surface of the tibial tuberosity and both structures then fixed with a cancellous screw, reinforced by repair of surrounding fascia and periosteum^[5]. However, we feel this technique causes crushing of the tendon tissue under the screw head and effective shortening of the tendon with a risk of patella baja. Alternatively, the tibial tubercle can be reduced and held with a screw and the tendon then sutured into the periosteum of the tibia^[4]. Bone anchors have been used to attach the tendon around the tubercle^[7], however we feel this would not provide the same security to the fixation without a box stitch passed through proximal extensor mechanism. An alternative is Kirschner wires to hold the tuberosity fragment, which are removed after several weeks of adequate bone healing^[6].

Our technique involves standard fixation of the tibial tubercle with cannulated screws, repair of the patella tendon with sutures anchored into a bone tunnel, and a final neutralization suture centrally anchored around a distal midline tibial screw. This reinforcement stitch acts

as a box stitch traditionally passed further proximally through the quadriceps tendon. Compared to previous methods, it does not require tendon or bone grafts, allows controlled adjustment of tension in the tendon and prevents discrepancy in the length of patella tendon. We feel this offers advantages in terms of reduced trauma to surrounding tissues, less stiffness and a robust repair.

Post-operatively, the knee is immobilised either using a cast or other external device and usually augmented with neutralisation wires^[8]. Duration of immobilization is varied in literature with some reports of using an above knee cast for up to seven weeks^[4,6]. Due to the robust nature of our repair, we felt we could expedite recovery with early well directed physiotherapy and mobilization exercises. The Cybex measurements of peak torque showed that the deficit in knee extension was similar to that of knee flexion, suggesting that a proportion of the loss of strength is due to lack of focused physiotherapy input which was corrected. This recovery of muscle strength compares well to the 40% deficit noted after treatment of a similar injury reported in literature^[7]. Early, considered physiotherapy is a vital component of management.

The security of our fixation method and early physiotherapy allowed the patient to participate in early rehabilitation. Our technique enables adaptable and secure repair of complex injuries of the patella tendon and tibial tuberosity with a rapid recovery and avoiding the need for a proximal anchorage.

CONFLICT OF INTEREST

The author(s) declare(s) that there is no conflict of interest regarding the publication of this paper.

REFERENCES

- 1 Bolesta MJ, Fitch RD. Tibial tubercle avulsions. *J Paediatric Orthop* 1986; **6**: 186-192.
- 2 Ogden JA, Tross RB, Murphy MJ. Fractures of tibial tuberosity in adolescents. *J Bone Joint Surg Am* 1980; **62**: 205-215
- 3 Frankl U, Wasilewski SA, Healy WL. Avulsion fracture of tibial tubercle with avulsion of the patellar ligament report of two cases. *J Bone Joint Surg Am* 1990; **72**: 1411-1413
- 4 Mayba I. Avulsion fracture of the tibial tubercle apophysis with avulsion of patellar ligament. *Journal of Pediatric Orthopaedics* 1982; **2(3)**: 303-306.
- 5 Goodier DN, Maffulli N, Good J. Tibial tuberosity avulsion associated with patellar tendon avulsion. *Acta Orthop Belg* 1994; **60(2)**: 235-237.
- 6 Boyle MJ, Dawe CJ. Avulsion fracture of the tibial tuberosity with associated proximal patellar ligament avulsion. A case report and literature review. *Injury Extra* 2011; **42(2)**: 22-24.
- 7 McMains MC, Virk S, Fisk E, Fajolu O, Flanigan DC. Simultaneous rupture of patella tendon with tibial tubercle avulsion fracture, anterior cruciate ligament avulsion fracture of the tibial spine in a skeletally mature patient: A case report. *Sport Exerc Med Open J* 2015; **1(1)**: 22-26.
- 8 Edwards TB, Lewis JE, Guanche CA. Patellar tendon and tibial tubercle reconstruction using quadriceps tendon with patellar bone plug autograft. *Journal of orthopaedic trauma* 1997; **11(4)**: 304-307.

Peer reviewer: Paphon Sa-ngasoongsong, MD, Department of Orthopedics, Faculty of Medicine, Ramathibodi Hospital, Bangkok, 10400, Thailand.