

## Surgical Hip Dislocation for Treatment of Slipped Capital Femoral Epiphysis

Mohammed Elmarghany, Tarek M. Abd El-Ghaffar, Mahmoud Seddik, Ahmed Akar, Yousef Gad, Eissa Ragheb, Alessandro Aprato, Alessandro Massè

Mohammed Elmarghany, Tarek M. Abd El-Ghaffar, Mahmoud Seddik, Ahmed Akar, Yousef Gad, Eissa Ragheb, Department of Orthopedic, Alazhar University hospitals, Cairo, 11675, Egypt  
Alessandro Aprato, Alessandro Massè, Centro traumatologico ortopedico hospital, TO, San Luigi hospital of Orbassano, TO, Faculty of Medicine and Surgery, University of Turin, Turin, 10126, Italy

**Conflict-of-interest statement:** The author(s) declare(s) that there is no conflict of interest regarding the publication of this paper.

**Open-Access:** This article is an open-access article which was selected by an in-house editor and fully peer-reviewed by external reviewers. It is distributed in accordance with the Creative Commons Attribution Non Commercial (CC BY-NC 4.0) license, which permits others to distribute, remix, adapt, build upon this work non-commercially, and license their derivative works on different terms, provided the original work is properly cited and the use is non-commercial. See: <http://creativecommons.org/licenses/by-nc/4.0/>

**Correspondence to:** Mohammed Elmarghany, Department of Orthopedic, Alazhar University hospitals, Cairo, 11675, Egypt.  
**Email:** mohammedelmerghany@yahoo.com  
**Telephone:** +201141341426  
**Fax:** +2-25128927

**Received:** September 26, 2016  
**Revised:** November 11, 2016  
**Accepted:** November 14, 2016  
**Published online:** December 28, 2016

### ABSTRACT

**BACKGROUND:** Surgical procedures with use of traditional techniques to relocate the proximal femoral epiphysis in the treatment of slipped upper femoral epiphysis are allied with a high rate of femoral head osteonecrosis. Therefore, most surgeons advocate in situ fixation of the slipped epiphysis with acceptance of any persistent deformity in the proximal femur. This residual deformity can lead to osteoarthritis due to femoroacetabular cam impingement.

**OBJECTIVE:** The primary aim of our study was to report the

results of the technique of capital realignment with Ganz surgical hip dislocation and its reproducibility to restore hip anatomy and function.

**PATIENTS AND METHODS:** This prospective case series study included thirty patients (32 hips, 13 Lt hip, 19 Rt hip) with stable chronic slipped capital femoral epiphysis after surgical correction with a modified Dunn procedure. This study included 22 males and 8 females. The mean age of our patients was 14 years (10-18 years). The mean duration of symptoms before the operation was  $4.56 \pm 2.5$  month. Mean follow up period was 14.5 month (6-36 months). The mean preoperative Alpha angle was  $97.850 \pm 13$ . The mean preoperative Slip angle was  $52.50 \pm 14.6$ . Harris hip score was done for all patients pre operatively and its mean was  $67 \pm 9.3$ , mean WOMAC score was  $88.4 \pm 3.8$ , mean Merle d'Aubigne score was  $12 \pm 1$ .

**RESULTS:** 30 hips had excellent and good clinical and radiographic outcomes with respect to hip function and radiographic parameters. 2 patients had fair to poor clinical outcome including 3 patients who developed AVN. The difference between those who developed AVN and those who didn't develop AVN was statistically significant in postoperative clinical scores ( $p = 0.000$ ). The mean slip angle of the femoral head was  $52.50 \pm 14.6$  preoperatively and was corrected to a mean value of  $5.60 \pm 8.20$  with mean correction  $46.850 \pm 14.90$  ( $p = 0.000$ ). Mean postoperative Alpha angle was  $51.150 \pm 4.20$  with mean correction of  $46.70 \pm 14.20$  ( $p = 0.000$ ). Post operative flexion was  $111.90 \pm 19.050$ . Post operative IR in 90 degree flexion was  $41.60 \pm 9.6$ . Post operative ER in 90 0 flexion was  $45.60 \pm 9.97$ . In our series mean postoperative HHS was ( $96.16 \pm 9.7$ ) and mean improvement was ( $29.6 \pm 9.6$ ) ( $p = 0.000$ ). Mean WOMAC score was ( $3.3 \pm 3.5$ ) and mean improvement was ( $85.12 \pm 4.7$ ) ( $p = 0.000$ ). Mean Merle d'Aubigne score was ( $16.8 \pm 2.4$ ) and mean improvement was ( $4.8 \pm 2.4$ ) ( $p = 0.000$ ) and as regard to Haymann and Hernodon score 30/32 hips were good and excellent results.

**CONCLUSIONS:** the modified Dunn procedure allows to restore the normal proximal femoral anatomy by complete correction of the slip angle. This technique may reduce the probability of secondary osteoarthritis and femoroacetabular cam impingement.

**Key words:** SCFE; Hip; Surgical hip dislocation

© 2016 The Author(s). Published by ACT Publishing Group Ltd.

Elmarghany M, Abd El-Ghaffar TM, Seddik M, Akar M, Gad Y, Raghieb E, Aprato A, Massè A. Surgical Hip Dislocation for Treatment of Slipped Capital Femoral Epiphysis. *International Journal of Orthopaedics* 2016; 3(6): 662-671 Available from: URL: <http://www.ghrnet.org/index.php/ijo/article/view/1848>

## INTRODUCTION

Slipped capital femoral epiphysis (SCFE) is a well known disorder of the hip in adolescents that is characterized by translation of the upper femoral epiphysis from the metaphysis through the physis<sup>[1]</sup>. Ernst Müller in 1888 was the first to describe this condition. An incidence from 0.2 (Japan) to 10 (United States) per 100,000 was reported<sup>[2]</sup>.

The term slipped capital femoral epiphysis is a misnomer as the epiphysis is held in the acetabulum by the ligamentum teres, and thus it is actually the metaphysis that moves upward and outward while the epiphysis remains in the acetabulum<sup>[1]</sup>. In most patients, there is an apparent varus relationship between the head and the neck, but occasionally the slip is into a valgus position, with the epiphysis displaced superiorly in relation to the neck<sup>[2]</sup>.

The failure develops through the growth plate, creating a three-dimensional deformity, with the distal fragment in varus in the coronal plane, in extension in the sagittal plane, and in external rotation in the axial plane<sup>[2]</sup>.

In the vast majority of cases, the etiology is unknown. Multiple theories have been proposed for the etiology of idiopathic SCFE, and it is likely a result of both biomechanical and biochemical factors<sup>[3]</sup>, the combination of these factors results in a weakened physis with subsequent failure<sup>[4]</sup>. SCFE may be associated with a known endocrine disorder<sup>[5]</sup>, renal failure osteodystrophy<sup>[6]</sup>, or with previous radiation therapy<sup>[7]</sup>, this factors may be also high risk for bilateralism. Some studies have shown that parathyroid hormone (PTH) and 1, 25-dihydroxyvitamin D [1, 25-(OH)<sup>2</sup>D] are involved in growth-plate chondrogenesis and matrix mineralization. Levels of 1, 25-(OH)<sup>2</sup>D were also significantly lower in patients with SCFE. The deficiency of M-PTH or 1, 25-(OH)<sup>2</sup>D during the growth spurt could result in SCFE<sup>[6]</sup>.

Slipped capital femoral epiphysis is classified according to both the clinical nature and the magnitude of the disorder. The traditional clinical classification of Fahey<sup>[8]</sup> includes pre-slip, acute, chronic and acute-on-chronic. The preferred clinical classification system for SCFE is the Loder<sup>[9]</sup> classification which classifies patients into stable and unstable on the basis of the patient's ability to bear weight.

Two radiographic classification systems are used. The Wilson<sup>[10]</sup> classification is based on relative displacement of the epiphysis on the metaphysis. The other method described by Southwick<sup>[11]</sup> measures epiphyseal–shaft angle (slip angle).

In slipped capital femoral epiphyses (SCFE), severity of slippage correlates with poor long-term clinical outcome scores and radiographic evidence of osteoarthritis<sup>[3]</sup>. In situ fixation of higher-grade SCFE has a low surgical risk<sup>[12]</sup> and has been advocated by authors who believe the deformed hip has the potential to remodel with some restoration of the disturbed anatomic axes<sup>[13,14]</sup>, however the remodeling potential remains controversial<sup>[15]</sup>.

Despite remodeling, the head-neck offset will remain abnormal<sup>[16]</sup>. This is the cause of potential impingement of the femoral neck with the acetabular cartilage<sup>[17]</sup>. Impingement in SCFE has been associated with damage of the acetabular cartilage, which may explain early onset of osteoarthritis after SCFE<sup>[18]</sup>. The additional complication with SCFE is the relatively high incidence of Avascular Necrosis (AVN), a devastating complication leading to significant disability in

this young patients<sup>[19]</sup>.

Slipped capital femoral epiphysis leads to early osteoarthritis resulting from FAI. Impingement in SCFE has been associated with damage of the acetabular cartilage, which may explain early onset of osteoarthritis after SCFE. In slipped capital femoral epiphysis (SCFE), severity of slippage correlates with poor long-term clinical outcome<sup>[18]</sup>.

Realignment procedures for treatment of SCFE are subcapital, basicervical, intertrochanteric, and subtrochanteric levels. Osteonecrosis as a complication of the surgery is rare in stable SCFE pinned in situ. The risk of necrosis has been described as almost reciprocally proportional to the distance of correction from the physis, a phenomenon that can be explained by the vulnerability of the blood supply to the epiphysis<sup>[19]</sup>.

The realignment procedures at the level of the deformity (i.e., subcapital level) can result in anatomic or near anatomic restoration of the proximal femur. As such, it is believed they offer the best chance of correcting the anatomic deformities that can lead to early osteoarthritis<sup>[20]</sup>.

To reduce the risk for osteonecrosis of the epiphysis during capital reorientation, tension of the posterolateral retinaculum, containing the end branches of the medial femoral circumflex artery is markedly reduced by wedge resection of varying size and location<sup>[21]</sup>.

The surgical hip dislocation technique, which originally described by Ganz, allow restoration of normal anatomy of proximal femur with complete correction of the slip angle, such that probability of secondary osteoarthritis and cam type FAI may be minimized it also allows direct inspection and preservation of physeal blood supply<sup>[22]</sup>.

Any child with an SCFE and open physis needs treatment; without stabilization, progression is inevitable, so once a slipped capital femoral epiphysis has been diagnosed, treatment is indicated to prevent progression of the slip<sup>[15]</sup>.

The introduction of a safe method to surgically dislocate the hip has been proposed and applied to the SCFE patient to improve on the current treatment strategies to prevent Femoro-Acetabular Impingement (FAI). In comparison to the cuneiform osteotomy, which require substantial femoral neck shortening to ensure tension-free correction of the femoral epiphysis modified Dunn osteotomy allows safe reduction by removal of the posterior callus and thinning of the femoral neck and hence should minimize leg length differences<sup>[23]</sup>.

The hip joint can be surgically dislocated using other approaches; however, the Ganz method of surgical hip dislocation has several advantages. As the abductor is detached by trochanteric flip osteotomy rigid fixation of this flip fragment by screws restores immediate stability and allows for early mobilization of the patient. Direct inspection and preservation of physeal blood supply and inspection of intra-articular pathology which can be evaluated and treated at the time<sup>[24]</sup>.

## MATERIALS AND METHODS

From October 2013 to October 2016 a prospective case series study was undergone at Alazhar university hospitals (Al-Hussein and Sayed Galal hospitals), Cairo, Egypt and in Torino university hospitals (C.T.O hospital and San Luigi Regione Gonzole hospital), Torino, Italy on patients with stable slipped capital femoral epiphysis treated with modified Dunn procedure. Nine patients were treated in Egypt while 23 patients were treated in Italy. Patients with established necrosis before the procedure, with other medical conditions such as renal insufficiency and unstable slippage or acute traumatic SCFE were

excluded from our study.

This prospective case series study included thirty patients (32 hips, 13 Lt hip, 19 Rt hip) with stable chronic slipped capital femoral epiphysis after surgical correction with a modified Dunn procedure. This study included 22 males and 8 females. The mean age of our patients was 14 years (10-18 years). The mean duration of symptoms before the operation was  $4.56 \pm 2.5$  month. Mean follow up period was 14.5 month (6-36 months). The mean preoperative Alpha angle was  $97.85^\circ \pm 13$ . The mean preoperative Slip angle was  $52.5^\circ \pm$

14.6. Harris hip score was done for all patients pre operatively and its mean was  $67 \pm 9.3$ , mean WOMAC score was  $88.4 \pm 3.8$ , mean Merle d'Aubigne score was  $12 \pm 1$  (Tables 1 and 2).

Measurements of slip and alpha angles were done using simple goniometer, TM-Reception (High-End)<sup>TM</sup> Viewer version 4.4 and SYNCROMED FUJIFILM programs.

**Surgical technique**

All operations were performed according to the technique described

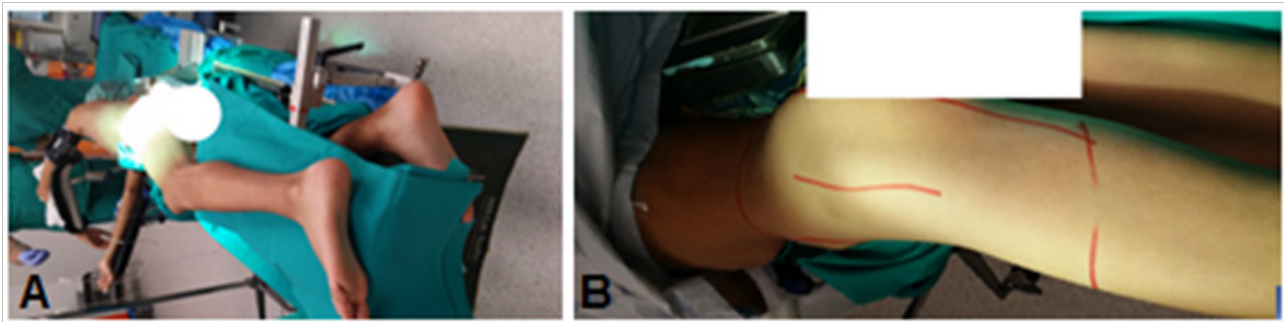


Figure 1 Patient position (A) and Skin incision (B) in Lt hip in patient No 25.

**Table 1** Demographics and preoperative slipped capital femoral epiphyses (SCFE) features.

Patient number	Age	Sex	Side	duration of symptoms (months)	Max follow up (months)	BMI (kg/m <sup>2</sup> )
1	12	M	Rt	7	36	22
2	15	M	Lt	6	35	32
3	18	M	Lt	8	35	25
4	15	M	Rt	8	34	32
5	14	M	Rt	10	32	21
6	13	M	Lt	8	30	26
7	12	M	Bilateral	5	30	30
8	12	M	Bilateral	8	27	30
9	14	M	Rt	6	18	30
10	15	M	Rt	3	16	33
11	16	M	Lt	8	20	32
12	14	F	Lt	2	15	24
13	16	M	Rt	2	13	28
14	14	M	Bilateral	3	24	30
15	14	M	Bilateral	6	12	30
16	15	M	Lt	3	9	34
17	14	F	Lt	2	15	31
18	13	F	Lt	5	12	27
19	13	F	Rt	6	14	22
20	15	M	Rt	2	14	28
21	14	M	Rt	4	15	29
22	15	M	Rt	5	13	30
23	12	F	Rt	1	12	34
24	13	F	Rt	1	6	30
25	11	M	Lt	5	8	26
26	10	M	Rt	2	10	31
27	11	F	Rt	2	8	30
28	12	M	Lt	3	7	28
29	13	M	Rt	2	7	29
30	13	M	Lt	6	13	27
31	10	F	Rt	2	6	25
32	16	M	Rt	5	6	33

**Table 2** preoperative features of slipped capital femoral epiphyses (SCFE) patients.

Patient number	LLD (cm)	Flexion	IR + flexion	ER + flexion	HHS score	WOMAC score	Merle score	Slip angle	Alpha angle
1	3	50		40	68	88	11	70	105
2	2	40		50	70	90	13	52	95
3	2	60		50	66	93	11	58	100
4	2	50		50	64	89	11	38	95
5	3	70		60	62	80	11	68	105
6	1	50		40	72	85	13	32	90
7	1	40		50	60	92	11	26	85
8	1	40		50	60	92	11	23	80
9	2	50		50	70	94	11	64	75
10	2	40		35	66	88	12	43	90
11	2	50		60	67	90	11	57	105
12	1	60		70	68	89	12	62	100
13	1	65		65	69	86	12	62	93
14	2	40		60	73	92	13	58	91
15	1	60		60	73	90	13	38	75
16	1	55	lost (No IR)	70	68	93	14	60.5	112.7
17	2	60		60	68	82	13	66	105
18	2	40		60	65	85	11	56	100
19	1	40		60	65	86	12	82.1	111.5
20	1	40		70	70	80	13	38	95
21	1	50		70	71	84	11	66	105
22	2	55		65	62	87	12	40.1	112
23	1	45		50	64	83	14	53	95
24	1	70		50	65	91	14	30.5	94.7
25	2	60		60	70	92	11	73.4	146.3
26	1	50		70	69	93	13	50	95
27	1	50		60	72	90	12	53	95
28	2	50		55	64	89	12	58	100
29	1	50		50	63	88	11	39	92
30	2	40		65	61	90	11	62	86
31	2	40		60	62	92	11	61	105
32	2	40		70	62	88	13	45	90

by Ganz *et al*<sup>[22]</sup>, under general anesthesia. The patient was placed in a lateral decubitus position with the leg draped so it was fully moveable. Antibiotic prophylaxis is administered pre-operatively.

A longitudinal lateral incision (Figure 1) was made centered over the greater trochanter with a sharp dissection carried down to the fascia lata, the approach was through the Gibson interval between

tensor fascia lata and gluteus maximus.

A trigastric trochanteric osteotomy (Figure 2A) was cut with an oscillating saw, leaving the trochanteric crest untouched. The 1 cm to 1.5 cm thick bony slice including the insertions of gluteus medius and minimus with the insertion of vastus lateralis was flipped anteriorly exposing the anterior hip capsule through the interval between the

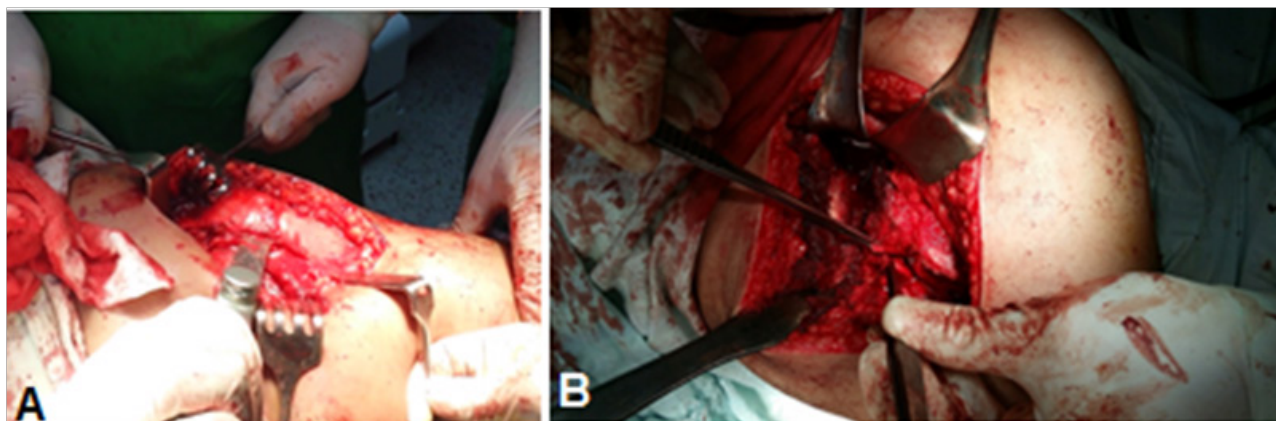
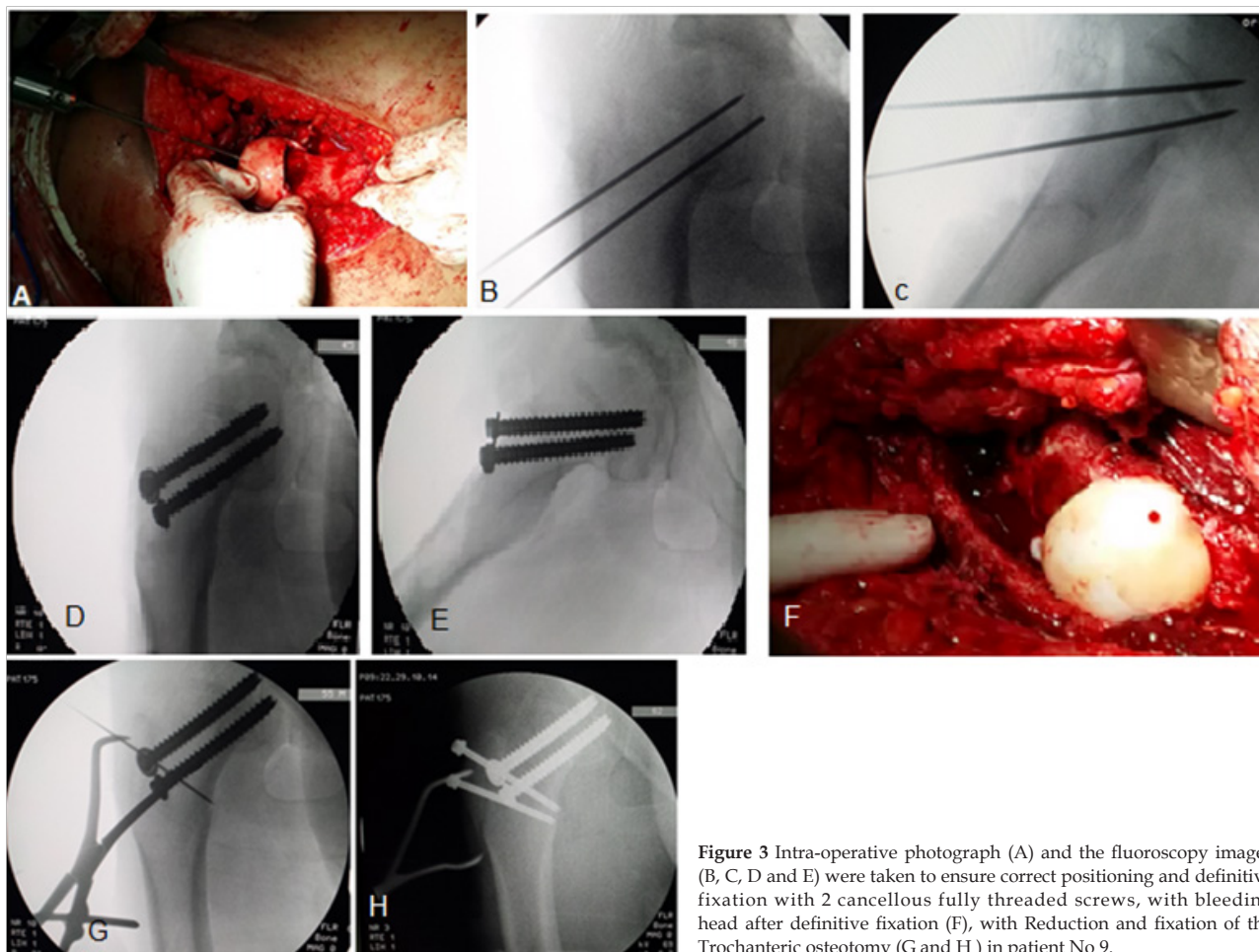


Figure 2 A) showing trochanteric osteotomy in patient No 9. B) Z-shaped capsulotomy in Lt hip in patient no 11.

**Table 3** Post operative features of SCFE patients treated with modified Dunn procedure.

Patient number	LLD (cm)	Complication	Flexion	IR + flexion	ER +flexion	HHS score	WOMAC score	Merle score	Hayman score
1	2	AVN	80	20	20	88	10	10	Good
2	2.5	AVN	70	10	20	66	11	10	Fair
3	0	Infection	120	45	50	100	0	18	Good
4	0	Negative	130	45	50	96	4	18	Good
5	0		100	45	50	100	3	18	Excellent
6	0		50	10	10	100	3	18	Good
7	2		100	40	45	68	12	11	Fair
8	2		100	45	50	68	12	11	Good
9		AVN	130	45	50	100	0	18	Excellent
10		Negative	120	45	50	100	2	18	Good
11			120	45	50	100	4	18	Good
12			120	45	50	98	0	18	Excellent
13			100	40	50	100	0	18	Good
14			120	45	50	98	2	17	Excellent
15			100	45	45	100	0	18	Excellent
16			100	45	45	98	4	18	Good
17			120	45	45	100	6	18	Excellent
18			100	45	45	100	0	17	Excellent
19			110	45	50	100	4	18	Excellent
20	0		110	45	45	100	0	18	Good
21			120	45	45	98	3	17	Excellent
22			130	45	50	100	0	17	Excellent
23			130	45	50	100	0	18	Excellent
24			120	45	50	99	2	18	Good
25			130	45	50	100	4	18	Excellent
26			120	45	50	100	4	18	Good
27			130	45	50	100	4	16	Excellent
28			130	45	50	100	0	18	Good
29			120	45	50	100	4	18	Excellent
30			110	45	50	100	4	18	Excellent
31			130	45	50	100	0	16	Good
32			80	20	20	100	5	18	Excellent



**Figure 3** Intra-operative photograph (A) and the fluoroscopy images (B, C, D and E) were taken to ensure correct positioning and definitive fixation with 2 cancellous fully threaded screws, with bleeding head after definitive fixation (F), with Reduction and fixation of the Trochanteric osteotomy (G and H) in patient No 9.

piriformis tendon and gluteus minimus.

Dissection of the overlying anterior hip capsule is continued as the greater trochanter is retracted further medially. After the entire anterior hip capsule has been exposed, a Z-capsulotomy (Figure 2B) is performed by first incising along the axis of the femoral neck and then extending proximally after the labrum is visualized and protected. The capsulotomy turns sharply at the acetabular rim and continues posteriorly in a curvilinear manner parallel to the labrum, back to the piriformis tendon. The capsulotomy is then opened to inspect and palpate, the head and head neck junction.

Epiphyseal perfusion is checked by inspecting the blood flow out of a simple drill hole from the periphery of the head directed towards the centre, then division of the ligamentum teres to allow femoral head dislocation. The area where the retinacular vessels enter the epiphysis could be identified. The acetabulum was inspected for cartilage damage or labral tear.

Development and release of the retinacular flap which composed of the periosteum of the femoral neck including the retinacular vessels help to preserve the blood supply of the femoral head during the femoral head realignment. The periosteum was released approximately 4 cm distal to the greater trochanter.

Further external rotation of the leg allowed thorough inspection of the posteromedial part of the femoral neck and resection of the posterior buttress bone at this location. The femoral neck was shaped to allow tension-free repositioning of the femoral head centred above the neck.

The remaining physis in the femoral head was curetted out in order to accelerate bony healing after the femoral head was centred on the

neck without tension on the retinaculum then provisional fixation with a K-wire and an intra-operative fluoroscopy was taken to ensure correct positioning had been obtained, in particular the varus-valgus relationship.

The aim was to achieve an anatomical position (Figure #) especially in relation to the fovea capitis and to avoid any varus malalignment as this would make the fixation less stable. The blood perfusion of the femoral head was rechecked again, followed by definitive fixation with three fully threaded 3.0 mm K-wires or cannulated (6.5 mm) screws.

The periosteal sleeve and capsule were approximated with loose sutures and the greater trochanter was reattached with two cortical screws (4.5 mm) (Figure 3 G and H). The fascia was accurately closed with a continuous suture followed by standard wound closure with a suction drain inside wound to prevent haematoma formation.

## RESULTS

The mean operative time was (132.56 ± 29.5) minutes. Intra operative blood loss was estimated by the anesthetics and it ranged from 100 CC to 500 CC with average 100 CC, none of our patients need intra operative or post-operative blood transfusion.

As regarding bleeding of head before dislocation as a test for viability the head was tested by peripheral drilling with K-wire, 30 head (93.75%) was positive bleeding before dislocation the remaining 2 heads (6.25%) with negative bleeding before dislocation. Bleeding of head after reduction was done to exclude tension on posterior retinaculum, 28 heads (87.5%) was positive bleeding after reduction,

while the remaining 4 heads (12.5%) was negative bleeding after reduction, 2 of them (6.25%) were with negative bleeding before dislocation and 2 of them (6.25%) were with positive bleeding before dislocation.

As regard method of fixation 9 hips (30%) were fixed by cannulated 6.5 fully threaded screws and in 23 hips (70%) we used three fully threaded 3.0 mm K-wires.

In our study, mean postoperative slip angle was ( $5.6^{\circ} \pm 8.2^{\circ}$ ) with mean correction ( $46.85^{\circ} \pm 14.9^{\circ}$ ). Mean postoperative Alpha angle was ( $51.15^{\circ} \pm 4.2^{\circ}$ ) with mean correction of ( $46.7^{\circ} \pm 14.2^{\circ}$ ).

As regarding postoperative ROM. Mean post operative flexion was ( $111.9^{\circ} \pm 19.05^{\circ}$ ). Mean post operative IR in  $90^{\circ}$  flexion was ( $41.6^{\circ} \pm 9.6^{\circ}$ ). Mean post operative ER in  $90^{\circ}$  flexion was ( $45.6^{\circ} \pm 9.97^{\circ}$ ).

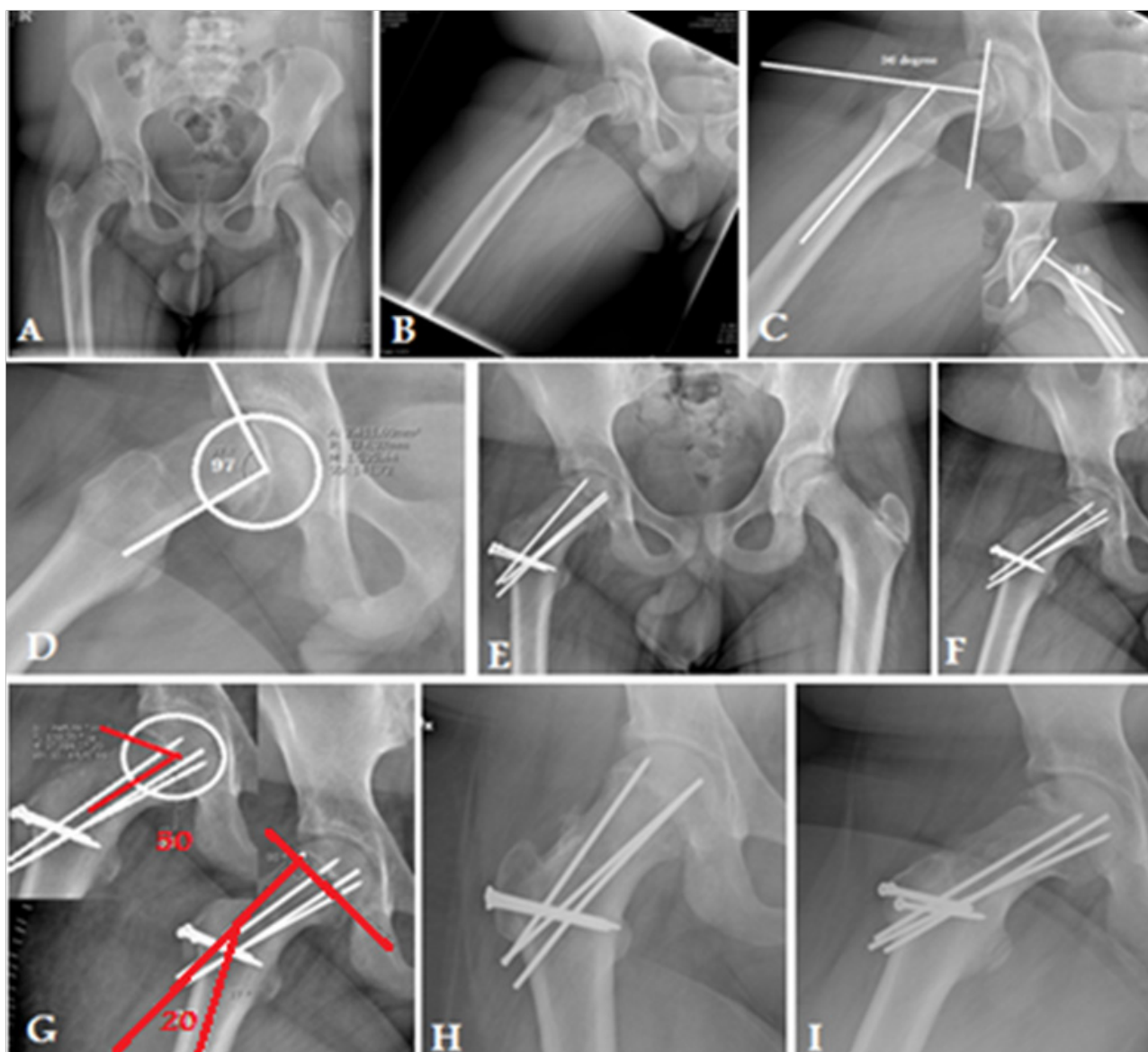
As regard postoperative complication, majority of cases 84.3% no major postoperative complication occurred. One patient (3%) developed post operative deep infection. Three cases (9.3%) developed post operative AVN. One case (3%) with bad reduction needed revision.

We didn't record any case of chondrolysis, OA, implant failure, symptomatic FAI or Heterotopic ossification occurred postoperatively. As regarding mean postoperative HHS in our series was ( $96.16 \pm 9.7$ ) and mean improvement was ( $29.6 \pm 9.6$ ). Mean WOMAC score was ( $3.3 \pm 3.5$ ) and mean improvement was ( $85.12 \pm 4.7$ ). Mean Merle d'Aubigne score was ( $16.8 \pm 2.4$ ) and mean improvement was ( $4.8 \pm 2.4$ ) and as regard to Haymann and Hernodon score 30/32 hips were good and excellent results (Tables 2 and 3).

## DISCUSSION

Our results show that repositioning the epiphysis and restoration of normal proximal femoral anatomy in SCFE is possible with a low risk of AVN by reducing tension on the posterosuperior retinaculum which contains the end branches of the medial femoral circumflex artery by wedge resection of posterior callus formed due to slippage.

According to Southwick radiological classification our study is the largest study including severe SCFE we had 20 patient were



**Figure 4** X-ray in 15 years old male with Rt chronic stable SCFE (case number 10). A) preoperative AP pelvis. (B) pre operative frog lateral view of the Rt hip. (C) preoperative measurement of southwick slip angle. (D) preoperative measurement of Alpha angle. (E) and (F) postoperative AP and Frog view. (G) Postoperative measurement of southwick slip and alpha angles. (H) 16-months postoperative AP and frog lateral X-ray showing complete union of trochanteric osteotomy and physis with no evidence of AVN.

classified as severe and 10 patients as moderate and 2 patients as mild. In K. Ziebarth *et al*<sup>[22]</sup> study 23 patients were classified as moderate and 12 patients were severe, in H. HUBER *et al*<sup>[25]</sup> study 3 patients were classified as mild, 17 were moderate, and 10 patients were severe, in T.Slongo *et al*<sup>[24]</sup> study 6 patients were classified as mild, 8 were moderate, and 9 patients were severe. Novais *et al*<sup>[26]</sup> study 15 patients (100%) were severe. Dan Cosma *et al*<sup>[27]</sup> study 7 patients (100%) were severe (Table 4).

In our study Preoperative slip angle was ranged from 23° to 82.1° with mean 52.5°. Postoperative slip ranged from -12.2° to 28° with mean of 5.6°, mean correction of 46.85°. In K. Ziebarth *et al*<sup>[22]</sup> Preoperative Slip angle was ranged from 34° to 70° with mean of 45.6°, postoperative slip angle ranged from 1° to 20° with mean of 8.6°, mean correction of 37°. H. HUBER *et al*<sup>[25]</sup> study Preoperative Slip angle was ranged from 19° to 77° with mean 44.9°, postoperative slip angle ranged from -18° to 25° with mean of 5.2°, mean correction of 39.7°. In T.Slongo *et al*<sup>[24]</sup> study Preoperative Slip angle was ranged from 39° to 57° with mean 47.6°, postoperative slip angle ranged from 3.5° to 6° with mean of 4.6°, mean correction of 43°. In Novais *et al*<sup>[26]</sup> Preoperative Slip angle was ranged from 54° to 81° with mean 65°, postoperative slip angle ranged from 6° to 23° with mean of 16°. In Dan Cosma *et al*<sup>[27]</sup> Preoperative Slip angle was ranged from 64° to 71.5° with mean 68°, postoperative slip angle ranged from 7.5° to 13.5° with mean of 9°. This reveals that our mean correction of slip angle is the highest due to inclusion of more severe cases (Table 4).

In our study postoperative Alpha angle was restored to normal. It ranged from 45° to 64° with mean of 51.15°, with mean correction of 46.7°. In K. Ziebarth *et al*<sup>[22]</sup> study postoperative Alpha angle ranged from 27° to 60° with mean of 40.6°, in H. HUBER *et al*<sup>[25]</sup> study postoperative Alpha angle ranged from 27° to 77° with mean of 41.4°, in T.Slongo *et al*<sup>[24]</sup> study postoperative Alpha angle ranged from 24° to 53° with mean of 38°. In Novais *et al*<sup>[26]</sup> study postoperative Alpha

angle ranged from 40° to 51° with mean of 44° (Table 4).

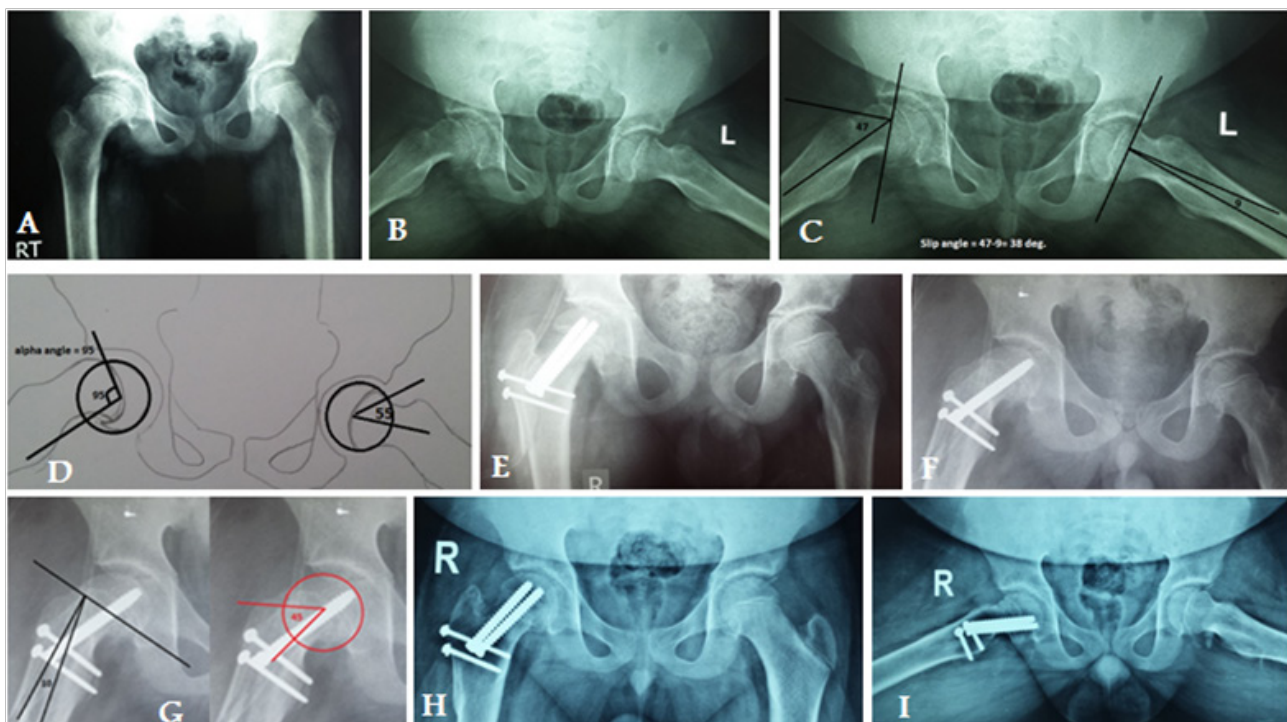
In comparison to other studies we restored near normal postoperative ROM. In our study Post operative flexion ranged from 50 to 130 with mean of 111.9, in K. Ziebarth *et al*<sup>[22]</sup> study post operative flexion was ranged from 80 to 120 with mean of 104, H. HUBER *et al*<sup>[25]</sup> study post operative flexion was more than 90° except in patient who developed AVN, T.Slongo *et al*<sup>[24]</sup> study post operative flexion was ranged from 20 to 130 with mean of 107.

Post operative IR in 90° flexion ranged from 10 to 45 with mean of 41.6, in K. Ziebarth *et al*<sup>[22]</sup> study post operative IR in 90° flexion was ranged from 5 to 45 with mean of 29, H. HUBER *et al*<sup>[25]</sup> study post operative IR in 90° flexion was ranged from 10 to 50 with mean of 33.3, T. Slongo *et al*<sup>[24]</sup> study post operative IR in 90° flexion was ranged from 10 to 60 with mean of 37.8.

Post operative ER in 90° flexion ranged from 15 to 50 with mean of 45.6, in K. Ziebarth *et al*<sup>[22]</sup> study post operative ER in 90° flexion was ranged from 20 to 60 with mean of 43, H. HUBER *et al*<sup>[25]</sup> study post operative ER in 90° flexion was ranged from 20 to 70 with mean of 49.8, T. Slongo *et al*<sup>[24]</sup> study post operative ER in 90° flexion was ranged from 10 to 60 with mean of 45.

We evaluated postoperative clinical outcome by use of 4 different clinical score. This allowed us to compare our results with the results of other published studies. HHS in our series was ranged from 66 to 100 with mean of 96.16. Mean postoperative HHS in K. Ziebarth *et al*<sup>[22]</sup> study was 99.6, in H. HUBER *et al*<sup>[25]</sup> study postoperative HHS ranged from 56 to 100 with mean of 97.8, in T.Slongo *et al*<sup>[24]</sup> study postoperative HHS ranged from 82 to 100 with mean of 99. In comparison to other studies our mean HHS was slightly lower due to involvement of more chronic cases which had slight persistent postoperative pain and limited ROM due to muscle weakness. This may improve on long term follow up with return of the patients to their full activity and regaining full muscle power.

WOMAC score ranged from 0 to 12 with mean of 3.3 while in



**Figure 5** X-ray in 15 years old male with Rt chronic stable SCFE (case number 4). (A) preoperative AP pelvis. (B) pre operative frog lateral view of the both hip. (C) preoperative measurement of southwick slip angle. (D) preoperative measurement of Alpha angle. (E) and (F) postoperative AP and Frog view. (G) Postoperative measurement of southwick slip and alpha angles. (H) 12-months postoperative AP and frog lateral X-ray showing complete union of trochanteric osteotomy and physis with no evidence of AVN.

Masse *et al*<sup>[28]</sup> study, postoperative pain score at WOMAC was 0.6 (ranged from 0-4) and postoperative function score at WOMAC was 2.2 (ranged from 0-12). Merle d'Aubigne score ranged from 10 to 18 with mean of 16.8. In K. Ziebarth *et al*<sup>[22]</sup> mean Merle d'Aubigne score was 17.8, in T.Slongo *et al*<sup>[24]</sup> study Merle d'Aubigne score ranged from 11 to 18 with mean of 17. Heyman and Hernodon score in our series was 30/32 had good and excellent results. In Novais *et al*<sup>[26]</sup> study Heymann and Hernodon score was 9/15 had good and excellent results. In Dan Cosma *et al*<sup>[27]</sup> study Heymann and Hernodon score was 6/7 had good and excellent results (Table 5).

As regard the modified Dunn osteotomy with surgical hip dislocation, the incidence of complications was low. In our study three cases (9.3%) developed post operative AVN. In H. HUBER *et al*<sup>[25]</sup> study they recorded one case of AVN (3.5%), in Masse *et al*<sup>[28]</sup> study they didn't recorded any case of AVN, in T.Slongo *et al*<sup>[24]</sup> study they also recorded one case of AVN (4.4%), Sankar *et al*<sup>[29]</sup> recorded 7 cases of AVN (26%), Novais *et al*<sup>[26]</sup> recorded one case of AVN (7%), Dan Cosma *et al*<sup>[27]</sup> didn't record any case of AVN.

We didn't record any case with implant failure. In H. HUBER *et al*<sup>[25]</sup> study they recorded 4 cases of implant failure necessitating revision of fixation with cortical screws. While in K. Ziebarth *et al*<sup>[22]</sup> study they recorded 3 cases of implant failure which necessitate revision of surgery, T. Slongo *et al*<sup>[24]</sup> study record one case of implant protrusion needed revision of fixation. Sankar *et al*<sup>[29]</sup> recorded 4

cases of implant failure which necessitate revision of surgery. Novais *et al*<sup>[26]</sup> recorded 2 cases of implant failure which necessitate revision of surgery.

In our series, the need for reoperation was low in comparison to other series. Only 3 patients needed reoperation; one of the three who developed postoperative AVN needed another surgery to remove the protruded screws and arthrodiastasis, one with late deep infection needed debridement and screw removal, one of bad reduction needed revision with adjustment of the reduction. Most of reoperations in other studies were due to revision of failed fixation which didn't occur in our study. Another cause of reoperation was development of postoperative H.O which developed after correction of acute slippage but in our study all cases were chronic so avoiding these complications. Sankar *et al*<sup>[29]</sup> recorded one patient (3.7%) needed open osteoplasty of residual deformity due to AVN, one patient (3.7%) of AVN need core decomp and another patient of AVN (3.7%) needed THR in addition to revision of failed implants and removal of protruded implant in 9 patients (33.5%) (Table 6).

**THE STRENGTH AND LIMITATIONS**

The strength points in the current study can be summarized in three points. The first point is that our study is the largest study dealing with management of chronic stable SCFE using Ganz surgical hip dislocation. The second is that it is the only study that uses 4 different

**Table 4** comparison of patient criteria in different studies.

		Ziebarth <i>et al</i> 2009	Slongo <i>et al</i> 2010	Huber <i>et al</i> 2011	Masse <i>et al</i> 2012	Sankar <i>et al</i> 2013	Novais <i>et al</i> 2015	Dan Cosma <i>et al</i> 2016	Current study
No of pts.		40 (40 hips)	23 (23 hips)	28 (30 hips)	19 (20 hips)	27 (27 hips)	15 (15 hips)	7 (7 hips)	30 (32 hips)
Age at operation	Range	16-Sep	17-Jul	9.4-16.6	19-Sep	9.7-16.0	17-Dec	12 - 13	18-Oct
	Mean	12.5	12	12.2	14.2	12.6	14	13	14
Sex	Male	17 (42.5%)	14 (60.9%)	11 (39.3%)	-	17 (63%)	11(73%)	7 (100%)	22 (73.3%)
	Female	23 (57.5%)	9 (39.1%)	17 (60.7%)	-	10 (37%)	4 (27%)	0	8 (26.7%)
Side	Rt	12 (30%)	9 (39.13%)	-	-	9 (33%)	9 (60%)	3 (42.9%)	17 (56.7%)
	Lt	28 (70%)	14 (60.8%)	-	-	18 (66.6%)	6 (40%)	4 (57.1%)	11 (36.7%)
	Bilateral								2 (6.6%)
Duration of symptoms	Range	1 day-3 years	2 days-224 day	-	-	6-184 hours	-	3.5 - 5.5 weeks	1-10 month
	Mean	4 months	35 day	-	-	35.9 hours	-	5 weeks	4.5 months
Follow-up(months)	Range		23-62	15-102	24-Jun	Dec-48	12- 60	8.5 - 23	Jun-36
	Mean	42	24	51.6	10.65	22.3	28.8	12	17.3
Fahey classification	Acute	13(32.5%)	-	3(10%)	2(10%)	27(100%)	0	2 (28.6%)	0
	Acute on chronic	0	14(60.9%)	0		0		1(14.3)	One (3%)
	Chronic	27(67.5%)	9(39.1%)	27(90%)	18(90%)	0	15 (100%)	4(57%)	31 (97%)
Loder classification	Stable	27(67.5%)	20(87%)	27(90%)	18(90%)	0	15 (100%)	6(85.7%)	32(100%)
	Unstable	13(32.5%)	3(13%)	3(10%)	2(10%)	27 (100%)	-	1 (14.3%)	-
Southwick classification	Mild	5(12.5%)	6(23%)	3(10%)		-	-	0	2(6.25%)
	Moderate	23(57.5%)	8(35%)	17(57%)		-	-	0	10 (31.25%)
	Severe	12(30%)	9(42%)	10(33%)	20(100%)	-	15 (100%)	7(100%)	20(62.5%)
Pre op Slip angle	Range	34-70 <sup>0</sup>	39-57 <sup>0</sup>	19-77 <sup>0</sup>		-	54-81 <sup>0</sup>	64- 71.5 <sup>0</sup>	23-82.1 <sup>0</sup>
	Mean	45.6	47.6	44.9	50.65	-	650	680	52.5
Postoperative slip angle	Range	1 <sup>0</sup> - 20 <sup>0</sup>	3.5 <sup>0</sup> - 6 <sup>0</sup>	-430		2-11 <sup>0</sup>	6 - 23 <sup>0</sup>	7.5 - 13.5 <sup>0</sup>	-12.2-28 <sup>0</sup>
	Mean	8.6	4.6	5.2	9, 45	60	160	90	5.6
	Mean correction	370	430	39.7	-	-	-	-	46.85
Pre op alpha angle	Range	-	-	-	-	-	93-120 <sup>0</sup>	-	75- 146.3 <sup>0</sup>
	Mean						1110	-	97.85
Postoperative Alpha angle	Range	27 <sup>0</sup> -60 <sup>0</sup>	24 <sup>0</sup> -53 <sup>0</sup>	27 <sup>0</sup> -77 <sup>0</sup>	-	-	40-51 <sup>0</sup>	-	45-64 <sup>0</sup>
	Mean	40.6	380	41.4	43. 11	-	440	-	51.15 <sup>0</sup>
	Mean correction	-	-	-	-	-	-	-	46.7



**Table 5 Comparison of Postoperative Clinical scores in different studies.**

Postoperative Clinical scores		Ziebarth <i>et al</i> 2009	Slongo <i>et al</i> 2010	Huber <i>et al</i> 2011	Masse <i>et al</i> 2012	Sankar <i>et al</i> 2013		Novais <i>et al</i> 2015	Dan Cosma <i>et al</i> 2016	current study
						No AVN	AVN			
HHS	Range		82-100	56-100		86.7-89.3	44.8-75.1			66-100
	Mean	99.6	99	97.1	98.2	88	60			96.16
WOMAC	Range					Pain(0-2)				0-12
						Function(0-12)				
	Mean	Pain(2.1) Function(3)			Pain(0.6) Function(2.2)					3.3
Merle d'Aubigne	Range		11-18							10-18
	Mean	17.8	17							16.8
Heyman and Herndorn								9/15 had good and excellent results	6/7 had good and excellent results	30/32 had good and excellent results

**Table 6 Comparison of incidence of Postoperative complications in different studies.**

	The Dunn osteotomy		Modified Dunn osteotomy						
	M.Lawane <i>et al</i> 2009	Ziebarth <i>et al</i> 2009	Slongo <i>et al</i> 2010	HUBER <i>et al</i> 2011	Masse <i>et al</i> 2012	Sankar <i>et al</i> 2013	Novais <i>et al</i> 2015	Dan Cosma <i>et al</i> 2016	Our study
Infection	0	0	0	0	0	0	0	0	1 (3%)
Implant failure	0	3 (7.5%)	1 (4.4%)	4 (13.5%)	0	4 (15%)	2 (13%)	0	0
H.O	0	3 (7.5%)	0	0	0	0	0	0	0
Delayed union	1(4%)	3 (7.5%)	0	0	0	0	0	0	0
AVN	5(20%)	0	1 (4.4%)	1 (3.5%)	0	7 (26%)	1 (7%)	0	3 (9.4%)
Chondrolysis	3 (12%)	-	-	-	0	-		0	0
Limited ROM		0	1 (4.4%)	0	0	7 (26%) due to AVN	6 (40%)	1 (14.2%)	3 (9.4%) due to AVN
OA		0	1 (4.4%)	0	0		1(7%)	0	0
FAI	1 (4%)	1 (2.5%)	0	0	0	1(3.7%)	0	0	0
Total incidence of complications	10 (40%)	10 (25%)	4(17.6%)	5(17%)	0	11(41%)	3 (20%)	1 (14.2%)	5 (15.6%)

clinical scores to assess postoperative clinical outcome and this allow feasibility to compare our results with the results of other published studies. The third point is that we had largest mean correction of slip angle postoperatively probably due to inclusion of more severe cases. On the other side this case series study has some major limitations, like any single cohort study; there was lack of comparison or control group in this case series study. Without a truly randomized long-term study about results of Ganz surgical hip dislocation it would be difficult to compare outcomes of this technique with other various surgical techniques such as in situ pinning, capital realignment, and intertrochanteric osteotomy. Moreover, it was done by 2 different surgeons in 2 hospitals which had direct influence on the outcome and postoperative results.

Another major limitation in our study is lack of long term follow up in comparison with other studies. This was due to late application of this technique in our institution on 2013, while in other studies they started very early in 1996<sup>[23]</sup>, 1998<sup>[22]</sup>, 2001<sup>[25]</sup>, 2004<sup>[24]</sup>.

One of major limitations was our dependence on rough method to detect head viability (peripheral K-wire drilling) which lack both sensitivity and specificity. The use of Doppler ultrasound probe can detect perfusion of both epiphysis and retinaculum so can be a good reliable test in predicting development of postoperative AVN.

## CONCLUSION

The modified Dunn osteotomy using Ganz surgical hip dislocation is our treatment of choice moderate and severe SCFE, allowing

anatomical restoration of proximal femur, direct inspection and preservation of physeal blood supply and inspection of intra-articular pathology which can be evaluated and treated at the time of the operation. In majority of cases we can relocate the epiphysis without need for shortening of the femoral neck. Modified Dunn procedure is safe, efficient and reproducible, but it has a long learning curve and it should be learned in a specialized centre before using it in clinical practice.

## ACKNOWLEDGEMENT

I would like to express my deepest gratitude to all staff members of orthopedic surgery department, faculty of medicine, Alazhar university, cairo, Egypt with special thanks to professor Ahmed shamma and staff members of orthopedic surgery department, faculty of medicine, Turin university, Turin, Italy, with special thanks to Andrea Damelioa and Ferdinando Tosto for their support.

Special thanks to Egyptian sector of mission and cultural affair, ministry of higher education for financial support.

## REFERENCES

- 1 Schein AJ. Acute severe slipped capital femoral epiphysis. *Clin. Orthop.* 1967; **51**: 151-166. [PMID: 6027012]
- 2 Segal LS, Weitzel PP, Davidson RS. Valgus slipped capital femoral epiphysis: fact or fiction. *Clin. Orthop.* 1996; **322**: 91-98. [PMCID: PMC2958296]
- 3 Weiner D. Pathogenesis of slipped capital femoral epiphysis:

- current concepts. *J. Pediatr. Orthop.* 1996 Part B; **5**: 67-73. [PMID: 8811532]; [DOI: 10.1097/01202412-199605020-00002.]
- 4 Loder RT, Wittenberg B, DeSilva G. Slipped capital femoral epiphysis associated with endocrine disorders. *J. Pediatr. Orthop.* 1995; **15**: 349-356. [PMID: 7790494]
  - 5 McAfee PC, Cady RB. Endocrinologic and metabolic factors in atypical presentations of slipped capital femoral epiphysis. Report of four cases and review of the literature. *Clin. Orthop.* 1983; **180**: 188-197. [PMID: 6354545]
  - 6 Wells D, King JD, Roe TF, Kaufman FR. Review of slipped capital femoral epiphysis associated with endocrine and renal diseases. *J. Pediatr Orthop.* 1993; **13**: 610-614. [PMID: 8376562]
  - 7 Loder RT, Hensinger RN, Alburger PD, Aronsson DD, Beaty JH, Roy DR, Stanton RP, Turker R. Slipped capital femoral epiphysis associated with radiation therapy. *J. Pediatr. Orthop.* 1998; **18**: 630-636. (caughted from Textbook of Hip Disorders in Childhood By John V. Banta, David Scrutton, 1st edition, 2003)
  - 8 Fahey J, O'Brien ET. Remodeling of the femoral neck after in situ pinning for slipped capital femoral epiphysis. *J. Bone and Joint Surg.* Jan. 1977; **59-A**: 62-68. [PMID: 833177]
  - 9 Loder RT, Richards BS, Shapiro PS, Reznick LR, Aronson DD: Acute slipped capital femoral epiphysis: The importance of physeal stability. *J Bone Joint Surg Am* 1993; **75**: 1134-1140. [PMID: 8354671]
  - 10 Wilson R. The association of femoral retroversion with slipped capital femoral epiphysis. *J Bone Joint Surg Am* 1986; **68**: 1000-1007. [PMID: 3745237]
  - 11 Southwick WO. Osteotomy through the lesser trochanter for slipped capital femoral epiphysis. *J. Bone and Joint Surg.* July 1967; **49-A**: 807-835. [PMID: 6029256]
  - 12 Brown Desmond. Seasonal Variation of Slipped Capital Femoral Epiphysis in the United States Journal of Pediatric Orthopaedics, March/April 2004; Volume 24 - Issue 2 - pp 139-143. [PMID: 15076596]
  - 13 Carney BT, Weinstein SL, Noble J. Long-term follow-up of slipped capital femoral epiphysis. *J Bone Joint Surg Am.* 1991; **73**: 667-674. [PMID: 2045391];
  - 14 Bellemans J, Fabry G, Molenaers G, Lammens J, Moens P. Slipped capital femoral epiphysis: a long-term follow-up, with special emphasis on the capacities for remodeling. *J Pediatr Orthop B* 1996; **5**: 151-157. [PMID: 8866278]; [DOI: 10.1097/01202412-199605030-00003.]
  - 15 Guzzanti V, Falciaglia F, Stanitski CL. Slipped capital femoral epiphysis in skeletally immature patients. *J Bone Joint Surg Br* 2004; **86**: 731-736. [PMID: 15274272]; [DOI: 10.1302/0301-620X.86B5.14397]
  - 16 Adolfsen SE, Sucato DJ. Surgical technique: open reduction and internal fixation for unstable slipped capital femoral epiphysis. *Oper Tech Orthop.* 2009; **19**: 6-12. [DOI: 10.1053/j.oto.2009.03.004.]
  - 17 Rab GT. The geometry of slipped capital femoral epiphysis implications for movement, impingement, and corrective osteotomy. *J Pediatr Orthop.* 1999; **19**: 419-424. [PMID: 10412987]
  - 18 Leunig M, Casillas MM, Hamlet M, Hersche O, Notzli H, Slongo T, Ganz R. Slipped capital femoral epiphysis: early mechanical damage to the acetabular cartilage by a prominent femoral metaphysis. *Acta Orthop Scand.* 2000; **71**: 370-375. [PMID: 11028885]; [DOI: 10.1080/000164700317393367]
  - 19 Aronsson DD, Loder RT, Breur GJ, Weinstein SL. Slipped Capital Femoral Epiphysis; Current Concepts. *J Am Acad Orthop Surg* 2006; **14**: 666-679. [PMID: 17077339]
  - 20 Leunig M, Slongo T, Kleinschmidt M, Ganz R. Subcapital correction osteotomy in slipped capital femoral epiphysis by means of surgical hip dislocation. *Oper Orthop Traumatol* 2007; **19(4)**: 389-410. [DOI: 10.1007/s00064-007-1213-7]
  - 21 Ganz R, Gill TJ, Gautier E, et al. Surgical dislocation of the adult hip a technique with full access to the femoral head and acetabulum without the risk of avascular necrosis. *J Bone Joint Surg Br* 2001; **83**: 1119-1124. [PMID: 11764423]; [DOI: 10.1302/0301-620X.83B8.11964]
  - 22 Ziebarth K: Capital Realignment for Moderate and Severe SCFE Using a Modified Dunn Procedure, *Clin Orthop Relat Res* 2009; **467**: 704-716. [PMID: 19142692]; [PMCID: PMC2635450]; [DOI: 10.1007/s11999-008-0687-4]
  - 23 Leunig M, Slongo T, Ganz R: Subcapital realignment in slipped capital femoral epiphysis: Surgical hip dislocation and trimming of the stable trochanter to protect the perfusion of the epiphysis. *Instr Course Lect* 2008; **57**: 499-507. [PMID: 18399604]
  - 24 Slongo T, Kakaty D, Krause F, Ziebarth K. Treatment of slipped capital femoral epiphysis with a modified Dunn procedure. *J Bone Joint Surg Am.* 2010; **92**: 2898-2908. [PMID: 21159990]; [DOI: 10.2106/JBJS.I.01385]
  - 25 H HUBER. Adolescent slipped capital femoral epiphysis treated by a modified Dunn osteotomy with surgical hip dislocation. *J Bone Joint Surg Br* 2011; **93-B**: 833-8. [PMID: 21586786]; [DOI: 10.1302/0301-620X.93B6.25849]
  - 26 Novais EN, Hill MK, Carry PM, Heare TC, Sink EL. Modified Dunn Procedure is superior to in situ pinning for short-term clinical and radiographic improvement in severe stable SCFE; *Clin Orthop Relat Res* 2015; **473**: 2108-2117 [PMID: 25502479]; [PMCID: PMC4419009]; [DOI: 10.1007/s11999-014-4100-1]
  - 27 Cosma D, Vasilescu DE, Corbu A, Valeanu M, Vasilescu D. The modified Dunn procedure for slipped capital femoral epiphysis does not reduce the length of the femoral neck. *Pak J Med Sci.* 2016; **32(2)**: 379-384. [DOI: <http://dx.doi.org/10.12669/pjms.322.8638>]
  - 28 Massè Alessandro, Aprato Alessandro, Grappiolo Guido, Turchetto Luigino, Campacci Antonio, Ganz Reinhold. Surgical hip dislocation for anatomic reorientation of slipped capital femoral epiphysis: preliminary results. *Hip International.* Apr-Jun 2012, **22** Issue 2, p137-144. [PMID: 22505180]; [DOI: 10.5301/HIP.2012.9208]
  - 29 Wudbhav N. Sankar, MD, Kelly L. Vanderhave, MD, Travis Matheney, MD, Jos'e A. Herrera-Soto, MD, and Judson W. Karlen, MD: The Modified Dunn Procedure for Unstable Slipped Capital Femoral Epiphysis, *J Bone Joint Surg Am.* 2013; **95**: 585-91. [DOI: 10.2106/JBJS.L.00203]

**Peer reviewer:** Chemello Cesare