

## Combined Intra-articular K-wire and Coracoclavicular Screw Fixation for Type III Acromioclavicular Joint Dislocations- A Randomized Controlled Study with Minimum of 3 Years Follow-up

Sourabh Chachan, Biswajit Sahu

Sourabh Chachan, MBBS, MS (ortho), MRCS (Edin.), Orthopaedic surgeon, Department of Orthopaedics, Changi General Hospital, Singapore

Biswajit Sahu, MBBS, MS (ortho), Associate Professor, Department of Orthopaedics, VSS Medical College, Sambalpur, Odisha, India

**Conflict-of-interest statement:** The author(s) declare(s) that there is no conflict of interest regarding the publication of this paper.

**Open-Access:** This article is an open-access article which was selected by an in-house editor and fully peer-reviewed by external reviewers. It is distributed in accordance with the Creative Commons Attribution Non Commercial (CC BY-NC 4.0) license, which permits others to distribute, remix, adapt, build upon this work non-commercially, and license their derivative works on different terms, provided the original work is properly cited and the use is non-commercial. See: <http://creativecommons.org/licenses/by-nc/4.0/>

Correspondence to: Sourabh Chachan, #13-15, Tower B2, 732 bedok reservoir road, Singapore-479262.

Email: [drsourabhchachan@gmail.com](mailto:drsourabhchachan@gmail.com)

Telephone: +6596906470

Received: November 28, 2016

Revised: April 18, 2017

Accepted: April 21 2017

Published online: August 28, 2017

### ABSTRACT

**BACKGROUND:** Treatment of Rockwood type III acromioclavicular dislocations is still controversial with evidence present in favour of both operative and non-operative interventions.

**MATERIAL AND METHODS:** A prospective randomized controlled clinical trial was conducted at the Department of Orthopaedics of a Level I trauma centre including 54 (male = 34, female = 20) cases of type III acromioclavicular dislocations,

randomized into two groups A (operative) and B (non-operative). Group A cases underwent surgery using combined intra-articular K-wire and coracoclavicular screw fixation. Group B cases were treated non-operatively using arm sling and rest.

**RESULTS:** Mean follow-up period was 40.8 months (range = 36-49). Mean Constant Shoulder scores for group A and B were 93 and 83.5 after 12 months ( $p$  value  $\leq 0.0001$ ); 93.3 and 86.5 after 36 months ( $p$  value  $\leq 0.0001$ ), respectively. Complications reported from group A were hardware failure, heterotopic ossification, distal clavicle osteolysis and superficial stich infection and from group B were cosmetic deformity and intermittent pain around shoulder.

**CONCLUSIONS:** In this study, operatively managed cases did significantly better than the non-operatively treated ones with faster and improved functional outcomes.

**Key words:** Acromioclavicular dislocations; Coracoclavicular screw; Constant shoulder score

© 2017 The Author(s). Published by ACT Publishing Group Ltd. All rights reserved.

Chachan S, Sahu B. Combined Intra-articular K-wire and Coracoclavicular Screw Fixation for Type III Acromioclavicular Joint Dislocations- A Randomized Controlled Study with Minimum of 3 Years Follow-up. *International Journal of Orthopaedics* 2017; **4(4)**: 796-801 Available from: URL: <http://www.ghrnet.org/index.php/ijo/article/view/1936>

### INTRODUCTION

Acromioclavicular dislocation is quiet common with most common mode being direct trauma due to fall on shoulder<sup>[1]</sup>. Treatment of Rockwood type III acromioclavicular dislocations is still controversial with evidence present in favour of both operative and non-operative interventions<sup>[1,2,3,4,5]</sup>. Various operative modalities available for fixation of acromioclavicular dislocations are intra-articular fixation with K-wires or Steinmann pins, ligament reconstruction procedures and extra-articular coracoclavicular repairs<sup>[1]</sup>. Each modality has

its own advantages and limitations. This study was conducted to compare the outcomes of combined intra-articular K-wire fixation and coracoclavicular screw repair against non-operative management for type III acromioclavicular dislocations.

## MATERIALS AND METHODS

Between January 201 and April 2013, a prospective randomized controlled clinical trial was conducted at the department of orthopaedics of a tertiary care centre. 54 (males = 34, females = 20) cases of Rockwood type III (OTA type 10B3.3 and 10B3.4) acromioclavicular dislocations were included in this study<sup>[1,2]</sup>. Two groups were created, group A (operative) received surgery with combined intra-articular k-wire and coracoclavicular screw fixation, whereas group B (control) received conservative management. All the cases were evaluated clinically and radiography was performed with anterior-posterior, lateral and Zanca views. Inclusion and exclusion criteria for patients were set (Table 1). All the surgeries were done by single surgeon. Evaluation was done using Constant Shoulder score at follow-up visits. Statistical analysis was done using unpaired student's *t*-test.

### Surgical technique

(1) General anaesthesia was used. (2) Patient was placed supine on operation table. (3) Whole limb along with neck and chest prepared with antiseptic solutions. (4) A curvilinear incision of appropriate size was taken over shoulder. (5) Soft tissue dissection was done to reach joint surface. (6) Joint was debrided free of any interposing soft tissue and haematoma was evacuated. (7) Open reduction of

acromioclavicular joint dislocation was achieved. (8) Joint was fixed with two 2.0 mm K- wires, driven from acromion to clavicle traversing acromioclavicular joint. (9) Then coracoclavicular repair was performed with 6.5 mm cannulated cancellous lag screw. (10) Acromioclavicular joint capsule was repaired. (11) Wound closed in layers.

**Table 1** Inclusion and Exclusion Criteria for study.

	Inclusion Criteria	Exclusion Criteria
1)	Isolated AC joint dislocation	Associated injuries
2)	Acute, < 7 days old	> 7 days old
3)	Closed dislocation	Open dislocation, soft tissue injury
4)	Rockwood type III injury (OTA type 10B3.3, 10b3.4)	Rockwood Type I, II, IV, V, VI
5)	Age = 20-50 years	Age ≤ 20 or > 50 years
6)	Normal neuro-vascular status of the limb	Abnormal neuro-vascular status of the limb due to current or pre-existing conditions

AC: acromioclavicular; OTA: Orthopaedic Trauma Association.

**Table 2** Age and Gender distribution of Patients.

Age & Gender group	Group A (operative)	Group B (non-operative)
1) 21-30 years Male	7	10
2) 21-30 years Female	3	3
3) 31-40 years Male	4	8
4) 31-40 years Female	5	6
5) 41-50 years Male	5	0
6) 41-50 years Female	1	2
7) Total	Males=16, Females=9	Males=17, Females=11

**Table 3** Group A (Operative).

Sr. No.	Age& Sex	Inj-Sx time (days)	Follow-up period (months)	Constant Shoulder Scores					Complications
				2 weeks	3 months	6 months	12 months	36 months	
1	23M	6	37	24	58	79	94	93	nil
2	29M	2	45	22	55	82	92	93	nil
3	33M	3	46	26	58	80	90	90	Coracoclavicular screw pull-out & Distal clavicle osteolysis
4	45M	5	48	20	51	78	92	93	nil
5	39M	3	36	24	56	76	90	89	nil
6	33M	3	38	20	51	73	94	95	nil
7	25M	2	37	26	58	82	98	97	nil
8	39M	3	39	18	51	76	90	92	Superficial stitch infection
9	45M	3	38	20	53	82	98	95	nil
10	23M	2	45	18	55	80	96	98	nil
11	41M	2	47	20	51	79	90	92	nil
12	27M	4	37	22	56	82	94	95	nil
13	43M	4	46	18	51	80	94	95	nil
14	29M	2	36	20	53	79	92	90	Heterotopic ossification
15	43M	2	48	28	56	82	96	95	nil
16	23M	2	45	20	55	82	94	96	nil
17	33F	3	42	20	58	79	90	89	nil
18	37F	3	37	22	51	79	92	91	nil
19	43F	2	40	22	53	76	94	92	K-wire failure
20	23F	1	39	22	56	78	92	96	nil
21	29F	3	36	26	58	82	96	98	nil
22	31F	4	40	24	53	79	92	94	nil
23	37F	3	42	24	55	82	94	92	nil
24	39F	1	40	20	58	80	92	93	nil
25	29F	2	40	24	53	78	90	89	Heterotopic ossification

Table 4 Group B (Non-operative).

Sr. No.	Age & Sex	Follow-up period (months)	Constant Shoulder Scores					Complications
			2 weeks	3 months	6 months	12 months	36 months	
1	24M	38	20	43	62	89	90	poor cosmesis
2	26M	40	22	41	66	81	85	nil
3	34M	36	20	41	64	83	88	poor cosmesis & intermittent pain
4	22M	45	18	41	62	83	84	intermittent pain
5	40M	38	22	46	64	79	86	poor cosmesis
6	36M	36	24	47	68	81	86	intermittent pain
7	34M	38	20	41	66	83	85	intermittent pain
8	26M	45	22	41	64	87	88	poor cosmesis & intermittent pain
9	38M	46	24	43	62	85	90	poor cosmesis
10	30M	46	24	46	62	79	84	poor cosmesis & intermittent pain
11	36M	45	26	46	64	81	84	intermittent pain
12	30M	39	18	41	64	83	88	intermittent pain
13	38M	45	20	39	62	85	88	intermittent pain
14	28M	45	16	37	64	83	89	intermittent pain
15	24M	42	20	41	66	87	89	intermittent pain
16	30M	36	24	43	62	81	85	nil
17	40M	36	18	41	64	85	87	poor cosmesis
18	22M	39	22	43	62	79	78	poor cosmesis & intermittent pain
19	38F	49	18	46	64	89	92	nil
20	26F	40	20	47	66	83	89	poor cosmesis & intermittent pain
21	34F	38	20	46	64	85	90	poor cosmesis
22	32F	41	24	43	62	81	85	intermittent pain
23	38F	48	24	46	64	85	85	intermittent pain
24	22F	38	22	41	66	89	90	nil
25	42F	38	18	39	64	87	90	poor cosmesis & intermittent pain
26	28F	37	22	37	62	79	80	poor cosmesis & intermittent pain
27	32F	40	22	41	68	81	85	poor cosmesis
28	38F	37	22	43	64	83	82	poor cosmesis & intermittent pain
29	44F	38	20	39	62	85	89	poor cosmesis

**Post-operative protocol**

Antibiotics and analgesics were given as required. Shoulder immobiliser was given for two weeks. Active and passive range of motion exercises were begun on 15<sup>th</sup> postoperative day and were increased as tolerable. Overhead abduction, weight lifting more than 4lbs, and sports participation was restricted for 12 weeks. K wire removal was performed at 4 weeks and coracoclavicular screw was removed at 12 weeks.

**Conservative treatment protocol**

Patients were given oral analgesics and arm sling for 7-10 days. Range of motion exercises were instituted as soon as tolerable. Heavy weight lifting, overhead abduction and active sports participation were restricted for at least 12 weeks or till there was no pain on palpation.

**RESULTS**

Mean age of all cases was 32.8 years (range = 22-45 years). Group A had 25 (males = 16, females = 9) cases while group B had 29 (males = 18, females = 11) cases (Table 2). Mean age of group A cases was 33.6 years while for group B was 32.1 years (*p* value = 0.22). Mean time between injury and surgery was 2.8 days (range 1-6 days). Mean follow-up period was 40.8 months (range = 36-49 months).

Post-operatively, the average Constant shoulder score for group A at 2 weeks, 3, 6, 12 and 36 months was 22, 54.5, 76.5, 93 and 93.3, respectively (Table 3). For group B, the Constant shoulder score at 2 weeks, 3, 6, 12 and 36 months was 21.1, 42.4, 63.9, 83.5 and 86.6, respectively (Table 4). The Constant shoulder score improved progressively in both the operative and non-operative groups. At 2 weeks post-surgery, there was no statistically significant difference between the Constant shoulder scores for operative and non-operative group (Table 5). However, from 3 months onwards till 36 months follow-up, the average Constant shoulder scores for operative group remained significantly better than the non-operative group (Table 5).

2 cases from group A (incidence = 8%) were complicated by hardware failure, one case had K-wire back-out (Figure 3) and other had coracoclavicular screw pull-out (Figure 4). 1 case from operative group (incidence = 4%) had superficial stitch infection which subsided with antibiotics. Heterotopic ossification was seen in 2 cases in group A (incidence = 8%) (Figure 5). Osteolysis of distal clavicle was observed in 1 case who also had coracoclavicular screw pull-out(incidence = 4%) (Figure 6). In group B, 15 (incidence = 51.7%) cases were unsatisfied with the cosmetic appearance of shoulder and 18 patients (incidence = 62.1%) reported intermittent pain around the shoulder which was mild to moderate in intensity. All other cases had a completely uneventful recovery with constant improvement in shoulder range of motion, strength, functional ability and Constant Shoulder scores.

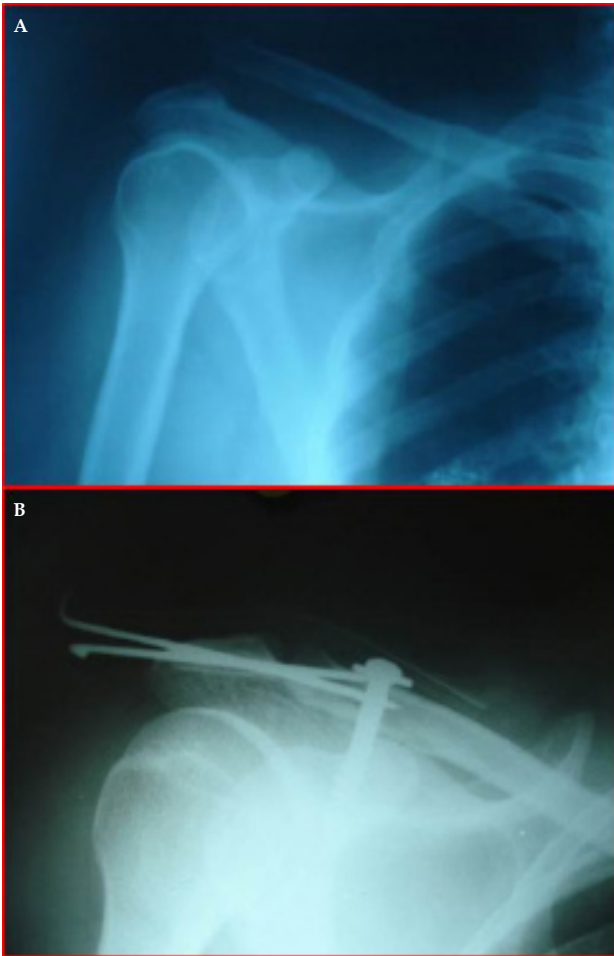


Figure 1 A: Case 1 pre-op X-ray; B: Case 1 post-op X-ray.

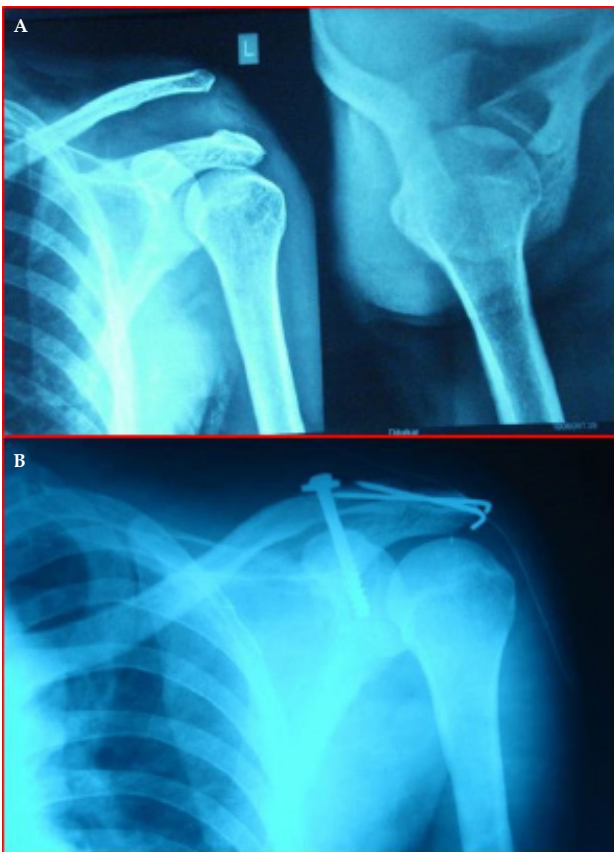

Figure 2 A: Case 2 pre-op X-ray; B: Case 2 post-op X-ray.

Table 5 Mean Constant Shoulder Scores of both groups.

Time	Group A (operative) CS scores	Group B (non-operative) CS scores	T-value	p-value (student t-test)
2 weeks	22	21.1	1.269	$p = 0.2102$
3months	54.5	42.4	15.978	$p \leq 0.0001$
6months	76.5	63.9	26.959	$p \leq 0.0001$
12months	93	83.5	12.53	$p \leq 0.0001$
36 months	93.3	86.6	8.158	$p \leq 0.0001$

CS score: Constant Shoulder Score.

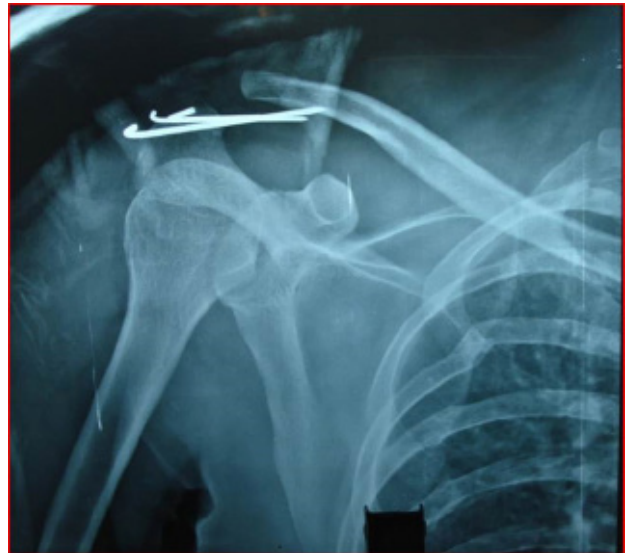


Figure 3 K-wire back-out.

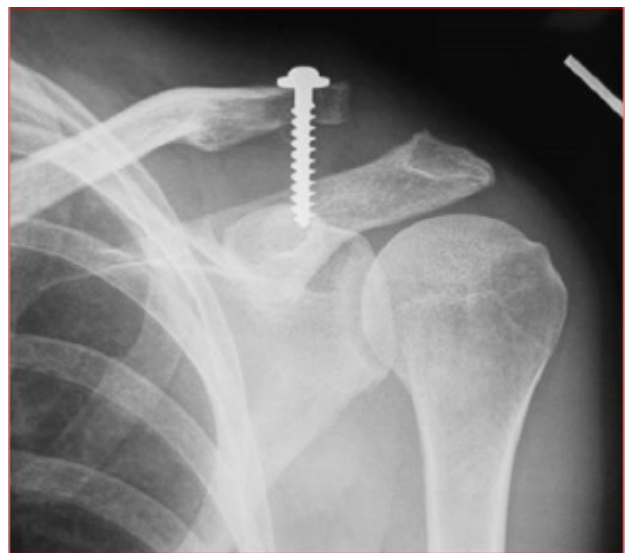


Figure 4 Coracoclavicular screw pull-out.

## DISCUSSION

Historically most of these cases have been treated conservatively with various bandages, slings and rest<sup>[1]</sup>. But as the technology improved and functional demands of the patients increased, the importance of having a perfect acromioclavicular joint with normal shoulder biomechanics became more obvious. The stability of acromioclavicular joint depends upon the ligamentous structures around it<sup>[1]</sup>. Most important is the coracoclavicular ligament<sup>[1]</sup>. This ligament is majorly involved in weight transmission across



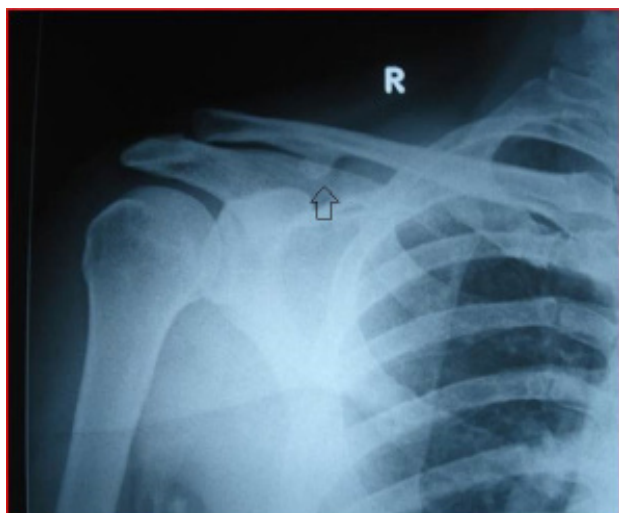


Figure 5 Heterotopic Ossification.

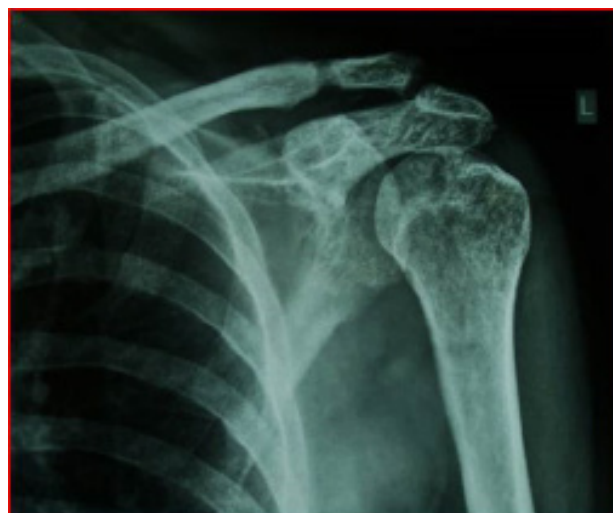

Figure 6 Distal clavicle osteolysis.

the pectoral girdle<sup>[1]</sup>. Currently, conservative treatment is indicated in Rockwood type I and II injuries only and types IV, V, VI are universally accepted as indications for operative management<sup>[1,2,4]</sup>. The treatment of type III acromioclavicular joint injuries is still controversial<sup>[1,2,3,4,5]</sup>. Although, various studies have compared operative and non-operative treatment methods, but there is lack of consistency in the treatment methods employed in these studies<sup>[1,2,3]</sup>. The use of numerous non-operative methods like strapping, slings, bandages, braces, etc. have been reported<sup>[1,3,6-9]</sup>. Many authors have reported good results with non-operative treatments and outcomes as good as operative treatments with relatively less complications<sup>[3,6-13]</sup>. Operative modalities have been broadly divided into intra-articular fixations, coracoclavicular repairs and ligament reconstruction procedures<sup>[1]</sup>. Intra-articular fixation includes use of Steinmann pins, K-wires, tension band wiring etc. for maintaining joint reduction and many authors have reported technical difficulties with placing of pins across the joint and also the fixation is less rigid with early loss of reduction and hardware pull-out<sup>[1]</sup>. Ligament reconstruction procedures like anatomical reconstructions and Weaver-Dunn procedures have gained widespread popularity recently<sup>[1,14]</sup>. Coracoclavicular repairs can be achieved with coracoclavicular screw, Dacron cerclage technique, mersilene tapes, biological screws etc<sup>[1,15,16-21]</sup>. The treatment of acromioclavicular joint injuries with coracoclavicular repair is based upon the fact that coracoclavicular ligament is ruptured in all cases of complete acromioclavicular dislocations<sup>[1]</sup>. Consequently the gap between coracoid process and clavicle increases and also weight transmission across pectoral girdle is hampered<sup>[1]</sup>. Coracoclavicular repairs helps in normalising the clavicle-coracoid process gap and apposes torn edges of coracoclavicular ligament for good healing<sup>[1]</sup>. The use of open and percutaneous techniques for coracoclavicular screw placements has also been reported<sup>[24]</sup>. But fixation with only coracoclavicular screw was reported to produce results only comparable to non-operative management and was associated with high complication rates of hardware failure<sup>[15,22-24]</sup>. To provide a stable joint, generally two or three surgical modalities like K-wire with ligament reconstruction or ligament repair with tension band wiring are combined. In 2006 Lin *et al* compared coracoclavicular fixation and acromioclavicular joint tension band wiring against coracoclavicular fixation and coracoacromial ligament reconstruction and found comparable outcomes in both the groups<sup>[5]</sup>. In this study, we combined the two surgical modalities of intra-articular K-wires and coracoclavicular

repair with screw to provide a more rigid construct and at the same time to decrease the common complications like hardware pull-out. On final analysis, we found that Constant Shoulder Score improvement was significantly ( $p$  value  $\leq 0.0001$ ) better in operatively treated group as compared to the non-operatively managed cases. In group A, only 20% cases reported complications as compared to about 69% cases reporting complications from the non-operatively treated group. This study shows that type III acromioclavicular dislocations can benefit from timely operative intervention in the form of combined intra-articular K-wire fixation and coracoclavicular repair with screw. Although non-operatively managed cases also showed constant improvement in Constant Shoulder Scores in this study but operatively managed cases performed significantly better both in terms of functional outcomes and complication rates.

## REFERENCES

1. Leesa MG, Ronald FH Jr, Gerald RW Jr. Acromioclavicular Joint Injuries. In: Bucholz R W, Heckman J D, Court-Brown C M, Tornetta P, editors. Rockwood And Green's Fractures In Adults, 7th edn. Philadelphia, Pa, USA: Lippincott Williams & Wilkins; 2010. p. 1210-42.
2. Kovilazhikathu Sugathan H, Dodenhoff RM. Management of Type 3 Acromioclavicular Joint Dislocation: Comparison of Long-Term Functional Results of Two Operative Methods. *ISRN Surg.* 2012; **2012**: 580504. [DOI: 10.5402/2012/580504]; [PMCID: PMC3384938]
3. Spencer EE Jr. Treatment of grade III acromioclavicular joint injuries: a systematic review. *Clin Orthop and Rel Research* 2007; **455**: 38-44. [DOI: 10.1097/BLO.0b013e318030df83]; [PMID: 17179783]
4. Trainer G, Arciero RA, Mazzocca AD. Practical management of grade III acromioclavicular separations. *Clinical Journal of Sport Medicine.* 2008; **18(2)**: 162-166. [DOI: 10.1097/JSM.0b013e318169f4c1]; [PMID: 18332693]
5. Lin WC, Wu CC, Su CY, Fan KF, Tseng IC, Chiu YL. Surgical treatment of acute complete acromioclavicular dislocation: comparison of coracoclavicular screw fixation supplemented with tension band wiring or ligament transfer. *Chang Gung Medical Journal.* 2006; **29(2)**: 182-189. [PMID: 16767967]
6. Schlegel TF, Burks RT, Marcus RL, Dunn HK. A prospective evaluation of untreated acute grade III acromioclavicular separations. *Am J Sports Med* 2001; **29(6)**: 699-703. [DOI: 10.1177/03635465010290060401]; [PMID: 11734479]
7. McFarland EG, Blivin SJ, Doehring CB, Curl LA, Silberstein

- C. Treatment of grade III acromioclavicular separations in professional throwing athletes: results of a survey. *Am J Orthop* 1997; **26**: 771-774. [PMID: 9402211]
8. Press J, Zuckerman JD, Gallagher M, Cuomo F Treatment of grade III acromioclavicular separations. Operative versus nonoperative management. *Bull Hosp Jt Dis* 1997; **56**: 77-83. [PMID: 9220095]
  9. Rawes ML, Dias JJ. Long-term results of conservative treatment for acromioclavicular dislocation. *J Bone Joint Surg* 1996; **78B**: 410-412. [PMID: 8636176]
  10. Calvo E, López-Franco M, Arribas IM. Clinical and radiologic outcomes of surgical and conservative treatment of type III acromioclavicular joint injury. *Journal of Shoulder and Elbow Surgery*. 2006; **15(3)**: 300-305. [DOI: 10.1016/j.jse.2005.10.006]; [PMID: 16679228]
  11. Nissen CW, Chatterjee A. Type III acromioclavicular separation: results of a recent survey on its management. *The American Journal of Orthopedics*. 2007; **36(2)**: 89-93. [PMID: 17405638]
  12. Larsen E, Bjerg-Nielsen A, Christensen P. Conservative or surgical treatment of acromioclavicular dislocation. A prospective, controlled, randomized study. *J Bone Joint Surg* 1986; **68A**: 552-55. [PMID: 3514625]
  13. Taft TN, Wilson FC, Oglesby JW. Dislocation of the acromioclavicular joint. An end result study. *J Bone Joint Surg* 1987; **69A**: 1045-51. [PMID: 3654696]
  14. Adam FF, Farouk O. Surgical treatment of chronic complete acromioclavicular dislocation. *International Orthopaedics*. 2004; **28(2)**: 119-22. [DOI: 10.1007/s00264-003-0520-3]; [PMID: 15224170]
  15. Bannister GC, Wallace WA, Stableforth PG, Hutson MA. The management of acute acromioclavicular dislocation. A randomized prospective controlled trial. *J Bone Joint Surg* 1989; **71B**: 848-50. [PMID: 2684990]
  16. Sundaram N, Patel DV, Porter DS. Stabilization of acute acromioclavicular dislocation by a modified Bosworth technique: a long-term follow-up study. *Injury* 1992; **23(5)**: 189-93. [DOI: 10.1016/S0020-1383(05)80043-9]; [PMID: 1587571]
  17. Guy DK, Wirth MA, Griffin JL, Rockwood CA Jr. Reconstruction of chronic and complete dislocations of the acromioclavicular joint. *Clin Orthop* 1998; **347**: 138-49. [PMID: 9520884]
  18. Talbert TW, Green JR 3rd, Mukherjee DP, Ogden AL, Mayeux RH. Bioabsorbable screw fixation in coracoclavicular ligament reconstruction. *J Long Term Eff Med Implants* 2003; **13(4)**: 317-23. [DOI: 10.1615/JLongTermEffMedImplants.v13.i4.50 ]; [PMID: 14649570]
  19. Stam L, Dawson I. Complete acromioclavicular dislocations: treatment with a Dacron ligament. *Injury* 1991; **22**: 173-76. [DOI: 10.1016/0020-1383(91)90034-C]; [PMID: 1830031]
  20. Goldberg JA, Viglione W, Cumming WJ, Waddell FS, Ruz PA. Review of coracoclavicular ligament reconstruction using Dacron graft material. *Aust NZ J Surg* 1987; **57**: 441-45. [DOI: 10.1111/j.1445-2197.1987.tb01394.x ]; [PMID: 2955777]
  21. Morrison DS, Lemos MJ. Acromioclavicular separation. Reconstruction using synthetic loop augmentation. *Am J Sports Med* 1995; **23**: 105-10. [DOI: 10.1177/036354659502300118]; [PMID: 7726339]
  22. Bosworth BM. Acromioclavicular separation: new method of repair. *Surg Gynecol Obstet* 1941; **73**: 866-71.
  23. Galpin RD, Hawkins RJ, Grainger RW. A comparative analysis of operative versus nonoperative treatment of grade III acromioclavicular separations. *Clin Orthop* 1985; **193**: 150-55. [PMID: 3971615]
  24. Tsou PM. Percutaneous cannulated screw coracoclavicular fixation for acute acromioclavicular dislocations. *Clin Orthop* 1989; **243**: 112-2. [PMID: 2721050]
- Peer reviews:** Abdel-Rahman Aly; Rubén Arellano; Ashish Babhulkar