

Anomalous Muscles, A Rare Cause of Carpal Tunnel Syndrome: A Case Report

Bakriga Batarabadja, Amouzou Komla Séna, Ayouba Gamal, Kombate Noufanangue, Dellanh Yanick, Walla Atchi, Abalo Anani, Dossim Assang

Bakriga Batarabadja, Amouzou Komla Séna, Ayouba Gamal, Kombate Noufanangue, Dellanh Yanick, Walla Atchi, Abalo Anani, Dossim Assang, Department of Orthopaedic Surgery. Teaching university hospital Sylvanus Olympio of Lomé, Togo

Conflict-of-interest statement: The author(s) declare(s) that there is no conflict of interest regarding the publication of this paper.

Open-Access: This article is an open-access article which was selected by an in-house editor and fully peer-reviewed by external reviewers. It is distributed in accordance with the Creative Commons Attribution Non Commercial (CC BY-NC 4.0) license, which permits others to distribute, remix, adapt, build upon this work non-commercially, and license their derivative works on different terms, provided the original work is properly cited and the use is non-commercial. See: <http://creativecommons.org/licenses/by-nc/4.0/>

Correspondence to: Bakriga Batarabadja, Department of Orthopaedic Surgery. Teaching university hospital Sylvanus Olympio of Lomé, Togo.

Email: mbakriga@gmail.com
Telephone: +228 90083878

Received: January 3, 2017

Revised: February 1, 2017

Accepted: February 4, 2017

Published online: February 28, 2017

ABSTRACT

Carpal tunnel syndrome (CTS) is secondary to compression or irritation of the median nerve in the osteofibrous canal formed by the flexor retinaculum and the carpal bones. The prevalence rate in the general population is between 7 and 19%. Several local and systemic causes have been described, but muscular abnormalities have rarely been reported in the literature. We report a clinical case that we encountered during a carpal tunnel release in our practice. A 62-year-old right handed, female patient, presented to the orthopedic consultation with paraesthesia of the first three fingers. The electromyogram showed motor deficiency in loaf

muscles therefore, allowed the diagnosis of CTS. The patient underwent surgery for CTS release. There was anomalous muscles attached to the palmaris longus, which was excised and the canal left open. At six months follow up all the symptoms of CTS completely resolved. Muscular abnormalities are found mainly in manual workers. Those abnormalities concern three muscles: the palmaris longus, the flexor digitorum superficialis of index, and the lumbricals. These muscles can be hypertrophied, bifid, duplicated, digastric, inverted or have an abnormal insertion, thus creating a mechanical restriction of the carpal tunnel. It is relevant to think about a muscular cause in clinical atypical presentation of carpal tunnel syndrome and MRI investigation. Complete and successful surgical resection of abnormal muscle provides excellent functional recovery.

Key words: Carpal tunnel syndrome; anomalous muscles; Togo

© 2017 The Author(s). Published by ACT Publishing Group Ltd. All rights reserved.

Bakriga B, Amouzou KS, Ayouba G, Kombate N, Dellahn Y, Walla A, Abalo A, Dossim A. Anomalous Muscles, A Rare Cause of Carpal Tunnel Syndrome: A Case Report. *International Journal of Orthopaedics* 2017; 4(1): 705-707 Available from: URL: <http://www.ghrnet.org/index.php/ijo/article/view/1959>

INTRODUCTION

Carpal tunnel syndrome (CTS) is secondary to compression or irritation of the median nerve in the osteofibrous canal, which is formed by the flexor retinaculum and the carpal bones. The CTS is the most common peripheral nerve entrapment syndrome worldwide^[1]. Widely described as the most common mono-neuropathy, CTS has an estimated incidence of 99/100 000 / year^[2,3]. The prevalence rate in the general population is between 7 and 19%^[4]. CTS pathogenesis is not well known in most cases, which are called idiopathic cases^[5]. Several local and systemic causes have been described^[6], but muscular abnormalities have rarely been reported in the literature^[7]. We report a clinical case that we encountered during a carpal tunnel release in our practice.

PATIENT AND OBSERVATION

A 62-year-old right handed, female patient with no medical history known, presented to the orthopedic consultation with paraesthesia of the first three fingers for a year. Clinical examination did not show any signs of deficiency in the median nerve area and no lump was felt within the palm. The electromyogram showed motor deficiency in loaf muscles therefore, allowed the diagnosis of CTS. The patient underwent surgery three months after the first consultation. After section of the flexor retinaculum (Figure 1), the median nerve was found compressed by a supranumerary muscle (Figure 2). There was a muscle attached to the palmaris longus. There was a lower insertion on the lower palmaris longus tendon. The anomalous muscle was excised and the canal left open. At six month, follow up all the symptoms of CTS completely resolved.

DISCUSSION

In most cases of CTS, no cause is identified. In some cases local or systemic issues as diabetes, hypothyroidism, alcohol consumption, and pregnancy have been reported as etiologies of CTS^[2,3,8,9]. Local causes, such as wrist fractures or tumor, compression are also reported^[10,11]. Muscular abnormalities are found mainly in manual workers. Those abnormalities concern three muscles: the palmaris longus^[12-13], the flexor digitorum superficialis of index^[14], and the lumbricals^[15]. These muscles can be hypertrophied, bifid, duplicated, digastric, inverted or have an abnormal insertion, thus creating a mechanical restriction of the carpal tunnel. The literature reports only isolated cases of such abnormalities. For Weißenborn and Sabri^[16], muscle abnormalities accounted for 0.8% of a total of 856 CTS in their study. The diagnosis may be referred to a patient not belonging to the usual age group with symptoms triggered or aggravated by manual activities. Modern imaging, as ultrasonography^[17], OR especially MRI^[18], may reveal the diagnosis, but the identification of the abnormalities remains an intraoperative fortuitous discovery in most cases as in our patient.

CONCLUSION

It is relevant to think about of a muscular cause in clinical atypical presentation of carpal tunnel syndrome and MRI investigation. Complete and successful surgical resection of abnormal muscle provides excellent functional recovery.

REFERENCES

1. Padua L, Coraci D, Erra C, Pazzaglia C, Paolasso I, Loreti C, et al. Carpal tunnel syndrome: clinical features, diagnosis, and management. *Lancet Neurol.* 2016; **15**(12): 1273-84. [PMID: 27751557]; [DOI: 10.1016/S1474-4422(16)30231-9]
2. von Schroeder HP, Botte MJ. Carpal tunnel syndrome. *Hand Clin.* nov 1996; **12**(4): 643-55. [PMID: 895328]
3. Newington L, Harris EC, Walker-Bone K. Carpal tunnel syndrome and work. *Best Pract Res Clin Rheumatol.* 2015; **29**(3): 440-53. [PMID: 26612240]; [PMCID: PMC4759938]; [DOI: 10.1016/j.berh.2015.04.026]
4. Ferry S, Pritchard T, Keenan J, Croft P, Silman AJ. Estimating the prevalence of delayed median nerve conduction in the general population. *Br J Rheumatol.* 1998; **37**(6): 630-5. [PMID: 9667616]
5. Michelsen H, Posner MA. Medical history of carpal tunnel syndrome. *Hand Clin.* 1 mai 2002; **18**(2): 257-68. [PMID: 12371028]
6. Palmer KT. Carpal tunnel syndrome: the role of occupational factors. *Best Pract Res Clin Rheumatol.* 2011; **25**(1): 15-29.

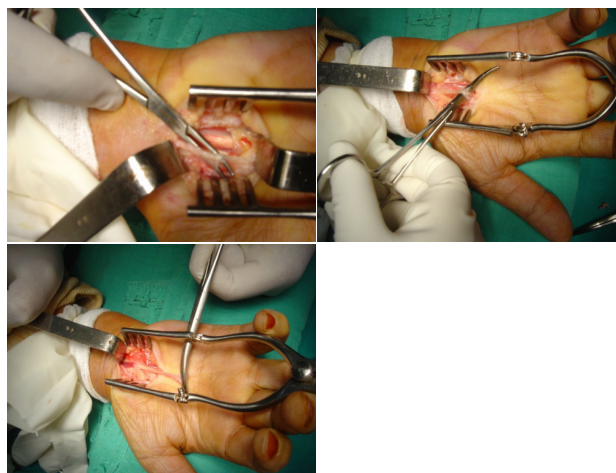


Figure 1 a/b/c Median nerve compressed by supranumerary muscle.

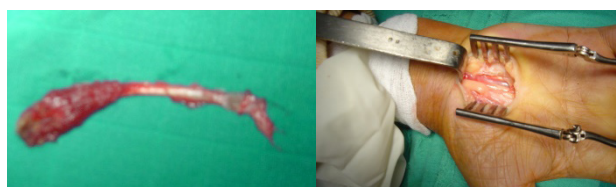


Figure 2 a/b- Resection of abnormal muscle, canal release.

[PMID: 21663847]; [PMCID: PMC3145125]; [DOI: 10.1016/j.berh.2011.01.014]

7. Samson P. Le syndrome du canal carpien. *Chir Main.* déc 2004; **23**, Supplement 1: S165-77. [DOI: 10.1016/j.main.2004.10.016]
8. Lozano-Calderón S, Anthony S, Ring D. The quality and strength of evidence for etiology: example of carpal tunnel syndrome. *J Hand Surg.* 2008; **33**(4): 525-38. [PMID: 18406957]; [DOI: 10.1016/j.jhsa.2008.01.004]
9. Giersiepen K, Spallek M. Carpal tunnel syndrome as an occupational disease. *Dtsch Arzteblatt Int.* 2011; **108**(14): 238-242. [PMID: 21547163]; [PMCID: PMC3087121]; [DOI: 10.3238/arztebl.2011.0238]
10. Niver GE, Ilyas AM. Carpal tunnel syndrome after distal radius fracture. *Orthop Clin North Am.* 2012; **43**(4): 521-7. [PMID: 23026468]; [DOI: 10.1016/j.ocl.2012.07.021]
11. Suginaka H, Hara A, Kudo T. An unusual case of common digital nerve compression caused by a lipoma arising from the flexor tenosynovium. *Hand Surg.* 2013; **18**(03): 435-7. [PMID: 24156595]; [DOI: 10.1142/S0218810413720337]
12. Saraf SK, Tuli SM. Anomalous m. palmaris longus producing carpal tunnel-like syndrome. *Arch Orthop Trauma Surg.* 1991; **110**(3): 173-4. [PMID: 2059545]
13. Depuydt KH, Schuurman AH, Kon M. Reversed palmaris longus muscle causing effort-related median nerve compression. *J Hand Surg Edinb Scotl.* 1998; **23**(1): 117-9. [PMID: 9571503]
14. Smith RJ. Anomalous muscle belly of the flexor digitorum superficialis causing carpal-tunnel syndrome. *Report of a case. J Bone Joint Surg Am.* 1971; **53**(6): 1215-6. [PMID: 5092807]
15. Eriksen J. A case of carpal tunnel syndrome on the basis of an abnormally long lumbrical muscle. *Acta Orthop Scand.* 1973; **44**(3): 275-7. [PMID: 4768793]
16. Weißenborn W, Sabri W. [Muscle anomalies as a cause of carpal tunnel syndrome]. *Handchir Mikrochir Plast Chir.* 1987; **19**(3): 153-5. [PMID: 3596372]
17. Pardal-Fernandez JM. [Carpal tunnel syndrome. The contribution of ultrasonography]. *Rev Neurol.* 2014; **59**(10): 459-69. [PMID: 25354508]

18. Zeiss J, Jakab E. MR demonstration of an anomalous muscle in a patient with coexistent carpal and ulnar tunnel syndrome. Case report and literature summary. *Clin Imaging*. 1995; **19**(2): 102-5.

[PMID: 7773871]

Peer reviewers: Tetsuya Shinozaki