

Review Outcome of Combined Open Reduction and Femoral Shortening Osteotomy for Developmental Dysplasia of the Hip in Children

Nguyen Ngoc Hung, Hoang Hai Duc

Nguyen Ngoc Hung, MD, PhD, Associate Professor, Viet Nam National Hospital For Pediatrics, 18/879 La Thanh Road, Dong Da District, Ha Noi, Viet Nam

Hoang Hai Duc, M.D, Viet Nam National Hospital For Pediatrics, 18/879 La Thanh Road, Dong Da District, Ha Noi, Viet Nam

Conflict-of-interest statement: The author(s) declare(s) that there is no conflict of interest regarding the publication of this paper.

Open-Access: This article is an open-access article which was selected by an in-house editor and fully peer-reviewed by external reviewers. It is distributed in accordance with the Creative Commons Attribution Non Commercial (CC BY-NC 4.0) license, which permits others to distribute, remix, adapt, build upon this work non-commercially, and license their derivative works on different terms, provided the original work is properly cited and the use is non-commercial. See: <http://creativecommons.org/licenses/by-nc/4.0/>

Correspondence to: Nguyen Ngoc Hung, MD, PhD, Associate Professor, Viet Nam National Hospital For Pediatrics, 18/879 La Thanh Road, Dong Da District, Ha Noi, Viet Nam.

Email: ngocyenhung@gmail.com

Telephone: +84-4-37841276

Received: January 4, 2017

Revised: January 22, 2017

Accepted: January 25 2017

Published online: February 28, 2017

ABSTRACT

BACKGROUND: Reports of the efficacy of Open reduction combined femoral shortening osteotomy on children for developmental dislocation of the hip. Surgical outcomes were evaluated clinically and roentgenographically.

METHODS: We performed a retrospective match-controlled study in which 58 patients, they were surgical femoral shortening osteotomy following Open reduction, Zigzag Osteotomy, Fibular Allograft (ZOFA) and femoral shortening osteotomy. Deformity of femoral head or neck or acetabulum according to the Severin,

Avascular Necrosis (AVN) according to Kalamchi, Clinical evaluation according to Barrett modified McKay criteria.

RESULTS: Between 2009 and 2014, Femoral shortening Osteotomy For 58 Hips (all patients operated unilateral side). There were 42 (72.4%) were girls and 16 (27.6%) were boys. None had preoperative skin or skeletal traction, nor derotational varus or valgus osteotomies. The Femoral Neck Anteversion angle: Average 27.726° (SD = 12.153), The Shaft - Neck angle: Average 149.649° (SD = 5.815), The Femoral Neck - Shaft angle: Average 162° (SD = 8.642). Average age at femoral shortening osteotomy was 29.9 months (range, 14-36 months). Average distance shortening osteotomy was 1.52 cm. Duration of the Follow-up was 28.6 months (range, 24-62 months); Average age at latest Follow-up 66.3 months (range, 38-85 months); There were 1 (1.7%) Trendelenberg gait. AVN in 9 (15.5%). Subluxation in 2 (3.4%). At latest result: Excellent in 44 (75.9%), Good in 8 (13.8%), Fair 4 (6.9%), and Poor 2 (3.4%); Satisfy Results (Excellent and Good) of Open reduction and Femoral Shortening in 52 (97.5%). The femoral head or neck or acetabulum were normal in 44 (75.9%) hips.

CONCLUSIONS: On the basis of this study, the femoral shortening Osteotomy reduce incidence AVN, Re-Dislocation, and improved Postoperative result.

Key words: DDH; Redislocation; Revision surgery; Hip dysplasia; Bone Allograft; Salter's osteotomy; Avascular necrosis

© 2017 The Author(s). Published by ACT Publishing Group Ltd. All rights reserved.

Hung NN, Duc HH. Review Outcome of Combined Open Reduction and Femoral Shortening Osteotomy for Developmental Dysplasia of the Hip in Children. *International Journal of Orthopaedics* 2017; 4(1): 695-704 Available from: URL: <http://www.ghrnet.org/index.php/ijo/article/view/1960>

INTRODUCTION

Developmental dysplasia of the hip (DDH) encompasses a spectrum of diseases that include hip instability, hip subluxation with underdeveloped acetabulum and incomplete coverage of the femoral

head and hip dislocation. In addition, contractures must be overcome before or at the time of reduction to avoid excessive pressure on the developing capital femoral ossific nucleus, which may lead to AVN.

Untreated hip dysplasia can lead to early onset arthritis, joint destruction and ultimately the need for joint replacement^[1] which adversely affect patient's quality of life. Thomas *et al* in 2007 with follow-up^[2] study at 40-45 years after open reduction and innominate osteotomy for late presenting DDH, reported an excellent prognosis in two third of the patients. Favorable coverage of the^[3] femoral head was reported to be obtained gradually by shifting the center of the femoral head caudally and medially as well as rotating the distal fragment anterolaterally^[4].

The use of femoral shortening has been shown to decrease the complications associated with open reduction, particularly redislocation and AVN^[5]. Once the child achieves walking age, treatment becomes more extensive. In the management of age group 18-24 months, majority of surgeons agree on open reduction and hip spica cast and a supplementary procedure like a proximal femoral osteotomy is usually not necessary in this age group^[6].

The purpose of this study was reviewed the clinical and radiological outcome following Open reduction, and femoral shortening osteotomy.

MATERIALS AND METHODS

After obtaining approval from our institutional review board, we queried the surgical database at our center to identify all patients who had undergone an open reduction, ZOFA^[7], and femoral shortening osteotomy for the treatment of DDH with. Patients with teratologic dislocations, neuromuscular or connective tissue disorders, and those patients with a history of a previous open hip procedure at another institution were excluded from the study. This study group was composed of patients with a diagnosis of DDH who were operated on between 2009 and 2014. Informed consent was obtained from all participants.

The study had the approval of the Ethical Review Committee of our Institute and was carried out in accordance with the tenets of the Declaration of Helsinki.

Between 2009 and 2014, Open reduction, ZOFA and Femoral shortening Osteotomy For 58 Hips (all patients operated unilateral side). There were 42 (72.4%) were girls and 16 (27.6%) were boys. None had preoperative skin or skeletal traction, nor derotational varus or valgus osteotomies. Average age at femoral shortening osteotomy was 29.9 months (range, 14-36 months) and Average age at latest Follow-up 66.3 months (range, 38-85 months) and Duration of the Follow-up was 28. 6 months (range, 24-62 months).

Femoral Neck Anteversion angle

The angle of torsion is called anteversion, anterotation, or anterior twist; similarly, if it points backward (posterior to the transcondylar plane), it is called retroversion, retortorsion, or posterior twist^[8].

There are many imaging methods described and used for measuring femoral anteversion, we agree Ruby's opinion favor the use of the Ryder-Crane technique^[9].

Biplanar method (Ryder-Crane)^[9]: With this technique, all roentgenograms are made with the patient supine. The x-ray tube is positioned directly over the hip. One roentgenogram is made with the limb in neutral position (extended) and a second with the hips and knees flexed to 90 degrees and with the thighs abducted to 30 degrees, the position being maintained by a specially constructed box. Lines representing the axis of the neck and the shaft of the femur

are drawn of the first roentgenogram. This is the apparent angle of torsion. The true torsion is determined by reference to a standard table of angles derived from trigonometric considerations.

Femoral Shaft-Neck angle

Using the AP view of the hip, angle formed by axis of femoral shaft and line drawn along axis of femoral neck passing through center of head of femur.

Surgical technique of Femoral shortening Osteotomy

Femoral shortening should be performed 6-8 weeks after open reduction, ZOFA, Pre-Operation with high Dislocation and femoral neck-shaft angle more 150 degrees (Figure 1).

Through a separate lateral approach, the proximal end of the femur was exposed subperiosteally and with osteotomy by cutting away a proximal portion of the distal fragment. The bone must be shortened sufficiently accommodate for the shortening of the muscle. The amount of operative shortening to be done is determined in the following way: after reducing the head into the acetabulum, the fragment are put together and the overriding end of the distal fragment is removed. Surgical shortening usually amounted to from one to two centimeters long, sufficient to relieve the muscular tension across the hip joint, fragments were allowed to overlap, and reduction was obtained quite easily. In performing intertrochanteric osteotomy we first detach the lesser trochanteric and re-attach it after the shortening. Derotation is performed by internal rotation of the upper fragment around the distal one. In oblique osteotomy the fragment are fixed by two wire loops both fragment (Figures 2 and 3).

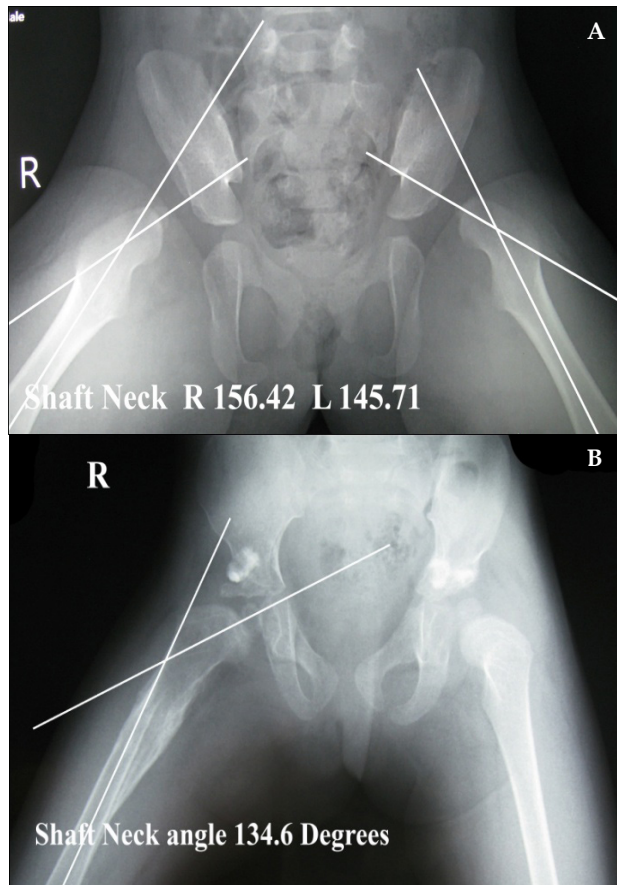


Figure 1 A. Pre-Operative Right Hip with Shaft Neck angle 156.4 Degrees; B. Post-Operative 22 weeks with Shaft Neck angle 134.6 Degrees.

Postoperative care

The double spica cast was applied immediately after surgery, hip in 30 degrees of flexion, 50 degrees of abduction, and 20 degrees of internal rotation.

The postoperative femoral shortening Osteotomy at Six to Eight weeks (twelve-fourteen weeks after surgery of Open reduction, ZOFA and Femoral shortening osteotomy), the entire cast is removed, and Patients then wear the abduction orthosis full-time except for

bathing (during which time the hips are kept in abduction). At about 6 months after surgery, the patient is gradually weaned from the brace to wear haft spica cast it only at night and nap time until acetabular development is normal. The haft spica cast (Figure 4) is usually worn for an average of 12 to 24 months after surgery. Weight bearing was not allowed until radiographic evidence of healing of the osteotomy site was obtained.

In bilateral cases, the other hip was operated upon after 3 months from the first side, and then the hip spica cast was applied for immobilization of both hips.

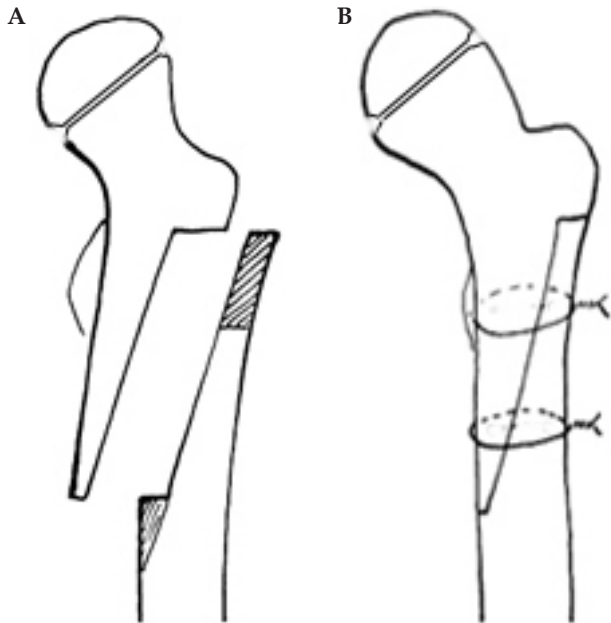


Figure 2 A. Shortening of the femur; B. Two steel wire loops both fragments.

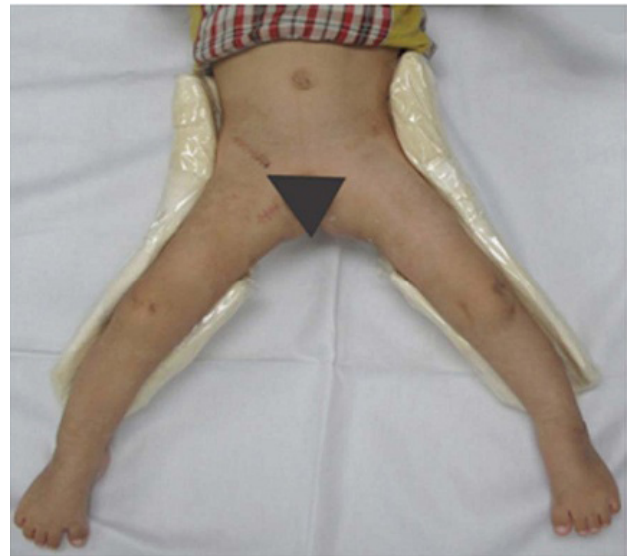

Figure 4 Patient is weared haft spica cast.

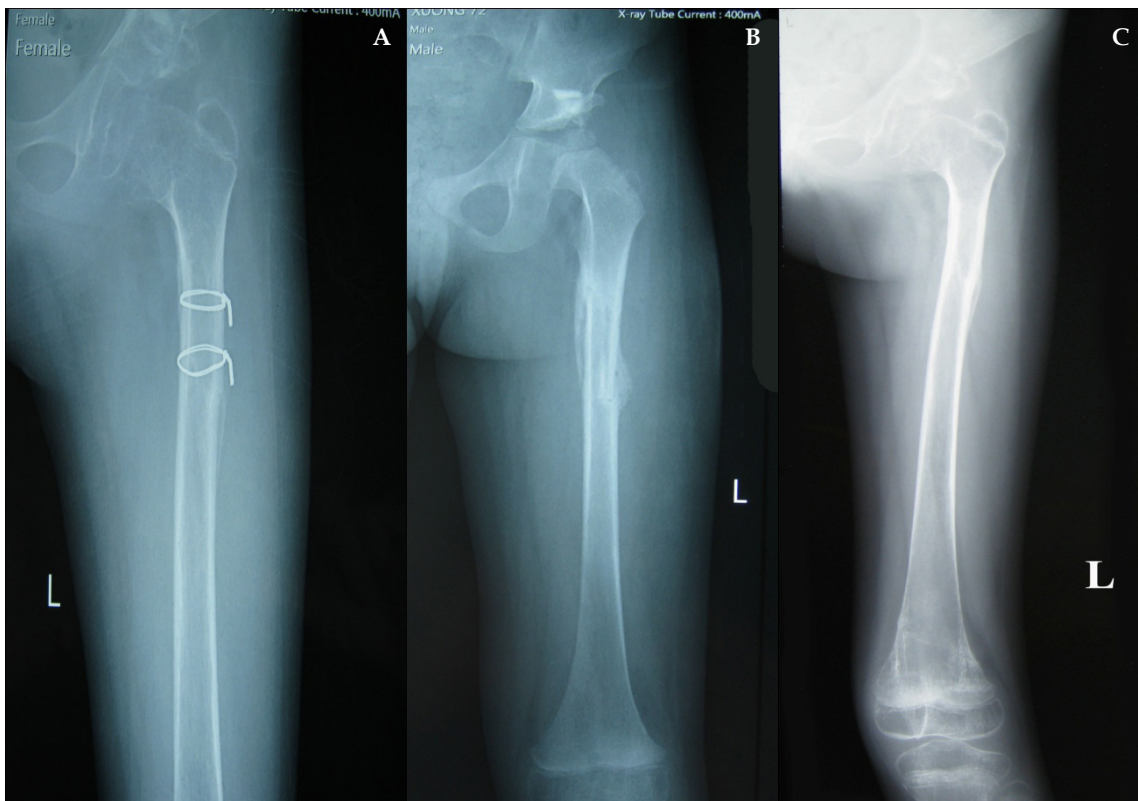


Figure 3 A. The fragment are fixed by two wire loops wire; B. Post-Operative 12 weeks; C. Post-Operative 20 weeks.

The allograft was considered to have been stable if the correction of the dysplastic acetabulum was maintained during the 2-year post-operative period and non extrusion of the graft had occurred from the osteotomy site. Fibular allograft incorporation into the ilium was considered to have taken place if complete union at the osteotomy site had occurred and confluence of the graft to the ilium was evident on the X-rays.

Evaluating result

The patients were scheduled to return to the outpatient clinic at three months intervals during the first day post-operatively and at 3 months, 6 months, 1 year, and 2 years after surgery and then at yearly intervals. The patients were evaluated clinically during each visit as to the range of motion of the affected hip, the quality of gait, Trendelenburg test, and the presence of any pain. Radiographs of each hip were made to assess the quality of reduction, the acetabular index, and the presence or absence of avascular necrosis. Each patient's preoperative radiographs were evaluated to determine the affected hip's acetabular index and station.

Limb length discrepancy can be measured by a physician during a physical examination and through X-rays. Usually, the physician measures the level of the hips when the child is standing barefoot. A series of measured wooden blocks may be placed under the short leg until the hips are level. If the physician believes a more precise measurement is needed, he or she may use X-rays. In growing children, a physician may repeat the physical examination and X-rays every six months to a year to see if the limb length discrepancy has increased or remained unchanged.

Assessment of AVN of the femoral head was performed according to Kalamchi and MacEwen's classification^[10]: Grade 1: Changes affecting the ossific nucleus; Grade 2: Lateral physeal damage; Grade 3: Central physeal damage; Grade 4: Total damage to the head and physis.

Details of radiological according to the Severin^[11] was used for the radiologic assessment of postoperative results: Gade 1: Normal; Grade 2: Moderate deformity of femoral head or neck or acetabulum; Grade 3: Dysplastic no subluxed; Grade 4: Subluxed; Grade 5: Head articulating with secondary acetabulum in upper of the original acetabulum; Grade 6: Dislocated; Grade 7: Arthritic.

Barrett's modification of McKay's criteria^[12] was used for the clinical assessment of postoperative results: Excelent result: Stable, painless hip, no limp, negative Trendelenburg sign, full range of motion. Good result: Stable, painless hip, slight limp, slight degree in range of motion. Fair result: Stable, painless hip, limp, positive Trendelenburg sign, and limited range of motion, or a combination of these. Poor result: Unstable or painful hip, or both; positive Trendelenburg sign.

Method of statistical analysis

Statistical analysis was done using the statistical program for social sciences (SPSS)-version 9.0. T-test was used to analyze the relations between the obtained results and the different variables. Five percent level of significance was chosen.

RESULT

Between 2009 and 2014, there were 58 Hips in 58 Patients with DDH underwent open reduction, ZOFA and Femoral shortening Osteotomy.

None had preoperative skin or skeletal traction, nor derotational varus or valgus osteotomies or shortening procedures, and second

operation with femoral shortening osteotomy in 58 Hips. Average distance shortening osteotomy was 1.52 cm.

The Femoral Neck Anteversion angle: Average 27.726° (SD = 12.153).

The Shaft – Neck angle: Average 149.649° (SD = 5.815).

The Femoral Neck - Shaft angle: Average 162° (SD = 8.642).

There were 16 Male (26.2%) and 42 (73.8%) Female; Right Hip in 12, 42 Left Hip in 30, Bilateral hip in 4 with affected Left hip; Average age at femoral shortening osteotomy was 29.9 months (range, 14-36 months). Average distance shortening osteotomy was 1.52 cm. Duration of the Follow-up was 28. 6 months (range, 24-62 months); Average age at latest 66.3 months (range, 38-85 months). There were 2 (3.4%) Trendelenberg gait. At latest result: Excellent in 44 (75.9%), Good in 8 (13.8%), Fair 4 (6.9%), and Poor 2 (3.4%). Details of radiological according to Severin with 44 (75.9%) in Grade I, 8 (13.8%) in Grade II, 4 (6.9%) in Grade III, 2 (3.4%) in Grade IV.

Avascular Necrosis Classification according to the Kalamchi [10] there were 9 (15.5%) AVN in with Grade I: 2 (22.2%), Grade II: 6 (66.7%), Grade III: 1 (11.1%).

Deficiency of leg length: Deficiency of leg length 1 cm: 3 (5.2%), Deficiency 2 cm: 2 (3.4%), and normal leg limb 53 (91.4%).

Deformity of femoral head or neck or acetabulum according to Severin^[11].

Details of radiological according to Severin with 44 (75.9%) in Grade I, 8 (13.8%) in Grade II, 4 (6.9%) in Grade III, 2 (3.4%) in Grade IV.

Clinical evaluation according to Barrett modified McKay criteria^[12].

At latest result of Clinical evaluation according to modified McKay criteria: Excellent in 44 (75.9%), Good in 8 (13.8%), Fair 4 (6.9%), and Poor 2 (3.4%). Satisfy Results (Excellent and Good) of Open reduction and Femoral Shortening: 52 (97.5%).

Complications

1. Subluxation: 2 (3.5%)
2. Avascular Necrosis 9 (15.5%)
3. Infection: 0
4. Fracture: 0
5. Trendelenburg gait: 1 (2.4%).
6. Sciatic nerve damage: 0

DISCUSSION

The principles of treatment of dislocated hip joint for an older child are quite different from those of a new born^[13]. In a child of walking age and beyond, achieving a concentrically reduced hip while minimizing complications is more challenging. In the older child the reduction of hip is difficult because of adaptive shortening of the extra articular soft tissues, acetabular dysplasia, capsular constriction, increased femoral anteversion, fibrofatty tissue in the acetabulum, hypertrophied ligamentum teres, and fixed inversion of limb. If left untreated, these dysplastic changes lead to osteoarthritis in early adulthood^[14].

Femoral Osteotomy

Children who present late with developmental dysplasia of the hip (DDH) may undergo femoral osteotomy. This was first described by Hey-Groves, 1928^[15], and popularised by Somerville and Scott.

1957^[16].

Femoral osteotomy, including shortening, varus osteotomy, or derotation osteotomy or any combination thereof, combined with open reduction, capsulorrhaphy, and possibly, pelvic osteotomy, has been considered by some to be a more extensive procedure than can safely be undertaken in one stage. Although we agree that it is a complicated procedure that should only be attempted by a surgeon who has extensive experience, it can clearly be accomplished safely without a major increase in morbidity compared with open reduction alone.

Femoral osteotomy combined with innominate osteotomy is usually performed to prevent excessive pressure on the head, causing osteonecrosis. This is also done in older children with severe anteversion^[16,17].

Anteversion of the femoral neck

In normal children, femoral anteversion usually measures 30 to 40 degrees at birth and slowly decreases over time to the mean adult value of 13 degrees^[18,19]. Femoral anteversion in normal hips, however, has been reported to be anywhere between 7 to 43 degrees for children 6 years of age, which is near the upper limit of age in our series. Increased femoral anteversion can cause an internal foot progression angle, and some authors have suggested that femoral anteversion may be related to osteoarthritis of the hip and knee^[20]. There was no relationship between age of the patient and the degree of femoral anteversion.

In children with DDH, changes in femoral anteversion and the indications for derotational femoral osteotomy remain controversial. It has generally been accepted that DDH is associated with increased femoral anteversion; however, Sarban *et al*^[21] did not show any significant difference in femoral version between dislocated and unaffected hips in walking-age patients with DDH.

Similar conclusions were drawn by Edelson *et al*^[22]; however, no specific data were mentioned in their report. Several adult series, however, have shown increases in femoral anteversion in DDH compared with controls. Sugano *et al*^[23] found an average of 10 to 14 degrees of increased anteversion in 35 hips with DDH compared with 15 unaffected control hips. Given these differences in opinion with regard to the degree of torsional deformity in DDH, it is not surprising that the indications for derotational osteotomy in walking-age patients remain unclear.

Early studies supported the routine use of femoral derotational osteotomy. In 1984, Berkeley *et al*^[13] reported on a series of 51 hips in children 12 to 36 months of age treated with open reduction. They advised performing a concomitant femoral derotational osteotomy if anteversion exceeded 60 degrees. Although they did not describe their method for assessing femoral anteversion, 85% of the children in their series underwent derotational femoral osteotomy. Wenger *et al*^[5] estimated femoral anteversion by palpating the femoral neck axis in relation to the distal femoral condylar axis and found that femoral anteversion was often increased to 40 to 60 degrees. They usually derotated 30 degrees to avoid potential iatrogenic posterior hip dislocation. In this study, mean femoral neck anteversion with average 27.7° (SD = 12.153) only, so we did not derotational femoral osteotomy.

Recent teachings, however, have moved away from derotational femoral osteotomy. Of the 2 major textbooks in pediatric orthopedic surgery, one advises derotational osteotomy primarily for cases of residual dysplasia, whereas the authors of the other “have not found excessive anteversion of the upper femur to be common and do not usually do derotation correction^[21,22].”

Sankar *et al* in 2011^[24] derotation of the femur is planned if there is more than 50 degrees of femoral anteversion. We advocated those authors’s opinion so did not derotation osteotomy of the femur to correct the anteversion. We didn’t advocate femoral derotational osteotomy in this study.

Femoral Neck Varus

It is known that the formation of coxa vara will increase the burden on the medial physis line and this in turn will accelerate medial augmentation leading, probably, to new vague formation in the hip^[24]. However, varus osteotomy has some drawbacks during or after the operation and at the late stage^[25]. Therefore, this procedure should be implemented only after thorough risk benefit evaluation.

The fact that varus osteotomy alters the mechanical axis of the lower extremity is another less mentioned problem. Suda *et al*^[26] demonstrated that varus osteotomy shifts the mechanical axis of the lower extremity to the medial knee and this in turn causes genu valgum deformity in the knee which persists even after the hip is revalgised. The same authors emphasized that problems may occur in the knees of such patients in longer follow-up periods and for this reason, just as for the hip, the knee also should be followed up.

Odgen *et al*^[27] detected a shift in femur proximal epiphysis in two cases with coxa vara. Again, Lahoti *et al*^[28] reported that they have observed epiphysiolysis in two children treated with derotation varus osteotomy for developmental hip dislocation and have treated both cases with valgisation osteotomy. The biomechanics of the hip can be altered to a great extent by varisation osteotomy. After this operation proximal femoral epiphysis is exposed to increased shearing stress and it is calculated that up to 2.5 times the shearing stress is imposed on the physis line with formation of 30 coxa vara^[36]. Chung *et al* stated that this shearing stress increases with age^[36]. Particularly when neck–shaft angle is reduced to 90, the physis line takes an almost vertical position which constitutes a risk with respect to epiphysiolysis^[27,28].

Pauwels 1980^[29] has suggested that this will cause a faster growth rate medially than laterally, which will eventually correct the orientation of the growth plate and cause progressive correction of the varus. Although some shear forces will be induced across the growth plate it is unlikely that they are responsible for the asymmetrical growth because they are evenly distributed across the plate. Varus deformity also causes relative trochanteric elevation and therefore abductor weakness; this may also contribute to the correction of the varus deformity.

Derotation and varus osteotomy of the femur has two goals. It corrects the almost invariable valgus and anteversion seen with congenital dislocation of the hip, and it further tightens the capsule of the hip by a screw-home mechanism. As an elongated and abnormally shaped hip capsule is of prime aetiological importance in the development of established dislocation, it seems rational to shorten it by plication. Much attention has been focused on the concentricity of hip reduction. This is not, of course, capable of accurate clinical interpretation. If at reduction the femoral head appears to enter deeply into the acetabulum, then reduction is frequently assumed to be concentric. This may well not be the case and indeed arthrography is a more reliable indicator of concentricity than the appearance at operation. Early lack of concentricity may well be partly responsible for the high rate of degenerative changes noted in the patients.

Femoral shortening Osteotomy

Femoral shortening has been shown to facilitate reduction and does not appear to increase the prevalence of osteonecrosis of the femoral

head^[30,5]. Many authors have reported success with a single-stage procedure consisting of open reduction, capsulorrhaphy, femoral shortening, and pelvic osteotomy^[31]. With femoral shortening as the fundamental step, this method can be applied in high dislocations to prevent undue pressure on the femoral head, which is the main cause of avascular necrosis, joint stiffness, and failures.

Since its first description by Hey Groves and Ombrédanne^[15,31] femoral shortening osteotomy has become increasingly popular as an adjunct in the open treatment of developmental dislocation of the hip (DDH). Femoral shortening effectively lengthens the muscles surrounding the hip, thereby reducing the force required to achieve concentric reduction^[32]. The use of femoral shortening has been shown to decrease the complications associated with open reduction, particularly redislocation and AVN^[5,33]. It is generally accepted that “high” dislocations and “older” children are most likely to benefit from a femoral shortening osteotomy. These terms, however, are noticeably ambiguous. We are not aware of any reports that quantify the height of a dislocation and relate this to the need to shorten the femur. Patient age is also an unclear indication for surgery. Klisic and Jancovic^[34] reported good results with femoral shortening in a series of patients older than 5 years of age, whereas Galpin *et al.*^[32] performed femoral shortening osteotomies in all children over 2 years of age. Wenger *et al.*^[5] have even advocated femoral shortening in certain children younger than 2 years of age. In this study, average age at femoral shortening osteotomy was 26.7 months (range, 14-36 months) (Table 1).

Although older children and high dislocations may be more likely to require a femoral shortening osteotomy, the ultimate decision about whether or not to shorten a given femur should depend on the ease of femoral head reduction in that specific patient. We prefer this individualized approach to an algorithm based on strict age or radiographic criteria because there are downsides to performing an unnecessary osteotomy. Adding a femoral shortening procedure increases operating time and blood loss, adds a second incision, and necessitates future hardware removal. In addition, an unnecessary femoral shortening osteotomy could overly decrease the soft tissue tension around the joint, putting the hip at risk for redislocation. Hung^[7] reported with 18 of 139 (13.0%) hips with redislocation in surgical treatment for DDH without Femoral Shortening Osteotomy, there were 2 of 58 hips (3.5%) redislocation in this study with Femoral Shortening Osteotomy, redislocation of femoral shortening osteotomy less than without femoral shortening osteotomy, differ significantly between the two Surgical procedure (*P*Value 0.044166).

Galpin *et al.*^[32] It was concluded that children who are two years or older and who have a congenital dislocation of the hip can safely be treated with an extensive one stage operation consisting of open reduction combined with femoral shortening and, often, pelvic osteotomy, without increasing the risk of avascular necrosis. An osteotomy of the proximal part of the femur to shorten the femur has been recommended to avoid the complication of avascular necrosis^[33]. This operation allows the tight structures that cross the level of the osteotomy to function as if they were lengthened and does so more effectively than a soft tissue release. Hung^[7] reported with 61 of 139 (43.9%) hips with AVN in surgical treatment for DDH without Femoral Shortening Osteotomy, there were 9 of 58 hips (15.5%) in this study with Femoral Shortening Osteotomy. AVN of femoral shortening osteotomy less than without femoral shortening osteotomy, differ significantly between the two Surgical procedure (*P*Value 0.000158).

We performed femoral osteotomy after 6-8 weeks initial operation

when femoral shaft-Neck angle more 150° and high Dislocation with grade IV of Tönnis classification only. The Shaft-Neck angle improved from mean 162 degrees (range, 150 – 171 degrees) to 132 degrees (range 128 – 141 degrees) at latest examination (Figure 1) (Table 2). The latest result with Femoral head or neck or acetabulum were normal according to Severin with 38 (90.5%) in this study. We agree with Kumar *et al.*^[35] opinion that the femoral shortening might prolong the operating time, increase blood loss, or increase the incidence of heterotopic bone formation.

Preoperative limb traction and Femoral Osteotomy

There have been many comparative studies directed at preoperative traction and femoral shortening. Some reported favourable outcomes following femoral shortening with preoperative traction^[36,37]. Others advocated open reduction and femoral shortening without preoperative traction. Satisfactory outcomes were reported in DDH patients aged ≥ 2 years who underwent femoral shortening without preoperative traction^[32]. Preoperative traction decreases technical difficulties during the operation and helps to diminish the length of the excised femoral segment. Open reduction with femoral shortening without preoperative traction was preferred in patients ≥ 3 years, and was associated with lower incidence of avascular necrosis^[5,38]. Schoenecker and Strecker^[33] reported a 54% incidence of avascular necrosis and a 31% incidence of redislocation after the use of skeletal traction in patients older than 3 years. Shih and Shih^[39] found no difference in outcome in patients treated with or without traction. In the present study, complications were fewer in patients who underwent open reduction and femoral shortening without preoperative traction. In this study, we did not use preoperative limb traction on all of our patients.

One-stage open reduction, capsulorrhaphy, Salter’s osteotomy and femoral derotation osteotomy without preliminary traction to relocate congenital dislocation of hips in late presenting children is a safe and highly effective method. It produces a low rate of complication and need for repeat surgery. It reduces the cost of treatment, minimises socioeconomic burden and psychological trauma incurred by lengthy hospitalisation of treatment with traction followed by closed reduction.

Traction has been used before reduction of a dislocated hip to decrease the risk of ischemia of the femoral head, but data supporting use of this treatment are inconsistent^[40].

Gage and Winter^[40] found a positive correlation between the incidence of avascular necrosis and increasing age, inadequate pre-reduction traction, and extreme positions of immobilization. Weiner *et al.* in 1977^[41], demonstrated the value of preoperative traction in reducing the incidence of avascular necrosis after closed reduction; however, nearly one-half of the children in their series who were older than eighteen months had that complication when traction was used for less than three weeks.

Some authors have advocated skeletal traction for older and heavier children^[30,42]. Browne^[30] reviewed a series of thirty hips that had congenital subluxation or dislocation; he stated that soft-tissue release, followed by a period of skeletal traction, was abandoned in 1974 as “being of little value”. The complications in his patients included an increased incidence of infection from contaminated pin sites at the time of open reduction. The possibility of injury to the distal femoral physis and to the sciatic nerve are theoretical risks that are inherent in treatment with traction.

Haidar *et al.* used skin traction for 2 weeks before simultaneous open reduction and Salter osteotomy^[43]. Only 3 of 37 hips had femoral head deformity from osteonecrosis and 4 hips had

Table 1 Information of Patients.

Case	Sex	Hip	Age at Operation (months)	Duration of Follow - up (months)	Age at Follow-up (months)	Deficient Limb length (cm)	Gait	Barrett modified Mackey's criteria[13]
1	F	L	18	39	57		Normal	Excellent
2	F	L	16	45	61		Normal	Excellent
3	M	L	29	42	71	-2	Trendelenberg	Fair
4	F	R	14	48	62		Normal	Excellent
5	F	L	32	40	72	-1	Limp	Good
6	F	L	31	38	69		Normal	Excellent
7	M	L	15	45	60		Normal	Excellent
8	F	L	26	51	77		Normal	Good
9	F	L	20	46	66	-1	Limp	Good
10	F	R	22	38	60		Normal	Excellent
11	M	L	14	48	62		Normal	Excellent
12	F	B/L	36	37	73		Normal	Good
13	M	R	33	42	75		Normal	Excellent
14	F	R	17	48	65		Normal	Excellent
15	M	L	19	39	61		Normal	Excellent
16	F	L	22	42	64		Limp (SubLux.)	Poor
17	F	L	28	56	84		Normal	Fair
18	F	L	19	45	64		Normal	Excellent
19	F	L	26	42	68		Normal	Excellent
20	F	L	31	38	69		Normal	Excellent
21	F	R	35	58	93		Normal	Excellent
22	M	L	18	62	80		Normal	Good
23	F	L	30	46	76		Normal	Excellent
24	F	R	17	39	68		Normal	Excellent
25	M	L	16	54	70		Normal	Excellent
26	F	L	32	47	79		Normal	Excellent
27	F	L	35	49	84		Normal	Excellent
28	M	B/L	18	45	63		Normal	Excellent
29	F	L	28	56	84		Normal	Excellent
30	F	R	29	38	67		Normal	Excellent
31	F	L	36	43	79		Normal	Excellent
32	M	L	33	49	82		Normal	Excellent
33	M	L	19	55	74	-1	Limp	Fair
34	F	L	22	46	68		Normal	Excellent
35	F	L	23	59	82		Normal	Excellent
36	F	L	34	42	78		Normal	Excellent
37	F	L	18	48	66		Normal	Excellent
38	M	R	29	56	85		Normal	Excellent
39	F	L	32	44	76		Normal	Fair
40	F	B/L	21	53	74		Normal	Excellent
41	F	L	19	46	65		Limp	Good
42	M	L	35	39	74		Normal	Excellent
43	F	R	22	36	68		Normal	Excellent
44	M	L	23	42	68	-2	Limp	Excellent
45	F	L	34	26	70		Normal	Good
46	F	L	18	27	65		Normal	Excellent
47	M	L	17	29	66		Normal	Excellent
48	F	R	16	32	68		Normal	Excellent
49	M	L	35	31	66		Limp (Sublux.)	Poor
50	F	L	28	28	66		Normal	Excellent
51	F	B/L	32	35	65		Normal	Good
52	F	L	18	35	69		Normal	Excellent
53	M	L	16	34	60		Normal	Excellent
54	F	R	29	33	69		Normal	Excellent
55	F	R	14	36	68		Normal	Excellent
56	F	L	32	31	63		Normal	Excellent
57	M	L	31	32	63		Normal	Excellent
58	F	L	32	36	68		Normal	Excellent

There were 16 Male (26.2%) and 42 (73.8%) Female; Right Hip in 12, 42 Left Hip in 30, Bilateral hip in 4 with affected Left hip; Age at Operation: 24.9 Months (SD = 7.19817); Duration of Follow-up: 42.5 Months (SD = 8.555785); Age at Follow-up: 70.2 Months (SD = 7.684118). There were 5 Deficient Limb length (1-2 cm); Limp 7; There were Trendelenberg 1; At latest result: Excellent in 44 (75.9%), Good in 8 (13.8%), Fair 4 (6.9%), and Poor 2 (3.4%).

Table 2 Roentgenographic Imagures.

Case	Acetabular Index Angle		Femoral Shaft-Neck Angle		Shortening Osteotomy (cm)	CE[12]	AVN[10]	Shenton line	Severin's class[11]
	Pre.Op	Latest	Pre.Op	Latest					
1	39.5°	20.1°	158.8°	134.6°	1	14.2°		Intact	I
2	40.4°	23.4°	162.5°	128.9°	1	14.3°		Intact	I
3	45.6°	18.2°	159.5°	139.6°	2	15.5°	+	Intact	III
4	36.8°	19.6°	166.8°	135.6°	1	14.8°		Intact	I
5	37.9°	22.4°	171.0°	129.5°	1	15.4°	+	Intact	II
6	48.6°	23.6°	156.4°	132.7°	2	15.4°		Intact	I
7	37.8°	18.9°	163.8°	139.2°	1	17.6°		Intact	I
8	51.4°	20.2°	156.4°	129.6°	1.5	19.1°		Intact	II
9	38.9°	16.3°	170.4°	133.5°	1	15.3°	+	Intact	II
10	41.5°	18.6°	163.4°	136.3°	1.5	14.5°		Intact	I
11	44.8°	17.6°	158.1°	139.1°	1	17.3°		Intact	I
12#	39.6°	21.5°	166.9°	138.6°	2	22.8°	+	Intact	II
13	36.8°	22.6°	163.2°	128.0°	2	18.6°		Intact	I
14	37.5°	21.2°	156.7°	130.9°	1.5	17.1°		Intact	I
15	40.2°	19.4°	158.9°	133.8°	1.5	17.3°		Intact	I
16	53.2°	20.7°	169.5°	140.6°	1.5	0		Broken	VI
17	38.8°	18.4°	165.2°	129.2°	2	21.8°	+	Intact	III
18	43.7°	20.6°	156.3°	132.7°	1	15.6°		Intact	I
19	45.8°	19.8°	158.6°	139.6°	1.5	17.2°		Intact	I
20	36.8°	17.4°	165.9°	129.9°	2	17.4°		Intact	I
21	42.9°	21.5°	157.6°	130.6°	2	22.4°		Intact	I
22	35.7°	16.9°	158.8°	134.5°	1	16.3°	+	Intact	II
23	42.8°	18.2°	161.5°	137.6°	1.5	17.2°		Intact	I
24	36.2°	19.6°	168.4°	141.0°	1	16.8		Intact	I
25	39.6°	21.7°	155.5°	137.1°	1	15.7°		Intact	I
26	40.7°	22.3°	158.6°	137.5°	2	19.5°		Intact	I
27	39.5°	16.9°	163.4°	129.6°	2	21.8°		Intact	I
28#	39.8°	19.8°	170.1°	138.7°	1	15.6°		Intact	I
29	38.1°	18.5°	154.3°	133.5°	1.5	21.7°		Intact	I
30	40.7°	22.6°	163.4°	137.8°	1.5	17.1°		Intact	I
31	38.6°	23.1°	159.8°	140.2°	2	19.3°		Intact	I
32	36.5°	17.3°	163.6°	128.7°	2	18.4°		Intact	I
33	38.4°	18.8°	168.4°	139.5°	1.5	19.4°	+	Intact	II
34	47.2°	21.9°	158.5°	134.8°	1.5	15.4°		Intact	I
35	36.3°	17.6°	154.8°	129.2°	1.5	16.5°		Intact	I
36	38.5°	22.4°	157.6°	130.6°	2	17.6°		Intact	I
37	41.5°	17.4°	165.4°	132.5°	1	15.1°		Intact	I
38	39.8°	19.3°	158.4°	139.3°	1.5	20.5°		Intact	I
39	44.6°	18.6°	167.8°	140.6°	2	16.3°	+	Intact	III
40#	42.9°	22.3°	156.8°	138.6°	1.5	19.1°		Intact	I
41	36.2°	21.5°	156.9°	138.8°	2	16.4°		Intact	I
42	38.8°	16.6°	158.3°	137.3°	1	15.6°	+	Intact	II
43	37.5°	21.2°	154.6°	136.2°	1.5	16.1°		Intact	I
44	36.6°	19.7°	160.6°	138.6°	1.5	16.6°		Intact	I
45	37.9°	18.6°	158.3°	132.5°	2	14.9°		Intact	II
46	38.5°	19.4°	156.9°	134.7°	1.5	15.5°		Intact	I
47	41.2°	18.9°	163.2°	140.2°	1	16.3°		Intact	I
48	38.6°	22.3°	166.8°	139.5°	1.5	17.4°		Intact	I
49	37.9°	20.8°	158.4°	135.3°	1.5	17.7°		Intact	I
50	44.8°	17.5°	155.5°	134.6°	1.5	0		Broken	III
51#	43.6°	19.8°	154.5°	139.6°	2	15.3°		Intact	II
52	35.6°	21.2°	156.6°	129.8°	1.5	17.8°		Intact	I
53	39.5°	18.6°	167.8°	138.4°	1.5	16.6°		Intact	I
54	38.7°	20.1°	158.1°	139.7°	1	17.7°		Intact	I
55	42.8°	19.5°	154.3°	131.5°	1	16.5°		Intact	I
56	36.8°	18.7°	168.3°	136.6°	2	15.6°		Intact	I
57	38.6°	20.9°	158.9°	139.4°	2	14.7°		Intact	I
58	38.3°	18.4°	156.7°	135.7°	1.5	15.8°		Intact	I

Average Acetabular index pre-operative 39.5 (Range, 36.2°-53.2°) (SD = 3.838294); Average Acetabular index at latest Follow-up 19.8° (Range, 16.3°-23.6°) (SD = 1.916975). Average Femoral Shaft - Neck angle pre-Operative 160.9° (range, 154.3°-171°) (SD = 4.880823). Average Femoral Shaft - Neck angle at latest Follow-up 135.4° (range, 128.0°-141.0°) (SD = 1.916975). Average Shortening Osteotomy 1.5 cm (1-2cm) (SD = 0.391750). #The patient had bilateral congenital dislocation, Operated left Hip (Patients in numbers: 12, 28, 40, 51). The Shenton line was intact in 36 hips don't measure CE for 2 cases Subluxation (broken Shenton's line in cas16 & cas 21), and the mean CE angle of Wiberg^[12] was increased to 17.1° (14.2°-22.4°) (SD = 2.122529). There were 9 AVN. In the Severin classification: 44 (75.9%) hips were Class I, 8 (13.8%) hips were class II, 4 (6.9%) hips were class III, 2 (3.4%) hips was Class VI.

temporary mottling of the femoral epiphysis (19%). Gulman *et al.*^[44], who did not use preoperative traction, reported osteonecrosis in 33 of 52 hips (63%) treated with one-stage open reduction and Salter's osteotomy^[45]. Comparison with previous reports indicates that preoperative traction may be useful in reducing the rate of osteonecrosis. Further comparative study is required to prove the effectiveness of pre-operative traction in preventing osteonecrosis.

Clinical evaluation according to modified McKay criteria: Excellent in 44 (75.9%), Good in 8 (13.8%), Fair 4 (6.9%), and Poor 2 (3.4%); Satisfy Results (Excellent and Good) in 52 (97.5%) in this study. Compared Satisfy Results in Operative Femoral Shortening Osteotomy better than without Femoral Shortening osteotomy (77.9%)^[7] differ significantly between the two Surgical procedure (PValue is 0.000341).

CONCLUSION

First, this combined procedure is a technically demanding, but satisfactory procedure in management of DDH patients between 1 and 3 years of age, and when performed in specialized centers, they are expected to give good long-term results. It is clear that the more closely the dysplastic anatomy could be restored to normal, the higher the percentage of favorable long-term results could be anticipated.

Second, femoral shortening must be considered, especially in patients with Shaft neck angle more 150°, may exclude the need for preoperative traction, and Surgical procedure will reduce rate of Redislocation and AVN.

Third, preoperative high dislocation grades, AVN, and arthrosis are the most relevant predictors of poor postoperative outcome. We also found that the degree of femoral head coverage and the growth of the proximal femur are the most significant factors affecting the prognosis.

Finally, divergence between the clinical and radiographic results in DDH related hip surgery exists and must be considered, and the clinical parameters are more valuable and more accurate.

The limitation of this study

The limitation of this study is comprise its retrospective nature and all the patients were not followed to skeletal maturity. The presence of residual hip dysplasia and problems relating to subluxation, trochanteric overgrowth and avascular necrosis if any should be recognized early and treated appropriately to ensure optimum results.

REFERENCES

1. Terjesen T. Residual hip dysplasia as a risk factor for osteoarthritis in 45 years follow-up of late-detected hip dislocation. *J Child Orthop* 2011; **5**: 425-31. [PMID: 23205144]; [DOI: 10.1007/s11832-011-0370-2]
2. Thomas SR, Wedge JH, Salter RB. Outcome at forty-five years after open reduction and innominate osteotomy for late-presenting developmental dislocation of the hip. *J Bone Joint Surg Am* 2007; **89**: 2341-50. [PMID: 17974875]
3. Tezeren G, Tukenmez M, Bulut O, *et al.* The surgical treatment of developmental dislocation of the hip in older children: a comparative study. *Acta Orthop Belg.* 2005; **71**: 678-85 [PMID: 16459857]
4. Kitoh H, Kaneko H, Ishiguro N. Radiographic analysis of movements of the acetabulum and the femoral head after Salter innominate osteotomy. *J Pediatr Orthop* 2009; **29**: 879-84. [PMID: 19934703]; [DOI: 10.1097/BPO.0b013e3181c1e314]
5. Wenger DR, Lee CS, Kolman B. Derotational femoral shortening for developmental dislocation of the hip: special indications and results in the child younger than 2 years. *J Pediatr Orthop* 1995; **15**: 768-779. [PMID: 8543606]
6. Mootha AK, Saini R, Dhillon M, *et al.* Do we need femoral derotation osteotomy in DDH of early walking age group? A clinicoradiological correlation study. *Arch Orthop Trauma Surg* 2010; **130**: 853-858. [PMID: 20012070]; [DOI: 10.1007/s00402-009-1020-8]
7. Hung NN. Revision of Outcomes and Complications Following Open Reduction, and Zigzag Osteotomy Combined with Fibular Allograft for Developmental Dysplasia of the Hip in Children. *Open Journal of Orthopedics* 2016; **6**(7): 184-200 [DOI: 10.4236/ojo.2016.67026]
8. Napoli MMM, Apostólico Netto A, Suguimoto C, Takedo LT. Anteversão dos colos femorais: estudo radiológico. *Rev Imagem* 1985; **7**: 111-116.
9. Ryder CT, Crane L. Measuring femoral anteversion: the problem and a method. *J Bone Joint Surg Am* 1953; **35**: 321-328. [PMID: 13052604]
10. Kalamchi A, MacEwen GD. Avascular necrosis following treatment of congenital dislocation of the hip. *J Bone Joint Surg Am* 1980; **62**: 876-888. [PMID: 7430175]
11. Severin E. Contribution to knowledge of congenital dislocation of hip joint: late results of closed reduction and arthrographic studies of recent cases. *Acta Chir Scand* 1941; **84** Suppl 63: 1-142.
12. Barrett WP, Staheli LT, Chew DE. The effectiveness of the Salter innominate osteotomy in the treatment of congenital dislocation of the hip. *J Bone Joint Surg Am* 1986; **68**: 79-87. [PMID: 3941122]
13. Berkeley ME, Dickson JH, Cain TE, Donovan MM. Surgical therapy for congenital dislocation of the hip in patients who are twelve to thirty-six months old. *J Bone Joint Surg Am* 1984; **66**: 412-420. [PMID: 6699058]
14. Wedge JH, Wasylenko MJ. The natural history of congenital disease of the hip. *J Bone Joint Surg Br.* 1979; **61**: 334-338. [PMID: 158025]
15. Hey-Groves EW. The treatment of congenital dislocation of the hip joint. In: Milford H, ed. The Robert Jones birthday volume. London: Oxford University Press, 1928; 73.
16. Somerville EW, Scott JC. The direct approach to congenital dislocation of the Hip. *J. Bone and Joint Surg* 1957; **39**(4): 623-640. [PMID: 13491626]
17. Sankar WN, Tang EY, Moseley CF. Predictors of the need for femoral shortening osteotomy during open treatment of developmental dislocation of the hip. *J Pediatr Orthop.* 2009; **29**: 868-871. [PMID: 19934701]; [DOI: 10.1097/BPO.0b013e3181c29cb2]
18. Fabry G, MacEwen GD, Shands AR. Torsion of the femur: a follow-up study in normal and abnormal conditions. *J Bone Joint Surg Am* 1973; **55**: 1726-1738. [PMID: 4804993]
19. Watanabe RS. Embryology of the human hip. *Clin Orthop.* 1974; **98**: 8-26.
20. Reikeras O, Bjerkreim I, Kolbenstvedt A. Anteversion of the acetabulum and femoral neck in normals and in patients with osteoarthritis of the hip. *Acta Orthopaedica Belgica* 1983; **54**: 18-23. [PMID: 6829278]
21. Sarban S, Ozturk A, Tabur H, *et al.* Anteversion of the acetabulum and femoral neck in early walking age patients with developmental dysplasia of the hip. *J Pediatr Orthop B* 2005; **14**: 410-414. [PMID: 16200015]
22. Edelson JG, Hirsch M, Weinberg H, *et al.* Congenital dislocation of the hip and Computerised axial tomography. *J Bone Joint Surg* 1984; **66**-B: 472-478. [PMID: 6746676]
23. Sugano N, Noble PC, Kamaric E, *et al.* The morphology of the femur in developmental dysplasia of the hip. *J Bone Joint Surg Br* 1988; **80**: 711-719. [PMID: 9699842]
24. Sankar WN, Young CR, Lin AG, *et al.* Risk factors for failure after open reduction for DDH: a matched cohort analysis. *J Pediatr Orthop* 2011; **31**: 232-9. [PMID: 21415680]; [DOI: 10.1097/

- BPO.0b013e31820c9b31]
25. Chung SMK, Batterman SC, Brighton CT. Shear strength of the human capital epiphyseal plate. *J Bone Joint Surg Am* 1976; **58**: 94-103. [PMID: 1249118]
 26. Suda H, Hattori T, Iwata H. Varus derotation osteotomy for persistent dysplasia in congenital dislocation of the hip. *J Bone Joint Surg Br* 1995; **77**: 756-61. [PMID: 7559705]
 27. Ogden JA, Gossling HR, Southwick WO. Slipped femoral epiphysis following ipsilateral femoral fracture. *Clin Orthop* 1975; **110**: 167-170. [PMID: 1157379]
 28. Lahoti O, Turnbull TJ, Hinves BL. Separation of the proximal femoral epiphysis after derotation varus osteotomy of the femur. *J Pediatr Orthop* 1988; **18**: 662-664. [PMID: 9746421]
 29. Pauwels F. Biomechanics of the locomotor apparatus. Translated by Maquet P and Furlong R. Berlin, etc: Springer-Verlag 1980.
 30. Browne RS. The management of late diagnosed congenital dislocation and subluxation of the hip with special reference to femoral shortening. *J Bone Joint Surg Br.* 1979; **61**: 7-12. [PMID: 422637]
 31. Ombredanne L. *Precis Clinique et Operatoire de Chirurgie Infantile.* Paris: Masson; 1923.
 32. Galpin RD, Roach JW, Wenger DR, *et al.* One-stage treatment of congenital dislocation of the hip in older children, including femoral shortening. *J Bone Joint Surg Am.* 1989; **71**: 734-741. [PMID: 2732262]
 33. Schoenecker PL, Strecker WB. Congenital dislocation of the hip in children. Comparison of the effects of femoral shortening and of skeletal traction in treatment. *J Bone Joint Surg Am.* 1984; **66**: 21-27. [PMID: 6690440]
 34. Klisic P, Jancovic L. Combined procedure of open reduction and shortening of the femur in treatment of congenital dislocation of the hip in older children. *Clin Orthop* 1978; **119**: 60-69. [PMID: 954325]
 35. Kumar S, Jain AK. Open Reduction of Late Unreduced Traumatic Posterior Hip Dislocation in Children. *Acta Orthopaedica Scandinavica* 1999; **70**: 599-602. [PMID: 10665726]
 36. Ashley RK, Larsen LJ, James PM. Reduction of dislocation of the hip in older children: a preliminary report. *J Bone Joint Surg Am* 1972; **54**: 545-550. [PMID: 5055152]
 37. Herold HZ, Daniel D. Reduction of neglected congenital dislocation of the hip in children over the age of six years. *J Bone Joint Surg Br* 1979; **61**: 1-6. [PMID: 422627]
 38. Gabuzda GM, Renshaw TS. Reduction of congenital dislocation of the hip. *J Bone Joint Surg Am* 1992; **74**: 624-31.
 39. Shih CH, Shih HN. One-stage combined operation of congenital dislocation of the in older children. *J Pediatr Orthop* 1988; **8**: 535-539. [PMID: 3170731]
 40. Gage JR, Winter RB. Avascular necrosis of the capital femoral epiphysis as a complication of closed reduction of congenital dislocation of the hip. A critical review of twenty years experience at Gillette Children's Hospital. *J Bone Joint Surg Am.* 1972; **54**: 373-88. [PMID: 4651266]
 41. Weiner DS, Hoyt WA, and O'Dell HW. Congenital Dislocation of the Hip. The Relationship of Premanipulation Traction and Age to Avascular Necrosis of the Femoral Head. *J. Bone and Joint Surg.* 1977, **59-A**: 306-311. [PMID: 849939]
 42. Zions LE, and Macewen GD. Treatment of Congenital Dislocation of the Hip in Children between the Ages of One and Three Years. *J. Bone and Joint Surg.* 1986; **68-A**: 829-846. [PMID: 3733773]
 43. Haidar RK, Jones RS, Vergoesen DA, Evans GA. Simultaneous open reduction and Salter innominate osteotomy for developmental dysplasia of the hip. *J Bone Joint Surg Br* 1996; **78**: 471-6. [PMID: 8636189]
 44. Gulman B, Tuncay IC, Dabak N, Karaismailoglu N. Salter's innominate osteotomy in the treatment of congenital hip dislocation: a long-term review. *J Pediatr Orthop* 1994; **14**: 662-6. [PMID: 7962513]
 45. Salter RB. Innominate osteotomy in the treatment of congenital dislocation and subluxation of the hip. *J Bone Joint Surg [Br]* 1961; **43-B**: 518-39. [PMID: 369757]

Peer reviewer: Perajit Eamsobhana