

Implementation of a Protocol for Treatment of Supracondylar Fractures of Humerus in Children

Oscar Ares, Roberto Seijas, Andrea Sallent, Andrea Domínguez, Mario Aguirre

Oscar Ares, Hospital Clinic Barcelona, Spain; Hospital Teknon Barcelona, Spain

Oscar Ares, Roberto Seijas, Andrea Domínguez, International University of Catalunya, Barcelona, Spain

Roberto Seijas, Orthopedic Surgery, Garcia Cugat Foundation Quiron Hospital Barcelona, Spain

Andrea Sallent, Mario Aguirre, Vall Hebron Hospital Barcelona, Spain

Conflict-of-interest statement: The author(s) declare(s) that there is no conflict of interest regarding the publication of this paper.

Open-Access: This article is an open-access article which was selected by an in-house editor and fully peer-reviewed by external reviewers. It is distributed in accordance with the Creative Commons Attribution Non Commercial (CC BY-NC 4.0) license, which permits others to distribute, remix, adapt, build upon this work non-commercially, and license their derivative works on different terms, provided the original work is properly cited and the use is non-commercial. See: <http://creativecommons.org/licenses/by-nc/4.0/>

Correspondence to: Oscar Ares, MD, PhD, Hospital Clinic Barcelona, C/ Villarroel 170. Stairs 12, Floor 4th, 08036, Barcelona, Spain.

Email: arestraumatologia@gmail.com

Telephone: +34932275533

Fax: +34932249871

Received: February 9, 2017

Revised: April 18, 2017

Accepted: April 21 2017

Published online: June 28, 2017

ABSTRACT

AIM: Supracondylar fractures of the humerus in children are very fearful lesions due to its diagnosis, treatment, associated lesions and the after-effects. Moreover, there are a broad number of treatments. In 2009 we implanted a protocol for the supracondylar fractures treatment.

METHODS: This a retrospective analysis of patients hospitalized with supracondylar fractures of the humerus between March

2009 and March 2011. In the study we analyzed the type of fracture according to Gartland's classification, type of immobilization and reduction and the number and placing of the Kirschner wires. Independent observer analyzed the results. Non-displaced fractures were not included.

RESULTS: A total of 45 patients were attended during that period. The mean age was 6.9 years old, 66% males and 66% with the left arm injured. Type of fracture: type II (14), type III (31). Three cases were treated with non surgical treatment. In 4 cases, closed surgical treatment was not sufficient and open reduction was required. The others thirty eight were treated with closed reduction surgery. The functional results of the patients were 38 excellent/good and 7 regular/bad. Radiological result shows a horizontalization of Baumann's angle related to the crossed pattern of the k-wires ($p = 0.043$). Statistical study shows a relationship between the protocol's follow-up and good results ($p = 0.039$).

CONCLUSION: Following the protocol guarantees an 84.4% less reinterventions and better clinical outcomes ($p = 0.039$). The crossed pattern of the Kirschner wires presents a good stabilization of the fracture but decreases the Baumann's angle ($p = 0.043$), and thus increasing the radiological cubital varus although it has no clinical repercussion ($p > 0.05$).

Key words: Supracondylar fracture of humerus; Supracondylar humerus fracture children; Gartland classification supracondylar; Protocol

© 2017 The Author(s). Published by ACT Publishing Group Ltd. All rights reserved.

Ares O, Seijas R, Sallent A, Domínguez A, Aguirre M. Implementation of a Protocol for Treatment of Supracondylar Fractures of Humerus in Children. *International Journal of Orthopaedics* 2017; **4(3)**: 753-757 Available from: URL: <http://www.ghrnet.org/index.php/ijo/article/view/1985>

INTRODUCTION

The elbow is site of 8 to 12% of fractures in children, having its peak incidence from 5 to 8 years old. Supracondylar fractures of the humerus comprise 75% of childhood fractures of the elbow, and boys sustain twice as many of these injuries as girls^[1].

Supracondylar fractures can be divided into two groups depending if the mechanism of injury is a trauma in extension or in flexion. To reliably predict the final carrying angle after reduction, Baumann's angle should be determined on AP X-rays of the elbow; that is, the angle between the long axis of humeral shaft and the growth plate of the lateral condyle^[2]. The angle between the axis of the humeral diaphysis and the longitudinal axis of the lateral condyle is approximately 64-81°^[3].

It is useful to classify supracondylar humerus fractures according to Gartland's system to decide the appropriate treatment ^[4]: Treatment for Type I fractures (non-displaced) is conservative, involving orthopedic protection. Regarding type II (mildly displaced) and III (completely displaced), several techniques have been used for treating them^[5]. Management of Type III fractures required anatomic reduction prior to bone stabilization. If closed reduction cannot be achieved, open reduction must be performed.

This study analyzes the implementation and results of a protocol (Figure 1) established by the Pediatric Orthopedics Department

(POD) of our hospital and put into practice by an emergency trauma team, which is independent of the POD. The protocol was designed to improve the outcome of treatment for supracondylar humerus fractures with respect to the use of non-standardized treatment for this type of injury.

MATERIALS AND METHODS

We performed a retrospective study analyzing implementation and results of a protocol (Figure 1) established by our hospital's POD. All children between March 2009 and March 2011 with supracondylar humerus fractures and hospitalized were included in the study. Non-displaced Gartland type I fractures (30 cases) were not included. A total of 45 patients comprised the study series, 30 (66.7%) boys and 15 (33.3%) girls, with a mean age of 6.9 years old (SD 2.7). All patients were visited at an approximate follow-up of 2 years after the fracture (mean: 30 months, SD 2).

The supracondylar fracture was located in the left arm in 29 cases

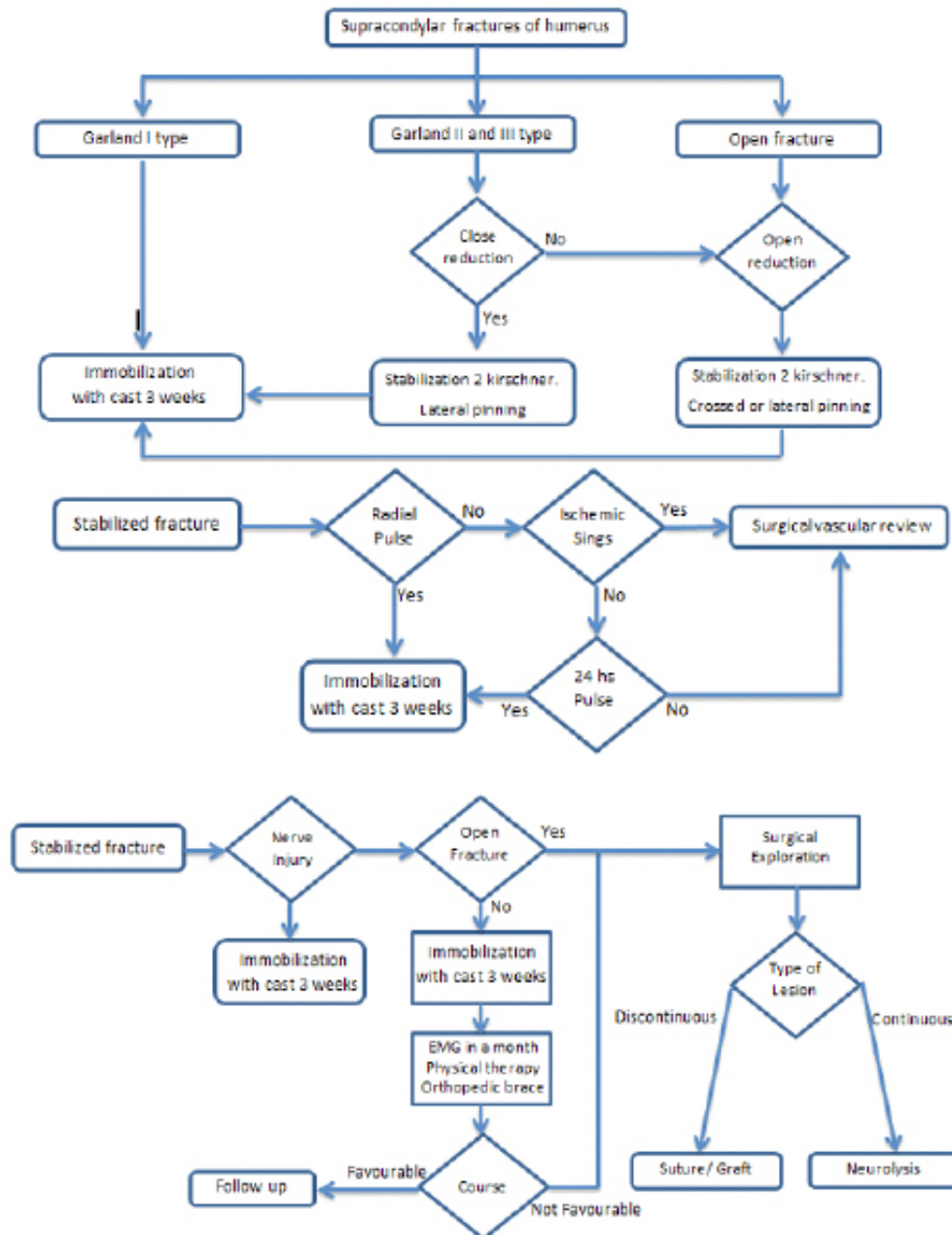


Figure 1 Treatment protocol.

(64.4%) and the right arm in 16 cases (35.6%). The mechanism of lesion was an accidental fall while walking in 38 cases (84.4%) and a fall while practicing sports or cycling in 7 cases (15.6%). Forty-four (97.8%) fractures occurred with the limb in extension and only one in flexion.

According to the Gartland classification, there were 14 Type II fractures (31.1%) and 31 Type III fractures (68.9%). Among the total, 88.6% showed no associated vascular or nerve lesions. There were 2 cases of associated vascular lesions, 2 nerve lesions, and 1 vascular and nerve lesion.

The protocol aims to establish a systematic step within supracondylar fractures of children, according to Gartland's classification. For Gartland type I fractures the first proposed choice is a cast immobilization for 3 weeks. For Gartland types II and III, the first option is closed reduction and lateral stabilization with 2 K-wires. If closed reduction is not possible the next option is open reduction and stabilization with 2 lateral or crossed K-wires, being the first choice in case of open fractures.

Regarding vascular lesion the protocol suggests that distal vascularization should be always revised. Once the fracture is stabilized if radial pulse is not present, ischemic signs must be observed; proceeding to urgent surgical review in case these are present. If ischemic signs do not appear within 24 hours, cast immobilization for 3 weeks is recommended. When radial pulse is present at the first review cast immobilization is the first choice.

Once the fracture is surgically stabilized and the patient has a nerve injury the protocol suggests that a cast immobilization during 3 weeks is the best option. If an open fracture is accompanied of a nerve injury, surgical revision must be performed. With closed fractures and nerve injuries, the first option is a cast immobilization during 3 weeks and proceed with EMG (electromyography) in a month, physical therapy and orthopedic brace and monitoring the clinical course. In case of unfavorable course, surgical review is required, classifying the type of nerve injury. If it is a continuous lesion probably a neurolysis must be done, whereas a discontinuous injury could be treated with graft or suture.

Treatment consisted of conservative orthopedic management in 3(6.6%) patients, closed surgical treatment in 38 (84.4%), and open surgery in 4 (8.9%) patients. One of the 3 patients who had received conservative treatment later required open reduction and fixation. Among the 38 fractures treated with closed reduction, 35 (92.1%) patients underwent percutaneous fixation with 2 Kirschner wires (K-wires) and 3 (7.9%) with 3 K-wires. Among those treated with open surgery, 1 (25%) patient had fixation with 2 K-wires and 3 (75%) with 3 K-wires.

Thus, 43 out of 45 fractures (89.4%) were surgically repaired with K-wire fixation; 37 (86.04%) with 2 pins and 6 (13.96%) with 3 pins. Among the patients undergoing percutaneous treatment, the mean duration of fixation was 26.13 days (SD 5.06). Among the 43 surgically treated fractures, there were 2 K-wire insertion patterns: 74.4% (32) followed a lateral pattern and 25.6% (11) a crossed pattern.

The outcomes were analyzed clinically, radiological and clinical score. Clinically, the joint balance was measured in flexion, extension, pronation, and supination with the Flynn Scale. The radiological outcome was based in the Baumann's angle^[2] and the carrying angle. Functional outcome was measured by the Flynn scale^[6], which has 4 classifications, excellent, good, regular, bad. Because of our small sample size, the results were stratified into good and poor.

As the sample does not follow a Gaussian distribution, we apply nonparametric test. The Fisher test was used for the analysis of the

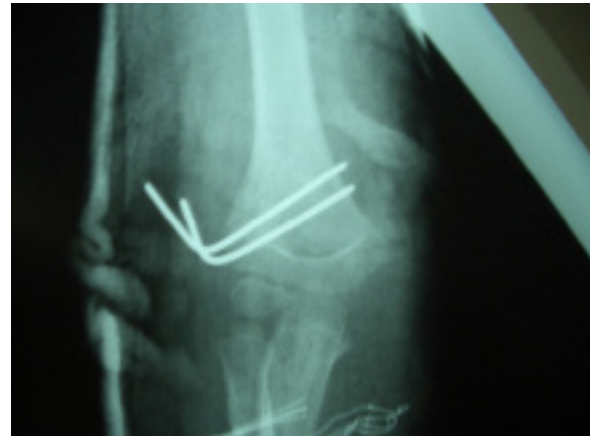

Figure 2 Postoperative AP X-ray. Supracondylar fracture of the humerus (Gartland type II) laterally approached with 2 K-wires.

Table 1 Range of motion. Two years after surgery.

	Flexion	Extension	Pronation	Supination
MEAN	126.05	-7.11	89.74	87.90
SD	10.54	19.82	1.62	12.98

Table 2 Significant differences were observed regarding the analysis of the radiological results according to the pinning position (P=0.043), although no clinical repercussions were observed.

K-Wire Pattern	Mean Baumann Angle	SD
Lateral	76.88	25.37
Crossed	80.86	12.01

Flynn classification because it is a qualitative variable. This test is used in the analysis of contingency tables and when the sample sizes are small. The Mann Whitney U test was used as a non-parametric test for independent samples and quantitative variables.

RESULTS

Forty-five patients were included in the present study. According to the Gartland classification, there were 14 Type II fractures (31.1%) and 31 Type III fractures (68.9%). Regarding vascular or nerve injury there were 2 cases of associated vascular lesions, 2 nerve lesions, and 1 vascular and nerve lesion (summing up 11.4% of the fractures). Eight patients were lost during the analysis. The missing patients did not return after the pins had been removed or answer our telephone calls after 2 years of follow up.

K- wires were left in place for a mean time of 26.13 days (SD 5.06). The two-years results regarding range of motion are shown in table 1.

No significant differences were observed in outcomes (measured with Flynn's classification) regarding the placement of 2 or 3 K-wires (Table 2). The Flynn classification was available in 37 cases: 31 (84.2%) fractures had a good outcome and 6 (15.8%) a bad outcome according to the Flynn criteria. Radiological position of 2 K-wires can be seen in figure 2.

Table 2. Significant differences were observed regarding the analysis of the radiological results according to the pinning position (p = 0.043), although no clinical repercussions were observed.

The Fisher test yielded a non-significant P value of 0.622, indicating that fixation with 2 pins does not result in a poorer outcome than fixation with 3 pins. The protocol was considered to be properly followed when a patient underwent surgical treatment and closed

reduction was performed regardless of pin insertion. The protocol was correctly implemented in 84.4% of cases. Less reinterventions and better clinical outcomes were observed ($p = 0.039$). The remaining 15.6 % could not follow the protocol because in these patients 3 k-wires were used and the protocol only contemplates 2 k-wires. We analyzed whether K-wire positioning was related with functional outcome or joint balance. Using the Fisher exact test ($p = 0.603$) and Mann Whitney U test ($p > 0.05$), we found no significant relationship between K-wire positioning and function.

Analysis of the radiological results according to the pinning pattern used is displaced in table 2, showing that the angle of Baumann was more horizontal with crossed pinning than with lateral pinning ($p = 0.043$), producing cubitus varus ($p = 0.603$) but without functional repercussions ($p > 0.05$).

DISCUSSION

The use of a surgical treatment protocol for displaced supracondylar humerus fractures established by the POD resulted in a high proportion (84.2%) of excellent and good results^[6]. It has been reported that outcomes obtained with 2 K-wires are better than with other techniques using more pins^[7]. We found that there were no statistical differences in the clinical results of using 2 pins or 3, like Abzug reported^[8].

Flynn popularized the technique of fixation with pins and demonstrated the utility of this method^[6]. Current controversy lies in the question of whether to use crossed or lateral pins. Zions^[9] reported that the use of 2 lateral pins results in less rotational stability than one medial and one lateral (crossed pins), and concluded that in displaced fractures the fixation with lateral pins requires less strength than crossed pinning. Ladenhauf reported that that placement of a medial pin carries the risk of iatrogenic ulnar nerve injury, whereas lateral pinning carries an increased risk of median neuropathy. Therefore, it is recommended to avoid medial pinning to prevent ulnar nerve injury and stabilize the fracture with two or three lateral pins. Today, the preferred treatment of displaced supracondylar humerus fractures is immediate closed reduction and percutaneous fixation. In case of instability of the medial column, a medial pin may be used, but possibility of iatrogenic ulnar nerve injury should be considered^[10].

Pretell Mazzini^[11] reported that regarding the functional outcome show a high frequency of excellent results within the lateral and medial approaches and a high frequency of good results within the anterior approach. The most common reason for a failed reduction is the proximal fragment's buttonholing through the brachialis muscle^[12]. There is some evidence that fibrosis in the brachialis muscle is the principal obstruction to the restoration of extension and some authors have demonstrated no correlation between stiffness and the type of surgical approach used, especially regarding the posterior approach^[13]. However, Gruber and Hudson^[14] correlate motion restriction with posterior incisions. In our protocol the preferred approach is lateral pinning due to the reduced risk of nerve injury and better biomechanical outcomes.

In the study of Eren *et al*^[15] a total of 40 patients with type 3 of Gartland fractures were divided equally into lateral or medial approach and authors did not find significant differences between groups in terms of functional or cosmetic results and have reported greater biomechanical stability with cross pinning, although lateral pinning presents a lower associated risk of ulnar nerve injury.

The incidence of cubitus varus deformity in these fractures is 9% to 58%^[16]. The most common cause of cubitus varus is faulty

consolidation of the distal humeral fragment rather than physial closure.

The duration of K-wire fixation was 26.13 days. We propose fixation of the fracture for only 21 days regardless the comminution of the fracture. The time increase is a result of the availability of the operating rooms. Other authors, such as Shen *et al*^[17], report longer mean fixation times.

We use a technique involving fixation with 2 or 3 K-wires^[18] instead of retrograde fixation, as some authors have proposed^[19]. As to the pinning pattern (crossed or lateral), we have found no differences in functional outcome between these options, in line with several authors^[20]. Nonetheless, we mainly use the lateral pattern because it carries a lower risk of injury to the ulnar nerve. Skaggs *et al*^[7] have also recommended lateral pinning. When using the crossed pattern, we perform a mini-open technique, as it is performed by other authors^[21], to avoid ulnar nerve neurological complications. Therefore, we do not use any type of electric instrumentation to localize the ulnar nerve, as has been proposed by Wind *et al*^[22].

Regarding open reduction, there were no poor functional outcomes in our series, but the number of patients undergoing this surgery may have been too small to detect statistically significant differences. The type of approach was not analyzed in our patients; therefore, we cannot compare this data with the results of other series, in which a medial^[23], lateral, or anterior^[24] approach is recommended. Nor did we include in the analysis the time that passed between the accident and the surgical intervention in the patients undergoing surgery.

The radiographic findings in open reduction showed horizontalization of Baumann's angle, a circumstance that might generate problems regarding cubitus varus, although this would not necessarily have clinical implications. Oh *et al*^[25] found a similar correlation between open reduction and horizontalization of Baumann's angle. The worse outcomes observed were within the patients with open reduction as their fractures could not be adequately resolved with closed reduction; which could explain the poorer outcomes.

Treatment for these fractures is mainly based on closed reduction and percutaneous K-wire fixation; in our study, only 8% required treatment with open reduction. Following with our series, greater displacement and older age were associated with a higher probability of requiring open reduction.

CONCLUSION

In summary, fixation of supracondylar humerus fractures with only 2 K-wires is not associated with poorer results; hence, we recommend fixation with 2 pins providing that the fracture is well stabilized. Neither of the 2 pinning patterns (lateral or crossed) provides better outcome. Thus we recommend the lateral pattern, which has a lower associated risk of ulnar nerve injury. Crossed pinning is related to a higher incidence of horizontalization of Baumann's angle, which may result in a greater incidence of cubitus varus, although this is unlikely to have functional repercussions. In 85% of cases in our series the functional results were good. We found no significant relationship between the final functional outcome and age, side of the fracture, sex, type of trauma causing the injury, type of fracture, and degree of displacement, additional vascular or nerve injury, or treatment used.

Use of the treatment protocol established by our hospital has yielded good functional results.

LIMITATIONS

First, ours is a single-center non-randomized and retrospective study.

Because of our small sample size, the results were stratified into *good* and *poor* it could be a bias, this stratification is not very discriminative or accurate.

Regarding open reduction, there were no poor functional outcomes in our series, but the number of patients undergoing this surgery may have been too small to detect statistically significant differences. The radiographic findings in open reduction showed horizontalization of Baumann's angle, a circumstance that might generate problems regarding cubitus varus, although the patients in the present study did not present clinical implications.

Another limitation is the lack of a radiological comparison of contralateral Baumann's angle.

CONFLICT OF INTERESTS

Each author certifies that he or she has no commercial associations (eg, consultancies, stock ownership, equity interest, patent/licensing arrangements, etc) that might pose a conflict of interest in connection with the submitted article.

REFERENCES

- Wilkins KE. The operative management of supracondylar fractures. *Orthop Clin North Am* 1990; **21**: 269-89.
- Williamson DM, Coates CJ, Miller RK, Cole WG. Normal characteristics of the Baumann (humerocapitellar) angle: an aid in assessment of supracondylar fractures. *J Pediatr Orthop* **12**: 636-9.
- D'Arienzo M, Innocenti M, Pennisi M. [The treatment of supracondylar fractures of the humerus in childhood (cases and results)]. *Arch Putti Chir Organi Mov* 1983; **33**: 261-9.
- GARTLAND JJ. Management of supracondylar fractures of the humerus in children. *Surg Gynecol Obstet* 1959; **109**: 145-54..
- Topping RE, Blanco JS, Davis TJ Clinical evaluation of crossed-pin versus lateral-pin fixation in displaced supracondylar humerus fractures. *J Pediatr Orthop* **15**: 435-9.
- Flynn JC, Matthews JG, Benoit RL. Blind pinning of displaced supracondylar fractures of the humerus in children. Sixteen years' experience with long-term follow-up. *J Bone Joint Surg Am* 1974; **56**: 263-72.
- Skaggs DL, Cluck MW, Mostofi A, *et al.* Lateral-entry pin fixation in the management of supracondylar fractures in children. *J Bone Joint Surg Am* 2004; **86-A**: 702-7.
- Abzug JM, Herman MJ. Management of supracondylar humerus fractures in children: current concepts. *J Am Acad Orthop Surg* 2012; **20**: 69-77. [DOI: 10.5435/JAAOS-20-02-069]
- Zionts LE, McKellop HA, Hathaway R. Torsional strength of pin configurations used to fix supracondylar fractures of the humerus in children. *J Bone Joint Surg Am* 1994; **76**: 253-6.
- Ladenhauf HN, Schaffert M, Bauer J. The displaced supracondylar humerus fracture: indications for surgery and surgical options: a 2014 update. *Curr Opin Pediatr* 2014; **26**: 64-9. [DOI: 10.1097/MOP.0000000000000044]
- Pretell Mazzini J, Rodriguez Martin J, Andres Esteban EM. Surgical approaches for open reduction and pinning in severely displaced supracondylar humerus fractures in children: a systematic review. *J Child Orthop* 2010; **4**: 143-52. [DOI: 10.1007/s11832-010-0242-1]
- Rasool MN, Naidoo KS Supracondylar fractures: posterolateral type with brachialis muscle penetration and neurovascular injury. *J Pediatr Orthop* **19**: 518-22.
- Kumar R, Kiran EK, Malhotra R, Bhan S. Surgical management of the severely displaced supracondylar fracture of the humerus in children. *Injury* 2002; **33**: 517-22. [DOI: 10.1016/s0020-1383(02)00031-1]
- Gruber MA, Hudson OC. SUpracondylar fracture of the humerus in childhood. end-result study of open reduction. *J Bone Joint Surg Am* 1964; **46**: 1245-52.
- Eren A, Ozkut AT, Altıntaş F, Güven M. [Comparison between the lateral and medial approaches in terms of functional and cosmetic results in the surgical treatment of type III supracondylar humeral fractures in children]. *Acta Orthop Traumatol Turc* 2005; **39**: 199-204. doi: 10.1097/01.bpb.0000060288.16932.08
- Skaggs DL, Flynn JM, Beaty JH, Rockwood CA, James R KM. Supracondylar fractures of the distal humerus. Fractures in Children. Wolters Kluwer/Lippincott, Williams & Wilkins 2010
- Shen J, Jin J, Yang X, Qiu G. Closed reduction and percutaneous K-wires fixation of displaced supracondylar humerus fractures in children. *Chin Med Sci J* 2000; **15**: 179-82.
- Gajdobranski D, Marić D, Tatić M, *et al.* [Osteosynthesis with Kirschner wires in the treatment of dislocated supracondylar humeral fractures in children]. *Med Pregl* **56**: 355-61.[DOI: 10.2298/mpns0308355g]
- Weinberg A-M, von Bismarck S, Castellani C, Mayr J. [Descending intramedullary nailing for the treatment of displaced supracondylar humeral fractures in children]. *Chirurg* 2013; **74**: 432-6. [DOI: 10.1007/s00104-002-0595-1]
- Yousri T, Tarassoli P, Whitehouse M, *et al.* Systematic review of randomized controlled trials comparing efficacy of crossed versus lateral K-wire fixation in extension type Gartland type III supracondylar fractures of the humerus in children. *Ortop Traumatol Rehabil* **14**: 397-405. [DOI: 10.5604/15093492.1005083]
- Gosens T, Bongers KJ. Neurovascular complications and functional outcome in displaced supracondylar fractures of the humerus in children. *Injury* 2033; **34**: 267-73. [DOI: 10.1016/s0020-1383(02)00312-1]
- Wind WM, Schwend RM, Armstrong DG Predicting ulnar nerve location in pinning of supracondylar humerus fractures. *J Pediatr Orthop* **22**: 444-7.[DOI: 10.1097/01241398-200207000-00006]
- Kumar R, Malhotra R. Medial approach for operative treatment of the widely displaced supracondylar fractures of the humerus in children. *J Orthop Surg (Hong Kong)* 2000; **8**: 13-18.
- Koudstaal MJ, De Ridder VA, De Lange S, Ulrich C. Pediatric supracondylar humerus fractures: the anterior approach. *J Orthop Trauma* 2002; **16**: 409-12. [DOI: 10.1097/00005131-200207000-00007]
- Oh C-W, Park B-C, Kim P-T, *et al.* Completely displaced supracondylar humerus fractures in children: results of open reduction versus closed reduction. *J Orthop Sci* 2003; **8**: 137-41. [DOI: 10.1007/s007760300023]

Peer reviewer: Yogesh Salphale; Kapil Bakshi