

## Clinical Outcomes of the Phn Intramedullary Nail for Proximal Humeral Fractures

Oscar Ares, Andrea Sallent, Roberto Seijas, Ariadna Caparrós

Oscar Ares, Ariadna Caparrós, Hospital Clinic Barcelona, Spain  
Oscar Ares, Oscar Ares, International University of Catalunya, Barcelona, Spain  
Andrea Sallent, Vall Hebron Hospital Barcelone, Spain  
Roberto Seijas, Orthopedic Surgery, Garcia Cugat Foundation Quiron Hospital Barcelone, Spain  
Oscar Ares, Hospital Teknon, Barcelone, Spain

**Conflict-of-interest statement:** The author(s) declare(s) that there is no conflict of interest regarding the publication of this paper.

**Open-Access:** This article is an open-access article which was selected by an in-house editor and fully peer-reviewed by external reviewers. It is distributed in accordance with the Creative Commons Attribution Non Commercial (CC BY-NC 4.0) license, which permits others to distribute, remix, adapt, build upon this work non-commercially, and license their derivative works on different terms, provided the original work is properly cited and the use is non-commercial. See: <http://creativecommons.org/licenses/by-nc/4.0/>

**Correspondence to:** Oscar Ares MD, PhD, Hospital Clinic Barcelona, C/ Villarroel 170. Stairs 12, Floor 4th, 08036, Barcelona, Spain.  
Email: [arestraumatologia@gmail.com](mailto:arestraumatologia@gmail.com)  
Telephone: +34932275533  
Fax: +34932249871

Received: February 9, 2017  
Revised: May 7, 2017  
Accepted: May 9 2017  
Published online: June 28, 2017

### ABSTRACT

**AIM:** Our aim was to analyze the functional outcomes of our initial experience in the treatment of proximal humeral fractures. The present technique lies in the implantation of an intramedullary nail with a spiral blade and guided interlocking distal bolts.

**METHODS:** The series consisted of 5 patients (mean age 43.2 years old). Proximal humeral fractures included AO/ASIF type 11-B2 (3

cases) and type 11-A3 (2 cases). Follow-up was 15.7 months, observing absolute bone healing in all cases.

**RESULTS:** Mean range of motion was 120° (SD 12). The mean central score on the Constant scale was 85.60 points (69-100) on the affected side, compared to the 97.60 points (100-88) obtained in the healthy side. The age- and sex-adjusted Constant score was 86.70 (SD 13). The physical component of the SF-12 indicated a moderate impact on health-related quality of life.

**CONCLUSION:** Based on the favorable clinical and radiological outcome, the PHN nail appears to be an effective implant for attaining stability in displaced fractures, and this should be included as a possible form of treatment within the range of possible surgical repairs.

**Key words:** PHN intramedullary nail; Proximal humeral fractures; Outcomes; Constant score

© 2017 The Author(s). Published by ACT Publishing Group Ltd. All rights reserved.

Ares O, Sallent A, Seijas R, Caparrós A. Clinical Outcomes of the Phn Intramedullary Nail for Proximal Humeral Fractures. *International Journal of Orthopaedics* 2017; **4(3)**: 763-766 Available from: URL: <http://www.ghrnet.org/index.php/ijo/article/view/1987>

### INTRODUCTION

Proximal humerus fractures, mainly occurring at the surgical neck level, are more common in elderly people whose grade of osteoporosis makes internal synthesis more challenging, being a fall from standing in an elderly osteoporotic woman the most common mechanism of fracture<sup>[1,2]</sup>. However, the incidence of these fractures is currently increasing in active, young people being a high-energy traumatism the most common cause within this group<sup>[3,4,5]</sup>.

Osteosynthesis of proximal humeral fractures is a source of controversy due to the numerous available treatment options: plates, screws, Kirchner wires, intramedullary nails, percutaneous nailing and external fixation<sup>[6,7,8]</sup>. Regarding plates and nails, the need to open the affected area and the likely poor bone quality in older patients can make fixation challenging<sup>[9,10]</sup>. The complications associated to

anterograde nails are rotator cuff injury and subacromial syndrome due to proximal migration<sup>[11,12]</sup>, whereas a perforation of the humeral head<sup>[13]</sup> and supracondylar humeral fracture can occur during retrograde nail placement. Percutaneous fixation with wires can be affected by the musculature of the shoulder, and it is a less stable, technically more difficult osteosynthesis.

Our aim is to describe the clinical and functional outcomes (measured with Constant scale<sup>[14]</sup>, SF-12<sup>[15]</sup> and DASH questionnaire<sup>[16]</sup>) of our initial experience in the treatment of proximal humeral fractures using an intramedullary nail with a spiral blade and guided interlocking distal bolts.

## MATERIALS AND METHODS

Five fractures (3 men; 2 women) with a follow-up of 1 year are described. Mean age was 43.2 years old (SD 20.5). The lesion was caused by a high-energy mechanism in 2/5 of cases. Three patients had AO-ASIF type 11-B2 fractures, while the remaining two presenting AO-ASIF type 11-A3. AP and lateral X-rays were used in all cases to diagnose and classify the fracture (Figure 1). Each patient was informed that data concerning the case would be submitted for publication, and signed an informed consent according to it. The

hospital's Ethical Committee approved the present study and this was performed according to the ethical standard laid down in the 1964 Declaration of Helsinki, as revised in 2008.

Proximal humeral nails (PHN) were used in all cases, with a diameter-size of 7 mm and a proximal spiral blade and bolt, as well as two distal interlocking bolts inserted with a single guiding device (Synthes®, Switzerland) (Figure 2). With this system, an oblique bolt can be inserted in a distal-to-proximal direction to increase the stability of the synthesis, if required. All patients underwent immobilization with a sling for two weeks and started physical therapy following this period of time.

Patients were assessed with DASH, SF-12, and Constant tests during the last follow-up (Table 1). On the DASH scale, the lower the score the better the outcome, in contrast to SF-12 and Constant.

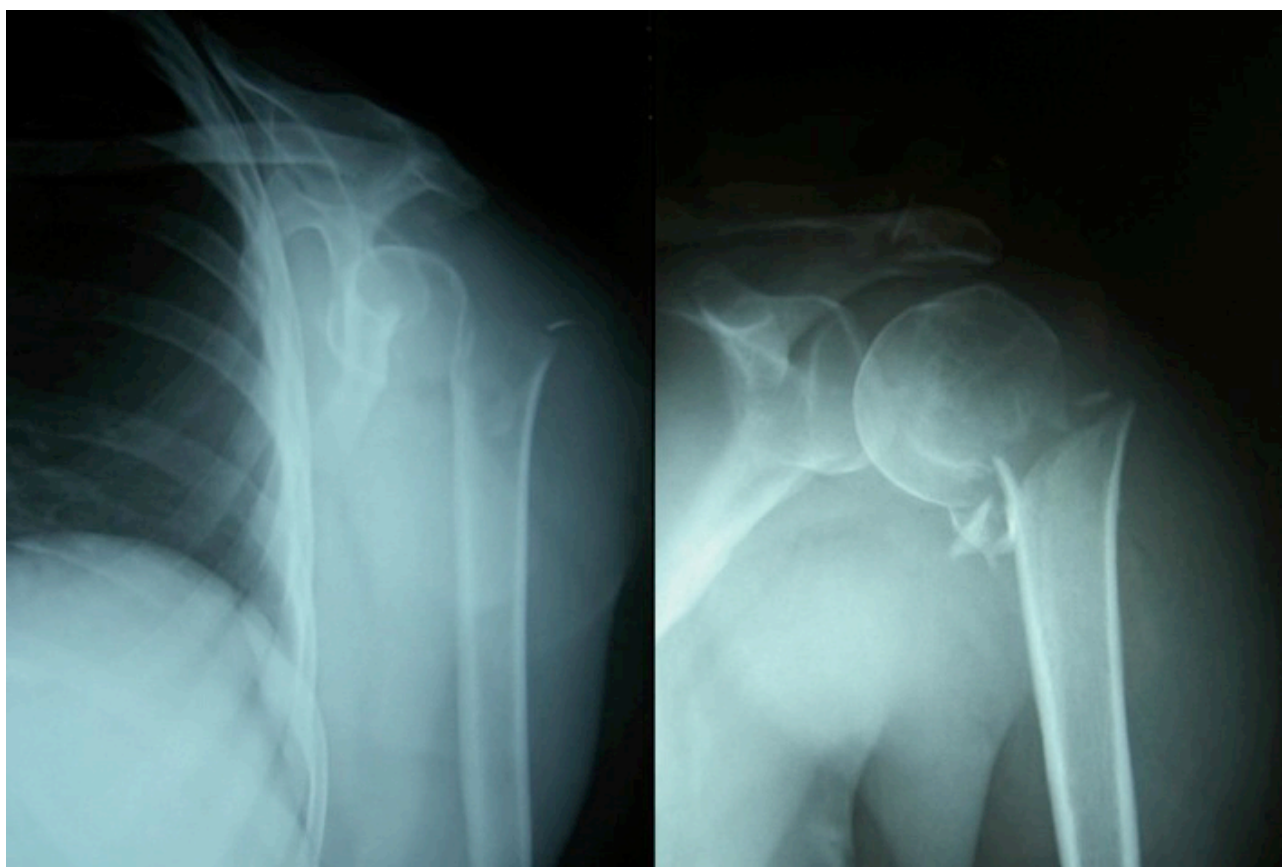
Effect size, a standardized difference of means, was calculated to assess the magnitude of the difference in health-related quality of life (HRQoL) scores.

## RESULTS

Consolidation of the fracture without secondary displacement was achieved in all cases.

**Table 1** Clinical results, measured with three different questionnaires (DASH, SF-12, Constant).

	Follow-up (months)	Side Fx	Dominant side	DASH	SF-12		Constant Affected	Constant Healthy	Constant difference	Constant adjusted (%)
					Physical	Mental				
Case 1	18	Right	Right	47.50	35.67	44.87	70	88	18	79.5
Case 2	15	Left	Right	29.17	38.27	42.22	98	100	2	98
Case 3	14	Left	Right	0	56.68	57.44	100	100	0	100
Case 4	18	Right	Right	35.83	36.80	56.03	69	100	31	69
Case 5	17	Left	Right	17.50	45.05	50.63	91	100	9	91



**Figure 1** AP X-rays in neutral position, fracture of the anatomical neck of the humerus (right image; enlarged).

Mean range of motion was 0-120° (SD 12). Mean score on the Constant scale was 85.60 points on the affected side (SD 15.076) and 97.60 points on the healthy side (SD 5.37). Patients presented an average decrease of 12 points (SD 12.75) on the injured side in comparison to the contralateral. The mean weighted score (affected/healthy) for the ability to perform movements with respect to the healthy shoulder was 87.5% (SD 13.08). Patient 4 showed 69 points on the Constant scale due to a subacromial syndrome developed by slight protrusion of the nail. Withdrawal of the implant was proposed to improve the symptoms, but the patient refused this procedure.

Mean score on the DASH scale was 26.00 points (SD 18.15). Mean scores on the SF-12 scale were 42.49 (SD 8.7) for the physical component and 50.24 (SD 6.68) for the mental component. There were no statistically significant differences ( $p > 0.05$ ) with respect to the age- and sex-adjusted values.

The effect size was obtained as the difference between the means of the group, divided by the standard deviation of the group. Generally accepted guidelines define an effect size around 0.2 as “low”, 0.5 as “moderate” and  $\geq 0.8$  as “large”<sup>[17]</sup>. Effect size in the present series showed a moderate worsening for the physical component (0.75) and a small change within the psychological aspect.

## DISCUSSION

The major findings of this study were that the radiological and clinical results of our initial experience with the PHN were satisfactory in 100% of our cases. Radiological examination showed correct consolidation in all patients and tests assessing clinical outcomes were highly favorable.

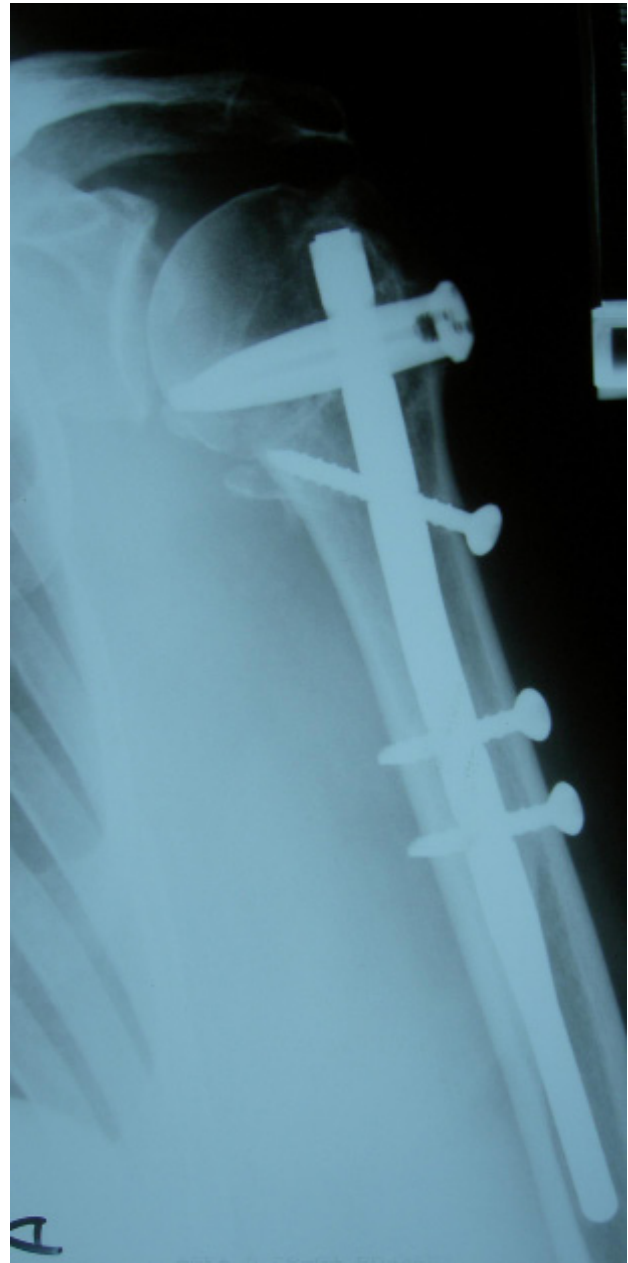Several studies have shown that confer greater biomechanical stability on the implant rather than simple fixation with screws<sup>[18,22]</sup>. Hessmann *et al.* studied the biomechanical properties of four different implants, concluding that both the intramedullary nail and internal fixator were stronger than the plates<sup>[18,19]</sup>. Furthermore, the system of insertion of a single spiral blade, instead of several screws as in other implants, decreases the risk of neurological lesion<sup>[18,20,21]</sup>. The highly demanding, young patients in our series achieved complete functional recovery with excellent results. PHN, in contrast to plates and screws, allows a less aggressive approach without the need of opening the focus of fracture or increasing the vascular lesion to the humeral head<sup>[23,24]</sup>.

In patients treated with the 7-mm PHN, no cases of implant breakage during the procedure or follow-up were observed, in line with the outcomes of other studies<sup>[25,26]</sup>. Moreover, there were no cases of pseudoarthrosis, necrosis of the head or delays in consolidation. The fact that the distal interlocking bolts to block rotation are implanted with the use of a guiding system makes the surgical procedure faster and more highly reproducible. There were no cases of distal blocking failure.

The mean score obtained with the Constant scale<sup>[14]</sup> compares favorably with the reported scores ranging from 63.0 to 87<sup>[18,23,25]</sup>. The SF-12 scale did not show relevant differences from general population's data. Nonetheless, analysis of the impact on HRQoL showed a moderate effect on the physical component, with no effect on the psychological component.

Several limitations should be considered when reviewing the present study. The number of patients included is relatively small, and thus, further randomized studies should be performed to draw clearer conclusions.

This study supports the use of intramedullary nails for selected fractures of the proximal humerus in both young and older patients with osteoporosis. The PHN with spiral blade and guided



**Figure 2** Postoperative X-ray showing the nail with the spiral blade and the three screws.

interlocking distal bolts provides good stability in osteoporotic bones. This technique has less aggressiveness and is particularly useful in fractures at the surgical neck. Despite the fact that it is necessary to invade the rotator cuff, the clinical differences observed between the affected and the healthy sides with the Constant scale were over 80%.

Although the outcomes of PHN (Synthes®) require further assessment, the results obtained in this initial experience were very favorable and promising.

## REFERENCES

1. Robinson CM, Seah M, Akstar MA. The epidemiology, risk of recurrence, and functional outcome after an acute traumatic posterior dislocation of the shoulder. *J Bone Joint Surg Am* 2011; **93(17)**: 1605-13. [DOI: 10.2106/JBJS.J.00973]
2. Barvencik F, Gebauer M, Beil FT, Vettorazzi E, Mumme M, Rupprecht M, Pogoda P, Wegscheider K, Rueger JM, Pueschel K, Amling M. Age- and sex-related changes of humeral head

- microarchitecture: histomorphometric analysis of 60 human specimens. *J Orthop Res* 2010; **28**(1): 18-26. [DOI: 10.1002/jor.20957]
3. Rajasekhar C, Ray PS, Bhamra MS. Fixation of proximal humeral fractures with the Polarus nail. *J Shoulder Elbow Surg* 2001; **10**: 7-10. [DOI: 10.1067/mse.2001.109556]
  4. El-Sayed MMH. Surgical management of complex humerus head fractures. *Orthop Rev (Pavia)* 2010; **2**(2): e14. [DOI: 10.4081/or.2010.e14]
  5. Gottschalk HP, Browne RH, Starr AJ. Shoulder girdle: patterns of trauma and associated injuries. *J Orthop Trauma* 2011; **25**(5): 266-71. [DOI: 10.1097/BOT.0b013e3181e47975]
  6. Osman N, Touam C, Masmajejan E, Asfazadourian H, Alnot JY. Results of non-operative and operative treatment of humeral shaft fractures. A series of 104 cases. *Chir Main* 1998; **17**: 195-206. [PMID: 10855286]
  7. Guy P, Slobogean GP, McCormack RG. Treatment preferences for displaced three- and four-part proximal humerus fractures. *J Orthop Trauma* 2010; **24**(4): 250-4. [DOI: 10.1097/BOT.0b013e3181bdc46a]
  8. Min W, Davidovitch RI, Tejwani NC. Three-and four-part proximal humerus fractures: evolution to operative care. *Bull NYU Hosp Jt Dis.* 2012; **70**: 25-34. [PMID: 22894692]
  9. Stromsoe K. Fracture fixation problems in osteoporosis. *Injury* 2004; **35**: 107-113. [PMID: 14736465]
  10. Mantila Roosa SM, Hurd AL, Xu H, Fuchs RK, Warden SJ. Age-related changes in proximal humerus bone health in healthy, white males. *Osteoporos Int* 2012; **23**(12): 2775-83. [DOI: 10.1007/s00198-012-1893-1]
  11. Grandl G, Dietze A, Arndt A, Beck M, Gierer P, Borsch T, Mittlmeier T. Angular and sliding stable anterograde nailing (Targon PH) for the treatment of proximal humeral fractures. *Arch Orthop Trauma Surg* 2007; **127**(10): 937-44 [DOI: 10.1007/s00402-007-0425-5]
  12. Giannoudis PV, Xypnitos FN, Dimitriou R, Manidakis N, Hackney R. "Internal fixation of proximal humeral fractures using the Polarus intramedullary nail: our institutional experience and review of the literature". *J Orthop Surg Res Dec* 2012; **19**(7): 39. [DOI: 10.1186/1749-799X-7-39]
  13. Wachtl SW, Marti CB, Hoogewoud HM, Jakob RP, Gautier E. Treatment of proximal humerus fracture using multiple intramedullary flexible nails. *Arch Orthop Trauma Surg* 2000; **120**(3-4): 171-5. [PMID: 10738877]
  14. Constant CR, Murley AH. A clinical method of functional assessment of the shoulder. *Clin Orthop Relat Res* 1987; **(214)**: 160-164. [PMID: 3791738]
  15. Ware J Jr, Kosinski M, Keller SD. A 12-Item Short-Form Health Survey: construction of scales and preliminary tests of reliability and validity. *Med Care* 1996; **34**: 220-233. [PMID: 8628042]
  16. Rosales RS, Delgado EB, Diez de la Lastra-Bosch. Evaluation of the Spanish version of the DASH and carpal tunnel syndrome health-related quality-of-life instruments: cross-cultural adaptation process and reliability. *J Hand Surg Am* 2002; **27**: 334-343. [PMID: 11901395]
  17. Kazis LE, Anderson JJ, Meenan RF. Effect sizes for interpreting changes in health status. *Med Care* 1989; **27**: S178-S189. [PMID: 2646488]
  18. Hessmann MH, Hansen WS, Krummenauer F, Pol TF, Rommens P. Locked plate fixation and intramedullary nailing for proximal humerus fractures: a biomechanical evaluation. *J Trauma* 2005; **58**: 1194-1201. [PMID: 15995470]
  19. Boudard G, Pomares G, Milin L, Lemonnier I, Coudane H, Mainard D, Delagoutte JP. Locking plate fixation versus antegrade nailing of 3- and 4-part proximal humerus fractures in patients without osteoporosis. Comparative retrospective study of 63 cases. *Orthop Traumatol Surg Res* 2014; **100**(8): 917-24. [DOI: 10.1016/j.otsr.2014.09.021]
  20. Liu KY, Chen TH, Shyu JF, Wang ST, Liu JY, Chou PH. Anatomic study of the axillary nerve in a Chinese cadaveric population: correlation of the course of the nerve with proximal humeral fixation with intramedullary nail or external skeletal fixation. *Arch Orthop Trauma Surg.* 2011; **131**(5): 669-74. [DOI: 10.1007/s00402-010-1184]
  21. Spiegelberg BG, Riley ND, Taylor GJ. Risk of injury to the axillary nerve during antegrade proximal humeral blade nail fixation - an anatomical study. *Injury* 2014; **45**(8): 1185-9. [DOI: 10.1016/j.injury.2014.05.006]
  22. Foruria AM, Carrascal MT, Revilla C, Munuera L, Sánchez-Sotelo J. Proximal humerus fracture rotational stability after fixation using a locking plate or a fixed-angle locked nail: the role of implant stiffness. *Clin Biochem (Bristol, Avon)* 2010; **25**(4): 307-11. [DOI: 10.1016/j.clinbiomech.2010.01.009]
  23. Brooks CH, Revell WJ, Heatley FW. Vascularity of the humeral head after proximal humeral fractures. An anatomical cadaver study. *J Bone Joint Surg Br* 1993; **75**: 132-136. [PMID: 8421010]
  24. Gardner MJ, Voos JE, Wanich T, Helfet DL, Lorich DG. Vascular implications of minimally invasive plating of proximal humerus fractures. *J Orthop Trauma* 2006; **20**(9): 602-7. [DOI: 10.1097/01.bot.0000246412.10176.14]
  25. Lin J. Effectiveness of locked nailing for displaced three-part proximal humeral fractures. *J Trauma* 2006; **61**: 363-374. [DOI: 10.1097/01.ta.0000224148.73016.30]
  26. Kloub M, Holub K, Polakova S. Nailing of three- and four-part fractures of the humeral head -- long-term results. *Injury.* 2014; **45** **Suppl 1**: S29-37. [DOI: 10.1016/j.injury.2013.10.038]

**Peer reviewers:** Anestis Iossifidis; Adrianus den Hertog; Ashish Babhulkar