

Tennis Elbow Pathogenesis

Gemma Vicens, Roberto Seijas, Andrea Sallent, Andrea Dominguez, Oscar Ares, Andrea Torrecilla

Gemma Vicens, Andrea Torrecilla, Medical student Universitat Internacional de Catalunya, Spain

Roberto Seijas, Orthopedic Surgery, Garcia Cugat Foundation Quiron Hospital Barcelone, Spain

Roberto Seijas, Oscar Ares, Basic Sciences Department, International University of Catalunya, Spain

Andrea Sallent, Vall Hebron Hospital Barcelone, Spain

Andrea Dominguez, Medical Student, Autonomia University of Barcelone, Spain; International University of Catalunya, Barcelona, Spain

Oscar Ares, Hospital Clinic Barcelone, Spain; Hospital Teknon Barcelone, Spain

Conflict-of-interest statement: The author(s) declare(s) that there is no conflict of interest regarding the publication of this paper.

Open-Access: This article is an open-access article which was selected by an in-house editor and fully peer-reviewed by external reviewers. It is distributed in accordance with the Creative Commons Attribution Non Commercial (CC BY-NC 4.0) license, which permits others to distribute, remix, adapt, build upon this work non-commercially, and license their derivative works on different terms, provided the original work is properly cited and the use is non-commercial. See: <http://creativecommons.org/licenses/by-nc/4.0/>

Correspondence to: Oscar Ares, MD, PhD, Hospital Clinic Barcelona, C/ Villarroel 170. Stairs 12, Floor 4th, 08036, Barcelona, Spain.

Email: arestraumatologia@gmail.com

Telephone: +34932275533

Fax: +34932249871

Received: February 9, 2017

Revised: April 18, 2017

Accepted: April 21 2017

Published online: June 28, 2017

ABSTRACT

AIM: Lateral epicondylitis, also known as tennis elbow, is a common pathology that usually affects tennis players and athletes involved in overhead throwing, especially athletes between 30 and 50 years old.

It is a painful condition that starts with swelling of the tendons that attach to the lateral epicondyle of the humerus and continues as a tendinosis. This pathology is related to a repetitive contraction of the extensor carpi radialis and it could also be associated with the conditions of the tennis racquet, an improper technique while playing tennis or with the frequency of play. The aim of this review is to analyze the different causes of suffering lateral epicondylitis in tennis players and its pathogenesis.

METHODS: A bibliographic research has been performed with Medline database. In order to obtain as much as relevant literature possible, the key words used were: tennis elbow AND pathogenesis. Only manuscripts that had been published in the last five years and only English-written studies were selected, as well as studies that really mentioned pathogenesis of lateral epicondylitis in adult tennis players.

RESULTS: 434 results were obtained reducing to 81 manuscripts in the last five years. Following the selection criteria, four systematic reviews were obtained referring to tennis elbow in athletes and pathogenesis. These studies mentioned the possible causes of lateral epicondylitis, especially in tennis players due to their constantly exercise over the extensor muscles that have their origin in the humeral epicondyle in order to keep going with the tennis practice.

CONCLUSIONS: A repetitive contraction of the extensor carpi radialis seems to cause lateral epicondylitis in tennis players. But, in fact, there are some aspects that differ: the conditions of the racquet could be a cause of this pathology, as well as an incorrect technique while playing tennis and the frequency of play.

Key words: Tennis elbow; Lateral epicondylitis; Tennis; Pathogenesis

© 2017 The Author(s). Published by ACT Publishing Group Ltd. All rights reserved.

Vicens G, Seijas R, Sallent A, Dominguez A, Ares O, Torrecilla A. Tennis Elbow Pathogenesis. *International Journal of Orthopaedics* 2017; 4(3): 767-769 Available from: URL: <http://www.ghrnet.org/index.php/ijo/article/view/1988>

INTRODUCTION

Lateral epicondylitis (or tennis elbow) was previously considered to

be a tendinitis^[1,2]. However, it has also been described as a chronic symptomatic degeneration of the tendons of the extensor muscles of the forearm attached to the lateral epicondyle of the humerus, also known as a tendinosis^[3]. It is described to start with a pretendinous inflammation, and thus referred as a tendinitis, and it continues with the presence of angiofibroblastic hyperplasia, which is the concentration of fibroblasts, vascular hyperplasia and disorganized collagen^[3-5]. When the rate of stretching the wrist extensor muscles overpasses the resistance of the tendon, a micro-tear appears, and the accumulation of these micro-tears finally causes the tendinosis^[3].

It is a painful condition that affects the origin of the extensor carpi radialis brevis (ECRB) as well as possibly affecting the wrist extensors muscles that have their origin in the lateral epicondyle of the humerus. It can lead to the loss of function of the affected limb, being a self-limiting pathology^[4].

Tennis elbow is common in racquet sports, such as tennis, and often caused by overuse or repetitive strain due to the repeated extension of the wrist against resistance while the movement of throwing the ball is done. Moreover, other activities like prolonged computer typing or playing the piano can produce the same effect^[6].

The incidence of lateral epicondylitis is reported to be 1-3% in adults^[3,4,6]. 10% to 50% of tennis players develop this epicondylalgia at some time during their careers^[5,6]. Men tennis players are usually more affected than women tennis players, but it affects equally in non-athlete general population, mainly those who are between 30 and 50 years old^[4,6]. Furthermore, dominant extremity is more common to be the affected^[4,6].

The aim of this study is to review the current literature in order to gather information about the pathogenesis of tennis elbow or lateral epicondylitis.

METHODS

A bibliographic research has been performed with Medline database (PubMed) in June 2016. In order to obtain as much as relevant literature possible, the key words used were: tennis elbow AND pathogenesis.

After the research with these key words mixed, 434 results were obtained. Only manuscripts that had been published in the last five years were selected, reducing to 81 manuscripts. Only English-written studies were selected, as well as studies that really mentioned pathogenesis of lateral epicondylitis in adult tennis players. Finally, 4 papers were obtained (Figure 1).

RESULTS

Following the selection criteria, four systematic reviews were obtained referring to tennis elbow in athletes and pathogenesis. These studies mentioned the possible causes of lateral epicondylitis, especially in tennis players due to their constantly exercise over the extensor muscles that have their origin in the humeral epicondyle in order to keep going with the tennis practice. Different causes were described as shown in Table 1.

DISCUSSION

The present review analyzes the possible causes of lateral epicondylitis in tennis players in order to prevent it while playing tennis. All studies reviewed agree that tennis elbow is caused by repetitive eccentric contractions of the extensor carpi radialis brevis (ECRB) commonly done during the overhead throwing. But, in fact, it is postulated that depending on the morphology in the capitulum of

the humerus shape and tendon attachment, some individuals are more prone to develop lateral epicondylitis than others^[6].

Several authors agree that a poor or incorrect backhand technique in tennis leads to lateral epicondylitis^[3,4,6]. Thus, it is important that tennis players find out the best technique to avoid developing this pathology. Moreover, the conditions of the tennis racquet, such as its size and the tightness of the strings, can lead to develop this lesion, as it has been previously described^[3,4].

It is believed that elbow injuries are becoming more common as more people participate in throwing and racquet sports^[7]. Frostick^[7] says that the most usual injuries in racquet sports, such as tennis, include lateral epicondylitis with backhand, medial epicondylitis on downswing with trailing arm and lateral epicondylitis with leading arm. Elbow tendinopathy prevalence can be as high as 40% of tennis injuries^[8]. Furthermore, Hamilton^[9] noted that the mean age of incidence was 45 years old and its incidence might be expected to continue increasing into older age groups as degenerative changes continue.

It is known that lateral epicondylitis is caused by a repetitive contraction of the extensor carpi radialis brevis (ECRB), so that an increased frequency of a tennis play make contract more this muscle and lead to an apparition of inflammatory process and finally to micro-tears that cause the tendinosis^[2]. From the study done by Gurchow^[8], it can be said that players over 40 years old and playing more than 2 hours per day had nearly twice the risk of developing tennis elbow than those who played less than 2 hours, and players below 40 years old who played 2 or more hours had over 3.5 times the risk of those who played less.

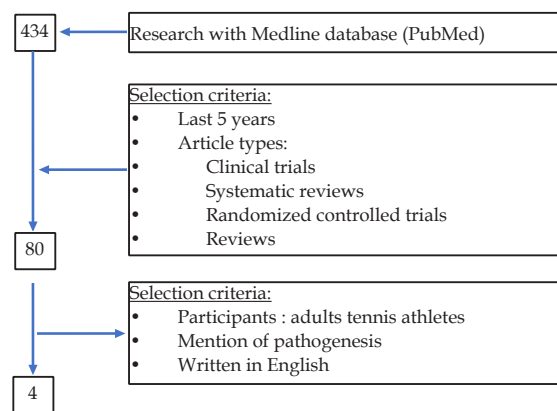


Figure 1 Summary of the research and selection criteria done using the key words “tennis elbow” and “pathogenesis”.

Table 1 Studies reviewed.

Author	Year	Level of evidence	Causes
Ahmad <i>et al</i> [3]	2013	IV	Incorrect technique
			Extended duration of play
			Frequency of play
			Size of the racket
Waseem <i>et al</i> [4]	2012	IV	Poor backhand technique in tennis
			Racket grip too small
			Strings too tight
			Playing with wet, heavy balls
Van Hofwegen <i>et al</i> [5]	2010	IV	Repetitive eccentric contractions of the ECRB muscle during backhand tennis swings
Brummel <i>et al</i> [6]	2014	IV	Improper technique

Goldi *et al*^[10] added that this micro-trauma resulting from repetitive contraction of the extensor carpi radialis brevis muscle due to wrist extension causes granulation tissue at the origin of this muscle.

With reference to the previous concepts, it is necessary not only to know if your own technique is the one that makes the extensor carpi radialis brevis muscle work less or if it is affecting the tendon of this one; but also try to do that rate of stretching the wrist extensor muscles that will not overpass the resistance of the tendons and cause the micro-tears.

Despite the existing elbow injuries in tennis players, we might also take into account other pathologies that produce elbow injuries that are common as well. Some examples of these ones could be valgus extension overload of the posterior compartment, flexor-pronator soreness, hyperextension and dislocation, olecranon bursitis, posterior impingement, ulnar collateral ligament sprain and ulnar nerve irritation, among others^[7]. These mentioned pathologies are not only common in racquet sports or golf, but also in other sports such as basketball, baseball, volleyball or gymnastics. However, sport is not a requirement for lateral epicondylitis, it can also be related to physical workplace factors such as forceful work, extreme posture and repetitive movements^[11], as seen in a prolonged computer typing.

In conclusion, a repetitive contraction of the extensor carpi radialis seems to cause lateral epicondylitis in tennis players. But, in fact, there are some aspects that differ: the conditions of the racquet could be a cause of this pathology, as well as an incorrect technique while playing tennis and the frequency of play.

Limitations

Several limitations should be taken into consideration. Level of evidence of this review should also be taken into account due to all of the papers reviewed had a level IV of scientific evidence.

REFERENCES

1. Baker CL, Nirschl RP. Lateral tendon injury: open and arthroscopic treatment. In: Atchek DV, Andrews JR, eds. The athlete's elbow. Philadelphia: Lippincott Williams & Wilkins 2001; 91-103.
2. Kraushaar BS, Nirschl RP. Tendinosis of the elbow (tennis elbow). Clinical features and findings of histological, immunohistochemical, and electron microscopy studies. *J Bone Joint Surg Am.* 1999 Feb; **81(2)**: 259-78. Review. [PMID: 10073590]
3. Ahmad Z, Siddiqui N, Malik SS, Abdus-Samee M, Tytherleigh-Strong G, Rushton N. Lateral epicondylitis: a review of pathology and management. *Bone Joint J.* 2013 Sep; **95-B(9)**: 1158-64. [PMID: 23997125]; [DOI: 10.1302/0301-620X.95B9.29285].
4. Waseem M, Nuhmani S, Ram CS, Sachin Y. Lateral epicondylitis: a review of the literature. *J Back Musculoskelet Rehabil.* 2012; **25(2)**: 131-42. Review. [PMID: 22866337]
5. Van Hofwegen C, Baker CL 3rd, Baker CL Jr. Epicondylitis in the athlete's elbow. *Clin Sports Med.* 2010 Oct; **29(4)**: 577-97. [PMID: 20883898]; [DOI: 10.1016/j.csm.2010.06.009]
6. Brummel J, Baker CL 3rd, Hopkins R, Baker CL Jr. Epicondylitis: lateral. *Sports Med Arthrosc.* 2014 Sep; **22(3)**: e1-6. [PMID: 25077751]; [DOI: 10.1097/JSA.0000000000000024]
7. Frostick SP, Mohammad M, Ritchie DA. Sport injuries of the elbow. *Br J Sports Med.* 1999 Oct; **33(5)**: 301-11. [PMID: 10522631]; [PMCID: PMC1756201]
8. Gruchow HW, Pelletier D. An epidemiologic study of tennis elbow. Incidence, recurrence, and effectiveness of prevention strategies. *Am J Sports Med.* 1979 Jul-Aug; **7(4)**: 234-8. [PMID: 474862]
9. Hamilton PG. The prevalence of humeral epicondylitis: a survey in general practice. *J R Coll Gen Pract.* 1986 Oct; **36(291)**: 464-5. [PMID: 3440991]; [PMCID: PMC1960610]
10. Goldie I. Epicondylitis Lateralis Humeri (Epicondylalgia or Tennis Elbow). A Pathogenetical Study. *Acta Chir Scand Suppl.* 1964; **57**: SUPPL 339:1+. [PMID: 14192714]
11. Haahr JP, Andersen JH. Physical and psychosocial risk factors for lateral epicondylitis: a population based case-referent study. *Occup Environ Med.* 2003 May; **60(5)**: 322-9. [PMID: 12709516]; [PMCID: PMC1740535]

Peer reviewer: Naiquan (Nigel) Zheng