

## Direct Anterior Approaches in Hip Arthroplasty. An Ephemeral Trend or the Forthcoming 'Gold Standard'?

Nikolaos Platon Sachinis, Panagiotis Konstantinou, Paschalia Athanasiadou, Thomas Apostolou, Panagiotis Givissis

Nikolaos Platon Sachinis, Panagiotis Konstantinou, Paschalia Athanasiadou, Thomas Apostolou, Panagiotis Givissis, Interbalkan Medical Center, Thessaloniki, Greece

**Conflict-of-interest statement:** The author(s) declare(s) that there is no conflict of interest regarding the publication of this paper.

**Open-Access:** This article is an open-access article which was selected by an in-house editor and fully peer-reviewed by external reviewers. It is distributed in accordance with the Creative Commons Attribution Non Commercial (CC BY-NC 4.0) license, which permits others to distribute, remix, adapt, build upon this work non-commercially, and license their derivative works on different terms, provided the original work is properly cited and the use is non-commercial. See: <http://creativecommons.org/licenses/by-nc/4.0/>

**Correspondence to:** Nikolaos Platon Sachinis, MD, Platonos-Aisxylou, Peyka, 57010, Thessaloniki, Greece.

**Email:** [nick.sachinis@gmail.com](mailto:nick.sachinis@gmail.com)

**Telephone:** +306978305195

**Received:** January 12, 2017

**Revised:** February 22, 2017

**Accepted:** February 24 2017

**Published online:** April 28, 2017

### ABSTRACT

The incidence of osteoarthritis and subsequent number of total hip arthroplasties rises each year, corresponding to the aging but yet more active population. Patients request minimal scars and improved early results accompanied by long procedure survivability. Orthopaedic surgeons have utilised minimal invasive procedures in order to achieve these goals and Direct Anterior Approaches (DAA) fit as such techniques. Modified by the traditional Smith Petersen approach, DAA such as the Anterior Minimally Invasive Surgery (AMIS) and Anterior Supine Intermuscular (ASI) exploit the same internervous plane between the sartorius, rectus femoris (femoral nerve) and tensor fascia lata (superior gluteal nerve). Instrumentation plays a major role in establishing good exposure to acetabulum and femur

and differences exist between ASI and AMIS for the use of a special orthopaedic table (ASI uses a standard table). Clinical outcomes and survivability are analysed by several studies. Early results indicate faster recovery and shorter hospital stays and comparable medium and long term outcomes/survivability. However, most authors agree on DAA's lengthy learning curve and suggest that a surgeon may accomplish optimal results after 30-50 procedures approximately. Intraoperative complications, such as injury to lateral femoral cutaneous nerve and femur fractures, are specifically seen with use of DAA. Surgeons should be well educated and trained in anterior hip approaches before applying the latter. Quicker rehabilitation and comparable arthroplasty survival may be achieved but few studies exist and more are needed to be set, before DAA becomes the new 'gold standard' in hip arthroplasty.

**Key words:** Direct Anterior Approach; AMIS; ASI; DAA; Hip; Approach

© 2017 The Author(s). Published by ACT Publishing Group Ltd. All rights reserved.

Sachinis NP, Konstantinou P, Athanasiadou P, Apostolou T, Givissis P. Direct Anterior Approaches in Hip Arthroplasty. An Ephemeral Trend or the Forthcoming 'Gold Standard'? *International Journal of Orthopaedics* 2017; **4(2)**: 708-713 Available from: URL: <http://www.ghrnet.org/index.php/ijo/article/view/2007>

### INTRODUCTION

By 2030, approximately 67 million United States of America (USA) citizens aged 18 years or older are projected to have doctor-diagnosed arthritis<sup>[1]</sup>. Osteoarthritis is by far the most common as the lifetime risk of symptomatic hip osteoarthritis is 25.3%<sup>[2]</sup>. According to Rosemont *et al* in 2004, the number of primary Total Hip Replacements (THR) in United States was 232,857<sup>[3]</sup>. It is estimated that all hip arthroplasties (hemi and total) performed each year in the United States have increased from 333,200 in 2003 to 468,000 in 2012 with an average annual increase of 2.9%<sup>[4]</sup>. The incidence of THR alone increased 73 percent from 2000 to 2009: 123 percent for patients ages 45 to 64 and 54 percent for ages 65 to 84<sup>[5]</sup>.

It is a known fact that the majority of orthopaedic surgeons worldwide prefer conventional hip approaches such as the posterior and the lateral. There are numerous studies identifying the advantages of these<sup>[6,7]</sup>. The excellent exposure of the hip joint that they provide, make them an invaluable asset in each surgeon's arsenal, whether he performs a primary or a revision total hip arthroplasty.

However as the total number of THRs is growing each year, new needs arise both on patients and surgeons and hospitals. The number of younger patients undergoing THR increases and so do their expectations, not only in terms of functionality, but also in terms of smaller scars, earlier discharge and shorter rehabilitation period.

In contrast with conventional techniques, direct anterior approaches (DAA) seem to currently grow popularity among the orthopaedic hip surgeons and patients. Medacta documented the 110,000th hip arthroplasty performed via the Anterior Minimally Invasive Surgery (AMIS) technique in December 2013<sup>[8]</sup>. According to the Australian National Replacement Registry, in 2007 seven surgeons performed 73 hips and in 2013 sixty performed 2340 hip replacements. Most THRs (95%) were performed using the AMIS technique<sup>[8]</sup>.

Indications of DAA have been widened during recent years, in order to include dysplastic hips. Oinuma *et al*<sup>[9]</sup> have reported satisfactory outcomes in 322 cases of dysplastic hip that underwent total hip arthroplasties using the DAA. Several techniques have been developed with the use of DAA and specific instrumentation and implants. This review marks key points of DAA and highlights outcomes and complications as demonstrated in international literature.

## ANATOMY/APPROACH

The anterior approach to the hip, which is commonly known as 'Smith-Petersen approach', was described in 1881 by a German surgeon Dr Carl Hueter<sup>[10]</sup>. Frederic Laude<sup>[11]</sup> published an article which shows an adaptation of this approach, which Judet used also 50 years ago, but with a number of modifications in the operating table and the tissue retractors which create a 'minimally invasive anterior approach' to the hip for joint replacement (Figure 1A, B). This modified approach, which several French surgeons adopted, was the jumpstart for the AMIS technique<sup>[11]</sup>. Exploiting the same internervous plane Dr Erik De Witte and associates started using an alternative technique without the need of a traction table, the Anterior Supine Intermuscular (ASI)<sup>[12,13]</sup>.

Both of these approaches use the internervous plane between tensor fascia lata on the lateral side (superior gluteal nerve) and the sartorius and rectus femoris on the medial side (femoral nerve)<sup>[14]</sup>. The incision is placed normally 2-3 cm posterior and 1-2 cm distal to Anterior Superior Iliac Spine (ASIS). The subcutaneous tissue has two layers: one superficial (Campers fascia) and one deeper (Scarpa's fascia). Between this deeper layer and the fascia of the thigh muscles, the Lateral Femoral Cutaneous Nerve (LFCN) courses downwards through the operating field. For this reason it is preferred to make the incision of the fascia more laterally to minimize the risk of LFCN, which stays medially<sup>[13]</sup>. Then the fascia is incised in line with skin incision, over the tensor, and an Alice clamp is attached at the medial site of the fascia to help the surgeon as he bluntly sweeps the tensor muscle off the sartorial fascia<sup>[13]</sup>.

As a retractor is placed over the superolateral aspect of the femoral neck the surgeon should be careful in order to recognize and cauterize or ligate the branches of lateral femoral circumflex artery, as they are in the surgical field and an injury of them can cause bleeding, which may be difficult to control, if the artery branches retracted<sup>[13,15]</sup>. Then a retractor inferior to the femoral neck is placed. A third retractor may



**Figure 1** Special extension for a traction table (AMIS Mobile Leg Positioner, Medacta International SA, Castel San Pietro, Switzerland) that facilitates optimal leg positioning during a direct anterior approach surgery. A) Leg positioner folded, B) Leg positioner placed on traction table.

be placed under the rectus tendon on the top of the anterior rim of the acetabulum. However, this requires attention not to injury femoral

nerve and vessels. The next step is the exposure through capsulotomy. A L-shaped capsulotomy is performed in which, the first limb is in line with the intertrochanteric line along the superior border of the vastus intermedius and the other limb is parallel to the femoral neck up to the edge of the acetabulum<sup>[16]</sup>. Then the two standard retractors should be placed inside the capsule and the surgeon performs the osteotomy either in situ or with dislocated femoral head.

After removing of the femoral head, exposure of the acetabulum is usually very good with the use of one retractor anteriorly and one posterolaterally<sup>[17]</sup> (Figure 2). An external rotation of about 45° of the femur has been proven very useful for the visualization and the preparation of the acetabulum<sup>[18]</sup>. The very next step is preparation and insertion of the acetabular component according to the guidelines of the material used. The ideal cup position is when placed approximately at 45° inclination and 10°-20° of anteversion<sup>[14,16,18]</sup>. After the insertion of the cup, in order to facilitate femoral broaching and component insertion, the hip should be 90° externally rotated and hyper extended and adducted. Application of a femoral hook may help this procedure (Figure 3). The whole process could be done with the use of a special orthopaedic traction table, either PROFx (Orthopedic Systems Inc., Union City, CA) or HANA table (OSI, Union City, CA)<sup>[14,16,18]</sup>.

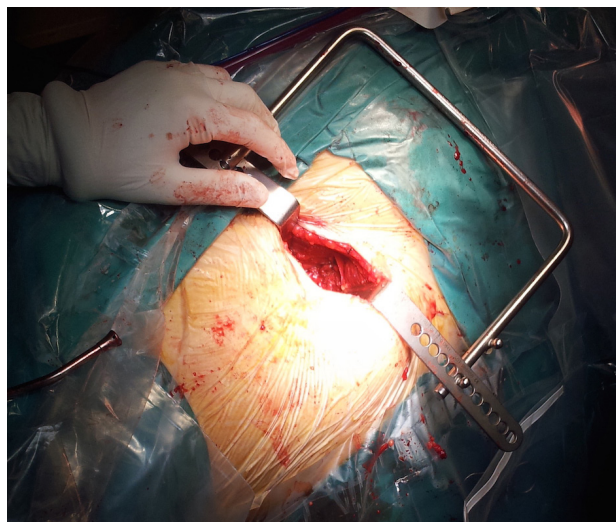
However, the use of this traction table is not imperative. The preparation of the femur can be managed without a special table, but with an experienced assistant placing the leg to the appropriate position each time<sup>[17]</sup>. This is the most clear and distinguished difference between AMIS and ASI techniques, the first requires a traction table, the second not. As soon as the femoral components are safely placed, reduction of the hip is managed. In regards to soft tissue closure, the anterior hip capsule can be closed with the tag suture. Then, the fascia lata can be closed with a running, followed by subcutaneous and skin closure<sup>[14,16,18]</sup> (Figure 4A, B).

## CURRENT DESIGNS

Several companies have produced designs in order to achieve long survivability, demonstrable good outcomes and low complication rates (Table 1). Survival has been studied by Solomon M<sup>[8]</sup> who analysed the Australian Registry and found that the combination of Versafit/Quandra (Medacta International SA, Castel San Pietro, Switzerland) had a cumulative percent revision of 4.9% at one year in 2009, which in 2010 was 3.1% and in 2012 was comparable to the percent of the general average revision rate. Additionally, the 5 years results in Uniklinik Balgrist, Zurich of Versafit/Quandra combination was 94.6%, 78.9% for the first 20 and 96.8% for the following 130 procedures regarding the overall five-year survival rate<sup>[8]</sup>.

Regarding other primary outcome measures, Solomon M<sup>[8]</sup> also studied the median Harris Hip Score (HHS) and WOMAC scores which were 99 points (61-100) and 0 points (0-7.5), respectively. The mean annual polyethylene wear was measured 0.0059mm/year. In another study, Šebečić *et al*<sup>[19]</sup> performed 35 THR with AMIS approach and Medacta implants. The early functional outcome at 2 and 4 months was measured by HSS. At two months and against a control group HSS were 80.2 vs 69.4 ( $p < 0.01$ , higher in AMIS group); at 4 months HSS were 92.4 vs 88.1 (higher in AMIS group).

Berend K.R. *et al*<sup>[20]</sup>, between January 2006 and August 2008, performed total hip arthroplasties by using the Taperloc Microplasty stem (Biomet, Warsaw, IN, USA). From the 655 THR performed with the Taperloc stem, 289 (39%) were done through an ASI approach, while 372 (57%) were done through a lateral approach (modified Hardinge approach). The author recorded that the average six-week HSS was significantly higher for those with the ASI approach, 80 vs



**Figure 2** Placement of a modified Charnley retractor in order to provide better visibility through a direct anterior approach, during a total hip arthroplasty. The retractor is placed transversely in relation to the incision, which is usually 8-10 cm.



**Figure 3** Part of instrumentation used during an Anterior Minimal Invasive Surgery (Medacta International SA, Castel San Pietro, Switzerland). Note the hook used to lift the proximal femur and the curved instrument for receiving different sized rasps.

75 ( $p < 0.0001$ ). The preoperative score was the same for these two groups.

Fitmore Hip Stem (Zimmer, Warsaw, IN) is designed so as to preserve more bone in the greater trochanter and it also has been used in studies combined with DAA approaches. Bal *et al*<sup>[21]</sup> presented results from 100 minimally invasive THAs. Mean operative duration was 53 minutes, mean blood loss was 185 cc (65-630); the follow up lasted 10 months and their complications were 1 case of pulmonary

embolism and 1 patient with calcar fracture. The authors assumed that inexperienced surgeons might not achieve results like these, while a single surgeon performed the 100 THAs of the study after receiving special training with cadavers. Yerasimides *et al*<sup>[16]</sup> analysed the outcomes after the use of Fitmore stem in a series of 1400 primary Hip Arthroplasties with DAA. The authors presented approximately 50 surface replacements, 70 revisions and no dislocations overall. The authors summarised in favour of the effectiveness of this approach.

Accolade designs from Stryker (Stryker Orthopaedics, Mahwah, NJ) are purposed for cementless press-fit application with a mini approach. Nakata *et al*<sup>[22]</sup> used Stryker hardware in a clinical comparative study of DAA with Mini Posterior Approach (MPA) that demonstrated faster recovery when it comes to hip function and gait ability by using DAA rather than MPA. The DAA group presented better cup positioning (99% over 91% of the MPA). This could be attributed to the lack of forced traction that might change the pelvic tilt angle. However, the blood loss volume in that study turned out to be greater in DAA.

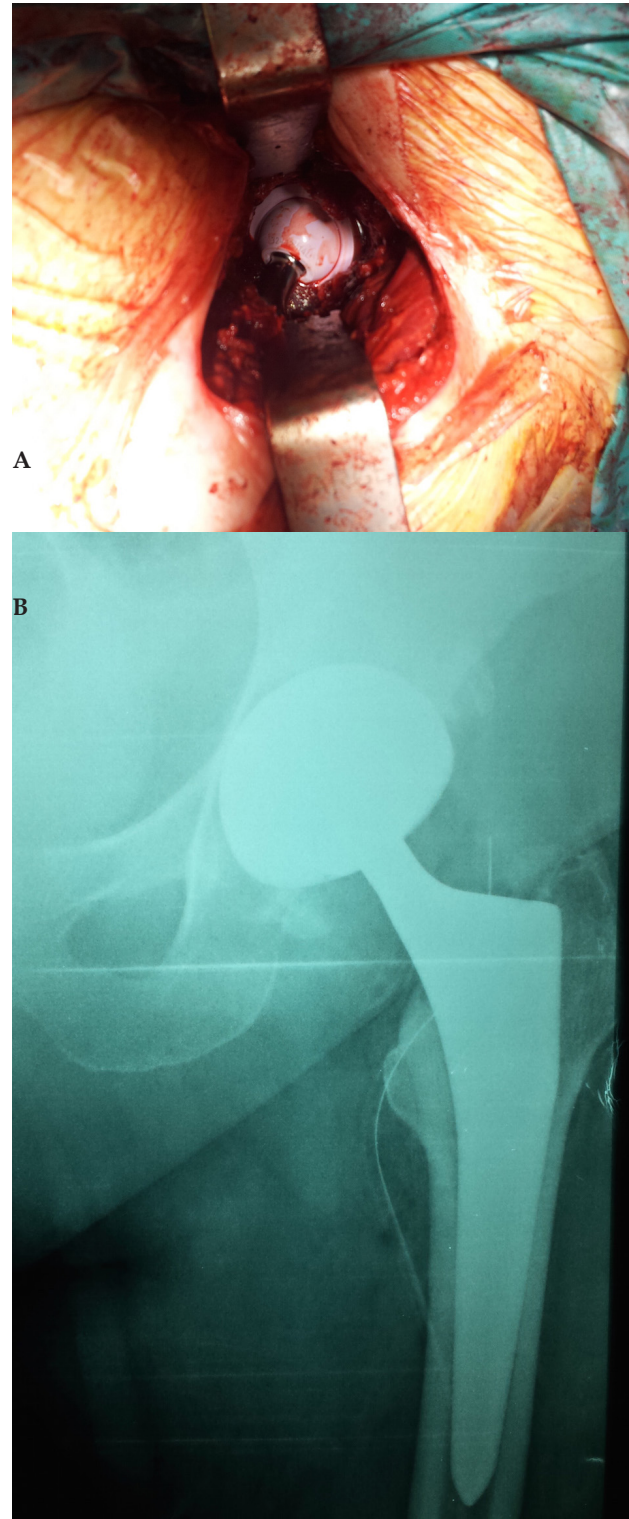
## LEARNING CURVE

Surgical experience is considered very important by many authors and extensive references are made to the so-called 'learning curve' of the procedure, either AMIS or ASI. Solomon<sup>[8]</sup> studying the Australian Registry since 2007, declares a surgeon experienced after 50 AMIS approaches so that complications may be reduced. Surgeons with less experience had a higher rate of complications. The author assumed the surgeon to be a trainee until that number of approaches is reached. He based this statement after showing from the Registry outcomes that in the first 50-100 procedures revision rates are double when compared to the following ones, and that during the first 15 procedures revision rates are 4 times higher. Woolson *et al*<sup>[23]</sup> found that adequate training is important for the reduction of complications and that complications were reduced after 30-40 procedures. Goytia *et al*<sup>[24]</sup> noticed substantial improvement in the reduction of complication rates after 60 procedures.

Spaans *et al*<sup>[25]</sup> compared 46 THAs with the Direct Anterior Approach to another 46 conventional THAs. To evaluate the learning curve effect, they divided the DAA group into 3 subgroups: the first subgroup involved the first 1-15 hips, the second involved the next fifteen hips, and the third, hips 31-45. Operation time (skin incision to skin closure), intraoperative blood loss, time of hospital stay, clinical outcome, and complications were compared in the 3 subgroups also. The operating time was the only diminished parameter, pointing a learning curve in these 45 procedures. In another study emphasising the procedure's learning curve, De Geest *et al*<sup>[26]</sup> noticed intraoperative fractures in low experienced surgeons concluding to a 'significant learning curve' with high complication rate in comparison to other methods.

## COMPLICATIONS

Intraoperative complications that are produced with a DAA, either AMIS or ASI, are mostly related to problems arising from relatively poor exposure of the femur or injury to LFCN. De Geest *et al*<sup>[26]</sup> in their previously mentioned study performed 300 hip arthroplasties with DAA approaches (by use of special orthopaedic tables) from March 2009 to March 2011. Medacta implants were used in 156 of them and Biomet implants in the rest 144. The intraoperative complication rate was 3% and the most common reason was femoral, great trochanter or calcar fracture. All the femoral fractures occurred



**Figure 4** A) Final placement of ceramic on ceramic prosthesis during a total hip arthroplasty through a Minimally Invasive Surgery (AMIS, Medacta International SA, Castel San Pietro, Switzerland). B) Anteroposterior radiograph of the hip of the same patient after skin closure confirming optimal implant placement.

with the Quadra Medacta stem and none with Taperloc Biomet stem. Periprosthetic femur fractures were found in 5 (1.67%) and infection was presented in 10 (3.33%) patients. Injury of the LFCN in this study happened in 16 (5.33%) cases. Šebečić *et al*<sup>[19]</sup> found one femoral perforation with rasp (3%), one fracture of greater trochanter

**Table 1** Companies that produce specific designs and instrumentation for direct anterior approaches.

Company	Stem	Special instrumentation
Medacta	AMISem-H	· Standard with 135° neck shaft angle
		· Lateralised with 127° neck shaft angle
	AMISem-H Collared	· Titanium- Niobium alloy
		· 80 µm thick Hydroxyapatite (HA) coating after a superficial sand-blasting of 4 to 7 µm roughness
	AMISem-C	· Standard with 135° neck shaft angle
		· Lateralized with 127° neck shaft angle
· High nitrogen stainless steel		
· Mirror polished surface		
Depuy-Synthes	Summit Porocoat	· Neck shaft angle 130°
		· High strength forged titanium alloy
		· 3-degree biplanar taper
		· Articuleze 12/14 neck taper
	Summit DuoFix HA	· Porous coating
		· Grit-blasted diaphyseal region
		· Polished distal bullet tip
		· Application of plasma-sprayed HA over Porocoat Porous Coating in DuoFix HA
	· Standard and high offset	
Stryker	Allocade TMZF	· Proprietary beta titanium alloy
		· 50 µm thick PureFix HA coating
		· Circumferential plasma spray surface over the proximal body
		· Offset options are available in both 132-degree and 127-degree neck angles
		· Reduced neck geometry
		· Tapered Wedge Design
Biomet	Taperloc microplasty hip stem	· Introduced in 2007 and has been shortened 35mm from the standard Taperloc stem
		· PPS (Porous Plasma Spray) coating
		· Flat Tapered Wedge
	Balance microplasty hip stem	· Bone conserving design is conducive to minimally invasive techniques, including ASI
		· Six degree anterior build-up allows potential for immediate weight bearing
		· PPS coating
	· Bone conserving design	
Zimmer	Fitmore hip stem	· Protasul - 64 WF Titanium alloy (Ti Al6V4)
		· Ti-Plasma (Ti-VPS) coating on the proximal surface
		· Rough blasting distally
		· Three Families (A, B-B extended & C)
		· Preserves natural bone in the greater trochanter
		· Different medial curvatures
	· Trapezoidal cross-section	
Mathys	TwinSys stem uncemented	· Triple taper design
		· Ti6A 4V material
	TwinSys stem cemented	· Plasma spray method is used to deposit a hydroxyapatite coating on the corundum-blasted surface
		· Triple tapered stem geometry
	· Mirror-bright polished surface to absorb micro-movements at the implant/cement coat interface	

(3%) and the most common complication was the injury of LFCN (2 patients, 6%). According to Berend *et al*<sup>[20]</sup> proximal femoral perforation was the most common intraoperative complication in the ASI group using the Taperloc Microplasty Stem (Biomet, Warsaw, IN, USA), despite its low rate (2 out of 289). Periprosthetic femoral fracture requiring stem revision and cable fixation was the most common reason for reoperation (4 out of 6 cases). The most usual major complication by the surgical procedure was LFCN injury in 2 out of 289 cases. The incidence of LFCN impairment after an anterior

approach reaches 14.8% according to Bhargava T *et al*<sup>[27]</sup>.

Regarding operating time, Spaans *et al*<sup>[25]</sup> compared 46 THAs with DAA to another 46 conventional THAs. They resulted to double surgery time (84 min in the DAA group and 46 min in the PLA group) and blood loss (704 mL in the DAA group and 364 mL in the PLA group) with the DAA. Also, a larger complication rate including complications as dislocation, revision due to cup migration and femoral stem collapse, and trochanteric fracture was found; 4 patients underwent intraoperative conversion from a DAA to a PLA. Hallert

*et al.*<sup>[17]</sup> also focused on complications resulting from 200 THAs using a DAA approach. Mean operating time was 114 minutes (statistically significant longer time in obese patients). Out of 200 there were 5 revisions, 3 perioperative femoral fractures and 6 dislocations, along with 3 cases of nerve injury and 2 infections. Certain problems can be presented in obese patients, or muscular patients or with short femoral neck and acetabular protrusion<sup>[17]</sup>.

## SUMMARY

As a relatively new trend arises, so does the interest among surgeons and patients. The promises of quicker recovery and improved early outcomes have been exhibited in international literature by several authors. But what has also been shown is the need for thorough education and increased practice with DAA in order for a surgeon to achieve long-term outcomes comparable to that of conventional approaches. Few published papers analyse the medium, or long-term survival of the prostheses placed by DAA and there is certainly a need for more studies showing all long-term outcomes of DAA. Anterior minimal invasive techniques may be granted the etiquette of the new trend in hip arthroplasty. Until becoming the ‘gold’ standard, there is a uncertainty whether education should be promoted to orthopaedic residents by including these techniques in their portfolio, or let only specific hip surgeons interested in DAA endorse its continuation. Results of future studies and debates at international meetings may provide the answer to this query.

## REFERENCES

- Hootman JM, Helmick CG. Projections of US prevalence of arthritis and associated activity limitations. *Arthritis and rheumatism* 2006; **54**(1): 226-229. [DOI: 10.1002/art.21562]
- Murphy LB, Helmick CG, Schwartz TA, Renner JB, Tudor G, Koch GG, *et al.* One in four people may develop symptomatic hip osteoarthritis in his or her lifetime. Osteoarthritis and cartilage / OARS, Osteoarthritis Research Society. 2010; **18**(11): 1372-9. 2998063. [DOI: 10.1016/j.joca.2010.08.005]
- Rosemont I. The Burden of Musculoskeletal Diseases in the United States. American Academy of Orthopaedic Surgeons. 2008.
- Fingar KR SC, Weiss AJ, Steiner CA. Most Frequent Operating Room Procedures Performed in U.S. Hospitals, 2003–2012. HCUP Statistical Brief. 2014(186).
- Drew J.M. LJK, Briggs V, Franklin P, Ayers DC. Trends in Total Hip Arthroplasty in the United States: The Shift to a Younger Demographic. 2014 Annual AAOS Meeting Proceedings. 2014; Paper No. 542.
- Sculco TP. Anterior approach in THA improves outcomes: opposes. *Orthopedics* 2011; **34**(9): e459-61. [DOI: 10.3928/01477447-20110714-29]
- Alecci V, Valente M, Crucil M, Minerva M, Pellegrino CM, Sabbadini DD. Comparison of primary total hip replacements performed with a direct anterior approach versus the standard lateral approach: perioperative findings. *Journal of orthopaedics and traumatology: official journal of the Italian Society of Orthopaedics and Traumatology*. 2011; **12**(3): 123-129. 3163771. [DOI: 10.1007/s10195-011-0144-0]
- 7th Medacta Orthopaedic Research and Education (M.O.R.E.) International Symposium proceedings. *The Bone & Joint Journal*. 96(B).
- Oinuma K, Tamaki T, Miura Y, Kaneyama R, Shiratsuchi H. Total hip arthroplasty with subtrochanteric shortening osteotomy for Crowe grade 4 dysplasia using the direct anterior approach. *The Journal of arthroplasty* 2014; **29**(3): 626-9. [DOI: 10.1016/j.arth.2013.07.038]
- C. H. Grundriss der chirurgie. 2nd edition. Leipzig. FCW Vogel. 1883.
- F. L. Total hip arthroplasty through an anterior Hueter minimally invasive approach. *Interactive Surgery* 2006; **1**(1-4): 5-11. [DOI: 10.1007/s11610-006-0011-5]
- de Witte PB, Brand R, Vermeer HG, van der Heide HJ, Barnaart AF. Mid-term results of total hip arthroplasty with the CementLess Spotorno (CLS) system. *The Journal of bone and joint surgery American volume*. 2011; **93**(13): 1249-55. [DOI: 10.2106/JBJS.I.01792]
- Moskal JT, Capps SG, Scaneli JA. Anterior muscle sparing approach for total hip arthroplasty. *World journal of orthopedics* 2013; **4**(1): 12-8. 3557317. [DOI: 10.5312/wjo.v4.i1.12]
- Jonathan G.Yerasimides JMM. Primary Total Hip Arthroplasty with a Minimally Invasive Anterior Approach. *Seminars in Arthroplasty* 2005; **16**(3): 186-90. [DOI: 10.1053/j.sart.2005.10.004]
- Uzel M, Tanyeli E, Yildirim M. An anatomical study of the origins of the lateral circumflex femoral artery in the Turkish population. *Folia morphologica* 2008; **67**(4): 226-30.
- Yerasimides JG. Use of the Fitmore(R) hip stem bone-preserving system for the minimally invasive anterior-supine approach in hip replacement. *American journal of orthopedics* 2010; **39**(10 Suppl): 13-6.
- Hallert O, Li Y, Brismar H, Lindgren U. The direct anterior approach: initial experience of a minimally invasive technique for total hip arthroplasty. *Journal of orthopaedic surgery and research* 2012; **7**: 17. 3419665. [DOI: 10.1186/1749-799X-7-17]
- Matta JM, Shahrdar C, Ferguson T. Single-incision anterior approach for total hip arthroplasty on an orthopaedic table. *Clinical orthopaedics and related research* 2005; **441**: 115-24.
- Sebecic B, Staresinic M, Culjak V, Japjec M. Minimally invasive hip arthroplasty: advantages and disadvantages. Medicinski glasnik: official publication of the Medical Association of Zenica-Doboj Canton, Bosnia and Herzegovina. 2012; **9**(1): 160-5.
- Berend KR, Lombardi AV, Jr., Seng BE, Adams JB. Enhanced early outcomes with the anterior supine intermuscular approach in primary total hip arthroplasty. *The Journal of bone and joint surgery American volume*. 2009; **91** Suppl 6: 107-20. [DOI: 10.2106/JBJS.I.00525]
- Bal BS, Vallurupalli S. Minimally invasive total hip arthroplasty with the anterior approach. *Indian journal of orthopaedics* 2008; **42**(3): 301-8. 2739476. [DOI: 10.4103/0019-5413.41853]
- Nakata K, Nishikawa M, Yamamoto K, Hirota S, Yoshikawa H. A clinical comparative study of the direct anterior with mini-posterior approach: two consecutive series. *The Journal of arthroplasty* 2009; **24**(5): 698-704. [DOI: 10.1016/j.arth.2008.04.012]
- Woolson ST, Pouliot MA, Huddleston JI. Primary total hip arthroplasty using an anterior approach and a fracture table: short-term results from a community hospital. *The Journal of arthroplasty* 2009; **24**(7): 999-1005. [DOI: 10.1016/j.arth.2009.04.001]
- Goytia RN, Jones LC, Hungerford MW. Learning curve for the anterior approach total hip arthroplasty. *Journal of surgical orthopaedic advances* 2012; **21**(2): 78-83.
- Spaans AJ, van den Hout JA, Bolder SB. High complication rate in the early experience of minimally invasive total hip arthroplasty by the direct anterior approach. *Acta orthopaedica* 2012; **83**(4): 342-346. 3427623. [DOI: 10.3109/17453674.2012.711701]
- De Geest T, Vansintjan P, De Loore G. Direct anterior total hip arthroplasty: complications and early outcome in a series of 300 cases. *Acta orthopaedica Belgica* 2013; **79**(2): 166-73.
- Bhargava T, Goytia RN, Jones LC, Hungerford MW. Lateral femoral cutaneous nerve impairment after direct anterior approach for total hip arthroplasty. *Orthopedics* 2010; **33**(7): 472. [DOI: 10.3928/01477447-20100526-05]