

Localized Gigantism: A Clinical Study of 20 Cases

Mohammed Khaja Nizamuddin Khateeb, Pundaleekappa Sabanna Kaladagi

Mohammed Khaja Nizamuddin Khateeb, Assistant Professor, Department of Orthopaedics, Esic Medical College, Kalaburagi. 585106, Karnataka, India

Pundaleekappa Sabanna Kaladagi, Professor, Department of Orthopaedics, S. Nijalingappa Medical College and H S K Hospital Research Centre, Bagalkot, Karnataka, India

Conflict-of-interest statement: The author(s) declare(s) that there is no conflict of interest regarding the publication of this paper.

Open-Access: This article is an open-access article which was selected by an in-house editor and fully peer-reviewed by external reviewers. It is distributed in accordance with the Creative Commons Attribution Non Commercial (CC BY-NC 4.0) license, which permits others to distribute, remix, adapt, build upon this work non-commercially, and license their derivative works on different terms, provided the original work is properly cited and the use is non-commercial. See: <http://creativecommons.org/licenses/by-nc/4.0/>

Correspondence to: Mohammed Khaja Nizamuddin Khateeb, Assistant Professor, Department of Orthopaedics, Esic Medical College, Kalaburagi. 585106, Karnataka, India.

Email: nizam.in4u@gmail.com

Telephone: +9620334813

Received: March 1, 2017

Revised: March 25, 2017

Accepted: March 28 2017

Published online: April 28, 2017

ABSTRACT

BACKGROUND: Localized Gigantism is uncommon condition encountered in clinical practice. Enlargement & thickening of a limb or digit may be due to Haemangioma, lymphangioma, lipoma or tumour mass. In these situations, only a defined element (vessels, subcutaneous fat, bone etc) is affected. Congenital localized gigantism strictly speaking, refers to the rare malformation characterized by enlargement of all structures of a limb, digit or its phalanges, subcutaneous fat, nerve, vessel, skin, nail etc. Localized gigantism has also been described under many names such as Macroductyly, Megalodactyly, Dactylomegaly, Macrosomia, Macrodistrophia lipomatosa(MDL).

MATERIAL AND METHODS: The Study of 20 cases of Localized form of gigantism in different congenital conditions was carried out in Mmcri Mysore, Kims Hubli and Esic Medical College Kalaburagi during the last 30 years. Here patients were mainly seeking medical advice for cosmetic reasons & for disability certificates. We took clinical photographs plain radiographs of affected limb, USG (Gray scale & Doppler) & Biopsy of tissue.

RESULTS: In all the cases there was abundance of fibrofatty tissue along with dense fibrous tissue, in few cases especially upper limb, nerves were enlarged & thickened. It was confined to Mega foot- 5 Cases since childhood, stretched shiny scaly dry skin, double the girth of opposite limb, Syndactyly (2 & 4th) Toe, Rudimentary (1st & 5th Toe Variation), Unilateral Giant Lower Limb -5 cases, Giant Upper Limb- 3 Cases, Radial Mega Hand Mega Thumb-4 cases, Macroductyly of Index Finger-3cases. All were compatible with normal life.

CONCLUSION: We conclude that it is a rare type of disease. No genetic involvement, any theories cannot be formed or dismissed. Few were associated with Neurofibromatosis. HPE: Excessive proliferation & accumulation of fat is the basic lesion. Surgical correction is the treatment of choice than observation, taking into account possible future complications in the absence of surgery and the beneficial outcomes of surgical procedures.

Key words: Congenital; Localized; Gigantism; Lower limb; Upper limb; Mega foot

© 2017 The Author(s). Published by ACT Publishing Group Ltd. All rights reserved.

Nizamuddin MK, Kaladagi PS. Localized Gigantism: A Clinical Study of 20 Cases. *International Journal of Orthopaedics* 2017; 4(2): 724-729 Available from: URL: <http://www.ghrnet.org/index.php/ijo/article/view/2017>

INTRODUCTION

Localized Gigantism is described as a rare, non-hereditary, congenital condition presenting with localized macroductyly and a proliferation of mesenchymal elements^[1]. There is in particular a marked increase in fibroadipose tissue. It usually involves areas of distribution of the plantar and median nerves^[2]. Enlargement & thickening of a limb or digit may be due to haemangioma, lymphangioma, lipoma, or tumour mass. In these situations, only

a defined element (vessels, subcutaneous fat, bone etc) is affected. Congenital localized gigantism strictly speaking, refers to the rare malformation characterized by enlargement of all structures of a limb, digit or its phalanges, subcutaneous fat, nerve, vessel, skin, nail etc. Localized gigantism has also been described under many names such as Macroductyly, Megalodactyly, Dactylomegaly, Macrosomia, Macrodistrophia lipomatosa.

Radiological investigations include plain film radiographs, USG and MRI, where findings may be typical. Plain films show lucent soft-tissue overgrowth as well as hypertrophy of osseous structures in the distribution of the median and plantar nerves. The localized gigantism is almost invariably recognized at birth, but starts to cause problems as the child grows. There may be difficulty in walking and in performing routine activities, but cosmetics are the main issue concerning the patient requiring consultation with surgeons. This disease is usually unilateral. The growth velocity may differ from digit to digit. The lower limb is more frequently involved than the upper limb. The abnormal area is usually along a specific sclerotome. The second and third digit of the hand and feet are most frequently involved, corresponding to the median nerve and medial plantar nerve supply in the upper and lower limb³¹.

MATERIAL AND METHODS

We had an exceptional opportunity to study 20 cases of localized gigantism in the department of orthopaedics Mmcri Mysore, Kims Hubli and Esic MC Kalaburagi, during the last 30 years. Here patients were mainly seeking medical advice for cosmetic reasons & for disability certificates. We took clinical photographs, plain radiographs of affected limb, USG (Gray scale & doppler) which showed soft tissue thickening (Figure 1) & no increased blood flow. Biopsy of tissue was also done. Some patients refused for the same. Out of these five were of Megafoot and five cases Giant lower-limb involvement, three were giant upperlimb cases, four were Macroductyly of the thumb and Macroductyly of index finger-3cases. Although parents noted the abnormalities shortly after birth, none of the patients presented before eight years of age. Increasing difficulty in wearing shoes and cosmetic worries were the main cause

for seeking medical advice. The presenting age ranged from 8 to 45 years. Twelve of these were male while eight were female (3:2) (Table 1). A detailed history revealed that the enlargement began shortly after birth in all the cases and the affected limb or digit grew at faster rate.

Clinical examination of the affected limb or finger or toe revealed thickened pale, glossy and non-tender skin. Consistency was firm in some areas and soft in others. Dorsal and lateral curvature of the affected digit was seen in two cases, while plantar flexion was seen in one case. Two of the patients had associated Neurofibromatosis. None had any other associated congenital anomalies. Area of pigmentation was noted in one case of Megafoot. Chromosomal studies performed demonstrated no abnormalities in any patient. None gave a family history of any such deformity. Clinical photographs and radiographs were taken in every case. In five cases de-fattening surgery was initially undertaken, but due to recurrence of the deformity, amputation of varying degree was required in all the cases. Inability to remove all the fibro-fatty tissues combined with subsequent regrowth was the main reason of failure. All the excised specimens were examined histologically. Table 1 shows the relevant details of all cases. Ultrasound (Gray scale and Doppler) examination of the digits revealed diffuse soft tissue thickening (Figure 1). No evidence of increased blood flow was found in the affected region in any of the cases.

RESULTS

We found that in our case study male to female ratio was 3:2 (12:8). The age group was 8-45 years with a mean of 25.3 years. Majority of the cases (50%) involved the lower extremity followed by upper limb with 13% of the cases (Table 1). It was confined to Megafoot- 5 cases since childhood. The skin was stretched, shiny, scaly dry and double the girth of opposite limb. Syndactyly of the 2 & 4th toe was present. Rudimentary toes with 1st & 5th toe variation was found. Unilateral Giant Lower Limb-5 cases (Figure 2), Giant Upper Limb- 3 Cases (Figure 3), Radial Mega Hand Mega Thumb-4 cases, Macroductyly of index finger was found in 3 cases. Neurofibromatosis was associated in two cases of giant lowerlimb (Figure 4). Syndactyly was found in

Table 1 Characteristics of patients in the study.

Case No.	Age (year)/sex	Location of anomaly	Digit involved	Syndactyly10	Nerve involvement	Associated conditions
1	45/male	Foot	All five toes	Present	No	None
2	8/male	Hand	Second and thumb	Absent	No	None
3	26/male	Lowerlimb	Whole limb	Absent	No	Neurofibromatosis
4	16/male	Foot	All five	Absent	No	None
5	8/female	Hand	Thumb	Absent	No	None
6	40/female	Upperlimb	All five	Absent	Yes	None
7	25/male	Lowerlimb	All five	Absent	No	Neurofibromatosis
8	21/male	Upperlimb	All five	Absent	Yes	None
9	12/female	Foot	All five	Absent	No	None
10	28/male	Foot	All five	Present	No	None
11	11/female	Hand	Thumb	Absent	No	None
12	29/male	Hand	Second	Absent	No	None
13	23/male	Hand	Thumb	Absent	No	None
14	16/female	Hand	Radial side	Absent	No	None
15	44/female	Upper limb	All five	Absent	No	None
16	22/male	Foot	All five	Absent	No	None
17	19/female	Lowerlimb	All five	Absent	No	None
18	35/female	Hand	Second	Absent	No	None
19	40/male	Lowerlimb	All five	Absent	No	None
20	38/male	Lowerlimb	All five	Absent	No	None

two cases of Megafoot. Radiographs demonstrated enlargement of both soft tissues and phalanges (Figure 5). Soft tissues at the volar surface were mostly involved. Mottled lucencies were noted in soft tissues in all five cases at the foot (Figure 1). Bone enlargement was restricted to the phalanges. Phalanges were longer and broader when compared with uninvolved phalanges of the same extremity (Figure 2).

Ultrasound (Gray scale and Doppler) examination of the digits revealed diffuse soft tissue thickening. No evidence of increased

blood flow or calcification was found in the affected region in any of the cases. Magnetic resonance imaging (MRI) scan showed fat tissue predominance and thickened condition of nerves and their sheaths. Computed tomography (CT) scans were used to detect proliferation of fat with bone overgrowth (Figure 6). Biopsy of the tissue showed abundant overgrowth of fibro-fatty tissue along with dense fibrous tissue (Figure 7). The hypertrophied adipose tissue with very large lobules of fat pervaded all surrounding tissues. An increase in bone-marrow fat was also seen. In few cases especially upper limb, nerves

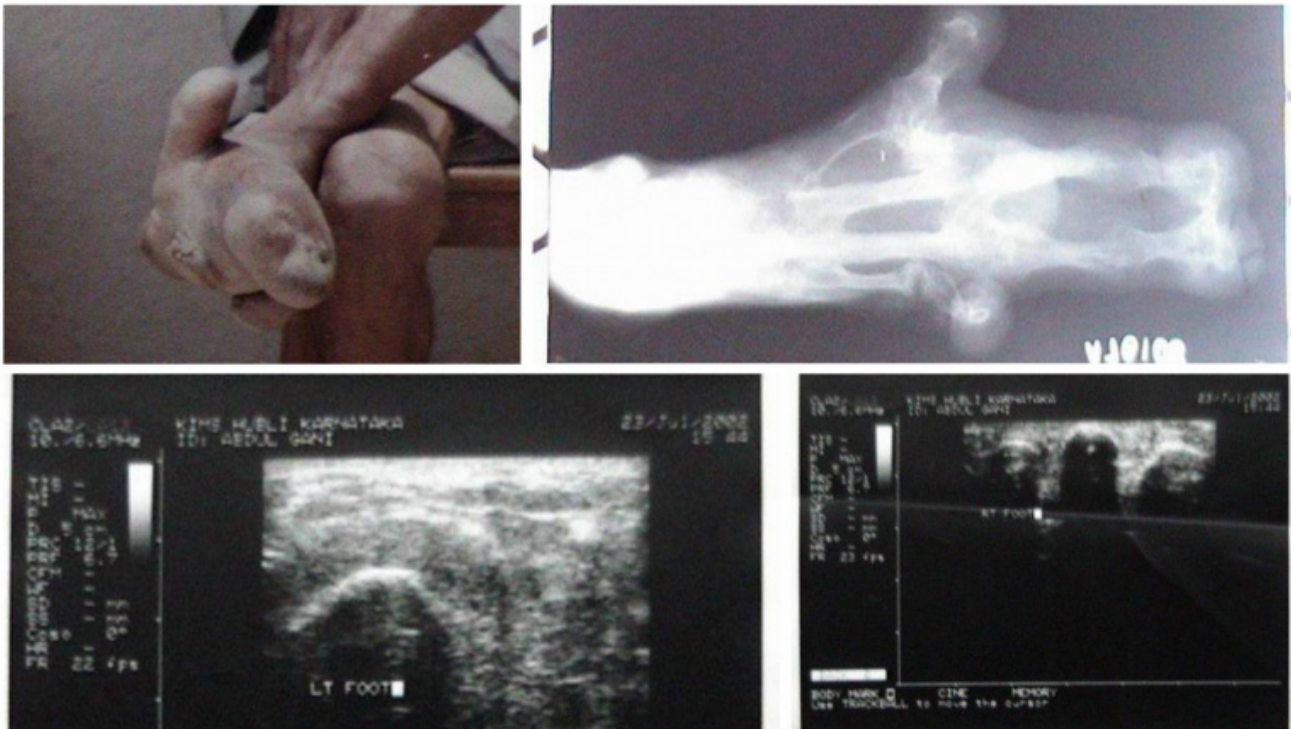

Figure 1 Mega foot of 45 year male patient with clinical Photograph, X-ray & Ultrasonography.

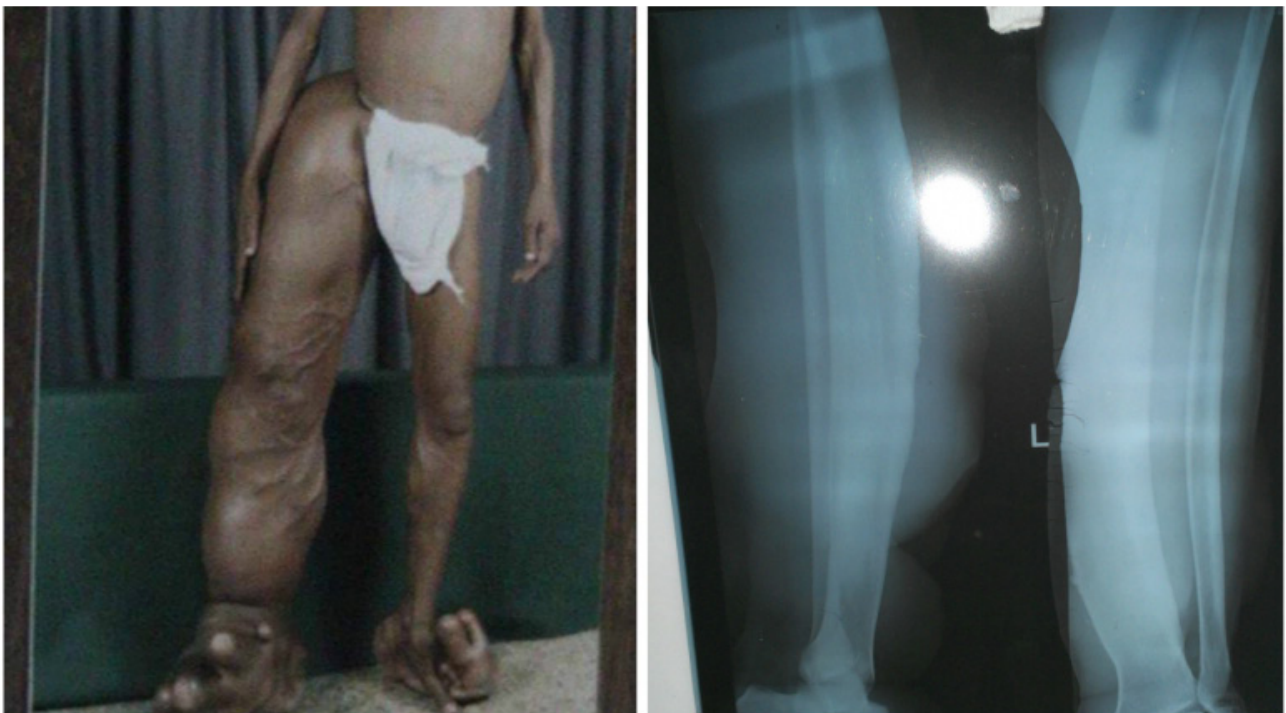

Figure 2 38 year male patient with Giant lowerlimb clinical photograph and X-ray.

were enlarged & thickened. There was excessive proliferation of epineural and perineural tissues; however, nerve fascicles were normal and neuromata were not seen. The skin showed dermal fibrosis and flattening of the rete-pegs. The indication for surgery was mainly cosmetic in cases of Macroductyly of the hand, whereas inability to wear shoes was the reason in Dactylomegaly of the foot.

DISCUSSION

In this study, we found that localized gigantism occurs primarily before the age of eight. Problems start to surface with the growth

of the child. Toddlers are reported to have difficulty in wearing shoes and to sustain repeated injuries, which may affect their daily activities, especially their learning development, social interaction, and self-confidence^[3].

The literature indicates a male preponderance. The male to female ratio in this series was 3:2. None of our patients had any family history of similar deformities. This is consistent with the previous literature, which states that heredity does not play a role^[4-7].

The etiology of the localized gigantism remains unclear. As the child grows there may be degenerative changes of small joints and compression of neurovascular structure. Few were associated with

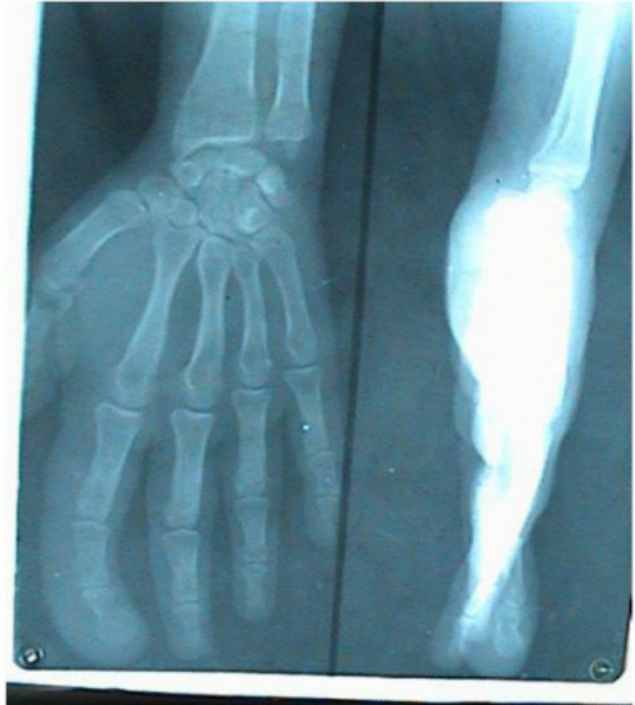
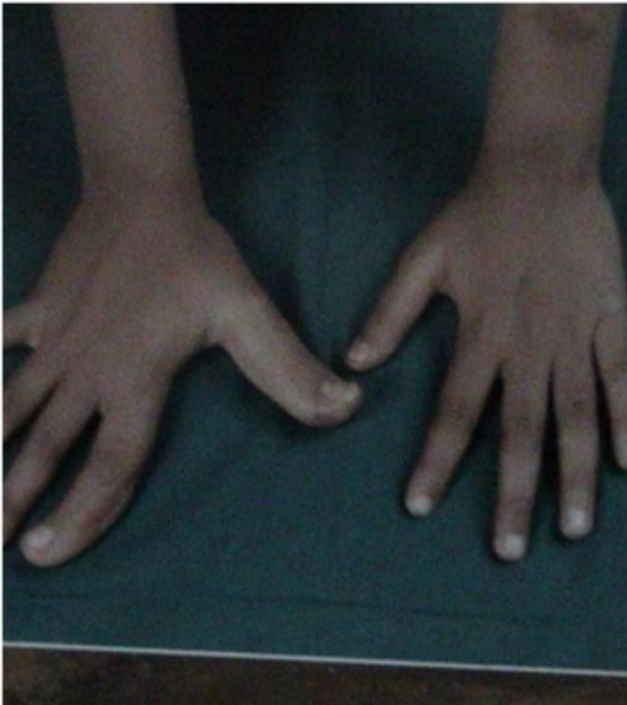
Figure 3 Radial Mega thumb and index finger of 8 year old female.

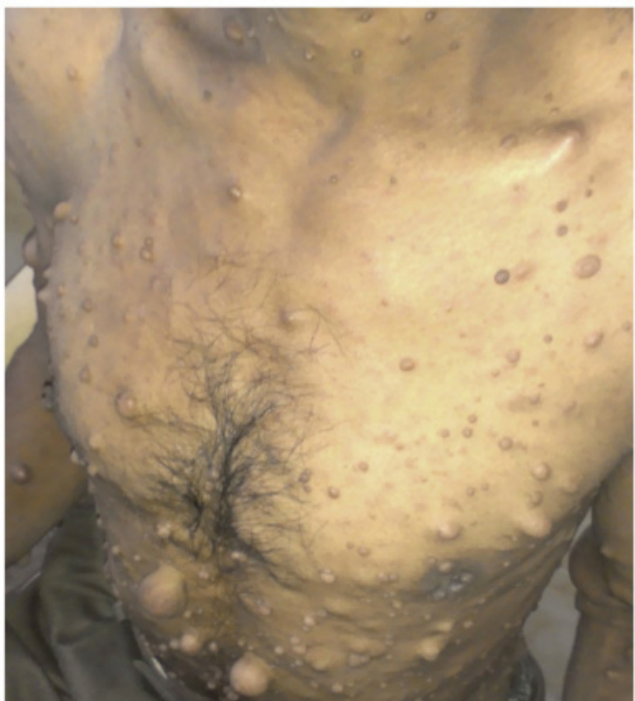

Figure 4 Associated Neurofibromatosis with giant lowerlimb in male patient.

congenital neurofibromatosis. Our histopathologic findings suggest that excessive proliferation and accumulation of fat is the basic lesion, whereas in macrodactyly of the hand involvement of nerves might be the fundamental lesion^[8]. In addition to our study, following careful review of the literature, we noted that the selectivity of the disease is such that only a single digit is affected, or when more than one digit is affected, usually these digits are adjacent. Furthermore, we observed overgrowth of the surrounding tissues even after ablative surgeries. Histopathologically cut sections are rich in adipose tissue sprinkled in a fine lattice like fibrous tissue as in our case series^[9].

The findings may be related to the theory that localized gigantism manifests according to the distribution of the Scelerotome^[10]-this is a group of mesenchymal cells that gives rise to the skeletal tissue of the body and develops into the vertebrae and ribs^[11]. As the little finger is rarely affected, it is also possible that the distribution is based on the median or plantar nerve innervations.

Plain radiographs demonstrate abnormalities in both the soft tissues and bony elements. The affected long bones, phalanges and metatarsal bones show an increase in width and length, and are often splayed at their distal ends, giving a mushroom like appearance. The

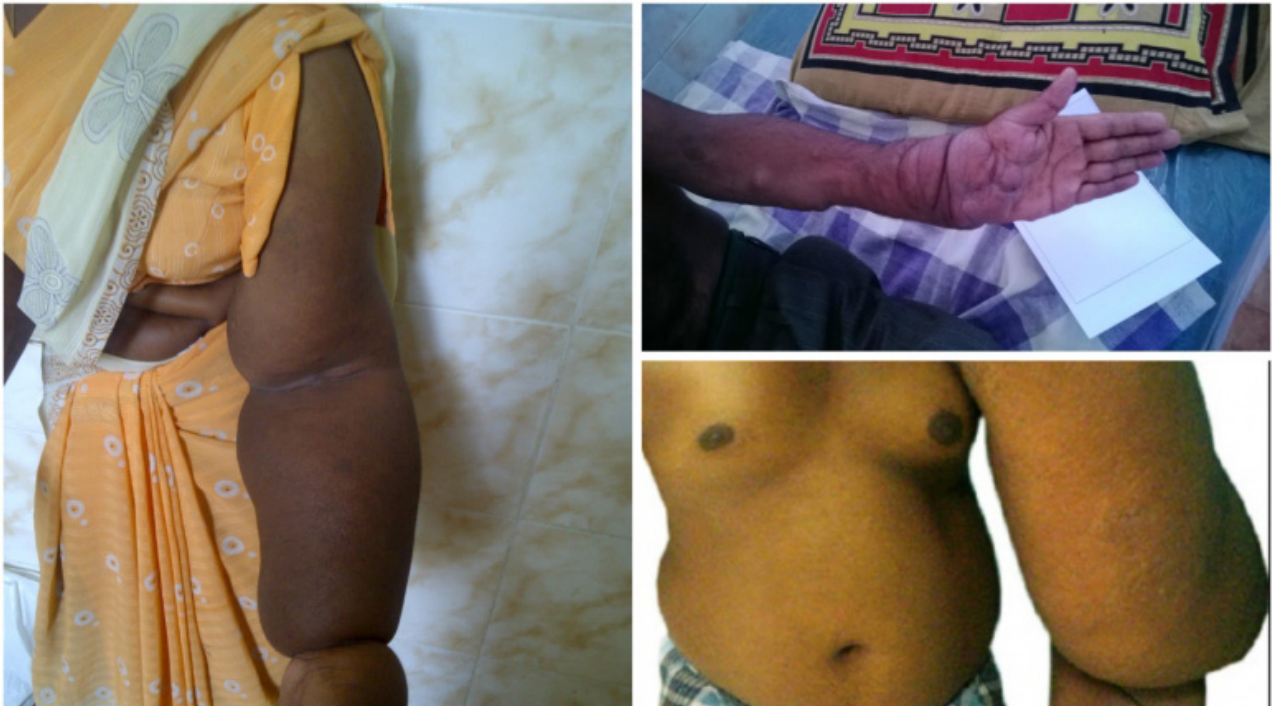

Figure 5 Giant upper limb- 3 cases.

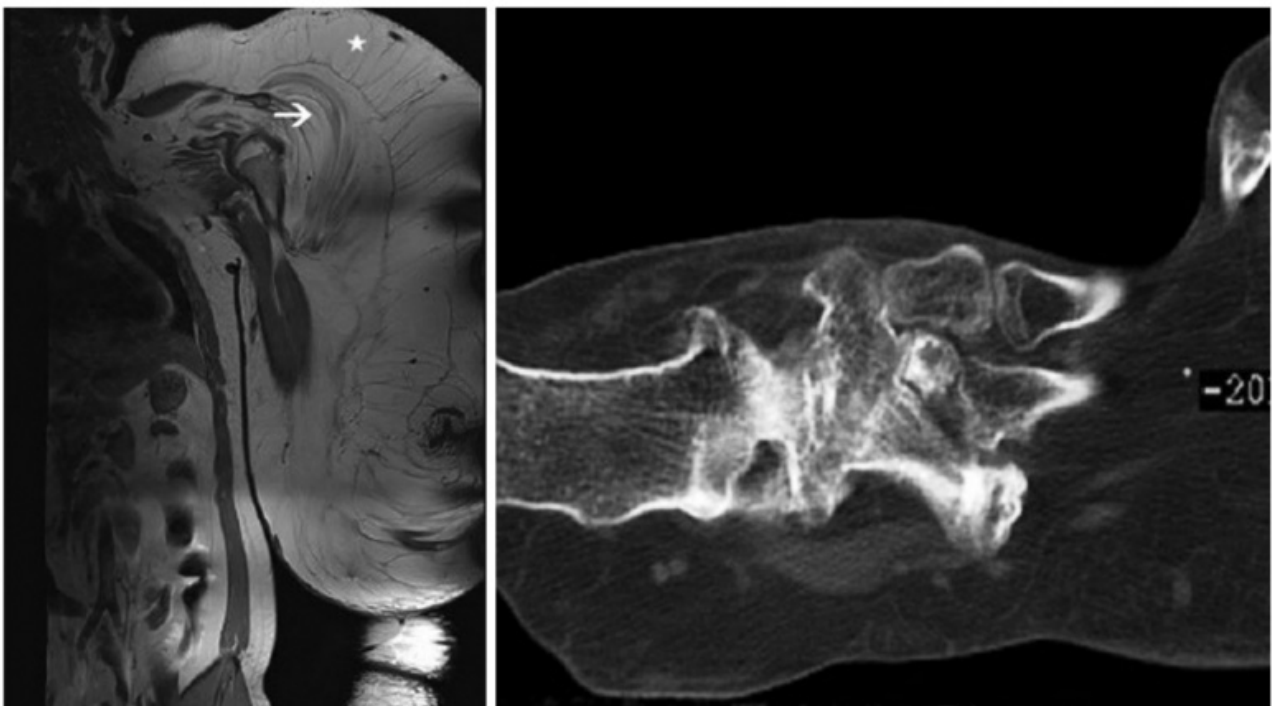


Figure 6 MRI and CT Scan images of localized gigantism- showing fat tissue predominance.

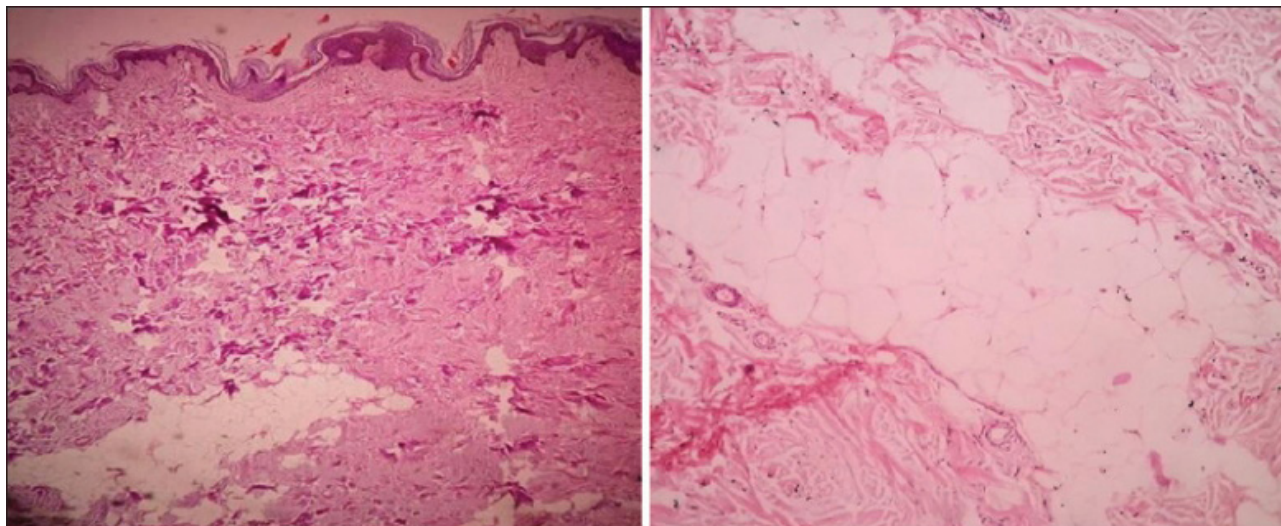


Figure 7 Histopathological Examination: Hypertrophied adipose tissue with very large lobules of fat pervaded all surrounding tissues.

articular surface may slant and in late childhood, severe secondary degenerative changes may affect the joints^[12]. Ultrasound can assess the soft tissue and changes in the nerve. These are better visualized on MRI. A CT is better to evaluate the changes in bone. The differential diagnosis of localized gigantism includes Macrodystrophia lipomatosa (MDL)^[13], Lymphangiomas, Hemangioma, Klippel-Trenaunay-Weber Syndrome, Neurofibromatosis, Proteus Syndrome, Fibrolipomatosis and idiopathic localized gigantism.

Surgical correction is the treatment of choice. The main surgical principle in treating this condition is to improve the cosmetic appearance and to preserve the neurological function as far as possible^[14]. Surgery is usually carried out after puberty when growth ceases. Cautious and planned use of multiple Debulking procedures, Epiphysiodesis, and various Osteotomies are recommended to achieve the best results. However, complications associated with overzealous debulking procedure lead to nerve injury with an incidence reported as high as 30-50%. A localized recurrence rate of 33-60% makes the management of localized gigantism more demanding^[14].

CONCLUSION

We conclude that it is a rare type of disease. Numerous etiologies of localized gigantism exist. While clinically the distinction may be difficult, radiological investigation is very useful in confirming the diagnosis. A proper clinical examination, plain radiograph and ultrasound can diagnose localized gigantism confidently, thus obviating the need for MRI, especially in a poor socio-economic set up. Amputation with prosthesis can be performed with satisfactory results if the gigantism is very huge and the patient is not ready for multiple Debulking surgeries. Considering the rarity of disease and in absence of any genetic involvement, no theory can be easily formed or dismissed.

DECLARATIONS

Ethical approval: The study was approved by institutional ethical committee.

REFERENCES

1. Sone M, Ehara S, Tamakwa Y, Nishida J, Honjoh S. Macrodystrophia lipomatosa: CT and MR findings. *mRadiat Med* 2000; **18(2)**: 129-132.
2. Mantadakis E, Deftereos S, Sivridis E, Michailidis L, Chatzimichael A, Prassopoulos P. Macroductyly of the right ring finger due to macrodystrophia lipomatosa: Pathologic and imaging characteristics. *International Journal of Case Reports and Images*. 2011; **2**: 6-10.
3. Kwon JH, Lim SY, Lim HS. Macrodystrophia lipomatosa. *Arch Plast Surg* 2013; **40**: 270-272.
4. Barsky AJ. Macroductyly. *J Bone Joint Surg* 1967; 49-A: 1255-1266
5. Goldman AB, Kaye JJ. Macrodystrophia lipomatosa: radiographic diagnosis. *AJR Am J Roentgenol* 1977; **128**: 101-105.
6. Tusge K. Treatment of macroductyly. *Plast Reconstr Surg* 1967; **41**: 232-239.
7. Feriz H. Macrodystrophia lipomatosa progressiva. *Virchow's Archiv fuer pathologische Anatomie und Physiologie und fuer klinische Medizin* 1925; **260**: 308-368.
8. Syed A, Sherwani R, Azam Q, Haque F, Akhter K. Congenital macroductyly: a clinical study. *Acta Orthop Belg*. 2005 Aug; **71(4)**: 399-404
9. Khan RA, Wahab S, Ahmed I, Chana RS. Macrodystrophia lipomatosa: 4 case reports. *Ital J Pediatr*. 2010; **36**: 69
10. Goldman AB, Kaye JJ. Macrodystrophia lipomatosa: radiographic diagnosis. *AJR Am J Roentgenol* 1977; **128**: 101-105.
11. Mosby I. Mosby's medical dictionary. St. Louis, MO: Mosby; 2009
12. Dhanasekaran J, Reddy AK, Sarawagi R, Lakshmanan PM. Imaging features of macrodystrophia lipomatosa: An unusual cause of a brawny arm. *BMJ Case Rep* 2014; 2014. pii: Bcr2014204899
13. Balakrishna BV, Prasad SRH. Macrodystrophia lipomatosa – A rare congenital disorder. *Indian J Radiol Imaging* 2005; **15**: 349-352
14. Tuli SM, Khanna NN, Sinha GP. Congenital macroductyly. *Br J Plast Surg* 1969; **22**: 237-243.

Peer reviewer: Peter Hui