

## Corrective Ulnar Osteotomy and Annular Ligament Reconstruction by Fascia Lata in Neglected Monteggia Fracture Dislocation in Children

Nguyen Ngoc Hung, Phung Cong Sang, Vu Tu Nam

Nguyen Ngoc Hung, MD, PhD, Associate Professor, Vietnam National Hospital for Pediatrics, 18/879 La Thanh Road – Dong Da District, Ha Noi, Viet Nam

Phung Cong Sang, MD, Vietnam National Hospital for Pediatrics, 18/879 La Thanh Road, Dong Da District, Ha Noi, Viet Nam

Vu Tu Nam, MD, Surgical Department, Hanoi Medical University, No 1. Ton That Tung Street, Dong Da District, Ha Noi, Viet Nam.

**Conflict-of-interest statement:** The author(s) declare(s) that there is no conflict of interest regarding the publication of this paper.

**Open-Access:** This article is an open-access article which was selected by an in-house editor and fully peer-reviewed by external reviewers. It is distributed in accordance with the Creative Commons Attribution Non Commercial (CC BY-NC 4.0) license, which permits others to distribute, remix, adapt, build upon this work non-commercially, and license their derivative works on different terms, provided the original work is properly cited and the use is non-commercial. See: <http://creativecommons.org/licenses/by-nc/4.0/>

**Correspondence to:** Nguyen Ngoc Hung, MD, PhD, Associate Professor, Viet Nam National Hospital For Pediatrics, 18 /, 879 La Thanh Road, Dong Da District, Ha Noi, Viet Nam.

Email: [ngocyenhung@gmail.com](mailto:ngocyenhung@gmail.com)

Telephone: +84-4-37841276

Received: July 28, 2017

Revised: August 17, 2017

Accepted: August 19 2017

Published online: August 28, 2017

### ABSTRACT

**BACKGROUND:** Neglected Monteggia fracture dislocation in children constitutes significant disability in respect to pain, stiffness, deformity, neurological compromise and restriction of activities of daily living. Many surgical technique have been described to manage neglected Monteggia fracture dislocation and common technique is the ulnar osteotomy for restoration of the ulnar length and reduction of the radial head with annular ligament reconstruction for restoration of the elbow biomechanics for this difficult problem.

**MATERIALS AND METHODS:** In a prospective study 13 patients with mean age of 7 years and 7 months, who presented with neglected Monteggia fracture dislocation, were studied. The time interval between injury and presentation mean 7.2 months and ranged from 2 months to 25 months. The patients were classified according to Bado. All children underwent open reduction of the radiocapitellar joint, Ulnar osteotomy with angulation distraction and annular ligament reconstruction by fascia lata. We used Kim's score the for evaluation of our results.

**RESULTS:** The mean follow-up period was 40.8 months. One of them without ulnar osteotomies healed uneventfully. Ulnar angulation at osteotomy site (°) mean 21.3° (16-25°); Ulnar lengthening at osteotomy site (cm) mean 0.85 cm (0.5-1.8 cm); Improvement Pre-Operation: Flexion-Extension 20.3%; Pronation 5,1%; Supination 13.7%; Total 13.7%. Surgical results: Excellent in 9; Good in 3; Fair in 1. Complication with nonunion in 1 case, Cubitus valgus in 2 cases; Subluxation in 1 case.

**CONCLUSION:** Late open reduction for chronically dislocated radial heads in children produces good to excellent results. Surgery for reduction should be attempted unless dysmorphism of the radial head restricts it. Open reduction with ulnar osteotomy with annular ligament reduction is the most commonly performed procedure and is expected to result in reduced pain and elbow deformity.statistically.

**Key words:** Missed monteggia fracture; Annular ligament reconstruction; Ulna osteotomy

© 2017 The Author(s). Published by ACT Publishing Group Ltd. All rights reserved.

Hung NN, Sang PC, Nam VT. Corrective Ulnar Osteotomy and Annular Ligament Reconstruction by Fascia Lata in Neglected Monteggia Fracture Dislocation in Children. *International Journal of Orthopaedics* 2017; **4(4)**: 802-810 Available from: URL: <http://www.ghrnet.org/index.php/ijo/article/view/2115>

### INTRODUCTION

Giovanni Battista Monteggia first described in 1814 the fracture dislocation now named after him. It represents a link between injuries of the forearm and the elbow. However, these injuries are

often missed at the time of initial trauma<sup>[1]</sup>. Missed or Neglected Monteggia fracture dislocation classically implies a duration of more than 4 weeks<sup>[2,3]</sup>. The patients also have significant disability in less severe injury with minimum angulations of ulnar fracture, where radial head dislocation may be missed. Bado reported an incidence of 1.7% in a cohort of 3,200 patients with forearm fractures<sup>[4]</sup>. Forearm fractures are common in children, accounting for about 20-30% of all fractures<sup>[5]</sup>. Not only are they less common, they are also one of the most frequently missed injuries, especially in children, where radial head dislocation may be associated with plastic deformation or green-stick fractures of the ulna. Monteggia fracture dislocation is a relatively rarer injury, accounting for about 1% of all pediatric forearm fractures<sup>[6,7]</sup>. About 25-50% of these injuries may be initially missed depending on the expertise and experience of the care provider<sup>[8]</sup>.

Radial head dislocation (RHD) is an uncommon injury in children. In most of the cases it is associated with an ulnar fracture or deformation as a part of the spectrum of Monteggia lesions. The classification of Bado remains the most commonly used for these types of injuries. It divides four types true Monteggia lesions and some “equivalent lesions” based on the direction of ulna angulation and radial head displacement<sup>[4]</sup>. Letts *et al* proposed a pediatric classification, subdividing the Bado type 1 based on the ulnar fracture pattern (plastic deformation, greenstick, and complete)<sup>[9]</sup>. Monteggia fractures in the pediatric population can result in excellent outcomes if recognized early and treated promptly. Restoration and maintaining the length and alignment of the ulna by closed reduction or surgery usually results in stable reduction of the radiocapitellar joint. However, missing or delayed recognition of RHD is the most common (16%-50%) and serious complication of pediatric Monteggia lesions, especially with plastic deformation of the ulna, resulting in a far more complex injury with often unpredictable surgical outcome. Unreduced dislocation of the radiocapitellar joint that is still present more than four weeks after the injury is considered chronic<sup>[10]</sup>.

Delayed recognition of a Monteggia fracture continues to pose a treatment challenge, as evidenced by the variety of surgical techniques that have been described. Procedures include ulnar and radial osteotomies, open or closed reduction of the radial head, repair or Annular Ligament Reconstruction (ALR)<sup>[11,12]</sup>, temporary fixation of the radial head with a transarticular wire, or some combination of these techniques<sup>[11,13]</sup>. Some have proposed leaving the radial head dislocated and excising it at skeletal maturity if pain or functional limitations are present<sup>[14]</sup>.

Long-term follow-up of untreated Monteggia fracture dislocations reveals development of premature arthritis, pain, instability, loss of pronation and supination, valgus deformity and a prominence on the anterior aspect of the elbow. Tardy nerve palsies have been reported subsequent to long-standing unrecognized Monteggia lesions<sup>[11,15]</sup>. Thus, it is imperative to treat the neglected fracture as soon as it is diagnosed. Fowles *et al* reported successful relocations up to 3 years after injury, Freedman *et al* performed reconstructive procedures up to six years after injury<sup>[13,16]</sup>.

In this report we present the clinical outcomes after treatment of neglected dislocated radial head in children by open reduction, angulating ulnar osteotomy and annular Ligament reconstruction by fascia lata.

## MATERIALS AND METHODS

A retrospective study was carried out to evaluate the results of surgical techniques performed from May 2010 and August 2015 in

13 patients of post traumatic symptomatic old Monteggia fracture–dislocation in the department of orthopaedics, National Hospital for Pediatrics. The operations were performed by single surgeon (Author). The study had the approval of the Ethical Review Committee of our Institute and was carried out in accordance with the tenets of the Declaration of Helsinki.

All children presented in a traumatic context with neglected RHD malunion of the ulna were involved in the study. None of the patients had a history of previous elbow pathology or surgery non patients had congenital dislocations, and none had been treated initially at our hospital.

The age of patients at the time of open reduction ranged from 6-12 years (average 7 years and 9 months). The gender of the cases was 8 girls and 5 boys; right side was affected 9 cases and left side in 4 cases. According to Bado classification indication (Table 1) 9 patients were of Bado type I, 3 patients were Bado type II, and 1 was of Bado type III. No patients with type IV reported.

The inclusion criteria included time interval between injury and surgical repair at least more than four weeks and this varied in our study between 2 - 25 months (average 12. 1 months). The exclusion criteria included gross distortion of the radial head. No posterior interosseous nerve palsy was detected preoperatively in any of the cases.

All patients had limited elbow and forearm motion and pain. No child presented with nerve palsy. On the preoperative radiographs, we noted the direction of dislocation, carrying angle, head–neck ratio and any abnormal bony architecture.

### Radiographic criteria

Any radiographic series for forearm fracture must include quality AP and lateral views of the elbow, which are necessary and usually sufficient to identify radiocapitellar incongruity. In the normal elbow, the central axis of the radius should pass through the center of the capitellum (Støren’s line). This holds true for all projections, and whether the radial head is ossified or not. The ulna should be scrutinized for plastic deformity or “bow sign”, with apex in the direction of radial head dislocation. The posterior ulnar cortex should be straight. Injury films should be followed with post reduction X-rays to confirm concentric reduction of the ulnohumeral and radiocapitellar joints.

**Table 1** Clinical data of the Patients.

Case	Gender	Side	Age at injury (Years, months)	Time to Operation (month)	Age at Operation (Years, months)	Follow - up period (month)
1	Female	Left	4. 7	25	7. 0	45
2	Male	Right	5. 8	7	6. 3	47
3	Female	Right	11. 2	6	11. 8	26
4	Female	Right	8. 3	9	9. 0	44
5	Female	Left	7. 1	4	7. 5	38
6	Male	Right	9. 8	5	10. 1	36
7	Male	Right	10. 6	3	10. 9	32
8	Female	Left	12. 5	2	12. 7	24
9	Male	Right	6. 4	8	7. 0	38
10	Female	Right	7. 9	5	8. 2	61
11	Female	Left	11. 8	6	12. 2	52
12	Male	Right	8. 4	4	8. 8	48
13	Female	Right	5. 4	9	6. 1	39
Mean			7. 7	7.2	8.6	40.8
			(4.7-12.5)	(2-25)	(6.1 - 12.2)	(24-61)

The status of the radial head reduction was evaluated. Radiographs (full length of the forearm) were obtained by placing the child's arm on the X-ray cassette with the elbow flexed 90° in the lateral position and the palm down (Figure 1). We have found that this method provides a true anterior-posterior image of the forearm, thus visualizing any bowing present in the ulna (Figure 2). It also allows visualization of the radial head dislocation by providing a true lateral image of the elbow.

They recommended that the maximum ulnar bow should be measured to detect ulnar bowing. For the measurement, a straight line is drawn on the lateral roentgenogram of the forearm along the dorsal border of the ulna from the level of the olecranon to the distal ulnar metaphysis. The presence or absence of ulnar bowing is determined by the maximal distance between this line and the ulnar shaft: a value of > 1 mm may signify the presence of ulnar bowing, while a value of < 1 mm indicates that the deformity does not significantly affect the rotation stability of the forearm<sup>[17]</sup>. (Figure 2).

### Clinical criteria

#### Range of motion (ROM) measurement

Preoperative and postoperative ROM, expressed as the sum of the flexion-extension arc and pronation-supination arc, was determined with a hand-held goniometer using standard methods. We defined a full flexion-extension arc as 140°, a full pronation arc as 75°, and a full supination arc as 85°<sup>[18]</sup>.

#### Elbow performance score

We adopted new criteria after the study was already underway when it was determined that the patients' satisfaction was not limited to any single factor. For example, deformity was so sensitive a factor for patients and parents in this study that it acted as the entire reason to have surgical correction in some patients. Postoperative satisfaction was also variable. Thus, the currently used scoring system of the elbow could not reflect the pre and postoperative evaluation of the neglected RHD precisely.

### Surgical Technique

The surgery was performed with the patient lying in the prone position with the elbow flexed. Under general anaesthesia and tourniquet applied on the upper arm, a postero-lateral skin incision was made to expose the radio-capitellar joint and the malunited site of the ulna through Speed and Boyd approach<sup>[19]</sup> which exposes the lateral surface of the ulna and the proximal fourth of the radius. The substance of the reflected supinator protects the deep branch of the radial nerve. After identification of the joint capsule, the annular ligament, which may be intact but displaced or ruptured and obstructed the radial head reduction, was located. Then, the intraarticular spaces of the radiocapitellar and the proximal radioulnar joints were cleared of debris by removing any fragments of interposed capsule, ligament, or osteochondral tissue. Reduction of the radial head into radial notch of proximal ulna was attempted, and its stability was assessed if the proximal radius is still unstable, maintain reduction with temporary oblique pin from the radius to the proximal ulna. In all patients stability could not be achieved and an ulnar osteotomy was performed of the ulna to ensure stability of the radial head. The proximal part of the ulna, i.e., the site of malunion or plastic deformity, is exposed through the standard dorsal approach. A straight osteotomy is made at the metaphyseal–diaphyseal junction. The osteotomy site is then angulated and lengthened simultaneously. The osteotomy is then fixed with a one-third tubular plate that has been bent to match the induced deformity (the plate was bent to 30°).

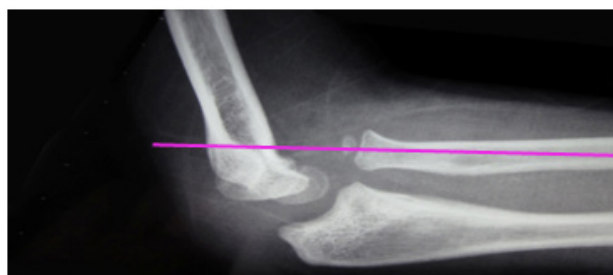

Figure 1 Head radial dislocation.

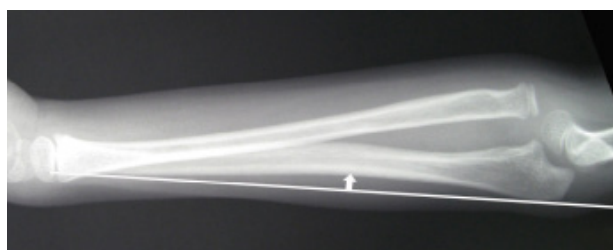

Figure 2 Ulnar bow should be measured to detect ulnar bowing.

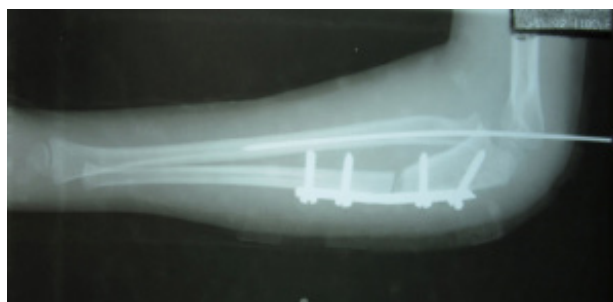


Figure 3 The osteotomy site is angulated and lengthened simultaneously. The osteotomy is then fixed with a one-third tubular plate.

The most proximal screw is cancellous and this simple construct combined with 4 weeks of casting was entirely sufficient (Figure 3).

#### Annular ligament Reconstruction

The bone tunnels were created using a 3.5-mm drill at the level of annular ligament (Figure 4). A strip of fascia lata with width of 1 cm and length of 6–8 cm was obtained from distal one third thigh is passed and wrapping it around the radial neck from the ulnar and securing it through a drill hole in the ulna (Figure 5).

A Kirschner wire was drilled percutaneously through the capitellum into the radial head with the elbow in 90 degrees of flexion and supination (Figure 3). The patients the ulna was fixed with a plate and screws. It was not necessary to perform radial osteotomy, temporary transarticular radio-capitellar wire stabilization.

Wound was closed in layers over a drain and immobilized for 6 weeks in a plaster cast at 90° flexion in supination. We fixed the radius with a transcapitular K wire in all cases, and the wire were removed after 2 weeks. Post-operative 6 weeks, removed plaster cast and we encouraged gentle active movement of the elbow. The patients were followed up at 3, 6, 12 months and then on yearly basis.

A new scoring system was subsequently based on the four parameters that the patients most considered as problems that needed to be solved: deformity, pain, ROM, and function. The four parameters were weighted equally, 25 points each, for a perfect score of 100 points: (1) deformity: 25, no concern; 15, minor concern; 0, major concern; (2) pain: 25, no pain; 15, intermittent mild pain but

not limiting activities; 0, pain, limiting activities; (3) range of motion (sum of the flexion-extension and pronation-supination arcs): 25, > 250°; 15, 250°-200°; 0, < 200°; (4) function: five activities of daily living (comb hair, feed self, open doorknob, hold on to subway overhead rail, put on shoes with hands) were identified and were given a weight of 5 points each if the patient could perform such tasks without a problem. If the patient could not accomplish these tasks, a zero was given for each task he or she failed to perform without difficulty. Total elbow performance score was graded as excellent (90 or more points), good (89-75 points); fair (74-60 points); or poor (< 60 points)<sup>[20]</sup>.

**Statistical analysis**

The data were analysed with Epi Info 6.04 software public domain statistical software for epidemiology, de-veloped by Centers for Disease Control and Prevention (CDC) in Atlanta, Georgia, USA, <http://wwwn.cdc.gov/epiinfo/html/prevVersion.htm>. We performed the  $\chi^2$  test for percentage and the t-student test for mean comparison between the preoperative and postoperative groups. P-values  $\leq 0.05$  were regarded as statistically significant. All readings were provided as average values together with the appropriate standard deviation.

**RESULTS**

In this study all cases had regular thorough follow up for a period mean 40.8 months (24-61 months) (Table 1). All patients were operative ulnar osteotomy with angulation at osteotomy site mean 21.3°; Ulnar lengthening at osteotomy site mean 0.86. cm (Table 2). All wounds healed primarily with no infection. There were no neurovascular complications, compartment syndrome, or implant breakage. One patient who underwent a diaphyseal osteotomy at the center of rotation of angulation developed a nonunion (Patient number 3), requiring bone grafting with auto bone graft, 6 months

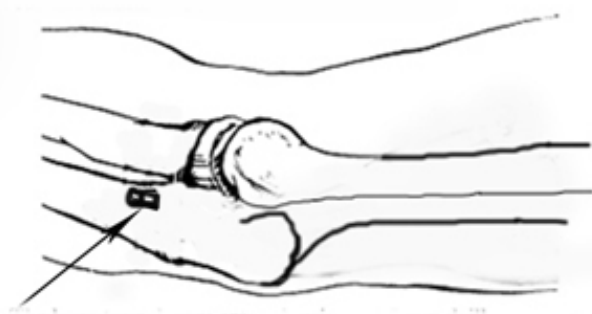


Figure 4 The bone tunnel were created a 3.5 mm drill.

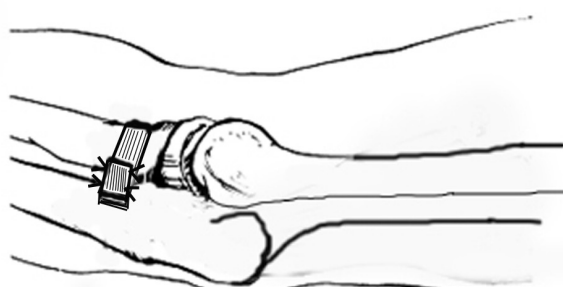

Figure 5 The fascia lata is passed and wrapping it around the radial neck from the ulnar and securing it through a drill hole in the ulna.

postoperatively with rapid consolidation.

The age of patients at the time of open reduction ranged from 6, 1-12, 7 years (average 7 years and 10 months). The gender of the cases was 8 girls and 5 boys; right side was affected 9 cases and left side in 4 cases.

At follow-up: Elbow, wrist and forearm motion was without pain, with mean elbow flexion- extension 127.7° (SD = 5.63). Mean forearm pronation was 71.2° (SD = 4.63), and all patients had supination of 79.6° (SD = 6.72) (Table 3). There was no sign of distal radio-ulnar joint instability. Radiographs at the latest review showed that the radial head was successfully reduced in all cases. In addition, no patient had any degenerative changes in the elbow joint.

**Clinical results**

The mean preoperative range of flexion-extension motion was 106.2°, and the mean postoperative range of motion was 127.7°, so the the improvement 20.3%. All patients had a supination-pronation arc of >100°; the range of pronation was always less than that of supination. The mean preoperative supination-pronation arc was 137.7°, and the mean postoperative supination-pronation arc was 150.8°, so the the improvement 9.51%. (Table 3). Although no correlation was noted between the range of movements achieved and the duration of treatment, patients treated earlier had a greater range of movements than those treated later (Table 4). The mean follow-up was 40.8 months (range 21-61 months). At the final follow-up, no patient had any sign of instability. Based on Kim’s scores<sup>[20]</sup> there were nine patients with excellent and three patients with good, and one patients with fair results at the final follow up. (Table 2)

**Radiological results**

The initial pre-operative radiographs showed nine patients of Bado type I fractures, three of Bado type II and one of the Bado type III (Table 2). There three patients were showed ulnar plastic deformy, they measured with a value of < 1 mm in this study (Figure 2).

At the final follow-up, the radiocapitellar line showed subluxation of radial head by radiocapitellar line which did not require any treatment. The mean healing time of ulnar osteotomy for 12 of them (92.3%) were 9 weeks (range 7-12 weeks). One child with ununion and postoperative 5 months, he had been operated bone grafting.

Table 2 Management of Technique and Outcome.

Case	Bodo type	Plastic deformation of the ulna	Ulnar angulation at osteotomy site (°)	Ulnar lengthening at osteotomy site (cm)	Complication	Kim’s Score
1	I	(-)	20	0.6	None	Excellent
2	I	(-)	19	0.7	None	Excellent
3	I	(+)	22	1.2	Nonunion	Fair
4	II	(-)	20	1	None	Excellent
5	I	(-)	20	0.7	Cubitus valgus	Good
6	I	(-)	25	1.2	None	Excellent
7	II	(+)	20	0.6	None	Excellent
8	I	(-)	23	0.6	None	Excellent
9	I	(-)	21	1.2	None	Excellent
10	II	(-)	20	1.1	Cubitus valgus	Good
11	III	(+)	19	0.6	None	Excellent
12	I	(-)	22	1.1	None	Excellent
13	I	(-)	26	0.5	Subluxation	Good
Mean			21.3°	0.85 cm		

**Complications**

There was residual subluxation of the radial head anteriorly in one patient (7.7%) (case 13), Cubitus valgus in two patients (15.4%) (case 5 and 10), nonunion in one patient (case 3). There were no cases of growth disturbance, heterotopic bone formation or radioulnar synostosis, arthritis, pain, stiffness deformity, neurological compromise and restriction of activities of daily living, elbow instability, secondary degenerative arthritis, late neuropathy, radial head overgrowth, tardy nerve palsies and potential degenerative arthritis, avascular necrosis of the radial head, infection, and a prominence on the anterior aspect of the elbow.

**DISCUSSION**

Radial head dislocation may occur in many different conditions, such as neuromuscular disorders; after trauma, with or without a fracture of the ulna; secondary to tumors of the forearm; or congenital, as seen with associated syndromes and diseases. Good and Wicks<sup>[21]</sup> suggested that RHDs can be divided into three types: congenital (when present from birth), developmental (because of abnormalities in growth period), and post-traumatic. Other authors have suggested

that RHD always follow trauma, with possible plastic deformation of the ulna, also called ‘traumatic ulnar bowing’<sup>[17,22]</sup>. Many of these so-called congenital dislocations may actually represent birth trauma leading to congenital dislocation of the radial head. True congenital RHD frequently shows a bilateral involvement, familial tendency, and associated dysplasia of the radial head and capitulum<sup>[23]</sup>.

This study agrees with others in that longstanding posttraumatic RHD causes dysplastic changes in not only the proximal radioulnar joint but the distal humerus as well<sup>[12,24]</sup>. The anatomic relationship between all three components of the elbow joint (ulnohumeral, radiocapitellar, and proximal radioulnar joint) must be maintained, especially in the skeletally immature patient, if normal development is to occur. The problems associated with neglected radio – ulnar dislocation after a Monteggia fracture – dislocation includes loss of forearm rotation, cubitus valgus, elbow instability, pain, degenerative arthritis, subluxation of the distal radioulnar joint and late neuropathy<sup>[12,25]</sup>.

Many authors have stated that a reconstructive procedure should be undertaken within 2 years of the initial injury<sup>[12,26]</sup>, thus implying that after 2 years the results are so poor that no surgical intervention is warranted. Best<sup>[27]</sup> reported a successful result in a child 6 years

**Table 3** Range of motion measurements (in degree).

Case	Preoperative				At follow - up			
	Flex-Ext arc	Pronation arc	Supination arc	Total arc	Flex-Ext arc	Pronation arc	Supination arc	Total arc
1	110	70	70	250	130	70	85	285
2	115	65	70	250	130	70	85	285
3	80	75	80	235	125	75	75	275
4	120	75	75	270	130	75	80	285
5	110	65	75	250	125	75	80	280
6	130	70	80	280	135	70	85	290
7	90	50	55	195	120	60	65	245
8	105	70	60	235	125	75	80	265
9	95	75	70	240	140	70	85	295
10	110	75	80	265	130	75	85	290
11	105	65	40	210	125	70	70	265
12	100	55	75	230	120	65	80	265
13	110	70	80	260	125	75	80	280
Mean	106.15	67.69	70	243.8	127.7	71.2	79.6	277.3
SD	12.93	7.8	11.9	23.64	5.63	4.63	6.72	13.93
Improvement					20.30%	5.10%	13.70%	13.70%
Pvalue					0.000	0.001	0,00001	0.000

% Improvement: [(B-A)/A] X 100 (A: Preoperative mean ROM in each arc; B: at follow - up in each arc), Improvement Pre-Postoperation: Flexion-Extension 20.3% - with *p* < 0.00001; Pronation 5,1% with *p*= 0.001267; Supination 13.7% - with *p* < 0.00001; Total 13.7% with *p* < 0.00001.

**Table 4** Elbow performance score

Case	Preoperative					At follow - up				
	Deformity	Pain	Motion	Function	Total	Deformity	Pain	Motion	Function	Total
1	25	15	15	20	85	25	25	25	25	100
2	15	25	15	15	70	25	25	25	25	100
3	15	15	15	10	50	15	15	25	15	70
4	25	25	25	20	90	25	25	25	25	100
5	25	15	15	15	60	15	25	25	15	80
6	25	25	25	20	95	25	25	25	25	100
7	25	25	0	20	70	25	15	15	25	90
8	25	15	15	25	80	25	25	25	25	100
9	25	15	15	20	75	25	25	25	25	100
10	25	15	25	25	70	15	25	25	20	85
11	15	25	15	20	75	25	25	25	25	100
12	25	15	15	20	75	25	25	25	25	100
13	15	15	25	20	85	15	25	25	20	85
Mean	21.92	18.84	16.92	19.23	75.38	21.92	23.46	24.23	22.69	93.07
SD	4.8	5.06	6.93	4	12.15	4.8	3.75	2.77	3.88	10.11
Improvement						0	24.50%	43.20%	18.00%	23.46%
Pvalue						0.000	0.000	0.000	0.000	0,00001

% Improvement + [(B-A)/A] X 100 (A: Preoperative mean ROM in each arc; B: at follow - up in each arc). Total elbow score: Excellent. ≥ 90; Good, 89-75; Fair, 74-60; Poor ≤ 60. Surgical results: Excellent. 9; Good 3; Fair 1. Elbow performance score in Preoperation and at follow - up with PValue 0.319626

after injury. In our series the average time from injury to surgery was 37 months, and one patient had their reconstruction 10 years after injury with recovery of near full range of motion. Seven of our patients were more than 2 years out from their initial injury at the time of reconstruction. We do not feel that there is a time window in which to do the Bell–Tawse reconstruction, and we will offer surgical intervention to any patient that we feel will benefit from such<sup>[27]</sup>. Time initial injury to operative within 7.2 months (2-25 months) in this study.

Another important point with respect to achieving a good functional outcome is the maximum age of the patient undergoing potential bone remodelling. Three of the patients reported here were over 10 years at the time of surgery, with the oldest being 12 years of age<sup>[16]</sup>. Owing to the potential complications of conservative methods in cases of neglected Monteggia injuries, it is important that the radial head be replaced in appropriate relation to the capitellum. This is especially true in children who are less than 12 years of age. Patient’s age at Operation mean 8.6 years (6.1 - 12.2 years) in this study.

**Ulnar Osteotomy**

We agree author’s opinion that “ ulnar osteotomy is the key for radial head reduction ”<sup>[20]</sup>. The treatment we propose has been previously described and is based upon the hypothesis that the primary problem is malunion of the ulna preventing reduction of the radial head. Consequently, the surgical technique consists of an ulnar osteotomy with lengthening and angulation. Lengthening permits reduction, providing sufficient place for the dysplastic head while avoiding excessive pressure on the radial head. The angulation creates an overcorrection, which firmly maintains the head in place for the time necessary for its stabilization.

Ulnar osteotomy is the key procedure in achieving and maintaining reduction as it addresses the primary deformity in the ulna<sup>[28]</sup>. Decreased length of the ulna and the angulation of the ulna in the direction opposite to the dislocation of the radial head are the most important findings leading to persistence of RHD<sup>[29]</sup>. The distance of ulnar osteotomy from the olecranon should be just enough to allow fixation of the ulna following osteotomy<sup>[30]</sup>.

Different types of ulnar osteotomies have been used in the literature. Hirayama *et al*<sup>[31]</sup> recommended a lengthening ulnar osteotomy with overcorrection of the ulnar deformity. Inoue *et al*<sup>[28]</sup> compared the results of simple and over-correction osteotomy of the ulna and found that the results were significantly better with overcorrection osteotomy. This was because of inadequate correction of ulnar deformity in patients with simple osteotomy, resulting in residual subluxation. The mean arc of forearm rotation was also higher in the group treated with overcorrection osteotomy. Overcorrection of ulnar osteotomy has also been recommended by other authors<sup>[22,32,33,34]</sup> and may also help by eliminating the mechanical block to radial rotation from callus or fibrous tissue.

**Annular Ligament Reconstruction**

Controversy exists regarding reconstruction of the annular ligament. Nakamura *et al*<sup>[34]</sup> and David-West *et al*<sup>[35]</sup> advocate it in all cases while others like Devnani<sup>[2]</sup> disregard it completely. Others like Bhaskar *et al*<sup>[3]</sup> prefer an intra-operative decision based on the stability of reduction.

It seems of no value to reconstruct or repair a ligament around a neck altered by a dysplastic head, since the latter will be progressively remodelled after reduction leading to an attenuation of the graft and predisposing to subsequent re-dislocation. On the other

**Table 5** Compared postoperative results only UO and UO combined ALR with the same Kim’s scores<sup>[20]</sup>.

Author(s)	Patient (number)	Age at surgery (mean, Y, months)	Time from injury to surgery (mean, Y, months)	Procedure	Follow-up (mean, Year. months)
Ulnar Osteotomy, without Annular ligament reconstruction					
Chauhan. 2017 [46]	6	6.5	1.2	UO	3
Park 2017 [47]	22	0.6	0.7	UO	2.4
Läderman 2007 [48]	6	6.5	1.5	UO	3
Ulnar Osteotomy, with Annular ligament reconstruction					
Hui 2005 [49]	15	8.3	0.3	UO, ALR	4.3
Mohamed 2013 [50]	12	7.9	0.1	OU, ALR	1.1
Lu 2017[51]	23	6	0.7	UO (18 of them), Repositioned the annular ligament (20 of them)	1.6
Bhaskar 2009[3]	12	7.4	0.9	UO, ALR (5 of them); UO (7 of them)	1.1
Hung 2017	13	7.7	0.7	UO, ALR	3.4

There were 3 studies only Ulnar Osteotomy and 5 studies were combined Ulnar Osteotomy and Annular ligament reconstruction.

**Table 5** Compared postoperative results only UO and UO combined ALR the same Kim’s scores [20] (continuous).

Authors	Results				Complications			
	Excellent	Good	Fair	Poor	Subluxation	Nonunion	Cubitus valgus	Infection
Ulnar Osteotomy, without Annular ligament reconstruction								
Chauhan. 2017 [46]	6				1	1		
Park. 2017[47]		21		1		1	2	
Läderman2007 [48]	6				1	1		
Ulnar Osteotomy, with Annular ligament reconstruction								
Hui. 2005[49]	11	3		1	1	1		
Mohamed 2013 [50]	8	4						2
Lu. 2017[51]	23							5
Bhaskar. 2009 [3]	10	2			1			1
Hung. 2017	9	3	1		1	1	2	

Postoperative Surgical only Ulnar Osteotomy with accepted result 97.1% and Ulnar osteotomy combined Ulnar ligament reconstruction was 97.4%,  $p > 0.05$ , so considered without statistically significant. Complications in Ulnar Osteotomy was 20.6%, in Ulnar osteotomy combined Ulnar ligament reconstruction was 20.0% with  $p = 0.943488$ , so considered without statistically significant.

hand, a short graft results in a tight constriction of the radial neck and functional limitation, as demonstrated by the postoperative thinning of the neck previously reported after the Bell Tawse procedure<sup>[36]</sup>. While lamination of the neck by the annular ligament temporarily maintains the head in place, it does not seem to us physiological. If re-dislocation occurs we are of the opinion that it not related to the absence of annular ligament reconstruction, but rather to a lack of angulation of the ulnar osteotomy. In our study one patient underwent arthrography at 1 month post-operatively for suspicion of subluxation that was in fact due to a radial head deformity. Such a pseudosubluxation has been previously described<sup>[22]</sup>.

Another point that is often raised is the choice of surgical technique used in the treatment of these lesions. Controversy exists regarding reconstruction of the annular ligament. Nakamura *et al*<sup>[34]</sup>, and David-West *et al*<sup>[35]</sup>, advocate it in all cases while others like Devnani<sup>[2]</sup>, and Bhojraj *et al*<sup>[36]</sup> disregard it completely. Others like Bhaskar *et al*<sup>[3]</sup>, prefer an intra-operative decision based on the stability of reduction. Garg *et al*<sup>[37]</sup> reported better results with annular ligament reconstruction using Palmaris longus graft. Freedman *et al* used a technique in which the annular ligament was not reconstructed but the radial notch was deepened to achieve stability<sup>[38]</sup>.

Several resources have been used for the reconstruction of the annular ligament: grafts from the fascial strips of the forearm<sup>[9,39]</sup>, fascia lata<sup>[37,40]</sup>, tendon of palmaris longus<sup>[12]</sup>, triceps tendon<sup>[31,37]</sup>, and extensor aponeurosis<sup>[12]</sup> as well as nylon thread<sup>[39]</sup>. However, each of these tissues has its own drawbacks. The forearm fascia and tendon of the palmaris longus are too weak to restrict the radius. Further, an additional incision is required for harvesting the fascia lata. Non-absorbable artificial suture materials, such as nylon, are unyielding and cannot accommodate the continued radial growth, thereby possibly leading to the narrowing of the radial neck. Bell Tawse and Lloyd-Roberts *et al* have reported good outcomes with the use of the slip of the triceps fascia<sup>[12,41]</sup>; therefore, we used the same material and similarly obtained good results.

Tanet *et al*<sup>[42]</sup> studied the intraoperative findings in 35 pediatric patients with acute Monteggia fractures. They found that the annular ligaments were not ruptured, but detached from the capsular ligament and retracted into the radiocapitellar joint. Thus, even in those patients who seemingly achieved a congruent reduction radio-graphically, the annular ligament was found entrapped in the radiocapitellar joint. As the annular ligament in children was very thin (2-3 mm), reduction and normal range of movements were possible even with the annular ligament in the joint. Thus, successful reduction is possible even in the absence of a functional annular ligament.

#### Bone grafting of osteotomy site

The need for a bone graft can be assessed on the basis of the gap at the osteotomy site and larger gaps should be bone grafted. Wang and Chang<sup>[43]</sup> recommended that gaps of more than 2 mm should be covered with a primary bone graft. Bhaskar<sup>[3]</sup> used bone graft for gaps more than 10mm. The use of a bone graft was mentioned in five studies in this review<sup>[34]</sup>. Bor *et al*<sup>[44]</sup> presented the results for patients in whom Ilizarov's frame was used for correction. After a mean of 4.5 months in the frame, all radial heads were well reduced. The mean lengthening of the ulna achieved was 2 cm, with no need for bone grafting or open reduction of the radial head.

Ray R and Gaston M<sup>[45]</sup> show one patient had a nonunion at the osteotomy site. This was attributed to the mid-diaphyseal position of the osteotomy and the distraction caused by lengthening of the ulna. In this study, one patient had anouion at the osteotomy site, with gap was 12 mm. Postoperative 5 months, he had been operated bone

grafting.

#### Complications

The additional dissection required to reconstruct the annular ligament might result in elbow stiffness, avascular necrosis of the radial head, heterotopic ossification, or radio-ulnar synostosis.

**Residual subluxation** was the most common complication at follow-up<sup>[27,37]</sup>. Overall, surgery was associated with improved range of motion in the majority of the studies<sup>[30,42]</sup>. ALR has been found to be associated with poorer range of movement at follow-up<sup>[3,10,20]</sup>. Considerable loss of range of motion was observed at follow-up in both flexion-extension and supination-pronation planes. Loss of pronation was the most commonly observed effect of late reconstruction on range of motion. In the series of Kim *et al*<sup>[20]</sup>, it was observed in 11 out of 15 patients. There were two patients with subluxation of radial head in this study.

**Radioulnar synostosis** may be an important complication of open reduction of the radial head. Synostosis was observed in one patient in the series by Oner and Diepstraten<sup>[46]</sup>, although no ulnar osteotomy was carried out. Dissection during open reduction of the radial head appears to be a greater risk factor for proximal synostosis.

There is a risk to the posterior interosseous nerve at the time of injury or the surgery. In some studies, transient radial nerve palsy was observed preoperatively, which improved gradually<sup>[30,39,43]</sup>. There is also a risk of ulnar nerve damage in cases with progressive valgus deformity of the elbow.

## CONCLUSIONS

Late open reduction for chronically dislocated radial heads in children produces good to excellent results. Surgery for reduction should be attempted unless dysmorphism of the radial head restricts it. Open reduction with ulnar osteotomy with ALR is the most commonly performed procedure and is expected to result in reduced pain and elbow deformity. Statistically, the degree of preoperative carrying angle asymmetry associated with flexion contracture correlated significantly with the elbow scores at follow-up. Indications for surgery must be individualized. The decision to perform surgery must be made by the patient, parents, and surgeon, taking into consideration preoperative expectations, potential complications, and postoperative rehabilitation.

Limitations of this study include the small cohort of patients and the number of Neglected Monteggia Fracture Dislocation was too small to perform parametric statistical analysis. Second, this is an interim outcome report as most patients were not followed-up until skeletal maturity. Third, the subjects of this study were not homogenous in terms of the implants used.

## REFERENCES

1. Rehim SA, Maynard MA, Sebastin SJ, and Chung KC. Monteggia fracture-dislocations: A Historical Review. *J Hand Surg Am.* 2014; **39(7)**: 1384-1394.
2. Devnani AS. Missed Monteggia fracture dislocation in children. *Injury.* 1997; **28**: 131-133. [PMID: 9205580]
3. Bhaskar A. Missed Monteggia fracture in children: Is annular ligament reconstruction always required? *Indian J Orthop.* 2009; **43**: 389-95. [PMCID: PMC2762552]
4. Bado JL. The Monteggia lesion. *Clin Orthop.* 1967; **50**: 71-86. [PMID: 6029027]
5. Noonan KJ, Price CT. Forearm and distal radius fractures in children. *J Am Acad Orthop Surg* 1998; **6**: 146-156. [PMID: 9689186]

6. Kay RM, Skaggs DL. The pediatric Monteggia fracture. *Am J Orthop (Belle Mead NJ)* 1998; **27**: 606-609.
7. Ring D, Jupiter JB, Waters PM. Monteggia fractures in children and adults. *J Am Acad Orthop Surg* 1998; **6**: 215-224. [PMID: 9682084]
8. Gleeson AP, Beattie TF. Monteggia fracture-dislocation in children. *J Accid Emerg Med* 1994; **11**: 192-194. [PMCID: PMC1342431]
9. Letts M, Loch R, Wiens J. Monteggia fracture-dislocations in children. *J Bone Joint Surg Br.* 1985; **67(5)**: 724-7.
10. Stoll TM, Willis RB, Paterson DC. Treatment of the missed Monteggia fracture in the child. *J Bone Joint Surg Br.* 1992; **74(3)**: 436-440.
11. Bell-Tawse AJS. The treatment of malunited anterior monteggia fractures in children. *Journal Bone and Joint Surg.* 1965; **47B**: 718-723. [PMID: 1587897]
12. Lloyd-Roberts GC, Bucknill TM. Anterior dislocation of the radial head in children. *J Bone Joint Surg Br* 1977; **59B**: 402-407.
13. Hurst LC, Dubrow EN. Surgical treatment of symptomatic chronic radial head dislocation: a neglected Monteggia fracture. *J Pediatr Orthop.* 1983; **3**: 227-230. [PMID: 6863531]
14. Steel MJ, Peterson HA. Management of chronic posttraumatic radial head dislocation in children. *J Pediatr Orthop* 1999; **19**: 306-312. [PMID: 10344312]
15. Kalamchi A. Monteggia fracture dislocation in children. *Journal Bone and Joint Surg.* 1986; **68-A**: 615-619.
16. Freedman L, Luk K, Leong JC. Radial head reduction after missed monteggia fracture; Brief report. *Journal Bone and Joint Surg.* 1988, **70-B**: 846-847. [PMID: 3192599]
17. Lincoln TL and Mubarak SJ. "Isolated" traumatic radial-head dislocation. *J Pediatr Orthop* 1994; **14**: 454-457. [PMCID: PMC4341054]
18. Morrey BF. The elbow and its disorders, 3d ed. Philadelphia: WB Sanders, 2000: 262-81.
19. Speed and Boyd. Fractures and dislocations in children: Campbell's operative orthopaedics. 2013
20. Kim HT, Park BG, Suh JT, Yoo CI. Chronic radial head dislocation in children, Part 2: results of open treatment and factors affecting final outcome. *J Pediatr Orthop.* 2002; **22(5)**: 591-597. [PMID: 12198459]
21. Good CJ, Wicks MH. Developmental posterior dislocation of the radial head. *J Bone Joint Surg Br* 1983; **65**: 64-65. [PMID: 6822604]
22. Kemnitz S, De Schrijver F, De Smet L. Radial head dislocation with plastic deformation of the ulna in children. A rare and frequently missed condition. *Acta Orthop Belg* 2000; **66**: 359-362. [PMID: 11103487]
23. Sachar K, Mih AD. Congenital radial head dislocations. *Hand Clin* 1998; **14**: 39-47.
24. Chambers HG, Wilkins KE. Dislocation of the head of the radius. In: Rockwood CA Jr, Wilkins KE, Beaty JH, eds. Fractures in Children. Philadelphia, New York: Lippincott-Raven, 1996: 873-8.
25. Bae Donald S. Successful strategies for managing monteggia injuries. *J Pediatr Orthop.* 2016; **36 Suppl 1**: S67-70. [PMID: 27100040]
26. Dormans JP, Rang M. The problem of Monteggia fracture-dislocations in children. *Orthop Clin North Am* 1990; **21**: 251-256. [PMID: 2326051]
27. Best TN. Management of old unreduced Monteggia fracture dislocations of the elbow. *J Pediatr Orthop* 1994; **14**: 193-199. [PMID: 8188833]
28. Inoue G, Shionoya K. Corrective ulnar osteotomy for malunited anterior Monteggia lesions in children. 12 patients followed for 1-12 years. *Acta Orthop Scand* 1998; **69**: 73-76. [PMID: 9524523]
29. Jupiter JB, Fernandez DL, Levin LS, Wysocki RW. Reconstruction of posttraumatic disorders of the forearm. *J Bone Joint Surg Am* 2009; **91**: 2730-2739. [PMID: 19884450]
30. Oner FC, Diepstraten AF. Treatment of chronic post-traumatic dislocation of the radial head in children. *J Bone Joint Surg Br* 1993; **75**: 577-581. [PMID: 8331112]
31. Hirayama T, Takemitsu Y, Yagihara K, Mikita A. Operation for chronic dislocation of the radial head in children. Reduction by osteotomy of the ulna. *J Bone Joint Surg Br* 1987; **69**: 639-642. [PMID: 3611173]
32. Horii E, Nakamura R, Koh S, Inagaki H, Yajima H, Nakao E. Surgical treatment for chronic radial head dislocation. *J Bone Joint Surg Am* 2002; **84**: 1183-1188. [PMID: 12107319]
33. Eamsobhana P, Kaewpornasawan K. Chronic Monteggia Lesions Treatment With Open Reduction and Z-Lengthening Technique With Annular Ligament Reconstruction.. *J Med Assoc Thai.* 2012; **95 suppl 9**: S47-53.
34. Nakamura K, Hirachi K, Uchiyama S, Takahara M, Minami A, *et al* Long term clinical and radiographic outcomes after open reduction for missed monteggia fracture-dislocations in children. *J Bone Joint Surg Am* 2009; **91**: 1394-1404. [PMID: 19487517]
35. David-West KS, Wilson NI, Sherlock DA, Bennet GC. Missed monteggia injuries. *Injury* 2005; **36**: 1206-1209. [PMID: 16214464]
36. Bhojraj SD. Surgical correction of malunited Monteggia fractures in children. *Indian J Orthop.* 1981; **21(2)**: 138-44.
37. Garg R, Fung BK, Chow SP, Ip WY. Surgical management of radial head dislocation in quadriplegic cerebral palsy—a 5 year follow-up. *J Hand Surg Eur Vol* 2007; **32**: 725-726. [PMID: 17993449]
38. Freedman L, Luk K, Leong JC. Radial head reduction after missed monteggia fracture; Brief report. *Journal Bone and Joint Surg.* 1988, **70-B**: 846-847. [PMID: 3192599]
39. Fowles JV, Sliman N and Kassab M. The Monteggia lesion in children. Fracture of the ulna and dislocation of the radial head. *J Bone Joint Surg Am* 1983; **65**: 1276. [PMID: 6654941]
40. Attarian D. Annular ligament reconstruction in chronic posttraumatic radial head dislocation in children. *Contemp Orthop* 1993; **27**: 259. [PMID: 10148877]
41. Cappellino A, Wolfe SW and Marsh JS. Use of a modified Bell Tawse procedure for chronic acquired dislocation of the radial head. *J Pediatr Orthop* 1998; **18**: 410. [PMID: 9600573]
42. Tan JW, Mu MZ, Liao GJ, Li JM. Pathology of the annular ligament in paediatric Monteggia fractures. *Injury* 2008; **39**: 451-455. [PMID: 18005963]
43. Wang MN, Chang WN. Chronic posttraumatic anterior dislocation of the radial head in children: thirteen cases treated by open reduction, ulnar osteotomy, and annular ligament reconstruction through a Boyd incision. *J Orthop Trauma* 2006; **20**: 1-5. [PMID: 16424802]
44. Bor N, Rubin G, Rozen N, Herzenberg JE. Chronic anterior monteggia lesions in children: report of 4 cases treated with closed reduction by ulnar osteotomy and external fixation. *J Pediatr Orthop* 2015; **35**: 7-10. [PMID: 24787311]
45. Ray R, Gaston M. Treatment of late-presenting Monteggia variant with an isolated, simple flexion ulnar osteotomy. *Journal of Pediatric Orthopaedics B* 2014, **23**: 472-476. [PMID: 24869904]
46. Chauhan P. Surgical treatment in children missed Monteggia lesions at Bhuji, Kutch, Gujarat: a retrospective study. *Int J Res Orthop.* 2017; **3(1)**: 30-34.
47. Park H, Kwang-Won P, Park KB, Kim HW, Eom NK, and Lee DH. Impact of Open Reduction on Surgical Strategies for Missed Monteggia Fracture in Children. *Yonsei Med J* 2017; **58(4)**: 829-836. [PMID: 28540998]
48. Lädemann A, Ceroni D, Lefe`vre Y, De Rosa V, De Coulon G, Kaelin A. Surgical treatment of missed Monteggia lesions in children. *J Child Orthop (2007)*; **1**: 237-242. [PMID: 19308516]
49. Hui JH, Sulaiman AR, Lee HC, Lam KS, Lee EH. Open reduction and annular ligament reconstruction with fascia of the forearm in chronic monteggia lesions in children. *J Pediatr Orthop* 2005; **25**:



Hung NN *et al.* Ulnar Osteotomy and ALR by fascia lata in RHD

- 501-506. [PMID: 15958904]
50. Mohamed HA. Surgical treatment of missed Monteggia fracture – Dislocation in Children without Annular ligament reconstruction. *El-Menia Med* 2013. Bull **24** (1). [PMID: 15958904]
51. Lu X, Yan G, Wang Y, Zhu Z, You H, Zhang J, and Guo Y. Repositioning of the Annular Ligament in the Management of Missed Monteggia Fracture. *J Pediatr Orthop* 2017; **37**: 20-22. [PMID: 26177057]
- Peer reviewer:** Perajit Eamsobhana