

Functional Outcome of Intramedullary Interlocking Nail and Plate Fixation in the Surgical Management in Distal Tibia Fracture: A Comparative Study

Vidyadhar Telang, Ujwal Ramteke, Ayush Singh, Hitesh Mangukiya, Ankit Marfatia, Abhishek Harsoor

Vidyadhar Telang, Ujwal Ramteke, Ayush Singh, Hitesh Mangukiya, Ankit Marfatia, Abhishek Harsoor, Department of Orthopaedics, Grant Government Medical College and JJ Hospital, Mumbai, India

Conflict-of-interest statement: The author(s) declare(s) that there is no conflict of interest regarding the publication of this paper.

Open-Access: This article is an open-access article which was selected by an in-house editor and fully peer-reviewed by external reviewers. It is distributed in accordance with the Creative Commons Attribution Non Commercial (CC BY-NC 4.0) license, which permits others to distribute, remix, adapt, build upon this work non-commercially, and license their derivative works on different terms, provided the original work is properly cited and the use is non-commercial. See: <http://creativecommons.org/licenses/by-nc/4.0/>

Correspondence to: Ujwal Ramteke, Department of Orthopaedics, Grant Government Medical College and JJ Hospital, JJ Marg, Byculla, Mumbai -400008, India.
Email: uj14ggmc@gmail.com
Telephone: +91 9975020857

Received: October 13, 2017

Revised: October 30, 2017

Accepted: November 2 2017

Published online: December 28, 2017

ABSTRACT

BACKGROUND: On the basis of the fracture location in the bone distal tibia fractures have the second highest incidence of all tibia fractures after the mid-shaft fracture of tibia. We conducted this study comparing functional outcome of intramedullary interlocking nail and locking plate fixation in the surgical management of extra-articular distal tibia fracture. We Assessed patients with Functional recovery between two treatment modality intramedullary interlocking nail and locking plate fixation in the surgical management of extra-articular distal tibia fracture.

MATERIAL AND METHOD: Total of 42 subjects were consecutively recruited for the study. The Patients with Distal tibia

fracture who came to our hospital Grouped into Group I and Group II. Group I ($n = 21$) patients were treated with Intramedullary interlocking nail; Group II ($n = 21$) patients were treated with open reduction and internal fixation with Plating. Clinical follow-up examination was performed at 4 weeks, 6 weeks, 10 weeks, 3 months, 6 months and 1 year. All patients were assessed clinically and radiographically. Assessment of the patient with Functional recovery was done with American orthopaedic foot and ankle score (AOFAS) minimum 6 months after injury.

RESULT: The functional outcome was assessed by American ankle and foot score (AOFAS). In our study, 12 (57.14%) patients had excellent, 6 (28.58%) patients had good, 2 (9.52%) had fair and 1 (4.76%) patients had poor functional outcome from Group I. In group II, 11 (52.38%) patients had excellent, 8 (38.1%) patients had good and 2 (9.52%) patients had fair outcome. The comparison of the various parameters of this study with other published data shows that the results were comparable.

CONCLUSION: Based upon the findings of the present study, both the methods studied are suitable treatments in the surgical management of extra-articular distal tibia fracture. IM nailing shows lower rate of delayed wound healing and superficial infection but more likely to require additional surgeries to achieve union, and probably will have more complaints of pain in their limbs or knee. While plating avoids malunion and knee pain but the functional and efficacy outcomes appear to be similar between the two treatment groups. Therefore, the choice of surgical procedure should be based on the surgeon's expertise, the clinical circumstances, and especially the patient's injury pattern.

Key words: Locking plates; Intramedullary nailing; Lower third tibial fractures; Distal third tibial fractures; Open reduction; Minimally invasive percutaneous plate osteosynthesis (MIPPO)

© 2017 The Author(s). Published by ACT Publishing Group Ltd. All rights reserved.

Telang V, Ramteke U, Singh A, Mangukiya H, Marfatia A, Harsoor A. Functional Outcome of Intramedullary Interlocking Nail and Plate Fixation in the Surgical Management in Distal Tibia Fracture: A Comparative Study. *International Journal of Orthopaedics* 2017; 4(6): 841-845 Available from: URL: <http://www.ghrnet.org/index.php/ijo/article/view/2163>

INTRODUCTION

Tibia is the most commonly fractured bone amongst all long bones of the body due to its position and lack of soft tissue protection. Distal tibial fractures are primarily located within a square based on the width of the distal tibia. On the basis of the fracture location in the bone, distal tibia fractures have the second highest incidence of all tibia fractures after the mid-shaft fracture of tibia^[1].

The management of distal tibial fractures has always held a particular interest for orthopaedic surgeons. Not only are these fractures relatively common, but they are often difficult to treat. The subcutaneous location of the antero-medial surface of the tibia means that severe bone and soft tissue injury is not infrequent, and there is a high incidence of open fractures compared with other long bones^[2]. Surgical stabilization of fractures and early mobilization of the patient provides best clinical outcome. Although treatment planning for fracture should be considered individually to achieve the optimal results, the effect of decision must be considered in the light of overall injury status and general condition of the patient. Distal Tibia fractures continue to be one of the most controversial fractures that we treat. Most of the controversy resides in the treatment techniques regarding the choice of implants, as the indication for surgery is fairly clear. Some surgeons treat the fracture based on fracture pattern and level of the fracture, mostly on external fixation if soft tissue injury is found, whereas others use predominately plate fixation and some prefer nailing techniques^[3]. These areas of controversy would seem to be an excellent target for prospective clinical research. Surgeons should be warned, however, that there are reasons that answering these questions is exceedingly difficult. Fracture patterns are complex, diverse, and technically demanding and do not lend themselves well to random allocation. In addition, the factors that lead to good versus poor outcomes often depend on treatment techniques than other factors, which can be controlled. For these reasons, new treatment techniques may need to continue to be evaluated in case series and cohort studies.

In Plate osteosynthesis for fractures of the distal tibia is often associated with delayed healing, infection, and hardware problems^[4]. With minimally invasive plate osteosynthesis (MIPPO) method rate of delayed union and infection rate is come down^[5]. Locked intramedullary nailing is the treatment of choice for closed fractures of the tibial shaft^[6]. For proper alignment, the nail should be centrally placed in both the proximal and distal fragments^[7] but most of the time does not fit properly into the distal fragment of the lower third of the tibia which leads complications. This places additional stress on the distal locking bolts that may lead to breakage and malalignment^[8]. Intramedullary nailing of more distal fractures is possible, but the ability to maintain a mechanically stable reduction becomes more difficult.

Therefore, we conducted this study comparing functional outcome of intramedullary interlocking nail and locking plate fixation in the surgical management of extra-articular distal tibia fracture.

MATERIALS AND METHOD

All patients attending the orthopaedic department with extra-articular fracture of distal tibia who met the inclusion criteria were counselled regarding the disease and the study and those willingly consenting to participate in the study were selected. Informed and written consent was obtained from all patients with consent form approved by the Institutional ethical committee. A total of 42 subjects were consecutively recruited for the study. The Patients with Distal tibia fracture

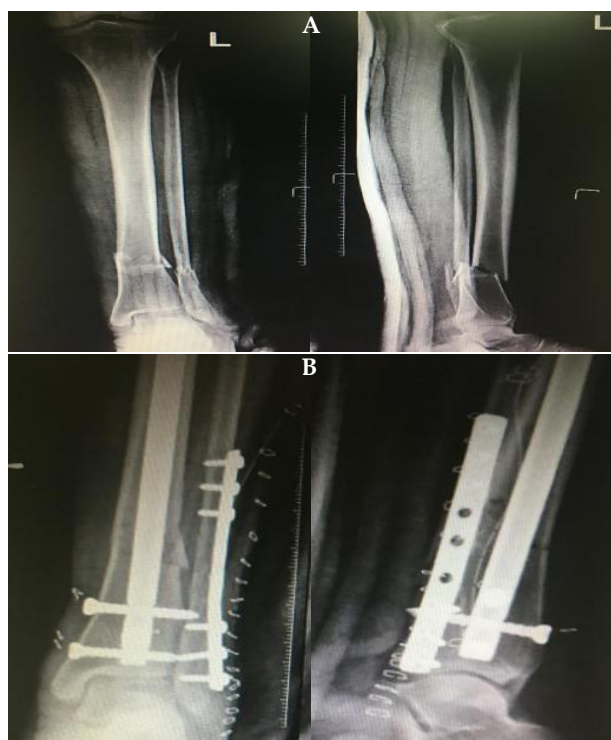

Figure 1 A: pre-op X-ray left leg AP view and lateral view. B: post-op X ray left leg AP view and lateral view.

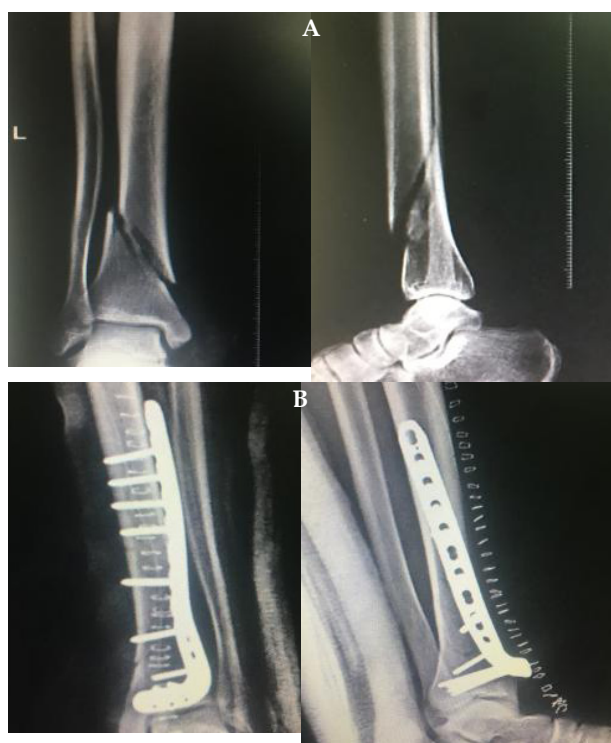

Figure 2 A: pre-op X-ray left leg AP and lateral view. B: post-op X ray left leg AP view and lateral view.

who came to our hospital Grouped into Group I and Group II. For each Group, patients were selected consecutively. Group I ($n = 21$) patients were treated with Intramedullary interlocking nail; Group II ($n = 21$) patients were treated with open reduction and internal fixation with Plating.

Inclusion criteria: Extraarticular fracture, age above 18 years and

less than 60 years, fibula fracture may/may not be associated, patients who were medically fit for surgery.

Exclusion criteria: Pathological fracture, all open fracture, associated compartment syndrome or vascular injury, polytrauma, intraarticular fracture. All the selected patients underwent routine investigations, was clinically evaluated in detail regarding the mode of injury and treatment taken prior to admission. A detailed examination was done to assess any deformity, associated injuries was noted, if any. Standard antero-posterior and lateral roentgenographic views of the affected leg including ankle, tibia and knee was taken. Patients were subjected to all relevant preoperative investigations and were taken up for surgery as soon as he/she was fit for anaesthesia. Surgery was performed under anaesthesia either with intramedullary nailing or plating method. Clinical follow-up examination was performed at 4 weeks, 6 weeks, 10 weeks, 3 months, 6 months and 1 year. All patients were assessed clinically and radiographically with following terms such as tenderness at fracture site, abnormal mobility, infection, pain on movement of knee and ankle joints and antero-posterior and lateral radiographs of the leg for union of fracture.

Assessment of the patient with Functional recovery was done with American orthopaedic foot and ankle score (AOFAS) minimum 6 months after injury. The data were imported into OpenEpi software; all analyses were performed with this software. Demographic characteristics of the study group were summarized with means and standard deviations (SDs) for interval level variables and with percentages for categorical variables. Normal ranges for differences were established as within 95% confidence interval; the Gaussian approximations of the means \pm 1.96 SDs were also calculated. A chi-square test (χ^2) test was used for the analysis of categorical variables. Comparison with two groups was done by t test for continuous variable and chi-square test for categorical variable. A p value of less than 0.05 was considered statistically significant.

OBSERVATION AND RESULTS

The present prospective study comprises of 42 cases with distal tibia fracture that were eligible for inclusion during the period from 2014-2016. Patients were subjected into two groups Group I – Surgeries with Intramedullary interlocking nails. Group II – Surgeries with plate fixation.

Age Distribution:

The incidence of cases in various age groups is shown in table:

Table 1 Age Distribution (n = 42).

Age (years)	Group I	Group II
18-29	11(26.2%)	7(16.67%)
30-39	6(14.28%)	9(21.43%)
40-49	2(4.76%)	3(7.14%)
50-59	2(4.76%)	2(4.76%)
Total	21(100%)	21(100%)

As seen in table 1, all patients are ranged from 18-59 years of age. Amongst group I, maximum patients (26.2%) being in the age group of 18-29 years. The mean (SD) age was 34.24 (9.83) years. Amongst group II, maximum patients (21.43%) being in the age group of 30-39 years. The mean (SD) age was 34.52 (9.30) years. Out of 42 cases, maximum cases were in age group of 18-29 years (n = 16) (38.1%).

Sex Distribution:

In our study, there were 33 (78.57%) male and 9 (21.43%) female pa-

tients present. In group I, 15 (35.72%) males and 6 (14.28%) female patients had undergone surgery. In group II 18 (42.87%) male and 3 (7.13%) female patients had undergone surgery

Table 2 Sex Distribution (n = 42).

Sex	Group I	Group II	Total
Male	15	18	33
Female	6	3	9
Total	21	21	42

Mode of Injury:

In our study, we had 22 patients who had sustained Road Traffic Accident (52.39%), 7 (16.67%) patients fall from height, 5 (11.9%) patients at home, 2 (4.76%) had Assault and 6 (14.28%) had Sport related injury.

Table 3 Mode of trauma to patients.

Mode of trauma	Group I	Group II	Total
Road traffic accident	12	10	22(52.39%)
Fall from height	3	4	7(16.67%)
Fall at home	2	3	5(11.9%)
Assault	1	1	2(4.76%)
Sport related injury	3	3	6(14.28%)

Type of Fracture:

In our study, 16 patients had AO 43 A1, 12 patients undergone treatment under group I and 4 patients under group II. 17 patients had AO 43 A2 type, in which 7 patients undergone treatment under group I and 10 patients under group II. 9 patients had AO 43 A3 type, in which 2 patients undergone treatment under group I and 7 patients under group II.

Table 4 Morphology of fractures AO type.

AO type	Group I	Group II
43 A1	12(57.14%)	4(19.45%)
43 A2	7(33.33%)	10(47.62%)
43 A3	2(9.53%)	7(33.33%)

Associated Injuries:

Our study had 6 head injuries, 4 clavicle fractures. Associated fibula fracture was present in 21 (100%) participants in group I and 21 (100%) patients in group II. Head injuries and clavicle fractures were associated with both fibula and tibia fractures.

Table 5 Associated injuries along with distal tibia fracture.

Associated injuries	Group I	Group II
Fibula fracture	21	21
Head injury	4	2
Clavicle fracture	2	2

Secondary Procedure:

Table 6 6 out of 21 cases had required secondary procedure in Nailing group.

Surgery	No. of cases	Percentage	
Nail	6	Bone marrow aspirate	3
		Nail exchange	2
		Dynamisation	1
		28.57%	

Intra And Post Operative Variable Including Complications:

In our study, we compared intra operative and post-operative vari-

ables. The mean operating time in nail i.e. Group I was 102.14 minutes, where in Group II 96.67 minutes. Mean union time in Group I was 18.43 weeks and 21.43 weeks in Group II. 2 patients had wound problem in group II. 3 patients complained knee pain from Group I. 3 patients had delayed union, 2 patients had malalignment, and one patient had nonunion in Group I. 2 cases had superficial infections and delayed wound healing in Group II.

According to our statistical analysis, mean operating time and mean time of healing between Group I and Group II were statistically significant ($p < 0.05$). 6 out of 21 cases had required secondary procedure in Nailing group.

Table 7 Different intra and post-operative variables.

	Group I	Group II
Mean ± SD operating time (min)	102.14 ± 8.15	96.67 ± 7.30
Mean ± SD time of union(weeks)	18.43 ± 2.04	21.43 ± 2.04
Delayed wound healing	0	2
Knee pain	3	0
Delayed union	3	0
Malalignment	2	0
Non union	1	0
Secondary procedure	6(28.57%)	0

Functional Outcomes:

Table 8 Outcome of patients in both groups.

AOFAS	Group I	Group II
Excellent	12	11
Good	6	8
Fair	2	2
Poor	1	0

DISCUSSION

In our study, after evaluating a results, treatment of lower third Tibial Fractures requires following considerations. We evaluated each fracture radiologically for displacement of fragments and preoperatively decided about type of implant. This preoperative planning helped us a lot while operating in theatre. We classified the fractures according to AO classification^[7]. We agree with Schmidt *et al*^[9] that younger patients mainly involved in fractures. We found that Out of 42 cases, maximum cases were in age group of 18-29 years ($n = 16$) (38.1%). We agree with Tyllianakis *et al*^[10] that males are more prone to get lower third tibial fractures because they are mainly involved in road traffic accidents or occupational accidents. We used esmarch bandage to help in reduction, which we found very helpful to decrease displacement. Large pelvic clamps also used sometimes to held the reduction. C-arm used for assessing the reduction and we found it very convenient and accurate. Our aim during surgery was to get anatomical reduction.

According to Imgi *et al*^[11] anatomic reduction of the fracture is necessary to get good functional outcome. Early range of motion should be started after giving adequate, stability and alignment with fixation^[11]. We also agree GS Kulkarni *et al*^[12] that early motion is necessary in order to obtain good result. Stiffness is usually the result of immobilization. In surgically treated patient mobilization should begin within 5 to 7 days^[10]. This, however, should not be carried out at the expense of the reduction or at the expense of wound healing. If any doubt exists as to the stability of fixation, then mobilization should begin either in traction and be continued in a cast brace or be-

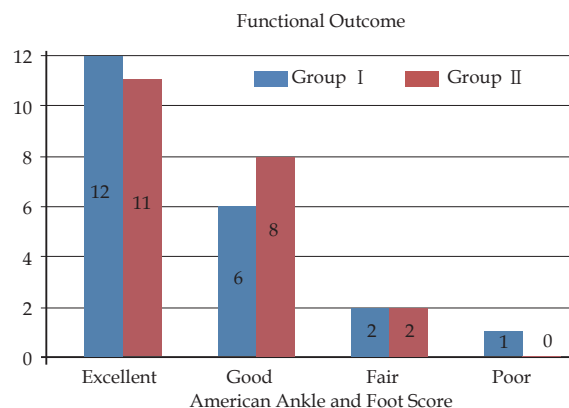


Figure 3 Comparison of Functional outcome in Group I and II.

gin in a cast brace from the start of motion post operatively. We also found that, mechanism of injury determines the type of fracture. We operated 32 out of 42 patients within 2 days of injury. For 10 patients We had to wait up to two weeks for oedema to subside, soft tissue injury to heal skin condition to improve. For 2 weeks we treated those patients with limb elevation in slab. Average hospital stay was 5.5 days and this resulted in reduced expense to the Patient. The principles of intramedullary nailing have been elaborately elucidated by Tanna *et al*^[13]. We started immediate active and passive knee and ankle range of motion exercises on 5th day. In few cases where pre-operative swelling or skin conditions was bad, we delayed it for two weeks. We agree with GS Kulkarni *et al.* that early range of motion exercises is necessary in order to obtain good results. We found Both modalities of fixation deserve place in management of distal tibia fractures. And overall results were comparable in both groups. Union time was shorter with intramedullary nailing compared to plate and screw method. But mean operating time was longer in nailing group compared with plate group. We recommend locked intramedullary nailing with at least two distal locking screws in AO type 43A1, 43A2 and plating by minimally invasive technique in 43A3 fracture types.

Locked intramedullary nailing has an advantage in restoration of ankle motion and reduced wound problems^[14]. Malalignment with nailing was more probably due ankle joint is near and difficult reduction. Better alignment can be achieved with the use of locked intramedullary nails by careful attention to the technique of central guide wire placement and avoiding eccentric reaming and use of blocking screws improves alignment and strength of bone implant construct. Whereas in Locked plate and screws can restore alignment better than intramedullary nails but the long term effect of malalignment needs further evaluation. Use of minimally invasive technique in plating reduces the wound problems^[15].

In our comparative randomized study, even though functional outcome with both the group was comparable. But considering the complication, requirement of secondary procedure with nailing was more. We agree with Hernigou *et al*^[16] that anterior knee pain is noted only with intramedullary technique and no knee complications were noted with plating group. Intramedullary nail being load sharing device, comparatively early mobilization can be started^[17]. Prolonged duration of protected weight bearing was required in patients treated with locked plate and screws^[18]. The fracture can heal a little faster with the application of intramedullary nail so that functional exercises can be started earlier whereas the risk of malunion is obvious lower in the plate group^[19]. In addition, the infection incidence is not higher with the plate fixation as we thought before. The comparison of the

various parameters of this study with other published data shows that the results were comparable. Further research is necessary, in order to evaluate whether this surgical technique in long term provides us with the safe and effective management options for distal tibia fracture.

CONCLUSION

In summary, both IM nailing and plating are appropriate treatments as IM nailing shows lower rate of delayed wound healing and superficial infection while plating avoids malunion and knee pain, but the functional and efficacy outcomes appear to be similar between the two treatment groups.

Therefore, the choice of surgical procedure should be based on the surgeon's expertise, the clinical circumstances, and especially the patient's injury pattern.

ACKNOWLEDGEMENT

We would like to acknowledge residents of radiology for contributing for this case series. Also lab and X-ray technicians whose sincere effort made this case report possible.

REFERENCES

- Pan RH, Chang NT, Chu D, Hsu KF, Hsu YN, Hsu JC, Tseng LY, Yang NP. Epidemiology of orthopedic fractures and other injuries among inpatients admitted due to traffic accidents: a 10-year nationwide survey in Taiwan. *Scientific World Journal*. 2014; **14**: 637872 [PMID: 24672344]; [DOI: 10.1155/2014/637872]
- Lokesh Holagundi, Deepak S, Dayanad, Ramachandra. Functional Outcome with Surgical Management in Distal Tibia Fracture. *IOSR Journal of Dental and Medical Sciences*. 2014; **13(5)**: 83-90.
- Hyder, N & Kessler, S & Jennings, Andrew & G De Boer, P. Compartment syndrome in tibial shaft fracture missed because of a local nerve block. *J Bone Joint Surg Br*. 1996 May; **78(3)**: 499-500. [PMID: 8636198]
- Johner, R, Wruhs O. Classification of Tibial Shaft Fractures and Correlation with Results after Rigid Internal Fixation. *Clin Orthop Relat Res*. 1983 Sep; **(178)**: 7-25. [PMID: 6883870]
- Nork SE, Schwartz AK, Agel J, Holt SK, Schrick JL, Winquist RA. Intramedullary nailing of distal metaphyseal tibial fractures. *J Bone Joint Surg Am*. 2005 Jun; **87(6)**: 1213-21. [PMID: 15930529]; [DOI: 10.2106/JBJS.C.01135]
- Janssen KW, Biert J, Van KA. Treatment of distal tibial fractures: plate versus nail: a retrospective outcome analysis of matched pairs of patients. *JBJS* 2007; **31(5)**: 709-714. [DOI: 10.1007/s00264-006-0237-1]
- Ahmad MA, Sivaraman A, Zia A, Rai A, Patel AD. Percutaneous Locking Plates for Fractures of the Distal Tibia: Our Experience and Review of the Literature. *Journal of Trauma Acute Care Surgery* 2010 Feb; **72(2)**: E81-7. [PMID: 22439240]
- Vallier HA, Bedi. Radiographic and clinical comparison of distal tibia fracture (4-11cm from plafond) nailing versus plating. *Journal of Orthopaedic Trauma*. 2008 May; **22(5)**: 30711. [PMID: 18448983]; [DOI: 10.1097/BOT.0b013e31816ed974]
- Schmidt AH, Finkemeier CG, Tornetta P. Treatment of closed tibial fractures. the American Academy of Orthopaedic Surgeons. *J Bone Joint Surg [Am]* 2003; **85**: 352-68 [PMID: 12690886]
- Tyllianakis M, Megas P, Giannikas D, Lambiris. The result of non-pilon fracture of the distal part of tibia treated with interlocking intramedullary nailing. *Orthopedics*. 2000 Aug; **23(8)**: 805-8. [PMID: 10952042]
- Imgi, Taesk. Distal metaphyseal fracture of tibia; a prospective randomised trial of closed reduction and intramedullary nail versus open reduction and plate and screw fixation. *J trauma*. 2005 Nov; **59(5)**: 1219-23. [PMID: 16385303]
- GS kulkarni, Sushrut Babhulkar. diaphyseal fractures of tibia and fibula in adult. Third edition. Textbook of orthopedics and trauma, 2016; Vol 3: 1616-1641.
- Tanna DD Interlocking nailing; 2nd ed. Book of elements of fracture fixation. New Delhi; 2004: 134-137
- Vallier HA, Cureton BA, Patterson BM. Factors influencing functional outcomes after distal tibia shaft fractures. *Journal of Orthopaedic Trauma* 2012; **26(3)**: 178-183. [PMID: 22198653]; [DOI: 10.1097/BOT.0b013e31823924df]
- Guo JJ, Tang N, Yang HL, Tang TS. A prospective, randomized trial comparing closed intramedullary nailing with percutaneous plating in the treatment of distal metaphyseal fractures of the tibia. *JBJS Br* 2010; **92(7)**: 984-988. [PMID: 20595119]; [DOI: 10.1302/0301-620X.92B7.22959]
- Hernigou P, Cohen D. Proximal entry for intramedullary nailing of tibia, the risk of unrecognized articular damage. *JBJS* 1998; **82B**: 33-41. [PMID: 10697311]
- Vallier HA, Cureton BA, Patterson BM. Randomized, prospective comparison of plate versus intramedullary nail fixation for distal tibia shaft fractures. *Journal of Orthopaedic Trauma* 2011; **25(12)**: 736-741. [PMID: 21904230]; [DOI: 10.1097/BOT.0b013e318213f709]
- Gupta RK, Rohilla RK, Sangwan K, Singh V, Walia S. Locking plate fixation in distal metaphyseal tibia fracture. *Indian journal of Orthopaedics*. 2010 Dec; **34(8)**: 1285-90. [PMID: 19820935]; [DOI: 10.1007/s00264-009-0880-4]
- Krishna A, Peshin C, Singh D. Intramedullary nailing and plate osteosynthesis for fractures of the distal metaphyseal tibia and fibula. *Journal of Orthopaedic Surgery (Hong Kong)* 2009; **17(3)**: 317-320. [DOI: 10.1177/230949900901700315]

Peer Reviewers: NGUYEN HUNG; YOGESH SALPHALE