

## Pediatric Gunshot Wounds of the Upper Extremity

Sherif Dabash, Chris Gerzina, Joshua E. Simson, Ahmed Elabd, Amr A. Abdelgawad, Miguel Pirela-Cruz

Sherif Dabash, Chris Gerzina, Joshua E. Simson, Ahmed Elabd, Amr A. Abdelgawad, Miguel Pirela-Cruz, Department of Orthopaedic Surgery & Rehabilitation, Paul L. Foster School of Medicine, Texas Tech University Health Sciences Center, El Paso, TX, the Unites States.

**Conflict-of-interest statement:** The author(s) declare(s) that there is no conflict of interest regarding the publication of this paper.

**Open-Access:** This article is an open-access article which was selected by an in-house editor and fully peer-reviewed by external reviewers. It is distributed in accordance with the Creative Commons Attribution Non Commercial (CC BY-NC 4.0) license, which permits others to distribute, remix, adapt, build upon this work non-commercially, and license their derivative works on different terms, provided the original work is properly cited and the use is non-commercial. See: <http://creativecommons.org/licenses/by-nc/4.0/>

Correspondence to: Amr Abdelgawad, MD, Associate Professor, Chairman, Department of Orthopaedic Surgery & Rehabilitation, Texas Tech University Health Sciences Center El Paso, Paul L. Foster School of Medicine, 4801 Alberta Avenue, El Paso, Texas 79905, the Unites States.

Email: [amr.abdelgawad@ttuhsc.edu](mailto:amr.abdelgawad@ttuhsc.edu)

Telephone: +1-915-215-5406

Fax: +1-915-545-6704

Received: March 27, 2018

Revised: April 9, 2018

Accepted: April 11 2018

Published online: April 28, 2018

### ABSTRACT

**BACKGROUND:** Gunshot wounds to the upper extremity in pediatric patients are an uncommon injury, but their impact on the patient can be severe. They can be accompanied by nerve damage, bone fracture, or tendon rupture. The most common cause of these pediatric gun injuries is unintentional firearm discharge. The most common type of firearm involved overall is a powdered weapon; however, non-powder weapons are a significant contributor to

pediatric firearm injury. The purpose of this study is to describe the characteristics and treatment outcomes of pediatric GSW in a level one trauma center on the US-Mexican border.

**METHODS:** Retrospective case series.

**RESULTS:** Ten patients met our inclusion criteria for the study. The most frequent mechanism of injury was due to violence (60%), and the most frequent type of firearm involved was a powdered weapon (80%). Males were more affected than females (70%). Six patients experienced bone fracture, three patients experienced nerve damage, and one patient experienced tendon damage. No patients had lasting physical deficits as the result of their injury.

**CONCLUSION:** Most of the pediatric GSW (60%) were due to violence. However, a significant percentage was due to accidental injury (40%). Addressing powder and non-powder weapon safety is warranted to reduce firearm injury in the pediatric population. Good outcomes can be expected in most pediatric GSW.

**Key words:** Pediatric gunshot wound; Violence; Trauma; Firearms; Upper extremity

© 2018 The Author(s). Published by ACT Publishing Group Ltd. All rights reserved.

Dabash S, Gerzina C, Simson JE, Elabd A, Abdelgawad AA, Pierla-Cruz MA. Pediatric Gunshot Wounds of the Upper Extremity. *International Journal of Orthopaedics* 2018; **5(2)**: 910-915 Available from: URL: <http://www.ghrnet.org/index.php/ijo/article/view/2302>

### INTRODUCTION

Firearm injuries are a possible cause of morbidity and mortality in pediatric patients<sup>[1]</sup>. These injuries can take an emotional and financial toll on the affected children and their families and may involve joints, bones, neurovascular structures, and the soft tissues encompassing these structures<sup>[2]</sup>. In 2009, injury-related deaths of adolescents 15 through 19 years of age had a firearm-related rate of 28.8%. These deaths included injuries resulting from homicide, suicide, and unintentional injury<sup>[3]</sup>. In 2015, the mortality rate of firearm injury in patients under 18 years old was 9.1%<sup>[4]</sup>. These injuries can be caused by projectiles from conventional powder propelled weapons as well as from non-powder weapons (e.g. BBs, pellets, airsoft ammunition,

nail guns). Most pediatric firearm injuries are due to powder weapons; however, non-powder weapons should not be discounted due to their potential for causing serious injury<sup>4,5,6</sup>.

Previously, firearm injury in the pediatric population was more commonly due to violence. However, in 2015, the National Injury Reports compiled by the Centers for Disease Control and Prevention (CDC) showed a higher rate of unintentional firearm injury (UFI) compared to violence-related firearm injury<sup>4,6,7</sup>.

We examined the epidemiology of pediatric upper extremity firearm injury at a level one trauma center in our region and compared it to national trends. We are presenting the characteristics and the results of the treatment outcome for this specific type of injury. There is not much literature discussing GSW in the upper extremity of pediatric patients.

## METHODS

This was an IRB approved retrospective case series conducted at a single Level 1 trauma center. The study was conducted using data from 2005 to 2015. Eligible subjects were patients younger than 18 years old who were treated for wounds from a fired projectile to the upper extremity. We defined ‘upper extremity wound’ as “a wound occurring to the hand, forearm, humerus, or the shoulder/scapula/clavicle area”. Patients were excluded if they received a projectile to the thorax, abdomen, or lower extremities.

Primary outcome measures were type of projectile, anatomic location and type of injury, and complications during the hospital course and at follow-up. Demographic data were also collected, including age, gender, reason for the injury (accidental/ violence), and where the injury occurred (within or outside of the U.S.). Data was collected from the University Medical Center of El Paso Level 1 Trauma Registry (Table 1).

## RESULTS

From our initial pool of 13 patients, 10 met the study criteria and had accessible medical record data. 70% (7/10) were males. 40% (4/10) of the injuries occurred as an unintentional firearm injury (UFI), and 60% (6/10) occurred due to violence. UFI case stats showed that 75% (3/4) of patients were 5 years of age or younger, and 50% (2/4) were caused by a non-powder firearm. All 6 of the cases due to violence occurred in Chihuahua, Mexico, while all 4 of the UFI cases occurred

in the U.S.

The injuries consisted of 3 hand wounds, 3 upper arm wounds, 3 shoulder/clavicle/scapula wounds, and 1 forearm wound. 6 patients presented with a fracture: 1 clavicle, 1 scapula, 2 humerus, 1 ulnar, and 1 fracture of the metacarpals. The 2 humerus fracture patients experienced acute nerve damage because of their injuries. 1 of these patients experienced vascular damage as well. The patient with an ulnar fracture presented concurrently with acute flexor digitorum superficialis (FDS) and flexor digitorum profundus (FDP) damage on the 5th digit. The patient with a scapula fracture reported decreased sensation in the distribution of the axillary nerve at presentation.

Of these 6 patients with fractures, 3 fractures achieved union and 1 patient experienced malunion of the 3rd and 4th metacarpals. 1 patient with a clavicle fracture and 1 patient with a scapula fracture did not have sufficient clinic data to determine union status of the fracture. The patient who experienced malunion of the 3rd and 4th metacarpals had no further surgery to correct the malunion. The remaining 4 patients presented with soft tissue damage and no fractures. None of the patients in our study had long term deficits stemming from these injuries.

Patient 1 had an open humerus fracture (grade 3C), and was repaired through open reduction internal fixation (ORIF) with an 8-hole plate. The surgical approach was done through the deltopectoral groove. Fracture union was achieved. During the surgery, an embolectomy of the brachial artery was performed. The complete occlusion required a left upper extremity brachial artery bypass with vein graft. A synthetic nerve graft of the median nerve was performed later, as the patient reported sensory and motor deficits of the median nerve. No lasting nerve or vascular damage occurred as a result of the initial injury or the subsequent surgeries.

Patient 2 had an injury in the shoulder/scapular region due to a powder weapon. Examination revealed bullet fragments imbedded in the subcutaneous tissue surrounding the inlet of the projectile. This injury developed an infection due to the open wound. However, the patient self-discharged from the hospital before treatment could be initiated. Data is not available on future complications, and the results of the infection and injury is unknown.

Patient 3 presented with open humerus fracture (grade 3B). This wound was successfully treated through ORIF with double plating technique. The patient initially presented with radial palsy but this

**Table 1** Patient demographics and type of injury.

Patient Number	Age	Sex	Injury	Treatment Received	Complications	Union/non-union
1	11	F	GSW	Brachial artery embolectomy, ORIF, brachial artery bypass, forearm fasciotomy, hand fasciotomy, synthetic median nerve graft reconstruction	Occlusion of left brachial artery, transection of median and ulnar nerves	Union
2	17	F	GSW to scapula/shoulder	Patient self-discharged	Infection	Unknown
3	17	M	GSW	ORIF	Right radial palsy	Union
4	10	M	GSW to left scapula/clavicle	Non-surgical (sling, clinic referral)	No complications	Unknown
5	15	M	GSW to elbow	No surgical treatment	No complications	N/A
6	3	M	GSW (self-inflicted -45 caliber)	I&D	Tendon damage to flexor digitorum profundus/superficialis (5th metacarpal)	Union
7	5	F	9 mm handgun into hand	I&D	No complications	Cross union between 3rd and 4th metacarpals
8	13	M	GSW to L Posterior Shoulder	I&D, wet to dry dressing, shoulder sling	Fracture of L Scapula - Coracoid process, decreased sensation in L axillary nerve distribution	Union
9	3	M	Nail gun	Removal of nail, I&D	No complications	N/A
10	17	Male	BB gun into hand	I&D with partial A1 pulley release	No complications	N/A

deficit resolved without any further need for surgery or procedures (Figure 1).

Patient 4 had a clavicle fracture and received non-surgical treatment with a sling. Data was not available on this patient to definitively determine union or non-union status of the fracture (Figure 2).

Patient 5 had a gunshot wound from a powder weapon to the lateral aspect of the elbow. This wound did not result in any musculoskeletal, vascular, or nerve damage and was not managed surgically.

Patient 6 presented with an ulnar fracture that was treated surgically with irrigation and debridement. The patient post-operatively reported limited mobility (lack of flexion on 5th digit, limited extension on 2nd, 3rd, and 4th fingers). Further irrigation was performed for exploratory purposes and to break surgical adhesions, as it was determined the patient had suffered acute tendon damage to the flexor digitorum profundus and the flexor digitorum superficialis of the 5th digit. The patient experienced no further deficits, and union of the fracture was achieved (Figure 3).

Patient 7 had fractures of the 3rd, 4th, and 5th metacarpal shafts. This injury was treated surgically with incision, drainage, and bulky dressing. The fracture achieved malunion with a cross-union between 3rd and 4th metacarpals. No further surgery was performed to correct the malunion (Figure 4).

Patient 8 presented with a fracture of the left scapula due to a gunshot wound to the posterior aspect of the shoulder. The scapula was fractured at the coracoid process and was treated with irrigation and debridement and a shoulder sling. The patient initially experienced decreased sensation in the distribution of the left axillary nerve. It is unknown if the patient achieved union of the fracture or the sensory

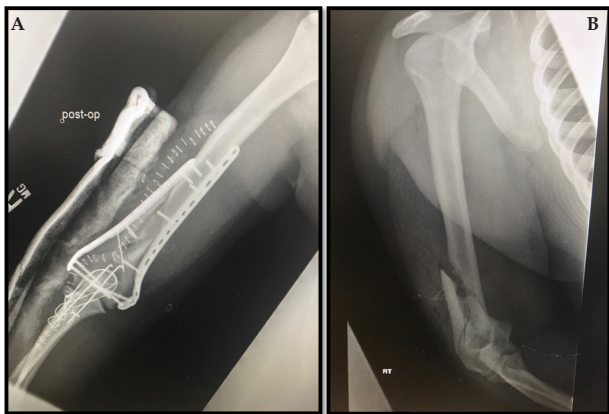
deficit of the axillary nerve resolved, as the patient did not return to the clinic for any follow up appointments.

Patient 9 and patient 10 presented with hand injuries as a result of an unintentional discharge of non-powder weapons. These injuries did not result in a fracture or vasculature/nervous system damage. These injuries were treated surgically with an incision to remove the offending projectile and subsequent surgical drainage. Neither patient experienced lasting deficits as the result of their initial injury or surgery (Figures 5 and 6).

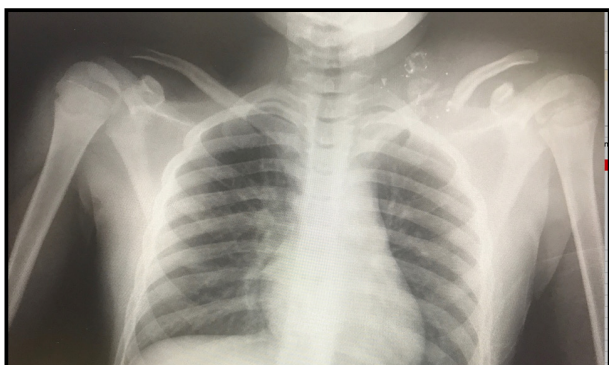
Missing data on patients is due to lack of follow up. We assume these patients did not return to the clinic for their follow up appointments because their wounds (fractures, soft tissue damage, and otherwise) healed with no complications.

## DISCUSSION

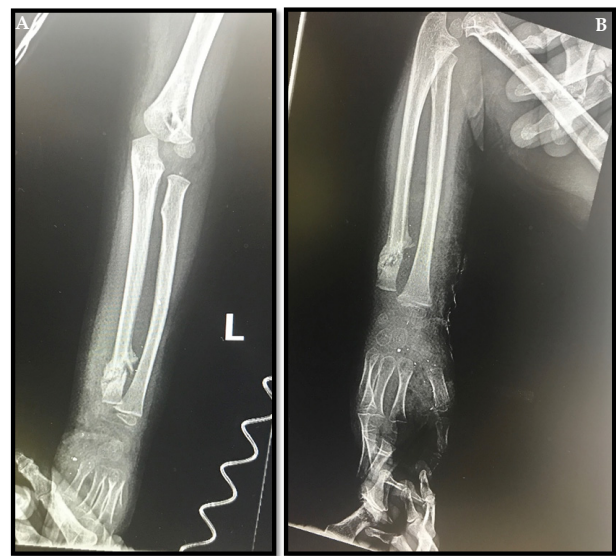
While violence remains the most common cause of firearm injury in the overall population, UFI has emerged as a more prevalent cause of pediatric gun trauma in the United States<sup>[4,8,9]</sup>. While most of our cases were due to violence (60%), most of the unintentional firearm patients were 5 years of age or under (75%). Our data is consistent with national reports that show younger children being more affected by unintentional firearm injury. Additionally, in a national survey conducted from 1993-1997, Powell found that in children younger



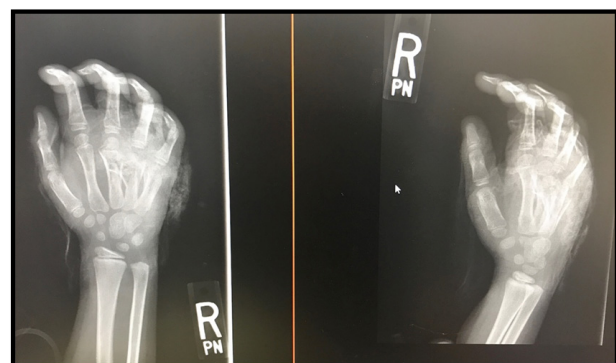**Figure 1** A, B. Patient 3; X ray R Arm. A. showing open R distal humeral fracture Grade B. B. ORIF of the fracture with double plating and Tension band wiring after olecranon chevron osteotomy.



**Figure 2** Patient 4; Xray Chest AP Showing L clavicle fracture.



**Figure 3** Patient 6; X ray L forearm and Elbow. A. Showing skeletally immature patient with L distal ulna fracture open Grade 2. B. showing united L distal ulnar fracture.



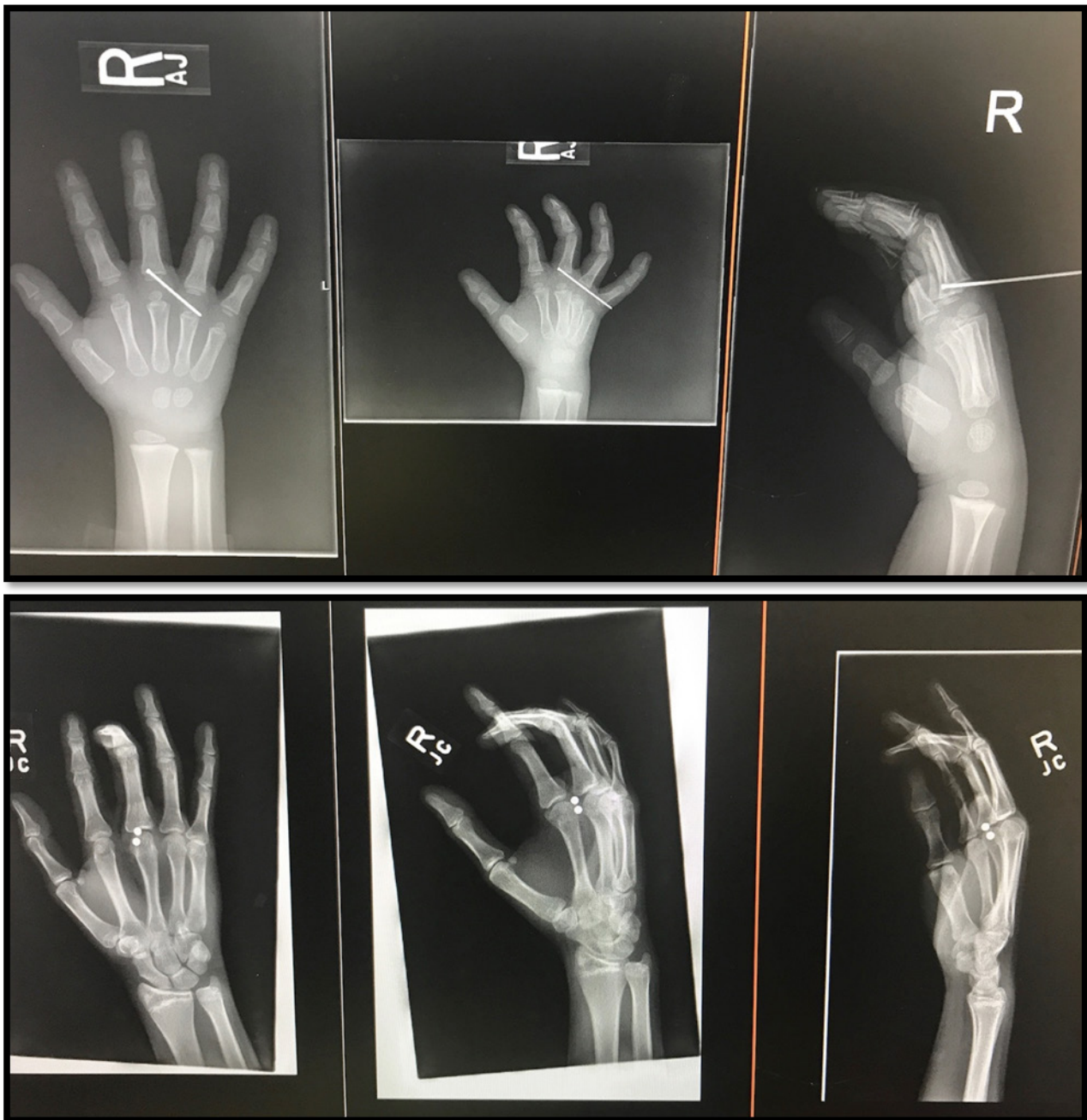**Figure 4** Patient 7; X ray AP/ oblique R hand and wrist A. showing comminuted fractures of the 3rd, 4th, and 5th metacarpal shafts. B. Showing malunion with a cross-union between 3rd and 4th metacarpals.

than 14 years old, non-powder weapons contributed to most of the nonfatal gunshot wounds<sup>[10]</sup>. This trend is consistent with the 2015 National Injury Reports by the CDC<sup>[4]</sup>. We speculate that this trend could be due to the assumption by patients and their parents that these weapons are less lethal than powder weapons. Patients and their parents may not realize the severity of injury that non-powder weapons can cause. Most of our patients were male, supporting national data that male children are more likely to be victims of gun injury<sup>[1,4,6,7,10,11]</sup>.

It is interesting to note that all our cases of violent gun injury occurred in Ciudad Juarez, Mexico. These patients were transported across the US/Mexico border to our hospital for treatment. We hypothesize that the drug-related violence in Ciudad Juarez contributed to some, if not all, of the traumas. In 2010, the homicide

rate in Ciudad Juarez reached a peak of 9.9 per day<sup>[12]</sup>. This falls directly in the middle of the time-period of our study (2005-2015). Unfortunately, children and adolescents have increasingly become victims of drug-related violence in Ciudad Juarez. Children as young as 10 have been employed by cartels to sell drugs, and cartels often target children of government officials and rival gang members<sup>[13]</sup>.

This proximity to cartel violence in Ciudad Juarez, Mexico may address the disparity between the national trend of unintentional firearm injuries being the most common modality of injury and our data. Our data states that 60% (6/10) of the cases included in our study are related to violence, whereas a study by Carter found that 64% of injuries occurred unintentionally<sup>[2]</sup>. The study by Carter obtained data from the National Hospital Ambulatory Medical Care Survey from 2001 to 2010 and focused on identifying national trends



**Figures 5 and 6** Patient 9 and patient 10; presented with hand injuries as a result of an unintentional discharge of non-powder weapons. These injuries did not result in a fracture or vasculature/nervous system damage. These injuries were treated surgically with an incision to remove the offending projectile and subsequent surgical drainage. Neither patient experienced lasting deficits as the result of their initial injury or surgical intervention.

in relation to pediatric firearm injuries<sup>[2]</sup>. Our study examined data from one trauma center in a specific locale; the proximity to Ciudad Juarez, Mexico and the cartel violence is a potential causal factor in this discrepancy versus the national trends examined in Carter’s study.

A study by Leventhal found that in children younger than 10 years of age, UFI’s were significantly more common than the intentional variety<sup>[11]</sup>. It should be noted that in pediatric gunshot fatalities, the clear majority (94.6%) of cases were due to violence<sup>[4]</sup>. Not only are these wounds a considerable cause of mortality in children, but damage to the bone and surrounding structures could result in long-term morbidity, such as chronic pain or loss of limb function<sup>[2,7]</sup>. Because of the potentially disastrous consequences of firearm injury, prevention is a major goal in public health policy<sup>[10]</sup>.

We can reasonably conclude from our data that younger children (10 years of age or younger) are more commonly victims of UFI’s, and their injuries can occur from a wide variety of modalities rather than strictly powder-based firearms. If interventions in gun safety education are to be enacted, our recommendation is that non-powder projectiles be included in this education as well.

The role of the physician in counseling the patient on gun safety may be very underutilized in the medical community. In a survey conducted by Williams, patients reported that they would be more likely to make firearm safety improvements in their homes if they would be counseled by a physician to do so<sup>[14]</sup>. In a study focusing

on firearm owners in a predominantly Hispanic community, an “intervention group” (who received either counseling, a brochure, or a free gun lock from a physician) was compared to a control group. The intervention however, did not result in a significant removal of guns from the home<sup>[15]</sup>. It is not known whether this improvement in gun safety decreased the incidence in UFI’s, as the current literature debates whether firearm ownership or firearm exposure is at the root of the UFI problem. The relationship between ownership of firearms and gun-related injuries has been described as “understudied” in our review of the current literature<sup>[15]</sup>.

The strength of this study that it is the first study (to the best of our knowledge) to describe GSW in pediatric upper extremity. Our results showed that fractures are the most common injury associated with firearm injuries. The associated risks of fracture healing include nonunion, malunion, and growth arrest (if the injury occurs at an open epiphyseal plate). Other complications were acute injury to nerves and tendons, but no lasting deficits were found in our study. We were unable to find current literature on the long-term morbidity due to pediatric firearm injuries; our study represents pilot data in this topic (Table 2).

The primary limitation of this study is the small sample size, as we have only drawn data from a single trauma center. Some patients may have been diverted to other hospitals or present to our emergency department without counseling orthopedic surgeon specialists due to minor BB wounds. Therefore, it cannot be said that our data draws

**Table 2** Literature review of the gun shot injuries.

Author	Time period of the Study	Date Published	Main Outcome	Number of Patients	Conclusions/Outcomes	Survey Instrument
Leventhal	2009	2014	7,391 (95% CI: 6,523-8,259) hospitalizations were due to firearm-related injuries. The hospitalization rate was 8.87 (95% CI: 7.83-9.92) per 100,000 persons.	7,391 hospitalizations of patients < 20 years old in 2009	On average, there were 20 hospitalizations per day due to firearm injuries in patients < 20 years old. Public health efforts are needed to reduce this common source of childhood injury	2009 Kids’ Inpatient Database (a nationally representative sample of discharge data from acute care hospitals of children and adolescents).
CDC Web-based Injury Statistics Query and Reporting System (WISQARS)	2015	2015	1458 fatalities due to firearms; 14,362 total nonfatal gunshot injuries in patients 0-17 years old.	Fatalities due to firearms: 1,458 Total nonfatal BB/pellet gun injuries: 7,451 Total nonfatal firearm wounds: 6,911 Total nonfatal gunshot injuries (firearm + BB/pellet): 14,362		NCHS Vital Statistics System for numbers of deaths. NEISS All Injury Program operated by Consumer Product Safety Commission for numbers of injuries. Bureau Census for population estimates.
Williams	2002-2013	2015	Handguns and air guns were major causes of morbidity and mortality in pediatric patients who suffered UFI.	100 UFIs over a 10-year period (0-19 years old)	Public health safety initiative and legislation changes are warranted to address pediatric firearm safety.	Retrospective single-center descriptive analysis; surveyed all patients with UFIs
Powell	1993-1997	2001	Boys 5 to 9 and 10 to 14 years old had the highest rates of injury related to nonpowder firearms, an estimated 36.2 and 99.8 per 100 000, respectively. Fifty-six percent of those 15 to 19 years old were assault victims.	115,131 children and adolescents	Nonfatal injuries related to powder firearms and nonpowder firearms (BB or pellet guns) are an important source of injury among US children and adolescents.	Data were obtained from the Firearm Injury Surveillance Study, 1993-1997; data were collected through medical record review at hospitals participating in the National Electronic Injury Surveillance System.
Carter	2001 – 2010	2017	Patients with firearm-related injuries were more likely to be male, African American, older (age, 12 to 19 years), and uninsured. In this study, 64% of firearm injuries occurred unintentionally.	198,969 firearm-related ED and clinic visits for children aged ≤19 years were identified (annual average, 19,897 visits)	Firearm-related trauma in children and adolescents is a tremendously costly major public health problem in the United States. It is a leading cause of morbidity and mortality among youth in the United States.	National Hospital Ambulatory Medical Care Survey

an absolute conclusion about the region. If a regional trauma registry were available, that would be a better resource for identifying all cases. Because of the small sample size, any statistical analysis of our data would lack sufficient power to draw definitive conclusions. Therefore, we conducted a descriptive analysis to examine possible trends and compared them with national data. Our study can be the foundation of other studies to discuss this type of lesion or similar lesions.

## CONCLUSION

This study outlines pediatric upper extremity firearm injuries encountered at our hospital over a ten-year period. While powder weapons were found to be the most common mechanism of injury, non-powder firearms were also a significant cause of injury. We found that violence was the most common cause of firearm injury in our patient population. We also found that unintentional firearm injury was more common than violence-related firearm injury in patients 10 years of age or younger. This study highlights the need not only for gun safety awareness and education, but also for physicians to recognize the potential of non-powder projectiles as a source of injury. This can lead to appropriate counseling of patients and parents about the dangers of both powder and non-powder projectile weapons.

## REFERENCES

- Leventhal JM, Gaither JR, Sege R. Hospitalizations due to firearm injuries in children and adolescents. *PEDIATRICS*. 2014; **133**(2): 219-225. [DOI: 10.1542/peds.2013-1809].
- Carter, Cordelia W. MD; Sharkey, Melinda S. MD; Fishman, Felicity MD. Firearm-related Musculoskeletal Injuries in Children and Adolescents. *Journal of the American Academy of Orthopaedic Surgeons*. 2017 March; **25**(3): 169-178. [DOI: 10.5435/JAAOS-D-15-00642].
- Dowd MD, Sege RD, COUNCIL ON INJURY, VIOLENCE, AND POISON PREVENTION EXECUTIVE COMMITTEE, American Academy of Pediatrics. Firearm-related injuries affecting the pediatric population. *PEDIATRICS*. 2012; **130**(5): e1416-e1423. [DOI: 10.1542/peds.2012-2481].
- WISQARS (Web-Based Injury Statistics Query and Reporting System). *Choice Reviews Online*. 2011; **48**(08): 48-4227-48-4227. [DOI: 10.5860/CHOICE.48-4227].
- Veenstra M, Prasad J, Schaeewe H, Donoghue L, Langenburg S. Nonpowder firearms cause significant pediatric injuries. *Journal of Trauma and Acute Care Surgery*. 2015; **78**(6): 1138-1142. [DOI: 10.1097/TA.0000000000000642].
- Senger C, Keijzer R, Smith G, Muensterer OJ. Pediatric firearm injuries: a 10-year single-center experience of 194 patients. *Journal of Pediatric Surgery*. 2011; **46**(5): 927-932. [DOI: 10.1016/j.jpedsurg.2011.02.032].
- Allareddy V, Nalliah RP, Rampa S, Kim MK, Allareddy V. Firearm related injuries amongst children: Estimates from the nationwide emergency department sample. *Injury*. 2012; **43**(12): 2051-2054. [DOI: 10.1016/j.injury.2011.10.040].
- Russo R, Fury M, Accardo S, Krause P. Economic and Educational Impact of Firearm-Related Injury on an Urban Trauma Center. *Orthopedics*. 2016; **39**(1): e57-e61. [DOI: 10.3928/01477447-20151228-02].
- Choi PM, Hong C, Bansal S, Lumba-Brown A, Fitzpatrick CM, Keller MS. Firearm injuries in the pediatric population. *Journal of Trauma and Acute Care Surgery*. 2016; **80**(1): 64-69. [DOI: 10.1097/TA.0000000000000893].
- Powell EC, Jovtis E, Tanz RR. Incidence and Circumstances of Nonfatal Firearm-Related Injuries Among Children and Adolescents. *Archives of Pediatrics & Adolescent Medicine*. 2001; **155**(12): 1364-1368. [DOI: 10.1001/archpedi.155.12.1364].
- James S. Davis, Diego M. Castilla, Carl I. Schulman, Eduardo A. Perez, Holly L. Neville, Juan E. Sola, Twenty years of pediatric gunshot wounds: an urban trauma center's experience. *Journal of Surgical Research* 2013; **184**(1): 556-560, ISSN 0022-4804, [DOI: 10.1016/j.jss.2012.12.047].
- Pachico E. Juarez Murder Rate Reaches 5-Year Low. *Insight crime*. January 4th, 2013. <http://www.insightcrime.org/news-analysis/juarez-murder-rate-reaches-5-year-low>
- O'Connor AM. Mexican drug cartels targeting and killing children. *Washington Post*. April 9th, 2011. [https://www.washingtonpost.com/world/mexican-drug-cartels-targeting-and-killing-children/2011/04/07/AFwkFb9C\\_story.html?utm\\_term=.827ccd739fba](https://www.washingtonpost.com/world/mexican-drug-cartels-targeting-and-killing-children/2011/04/07/AFwkFb9C_story.html?utm_term=.827ccd739fba) Accessed April 22nd, 2017.
- Ballard DH, Williams M, Samra NS. Role of nonpowder guns in pediatric firearm injuries. *The American Journal of Surgery*. December 2016. [DOI: 10.1016/j.amjsurg.2016.12.016].
- Carbone PS, Clemens CJ, Ball TM. Article. *Arch Pediatr Adolesc Med*. 2005; **159**(11): 1049-1054 [DOI: 10.1001/archpedi.159.11.1049]