

Percutaneous Endoscopic Cervical Discectomy and Osteophytes Removal Via an Anterior Transforaminal Approach for Radiculopathy: Technical Notes and Review

Santosh K Bashyal, Qing-Shuai Yu, Liang Chen, Zheng-Jian Yan, Lei Chu, Zhong-Liang Deng

Santosh K Bashyal, Devdaha Medical College Research Institute Extended Program of Kathmandu University, Rupandehi, Nepal
Qing-Shuai Yu, Liang Chen, Zheng-Jian Yan, Lei Chu, Zhong-Liang Deng, Department of Orthopaedics, the Second Affiliated Hospital, Chongqing Medical University, No. 76 Linjiang Road, District Yuzhong, Chongqing, 400010, China

Conflict-of-interest statement: The author(s) declare(s) that there is no conflict of interest regarding the publication of this paper.

Open-Access: This article is an open-access article which was selected by an in-house editor and fully peer-reviewed by external reviewers. It is distributed in accordance with the Creative Commons Attribution Non Commercial (CC BY-NC 4.0) license, which permits others to distribute, remix, adapt, build upon this work non-commercially, and license their derivative works on different terms, provided the original work is properly cited and the use is non-commercial. See: <http://creativecommons.org/licenses/by-nc/4.0/>

Correspondence to: Zhong-Liang Deng, MD, PhD, Department of Orthopaedics, The Second Affiliated Hospital, Chongqing Medical University, No.76 Linjiang Road, District Yuzhong, Chongqing, 400010, China.

Email: Zhongliang.deng@yahoo.com

Telephone: +8613608367586

Received: April 11, 2018

Revised: May 12, 2018

Accepted: May 14 2018

Published online: June 28, 2018

ABSTRACT

BACKGROUND: Cervical radiculopathy can be treated by anterior endoscopic approach to access its target pathology decompressing spinal nerve roots without fusion. The transforaminal anterior percutaneous endoscopic cervical discectomy approach is easy way to transverse process and decompress and remove osteophytes. It preserves spinal motion, stability and reduces risk of vertebral injury.

METHODS: A case selected had neck pain radiating toward right

arm for 2 month but severe pain from 20 days, neck deformities, head tilted toward right side. Neurological examination showed decreased sensation, weakness over right sided trapezius, biceps and triceps muscles. Eaton sign and Spurling sign were positive. Preoperative dynamic X-ray showed degenerative changes, osteophytes at C3-4, C5-6, CT -intervertebral foraminal stenosis at C3-4 and C5-6 level, MRI -disc protrusion severely compressing spinal cord at C3/4 level. We operated at most significant level as first successful newer approach for cervical radiculopathy with osteophytes removal, decompression and discectomy by PECD anterolateral (transforaminal approach) under general anesthesia.

RESULTS: Blood loss 100 mL. Hospital Stay 3 days. Operative time was 80 minute. There was marked improvement of preoperative VAS score from 7/10 to 3/10. After surgery drain was fixed for 24 hour to collect some residual fluids and avoid hematomas. There were no significant post operative events or surgery-related complications.

CONCLUSION: Under percutaneous endoscopic system is easy to visualize proper minute structure, drill, dissect and lessen the chance of iatrogenic injury, decrease risk of vertebral arteries. Anterior transforaminal endoscopic surgical approach can be further developed and trained for treatment of cervical radiculopathy in large population.

Key words: Cervical radiculopathy; Osteophytes; Minimal invasive surgery; PECD; Anterolateral (transforaminal) approach

© 2018 The Author(s). Published by ACT Publishing Group Ltd. All rights reserved.

Bashyal SK, Yu QS, Chen L, Yan ZJ, Chu L, Deng ZL. Percutaneous Endoscopic Cervical Discectomy and Osteophytes Removal Via an Anterior Transforaminal Approach for Radiculopathy: Technical Notes and Review. *International Journal of Orthopaedics* 2018; **5(3)**: 921-927 Available from: URL: <http://www.ghrnet.org/index.php/ijo/article/view/2311>

INTRODUCTION

Cervical spondylotic radiculopathy (CSR) is associated with nerve root compression, disorder in dermatomes and myotomes in upper

extremities with lower motor neuron sign of weakness, wasting, flaccid paralysis and hyporeflexia. As the posterolateral part of intervertebral disc and the surrounding uncovertebral joint form the anterior margin of intervertebral foramen. The posterolateral intervertebral disc herniation and the hyperplasia surrounding the posterolateral part of uncovertebral joint are the two main etiology of CSR. When conservative therapy failed and pain was beyond the tolerance, surgical intervention seems to be inevitable. For CSR accompanying with bony foraminal stenosis, the osteophyte located at the posterolateral part of uncovertebral joint could be hard to remove via an only posterior approach. A foraminoplasty via an anterior transforaminal approach could provide the direct decompression without the violation to spinal stability, which has been successively described by several surgeons, including anterior micro foraminotomy, anterior transuncal approach and further modified approached based on the former two approaches^[1-7]. However, none of them was performed under percutaneous endoscopy. With the development in the endoscopic technique, percutaneous endoscopic cervical discectomy (PECD) has emerged, which bridges the gap between conservative therapy and traditional surgery. The gap was longer duration and prolonged hospital stay. We have shared our preliminary exploration in endoscopic surgical approach in cervical spondylosis, including posterior translaminar approach, anterior transdiscal and transcorporeal approach. For the treatment of CSR, posterior translaminar approach seems to be more efficacious than the other two accesses. When the osteophyte was extended out of the intervertebral foramen, removing the osteophyte via a posterior approach could be dangerous due to the possibility of vertebral artery (VA) injury. In the following case of CSR with bony stenosis, we will share the new technique of anterior lateral percutaneous endoscopic cervical foraminoplasty (ALPECF) to remove the osteophyte and accomplish cervical nerve root decompression.

METHODS

Typical case

A 65-year-old male presented with neck pain radiating towards right arm since 2 month but more severe from 20 days, neck deformities, head tilted to right side. Neurological examination showed decreased sensation and weakness over right sided trapezius, biceps and triceps muscles 3/5 muscles power grading. Physical examination revealed Eaton sign and Spurling sign positive.

Preoperative dynamic X-ray (Figure 1A and B) showed degenerative changes and osteophytes at C3-4, C5-6. CT (computerized tomography) (Figure 2A) showed intervertebral foraminal stenosis at C3-4 and C5-6 level. CTA (computerized tomographic angiography)(Figure 2B) of Right and left done shows no abnormal position of vertebral arteries MRI (magnetic resonance imaging) (Figure 3) shows disc protrusion severely compressing spinal cord at C3/4 level and minimal at C5-6.

Operative procedure

A brief summary of ALPECF from skin incision to placement of endoscope and trajectory to transverse process to C3-4 level dissecting, decompression and foraminoplasty of a case. Under the guidance of C arm fluoroscopic the anterioposterior (AP) and lateral view and Spinal endoscopic system of SPINENDOS GmbH (SPINENDOS GmbH, München, Germany, whole surgery was done (Figure 6 and 7).

Under endotracheal general anesthesia, patient was placed in supine position with neck slightly extended by placing a rolled towel under the shoulders. A Strap was placed over the forehead for stabilization whose shoulder were gently held sidewise position by tape

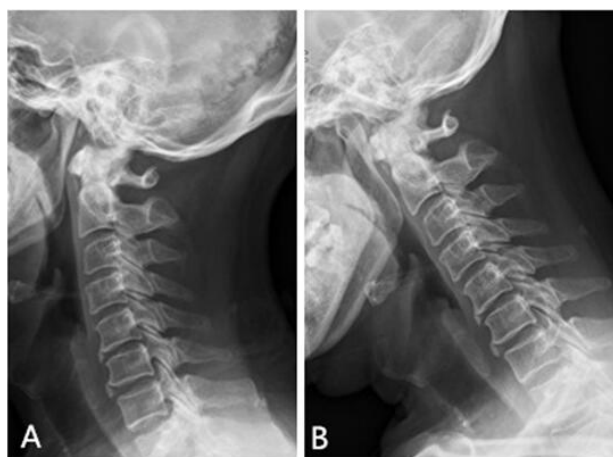

Figure 1 Preoperative Dynamic lateral cervical X-ray. C spine Flexion and Extension dynamic roentgenograms: Degenerative change, decreased disc height space at C3/4 level and Osteophytes at C3-4, C5-6. (A): Right Lateral-Extension View; (B): Right Lateral -Flexion View.

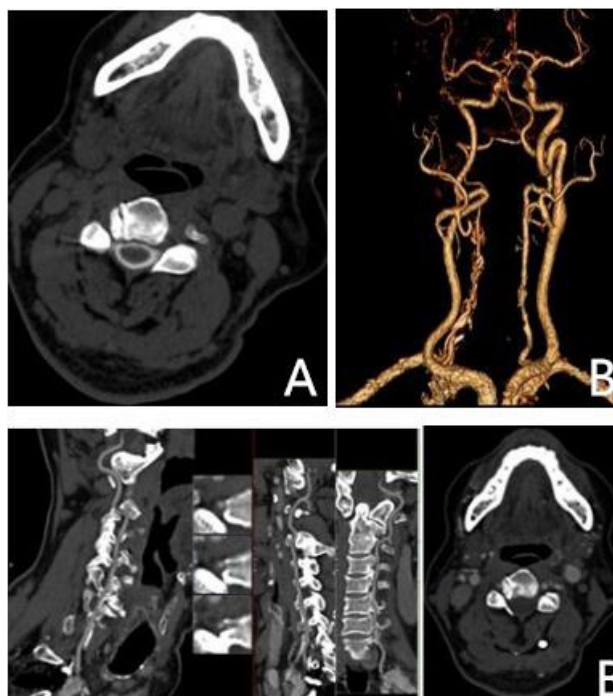


Figure 2 Preoperative CT Scan. Preoperative Axial Computer tomography images: (A): intervertebral foraminal stenosis at C3-4; (B): CTA of Right and left done shows no abnormal position of vertebral arteries.

(Figure 5A and B). A metal guide wire was placed into a gastric tube which helped to visualize the radiolucent esophagus during operation (Figure 7B). A clear visual field was maintained with a low energy bipolar radiofrequency (Ellman) and the continuous irrigation of 0.9% saline solution.

When the level of C3-4 was confirmed by C-arm fluoroscopy (Figure 5C and D), an 8-mm transverse skin incision was made, which was medial to the sternocleidomastoid muscle slightly below the pathological level (Figure 5E). A 2-finger technique was applied to create a small safe window between the lateral carotid artery and the medial tracheoesophagus. Through the skin incision, a puncture-needle complex (Figure 6A), incorporating a non-beveled sheath of a vertebroplasty needle outside (Figure 5F) and a blunted 1.5mm K-wire inside, was inserted cranially and laterally and placed on the anterior surface of C3 Vertebral body. The blunted puncture-needle

complex (Figure 6B, F) was slide to the notch between the C4 vertebral body and the right transverse process (Figure 6G). A long handled high speed endoscopic burr (Figure 7A, B) with a diameter of 5 mm was employed to partially remove the C4 transverse process to expose the right C3-4uncovertebral joint (Figure 5 G, H, J).The drilling trajectory was medially 10-12 degree and cranially parallel

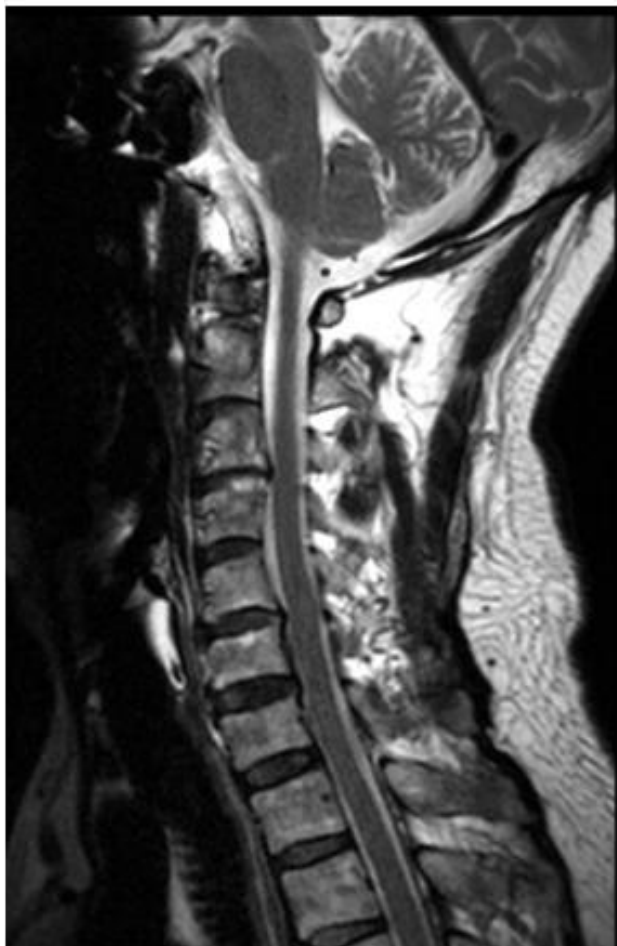

Figure 3 Preoperative MRI. Sagittal T2-Weighted and axial plane showing disc protrusion severely compressing spinal cord at C3/4 level and minimal at C5-6.

to the intervertebral space (Figure 6C, D).During the process, the osteophyte was visible which could be removed by an endoscopic burr (Figure 6F). For avoiding from the possibility of intraoperative VA rupture, the osteophyte should be removed from laterally to medially (Figure 5K). Especially when the osteophyte compressed VA, the lateral cortical wall of osteophyte should be preserved. When the medial part osteophyte was removed, the lateral cortical wall could be crash down by an endoscopic probe (Figure 7B). Thus VA could be observed and protected by the working sheath, which could facilitate partially removing the uncovertebral joint and retrieving the herniated disc fragment decreasing the risk of VA injury (Figure 7C). The foraminoplasty was terminated until a satisfactory mobilization of nerve root was confirmed under endoscopy. When the adequate decompression and hemostasis was done, all the instruments removed. Drainage tube was remained for 24 hours for collecting fluids and avoiding possibility of hematoma (Figure 5I). Incised would was sutured and covered with a water impermeable dressing.

Clinical outcome assessment

Operation was completed in 80 minutes. Patient was shifted to post-operative ward with antibiotics and dehydration treatment for 24 hours. After the procedure patient was asked to exercise neck muscles gradually and return to sedentary or nonphysical work after 3-4 days, however neck collar was advice for 3 weeks. Postoperative CT and MRI were confirmed the satisfactory neural decompression.

RESULTS

A tremendous improvement of clinical symptoms was observed instantly after operation. The radicular pain of VAS (visual analogue score) improved from preoperative 7/10 to 3/10. Post-operative range of movement in the neck was unrestricted. The drainage was only remained for 24 hour. There were no significant postoperative events or surgery-related complications, such as dysphagia, Horner syndrome, recurrent laryngeal nerve palsy, vagus nerve injury, tracheoesophageal injury, or cervical hemocele. In the first 3 weeks postoperatively, cervical collar was recommended. Postoperative CT (Figure 4A) and MRI (Figure 4B1, B2) and regular follow up done showed no disc narrowing, instability of cervical spine or no any sign of compression and stenosis and total removal of osteophytes and drilling tunnel.

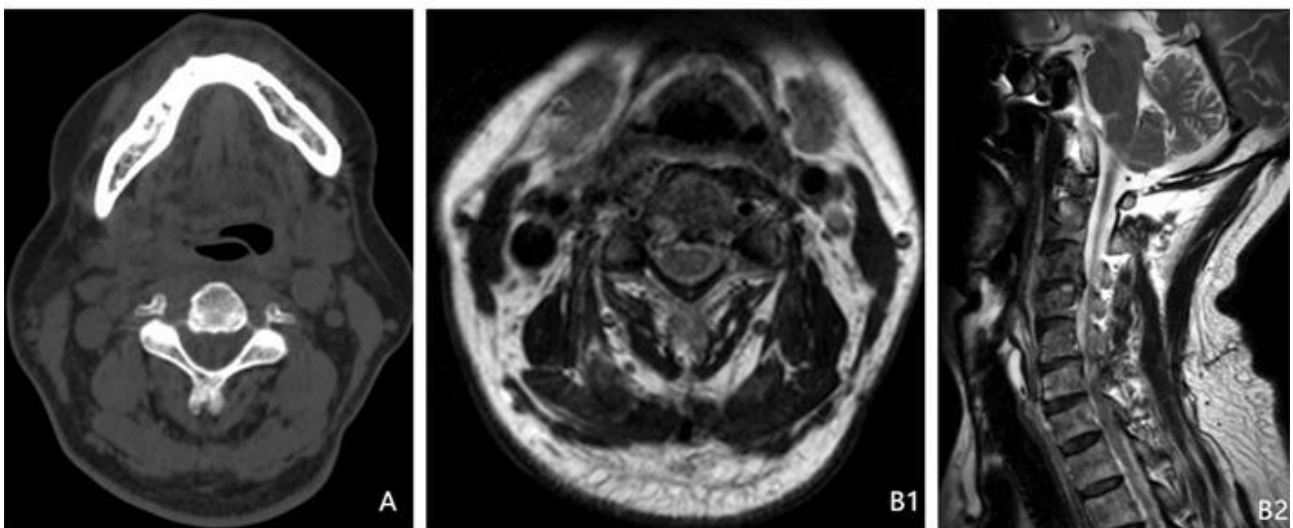


Figure 4 Postoperative CT Scan/MRI. (A): Axial CT images preservation of medial wall of intervertebral space foramina, wide intervertebral space, no compression or stenosis, adequate decompression. (B) (B.1 & B.2): T2W MRI show no compression on spinal cords.

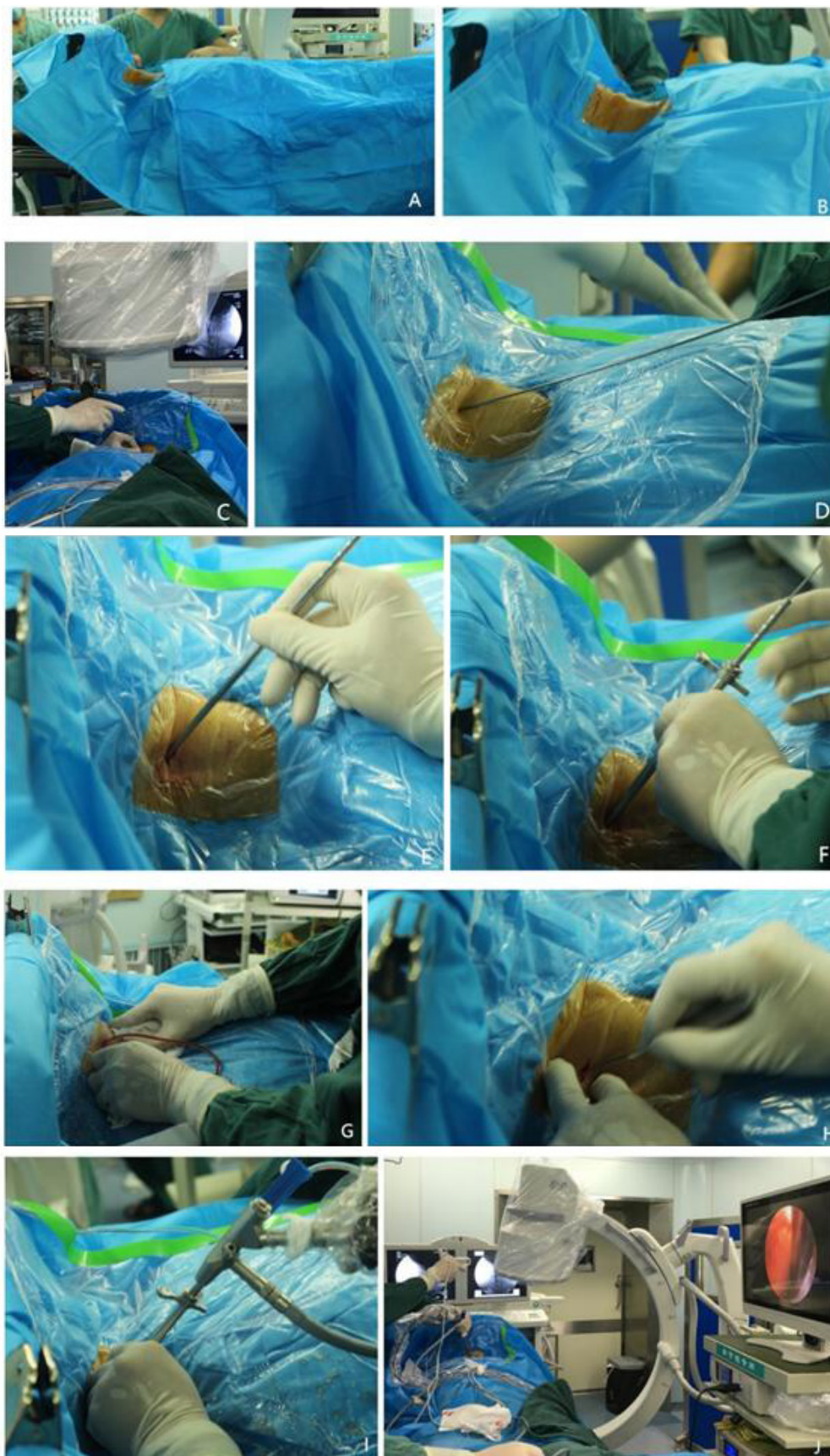

Figure 5 Operative preparation and transforaminal PECD approach in details. Operative preparation and transforaminal PECD approach in details. (A, B): Patient in supine position with neck slight extended. (C, D): The position of C3-C4 level confirmed by c arm fluoroscopy K wire from outside to verify the position target transverse process. (E): Rt side vertical incision 10 mm, 2 cm away from midline, dissect with narrow blade, small artery forceps to further retract small hole without tissue damage. (F): Inner k wire replaced by stylet to reach up anterior surface of C3. (G, H): placement of endoscopic system. (I): fixation of drain after surgery is completed. (J): MIS endoscopic working system for transverse process PECD to decompress and osteophytes removal.

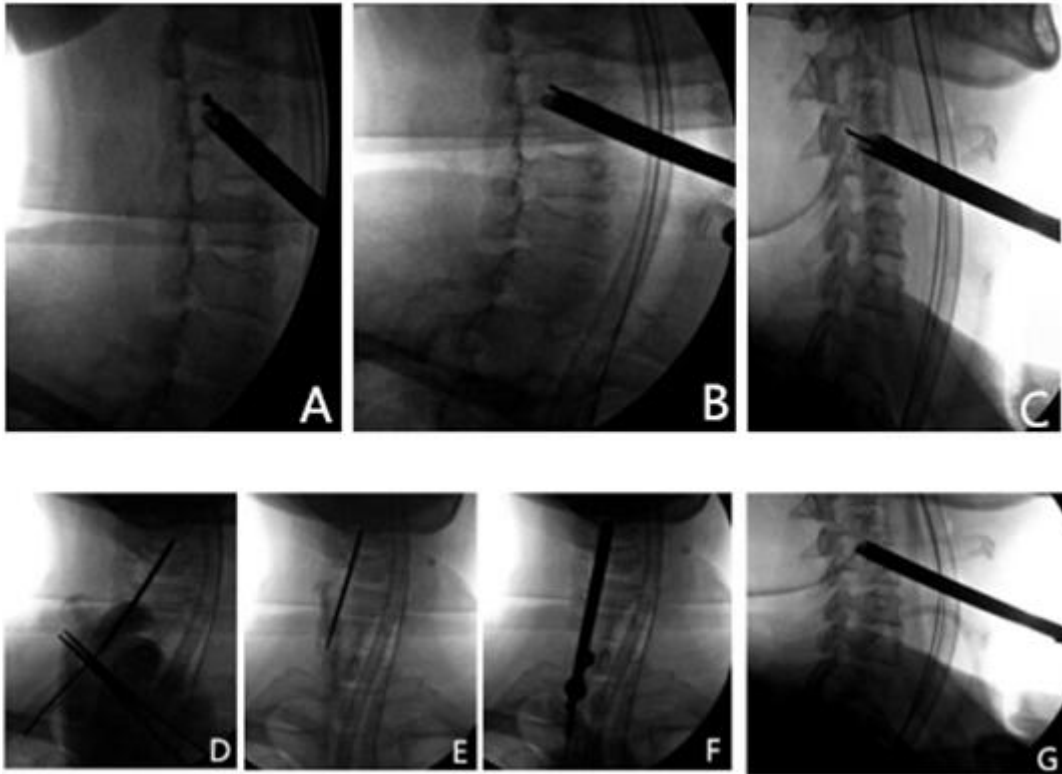


Figure 6 Intraoperative view under fluoroscopy. (A): A puncture-needle complex was inserted cranially and medially and placed on the anterior surface of C3. (B): the blunted inner K-wire was replaced by a sharp stylet, tip of the puncture needle complex is sharp. (C): the tip of the sharp stylet approximately reached the posterosuperior edge of C3. (D): blunted guide wire- tip of the puncture-needle complex is blunted. (E): the guide wire with the dilator sheath and the outer working sheath toward the former punctured hole of C3. (F): diamond high-speed burr along with the former trajectory toward C3. (G): The herniated nucleus pulposus and osteophytes is removed by a rongeur.

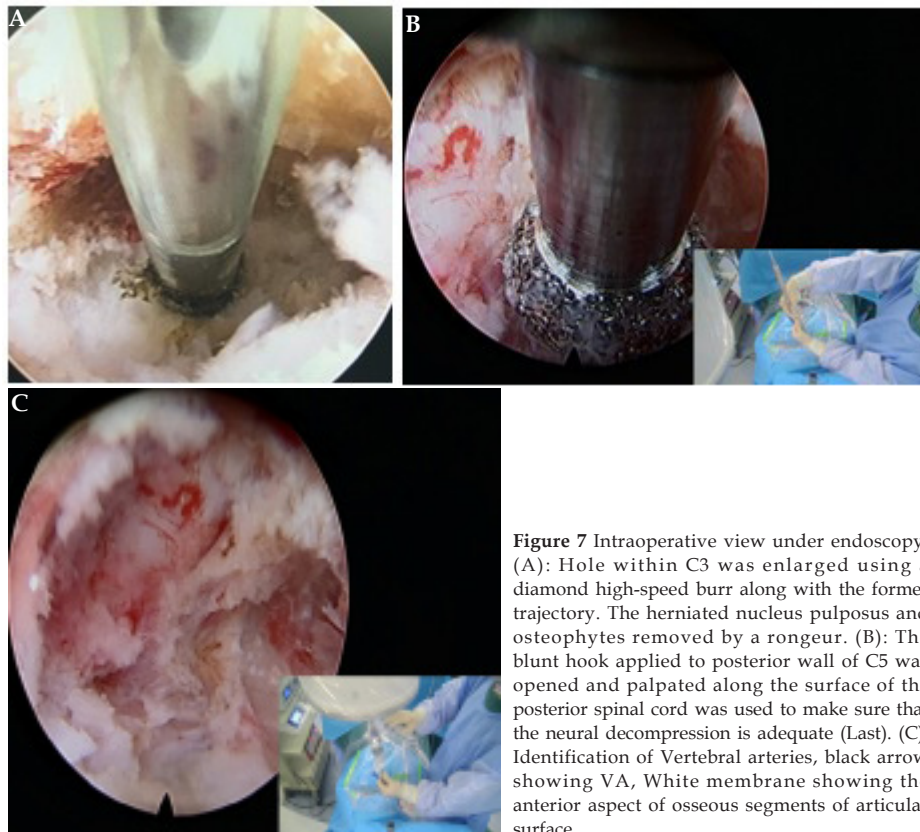

Figure 7 Intraoperative view under endoscopy. (A): Hole within C3 was enlarged using a diamond high-speed burr along with the former trajectory. The herniated nucleus pulposus and osteophytes removed by a rongeur. (B): The blunt hook applied to posterior wall of C5 was opened and palpated along the surface of the posterior spinal cord was used to make sure that the neural decompression is adequate (Last). (C): Identification of Vertebral arteries, black arrow showing VA, White membrane showing the anterior aspect of osseous segments of articular surface.

DISCUSSION

Depend on the location, extent and type of the compression pathology, curvature of the spine and presence of instability approaches is to be determined and planned. In 1928 Stookey first describe the clinical symptoms and anatomic location of cervical disc herniation and later Mixter and Barr stated and proved that laminectomy and disc excision can successfully relieve the radiculopathy pain^[8,9]. Robinson and Smith in 1955, Cloward in 1958 first time successfully performed anterior cervical discectomy with bone fusion to accomplish direct decompression of the compressive osteophytes and disc fragment^[10, 7,11]. Hilibrand *et al* studied 10 year outcome of clinical patients who had cervical fusion, found that up to 25 % patients had adjacent level degenerative diseases^[12]. Minimal invasive surgery was introduced as safe alternative management for cervical radiculopathy and myelopathy which has very good clinical outcomes and long term spinal stability without need of bone grafting and implants. With the continuous development of the spinal endoscopic technique in recent years, percutaneous endoscopic cervical discectomy (PECD) has emerged in order to address the need of preservation of functional motion of cervical spine and its stability while removing the underlying pathology. In current endoscopic surgical approach, only posterior translaminar approach could be more efficacious to deal with CSR. Unfortunately, this approach could not be inapplicable to remove the osteophyte located anterior to intervertebral foramen. Instability of spine occur when the decompression is done at multiple level or if more than 50 percentage of the facet joint is disrupted^[15].

The anterior transforaminal approach is minimally invasive effective method to treat unilateral cervical radiculopathy caused by disc prolapsed or uncovertebral osteophytes. This technique helps to prevent segment mobility and prevent the acceleration of degenerative changes at adjacent levels. In 1996 Jho described the technique of anterior cervical microforaminotomy to direct removal of compressive pathology and preserve the motion segments without bony fusion^[3,4]. J-Y Lee *et al*, found the new alternative and modified method to anterior discectomy with implantation of cervical prosthesis or posterior cervical foraminotomy. This method helped to allow the direct removal of the compressive lesion in neural foramen through a small keyhole transuncal approach. It is treatment for spondylotic foraminal stenosis and extruded disc fragments^[13,16]. Endoscopic surgery is less invasive approximately 7 mm hollow tube to insert without the placement of a retractor which makes surgery easier and simpler than traditional open method. When introducing the anterior transforaminal approach into cervical endoscopic surgery, the magnified field and adjustable visual angle could reduce the possibility of intraoperative iatrogenic injury. If greater visualization and structure is not so clear, a portion of the inferior spinal process can be removed. Ooi *et al* first used endoscope system in chronic arachnoiditis, nerve root entrapment during claudication caused by lumbar spinal stenosis to visualize intrathecal space pathology before surgery^[14,18] more importantly, although both endoscopic surgery and microendoscopy are with concurrent minimization of operation-related trauma, the most difference between them is that the procedure was accomplished under different media. As water mediated procedure rather than an air mediated operation, endoscopic surgery could achieve targeted decompression under continuous saline irrigation, which could generate hydraulic pressure reducing intraoperative bleeding and decreases the risk of infection.

Through PECD method radiculopathy symptoms can be improved by opening a hole to the prominent disc fiber to decrease disc pressure by dissecting the section of disc and reducing the mechanical

pressure around the pulp and nerve root which form the nucleus pulposus and fibers. The operation is more difficult if the herniated disc is in dorsolateral position lying entirely beneath the nerve root. As the most severe surgery related complication, vertebral artery (VA) injury could occur, especially exposing or drilling the joint and bones. Proper planning and preoperative evaluation of VA helps to assist the operating surgeon to avoid vertebral artery injury during anterior surgical approaches to the cervical spines. There is high degree of variation of transverse process and Vertebral arteries. It is recommended to careful CT and MRI for preoperative evaluation before surgery because there can be variation in transverse foramen and VA located relative to bony vertebral landmarks by spinal level and gender. Smith *et al* and Walike *et al* did the procedure related research found that there is a greater risk of VA laceration at cephaloid levels during lateral nerve root compression and lateral extension of central decompression procedure^[8,19,20]. It was found during lateral decompression while removing osteophytes projecting into the neural foramen that gradual decrease in distance from the apex of uncinat process to the medial border of transverse foramen. It is recommended to remove the osteophyte from laterally to medially where it can compress the vertebral artery. As a protective layer for VA, the lateral cortical wall of osteophyte should be resected until the medial osteophyte was removed. During foraminoplasty, VA could be observed and protected by the working sheath, which could facilitate partially removing the uncovertebral joint and retrieving the herniated disc fragment decreasing the iatrogenic risk of VA injury.

As the limitation of a case, the study needs to be done in larger population samples and long term follow up. With the concept of preservation of mobility and reconstruct the spine segments cervical disc arthroplasty was developed to replace it after discectomy of cervical radiculopathy or myelopathy in young cases^[21]. However Y-K park *et al* experienced removal of osteophytes and the uncinat process to decompress bony portion which destroy the posterolateral corner of the disc space and induces degenerative changes^[17]. The long term clinic follow up is still unclear. Additionally, a comparative study between anterior transforaminal and traditional posterior approach should be done to encourage emerging spinal surgeon for transformation of their skill of surgery.

CONCLUSION

This surgical Procedure can be superior, easy access to the pathological structure than traditional open method. It is minimal structural tissue damage and decreases the risk of vertebral artery puncture. Under the direct visual and percutaneous endoscopic system it is easy to visualize the proper minute structure, drill, dissect and lessen the chance of iatrogenic injury. This anterior transformational endoscopic surgical approach can be further developed and trained for the treatment of cervical radiculopathy in large population.

ACKNOWLEDGEMENTS

Author Contributions

Study concept and design: Drs. Santosh K Bashyal and Zhong-Liang Deng designed the study protocol; Acquisition of data: Dr. (s) Santosh K Bashyal, Qing-Shuai Yu, Liang Chen, Zheng-Jian Yan, Lei Chu, Saudia shawan, Zhong-Liang Deng had full access to all the data in the study and takes responsibility for the integrity of the data and the accuracy of the data analysis; Analysis and interpretation: Dr. (s) Santosh K Bashyal and Zhong-Liang Deng provided revision for intellectual content and final approval of the manuscript. Dr.(s) Santosh K Bashyal, Qing-Shuai Yu, Liang Chen, Zheng-Jian Yan,

Lei Chu, Saudia shawan, Zhong-Liang Deng managed the literature searches and summaries of previous related work and wrote the first draft of the manuscript; Study supervision: Zhong liang deng.

Conflict of Interest

All authors have no conflicts of interest to report. None of the authors of the manuscript received any remuneration. Further, the authors have not received any reimbursement or honorarium in any other manner. The authors are not affiliated in any manner with any remuneration. However, all the authors are members of the Spine unit of orthopedic department of second hospital of Chongqing medical university and practicing interventional pain physicians.

Funding/Support

The authors wish to disclose and thank the sponsor of the study. The study was sponsored by The Key Project of Natural science foundation of committee of science and technology (No.cstc2013jjBi0021), the National Nature science Foundation of china (No.81272005), the Key Project of Medical scientific research of Chongqing health and family planning commission (No.2016ZDXM007), the special foundation for scientific research platform of Chongqing (No.ctsc2015yfp-gcjsyjzx120019) funds. They had no influence or interference after the protocol was designed.

Role of Sponsor

The financial sponsor of this work had no role in the design and conduct of the study or the collection, management, analysis, and interpretation of the data. The sponsor also did not have a role in the preparation or review of the manuscript or the decision to submit. The authors also wish to thank for entire team members of spinal surgery of second hospital of CQMU. We also would like to thank the editorial board of JNS for review and criticism in improving the manuscript.

Ethics approval and consent

Chongqing Medical University Board of Research Ethics Committee Approved.

Consent for publication

Written consent obtained to publish from the participant.

REFERENCE

- Jho HD, Kim WK, Kim MH. Anterior microforaminotomy for treatment of cervical radiculopathy: part I disc preserving "functional cervical disc surgery". *Neurosurgery* 2002; **51**: S46-S53. [PMID: 12234429]
- Choi G, Lee SH, Bhanot A, Chae SY, Jung B, Lee S. Modified transcorporeal anterior cervical microforaminotomy for cervical radiculopathy: a technical note and early results. *Eur Spine J* 2007; **16**: 1387-1393. [PMID: 17203272]; [DOI: 10.1007/s00586-006-0286-6]
- Hakuba A. Trans-unco-discal approach. A combined anterior and lateral approach to cervical discs. *J. Neurosurg.* 1976; **45**: 284-291. [PMID: 781189]; [DOI: 10.3171/jns.1976.45.3.0284]
- Hakuba A, Komiyama M, Tsujimoto T, Ahn MS, Nishimura S, Ohta T, Kitano H. Transuncodiscal approach to dumbbell tumours of the cervical spinal canal. *J. Neurosurg.* 1984; **61**: 1100-6. [PMID: 6502239]; [DOI: 10.3171/jns.1984.61.6.1100]
- Hong WJ, Kim WK, Park CW, Lee SG, Yoo CJ, Kim YB, Jho HD. Comparison between transuncal approach and upper vertebral transcorporeal approach for unilateral cervical radiculopathy - a preliminary report. *Minim Invasive Neurosurg.* 2006; **49**: 296-301. [PMID: 1716334]; [DOI: 10.105/s-2006-954828]
- Choi G, Arbatti NJ, Modi HN, Prada N, Kim JS, Kim HJ, Myung SH, Lee SH. Transcorporeal tunnel approach for unilateral cervical radiculopathy: A 2-year follow-up review and results. *Minim Invasive Neurosurg.* 2010; **53**: 127-31. [PMID: 20809454]; [DOI: 10.1055/s-0030-1249681]
- Jacobeus HC. The practical importance of thoracoscopy in surgery of the chest, *Surgery. Gynecology & Obstetrics.* 1921; **32**: 493-500
- Stookey B, Compression of the spinal cord due to ventral extradural cervical chondromas. *Arch Neurol Psych* 1928; **20**: 275-278
- Mixter WJ, Barr JS. Rupture of the intervertebral disc with involvement of the spinal canal. *N Engl J Med* 1934; **211**: 210-215
- Robinson RA, Walker AE, Ferlic DC, *et al.* The results of anterior interbody fusion of the cervical spine. *J Bone Joint Surg Am.* 1962; **44**: 1569-1587
- Cloward RB. The anterior approach for removal of ruptured cervical disks. 1958. *J Neurosurg Spine.* 2007 May; **6(5)**: 496-511. [PMID: 17542522]; [DOI: 10.3171/Spi.2007.6.5.496]
- Korinath MC, Krüger A, Oertel MF, Gilsbach JM.. Posterior foraminotomy or anterior discectomy with polymethyl methacrylate interbody stabilization for cervical soft disc disease: results in 292 patients with monoradiculopathy. *Spine Phila Pa* 1976; May 15 2006; **31(11)**: 1207-1214. [PMID: 16688033]; [DOI: 10.1097/01b.rS.0000217604.02663.59]
- J.-Y. Lee, M. Lo`hr, P. Impekoven, J.-Kobke, R-I. Ernestus, H. Ebel, N. Klug. Small keyhole transuncal foraminotomy for unilateral cervical radiculopathy. *Acta Neurochir (Wien)* 2006; **148**: 951-958. [DOI: 10.1007/s00701-006-0812-7]
- Burman, "Myelography or the direct visualization of the spinal cord and its contents," *The Journal of Bone & Joint Surgery* 1931; **13(4)**: 695-696
- Zdeblick TA, Zou D, Warden KE. Cervical stability after foraminotomy. A biomechanical in vitro analysis. *J Bone Joint Surg (Am).* 1992; **74**: 22-27. [PMID: 173010]
- Jho HD. Microsurgical anterior cervical foraminotomy for radiculopathy: a new approach to cervical disc herniation. *J Neurosurg.* 1996; **84**: 155-160. [PMID: 8592215]; [DOI: 10.3171/jns.1996.84.20155]
- Youn KP, Hong JM, Taek HK, Joo HK. Long-term outcomes following anterior foraminotomy for one- or two-level cervical radiculopathy. *Eur Spine J* 2013; **22**: 1489-1496. [PMID: 2317750]; [DOI: 10.1007/s00586-013-2712-x]
- Ooi Y, Sato Y, Mikanagi K, Morisaki N. Myelography. 1977; **29(5)**: 569-574. [PMID: 141298]
- Vaccaro AR, Ring D, Scuderi G, Garfin SR. Vertebral artery location in relation to the vertebral body as determined by two-dimensional computed tomography evaluation. *Spine* 1994; **19**: 2637-41. [PMID: 7899957]
- Smith MD, Emery SE, Dudley A, Murray KJ, Leventhal M. Vertebral artery injury during anterior decompression of the cervical spine. A retrospective review of ten patients. *J Bone Joint Surg Br* 1993; **75**: 410-5. [PMID: 8496209]
- Jung SS, Chung JC, Park KS. Long-term follow-up results of anterior cervical microforaminotomy. *Korean J Spine* 2010; **7**: 66-72