

## APL Distal Insertion Variability: Cadaveric Variation in Abductor Pollicis Longus Accessory Slip Insertion Site

Michael Dobrowolski, Steven Habusta

Michael Dobrowolski, D.O., MHSA, Lake Erie College of Osteopathic Medicine, 1858 West Grandview Boulevard, Erie, PA 16509, the United States

Steven Habusta, D.O., Lake Erie College of Osteopathic Medicine, 1858 West Grandview Boulevard, Erie, PA 16509, the United States

**Conflict-of-interest statement:** The author(s) declare(s) that there is no conflict of interest regarding the publication of this paper.

**Open-Access:** This article is an open-access article which was selected by an in-house editor and fully peer-reviewed by external reviewers. It is distributed in accordance with the Creative Commons Attribution Non Commercial (CC BY-NC 4.0) license, which permits others to distribute, remix, adapt, build upon this work non-commercially, and license their derivative works on different terms, provided the original work is properly cited and the use is non-commercial. See: <http://creativecommons.org/licenses/by-nc/4.0/>

**Correspondence to:** Michael Dobrowolski, D.O., MHSA, Lake Erie College of Osteopathic Medicine, 1858 West Grandview Boulevard, Erie, PA 16509, the United States.

**Email:** [Michael.dobrowolski@med.lecom.edu](mailto:Michael.dobrowolski@med.lecom.edu)

**Telephone:** +1-267-304-0820

**Fax:** +1-814-868-2489

**Received:** June 1, 2018

**Revised:** July 3, 2018

**Accepted:** July 5 2018

**Published online:** August 28, 2018

### ABSTRACT

Fifteen cadaveric specimens were dissected to identify the insertion site(s) of Abductor Pollicis Longus tendon and accessory slips. Thirteen dissections revealed accessory slips with variable insertion sites leaving only two specimens with a single APL insertion. Eight dissections revealed three APL slips, three with three APL slips and two with four slips. APL slip insertion sites included: 20 slips inserting of the first metacarpal base, 13 slips inserting on the Trapezium and 2 on the Oppenens Pollicis. Variation was noted in

both presents and number of accessory slips of the APL as well as accessory slip insertion sites.

**Key words:** Abductor pollicis longus; Accessory slips; Basal joint motion; Cadaveric; Carpometacarpal joint arthritis; Basal joint arthritis; Joint force

© 2018 The Author(s). Published by ACT Publishing Group Ltd. All rights reserved.

Dobrowolski M, Habusta S. APL Distal Insertion Variability: Cadaveric Variation in Abductor Pollicis Longus Accessory Slip Insertion Site. *International Journal of Orthopaedics* 2018; **5(4)**: 948-951 Available from: URL: <http://www.ghrnet.org/index.php/ijo/article/view/2354>

### INTRODUCTION

Surgical competence relies upon understanding the dynamic interplay between bone and soft tissue anatomy. Anatomy encountered through defined surgical approaches is often predictable. Anatomical variation, itself, can also become predictable with experience<sup>[1]</sup>. Some anatomic variation can explain pathology, while other variations can be utilized in surgical corrections of pathology<sup>[2,3]</sup>. Anatomic variation is well defined in some areas of the body and less-so in others. Further, the development of procedure and prosthesis requires a profound appreciation of form and function. Thoroughly understanding anatomic variation can additionally drive understanding of pathogenesis making possible sound recommendations for primary and secondary preventative measures as well as surgical reconstruction<sup>[4,5]</sup>.

The thumb carpometacarpal joint functions through the transmission of force through the trapezium which has six surfaces, four of which are articular<sup>[6]</sup>. The largest articular surface is that which articulates with the first metacarpal. The basal joint articular surface is said to be saddle shapes (Figure 1)<sup>[7]</sup>. Force is generated by nine muscles which contribute to the thumbs great versatility. These muscles, each to variable extent, contribute to the respective force vectors carried out by the first carpometacarpal joint<sup>[8]</sup>. Not only do the forces vary with variable muscle contributions but also hand, wrist, and forearm positioning in space. Such force vectors across the

CMC joint vary in wrist flexion, extension, radial and ulnar deviation as well as supination and pronation<sup>[9]</sup>.

This study aims to further elaborate upon the complex anatomy of the first carpometacarpal joint and the forces it is susceptible to. Anatomic variation of the abductor pollicis longus in the form of multiple slips has been well documented<sup>[9]</sup>. Less understood is the variability in the insertion sites of these slips and the resultant force vectors derived from varied insertion<sup>[10]</sup>. Here APL slip insertions sites are identified and documented in cadavers.

## MATERIALS AND METHODS

Upon IRB approval and in coordination with our institutions cadaver lab, 15 cadavers, 8 male and 7 females were identified for dissection. Cadavers were embalmed and chosen based upon identification of intact wrist, more specifically, snuffbox anatomy.

Each cadaver was carefully incised over the anatomic snuffbox. A straight radiopalmar incision starting at the radial styloid and extending 3cm-4cm distally. The Extensor Pollicis Longus tendon, Brachioradialis tendon and Abductor Pollicis Longus tendon were identified and followed to their respective insertions. The APL was closely interrogated to assess number of accessory slips. Thereafter, each slip was carefully followed to identify its insertion site.

Standard surgical instruments were used to care out dissection. Careful record of the number of accessory APL slips and each respective insertion site was kept.

Table 1 Record of APL slip insertions sites.

APL Insertion Variation in 15 Cadaver Limbs	Tendon Slips	Percent
limbs with single tendon	2	13.3
dual tendon	8	53.3
triple tendon	3	20
quadruple tendon	2	13.3
limbs total	15	
insertion at metacarpal base	20	57.14
insertion at trapezium	13	37.14
insertion at opponens pollicis	2	5.71
total slips	35	
male	8	
female	7	

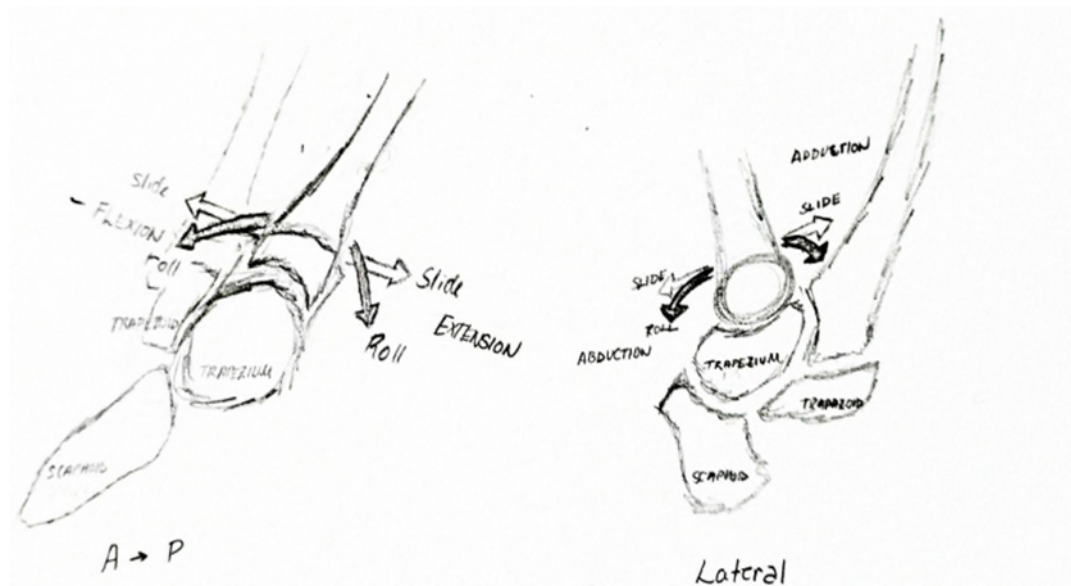


Figure 1 Simplified representation of the basal joint saddle characteristics.

## RESULTS

A total of 15 different cadaver upper extremities were dissected. The APL was identified noting number of accessory slips. Each slip was dissected onto its respective insertion site. Only two APLs were identified with 1 insertion site on the metacarpal base (figure 2). Eight specimens were found to have a single accessory slip which inserted on the trapezium in addition to the insertion site on the base of the metacarpal (Figures 3 and 4). Three dissections revealed two accessory slips which inserted on the trapezium and opponens pollicis fascia (Figure 5), in addition to the insertion site on the base of the metacarpal or with two insertions site to the metacarpal base. Finally, two upper extremities possessed three accessory slips in addition to the metacarpal base insertions site. These included insertions to the metacarpal base, trapezium and opponens fascia with multiple insertions site on the metacarpal base.

## DISCUSSION

Thumb carpometacarpal osteoarthritis has been thought to be associated with several anatomical variations. Evidence from previous research has led to the belief that accessory slip insertion site variation may play some role in the development of carpometacarpal joint osteoarthritis<sup>[11,9]</sup>. This is a less than well-defined anatomic variant and further elaboration is necessitated to prove or refute any association.

There are nine muscles allowing for motion of the thumb. These include; first dorsal interossei, abductor pollicis longus, extensor pollicis brevis, extensor pollicis longus, abductor pollicis brevis, flexor pollicis longus, flexor pollicis brevis, opponens pollicis and the adductor pollicis. Three nerves control these muscles; ulnar, median, and radial, while including innervation for the anterior interosseous nerve and deep branch of the radial nerve. These nine muscular contributions control movement of the thumb interphalangeal joint, metacarpophalangeal joint and carpal metacarpal joint<sup>[8]</sup>. The forces across each respective joint vary in relation to one another depending on each joint respective position and in relation to each other. The muscle has a dynamic role coordinating motion of the thumb and participation in force generation and stabilization as the thumb moves in three dimensions. Each muscles' variable contribution results in summation of force vectors that result in motion that is not in a single

muscle's plane of function but rather in a plane that is the sum of the force vectors of several contributing muscles<sup>[12]</sup>.

With great variability in tendinous insertions and a bitendinous APL being more common than not; a greater understanding of mechanical forces implicated by respective varied tendinous anatomy must be scrutinized<sup>[9]</sup>. As eluded to in the introduction; the muscles providing for motion about the thumb CMC joint

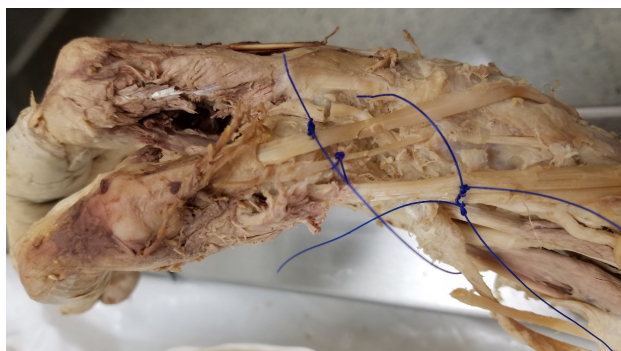


Figure 2 APL single insertion onto the base of the first metacarpal.

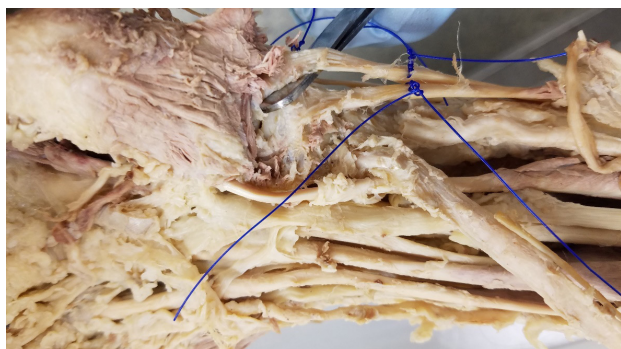


Figure 3 APL insertion onto the trapezium and base of first metacarpal.

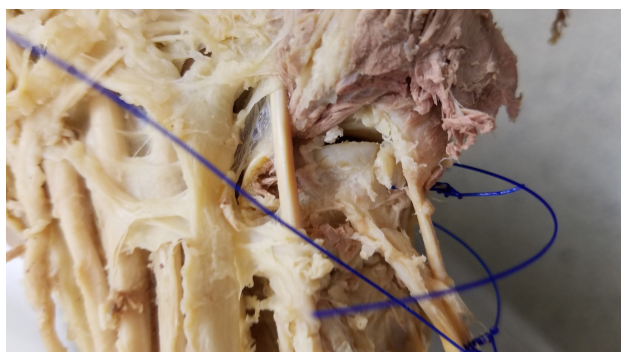

Figure 4 APL insertion on the base of the first metacarpal and slip insertion onto the trapezium.

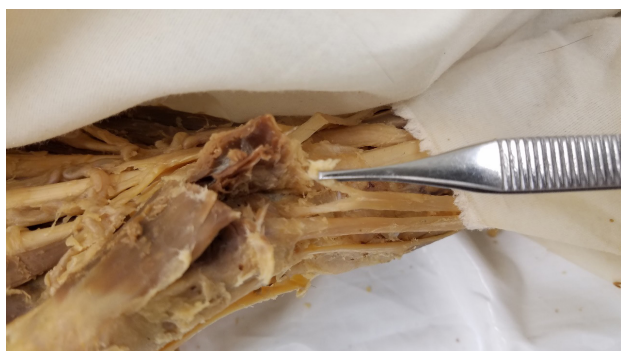

Figure 5 APL insertion onto the base of the first metacarpal and the opponens pollicis fascia.

have multiple functions and act in conjunction with one another to provide for the multiplanar motion of the thumb in space. These muscles, APL included, all act, to various extents to control thumb and hand functions<sup>[13]</sup>. The role of tendinous insertion on joint reactive forces about the basal joint and furthermore their roles in the development of degenerative joint disease and possibly DeQuervains Tenosynovitis may provide for (1): a greater understanding of thumb CMC osteoarthritis; (2): the development of more successful and patient specific treatment options; (3): greater understanding of the thumb CMC joint's motion, function, and influences in anatomic evolution.

Accessory tendinous insertions or the lack thereof may have significant effects on wear pathology. Surgical modification of tendinous insertion about the thumb may provide low morbidity procedural relief in the evolving field of thumb CMC joint arthritis treatment.

Limitations of this study include its size. Although this study provides insight regarding anatomic variability and aides in formulating future research direction, the sheer number of dissected specimen fail to provide any certainty regarding incidence of specific anatomic variation.

With the knowledge of APL accessory slip insertion cite variability further evaluation of the moment arm created by accessory slip variability on a given joint surface can be elaborated upon. Eventually APL accessory slip presence and insertion site variability can be interrogated for possible correlation in the development of pathology including basal joint arthritis. These same variations make prove useful in corrective and reconstructive surgical intervention as well.

## ACKNOWLEDGEMENT

Lake Erie College of Osteopathic Medicine cadaver lab in coordination with Dr. Kulesza. Lake Erie College of Osteopathic Medicine, 1858 West Grandview Boulevard, Erie, PA 16509.

## REFERENCES

1. Chang EY, Chung KC. Outcomes of trapeziectomy with a modified abductor pollicis longus suspension arthroplasty for the treatment of thumb carpometacarpal joint osteoarthritis. *Plast Reconstr Surg.* 2008 Aug; **122**(2): 505-15. [PMID: 18626369]; [PMCID: PMC4412263]; [DOI: 10.1097/PRS.0b013e31817d5419]
2. Roh MS1, Strauch RJ, Xu L, Rosenwasser MP, Pawluk RJ, Mow VC. Thenar insertion of abductor pollicis longus accessory tendons and thumb carpometacarpal osteoarthritis. *J Hand Surg Am.* 2000 May; **25**(3): 458-63. [PMID: 10811749]; [DOI: 10.1053/jhsu.2000.6463]
3. Gonzalez MH. The first dorsal extensor compartment: An anatomic study. *J Hand Surg Am.* 1995 Jul; **20**(4): 657-60. [PMID: 7594297]; [DOI: 10.1016/S0363-5023(05)80286-2]
4. Berger RA. A technique for arthroscopic evaluation of the first carpometacarpal joint. *J Hand Surg Am.* 1997 Nov; **22**(6): 1077-80. [PMID: 9471080]; [DOI: 10.1016/S0363-5023(97)80052-4]
5. Soejima O. Suspensionplasty With the Abductor Pollicis Longus Tendon for Osteoarthritis in the Carpometacarpal Joint of the Thumb. *J Hand Surg Am.* 2006 Mar; **31**(3): 425-8. [PMID: 16516737]; [DOI: 10.1016/j.jhsa.2005.12.010]
6. Humes D, Jahnich H, Rehn A, Compson JP. Osteology of the Trapezium. *J Hand Surg European vol.* 2004; **29B**: 1: 42-45. [DOI: 10.1016/j.jhsb.2003.09.014]
7. Zong-Ming Li, Tang J, Chakan M, Kaz R. Complex, Multidimensional Thumb Movements Generated by Individual Extrinsic Muscles. *J Orthop Res* 2008; **26**: 1289-1295. [DOI: 10.1002/jor.20641]

8. Oudenaarde, Van E. The Function of the Abductor Pollicis Longus Muscle as a joint Stabiliser. *J Hand Surg (British volume)* 1991; **16B**: 420-423. [DOI: 10.1016/0266-7681(91)90017-1]
9. Roy AN, De C, Banerji D, Das S, Chatterjee B, Halder TCJ. A cadaveric study of the first dorsal compartment of the wrist and its content tendons: anatomical variations in the Indian population *Hand Microsurg.* 2012 Dec; **4(2)**: 55-9. [DOI: 10.1007/s12593-012-0073-z]. Epub 2012 Jul 26.
10. Kim YJ, Lee JH, Baek JH. Variant course of the extensor pollicis longus tendon in the second wrist extensor compartment. *Surg Radiol Anat.* 2016 May; **38(4)**: 497-9. [PMID: 26253859]; DOI: 10.1007/s00276-015-1541-5]. Epub 2015 Aug 8.
11. Sugiura S, Matsuura Y, Kuniyoshi K, Nishikawa S, Toyooka T, Mori C, Suzuki T. Anatomic study of the first extensor compartment and relationship between extensor tendon width and it distal insertion. *Surg Radiol Anat.* 2017 Nov; **39(11)**: 1223-1226. [PMID: 28484860]; [DOI: 10.1007/s00276-017-1867-2]. Epub 2017 May 8.
12. Mobargha N, Esplugas M, Garcia-Elias M, Lluch A, Megerle K, Hagert E. The effect of individual muscle loading on the alignment of the base of the thumb metacarpal: a cadaveric study. *J Hand Surg Eur Vol.* 2016 May; **41(4)**: 374-9. [PMID: 26253421]; [DOI: 10.1177/1753193415597114]. Epub 2015 Aug 6.
13. McCann MR, Rust PA, Wallace R. The Stabilising Effect of the Anterior Oblique Ligament to Prevent Directional Subluxation at the Trapeziometacarpal Joint of the Thumb: A Biomechanical Cadaveric Study. *Arch Bone Jt Surg.* 2018 Mar; **6(2)**: 105-111. [PMID: 29600262]