

Delayed Removal of Clavicular Hook Plates; The Effect on Complications and Functional Outcome

Nathan Campbell, Ihab Hujazi, Jeremy Viner, Hans Marynissen

Nathan Campbell, Ihab Hujazi, Jeremy Viner, Hans Marynissen, The Royal Blackburn Hospital, Haslingden Road, Blackburn, BB2 3HH, the United Kingdom

Conflict-of-interest statement: The author(s) declare(s) that there is no conflict of interest regarding the publication of this paper.

Open-Access: This article is an open-access article which was selected by an in-house editor and fully peer-reviewed by external reviewers. It is distributed in accordance with the Creative Commons Attribution Non Commercial (CC BY-NC 4.0) license, which permits others to distribute, remix, adapt, build upon this work non-commercially, and license their derivative works on different terms, provided the original work is properly cited and the use is non-commercial. See: <http://creativecommons.org/licenses/by-nc/4.0/>

Correspondence to: Nathan Campbell, Flat 2/1 1001 Sauchiehall Street, Glasgow, G3 7TZ, the United Kingdom

Email: n.m.campbell@doctors.org.uk

Telephone: +44715941690

Received: May 18, 2018

Revised: June 18, 2018

Accepted: June 19 2018

Published online: October 28, 2018

ABSTRACT

This study aimed to determine whether leaving a clavicular hook plate in-situ for longer than six months is associated with a greater complication rate and reduced function compared to when removed within six months as recommended by manufacturer. Patients treated with a hook plate at our institute between January 2005 and October 2015 were categorised into two groups: removed within six months (group A); removed after six months (group B). Complications, ASES and SST score were compared between the groups. Fifty-two patients were identified with 30 patients in group A and 22 patients in group B. There was no significant difference between the groups in the outcome measures obtained from ASES or SST ($p = 0.52$; $p = 0.33$) or the complication rate ($p = 0.83$). Our study suggests that there is no difference between shoulder function and complication rate when the hook plate was removed after six months compared to when removed within six months.

Key words: Trauma; Clavicular fracture; ACJ dislocation; Hook plate

© 2018 The Author(s). Published by ACT Publishing Group Ltd. All rights reserved.

Campbell N, Hujazi I, Viner J, Marynissen H. Delayed Removal of Clavicular Hook Plates; The Effect on Complications and Functional Outcome. *International Journal of Orthopaedics* 2018; **5(5)**: 968-971 Available from: URL: <http://www.ghrnet.org/index.php/ijo/article/view/2365>

INTRODUCTION

For patients presenting with unstable distal clavicle fractures and acromio-clavicular joint (ACJ) dislocation (Rockwood type III-VI), surgical treatment would be advocated^[1,2,3,4,5]. The clavicular hook plate is a well-known method of treating these types of injury. Following fixation, the plate maintains the anatomical alignment of the clavicle and acromion with its hook extending under the acromion, acting as a lever^[4]. There have been a large number of studies demonstrating satisfactory clinical results and a low rate of complications when using the clavicular hook plate to treat these types of injuries^[1,2,3].

There is a general recommendation by the manufacturer (DepuySynthes) that the hook plate should be removed three months after implantation in order to prevent potential irritation to the acromion or impingement of the rotator cuff. Various studies have also suggested that leaving the hook plate in for a prolonged period of time can lead to osteolysis, plate displacement, impingement and rotator cuff tear^[6,7,8].

There is no current agreed timeframe in which the hook plate should be removed post insertion. In practice hook plates are removed between three and six months post insertion which takes into account both the recommendation by the manufacturer and the delay between listing and elective operating.

Although the studies above mention possible complications of using a hook plate, they do not comment whether the incidence or severity of these complications are related to the amount of time the hook plate is left in situ. Our study aims to determine whether leaving the hook plate in-situ for a period of time longer than six months is associated with a greater incidence of complications and reduced function compared to when removed within six months.

PATIENTS AND METHODS

All patients treated for ACJ dislocation (Rockwood grade III-VI) or distal clavicle fractures with a hook plate at the Royal Blackburn Hospital between January 2005 and October 2015 were identified from surgical records.

The surgery was carried out by one of five senior orthopaedic upper limb surgeons within the department following the method described by the manufacturer. Post-operatively patients were reviewed in the fracture clinic and received regular physiotherapy input. All patients followed strict instruction to avoid over the shoulder movement while the hook plate was in-situ to avoid possible irritation of the rotator cuff. On questioning all patients stated they had abided by this instruction. All patients were seen in clinic 4-6 weeks after hook plate insertion. Patients with clavicular fractures were booked for removal of hook plate when signs of healing were evident on plain radiograph for clavicular fractures. Patients with ACJ dislocation treated with a hook plate were examined 4-6 weeks post-operatively and if non-tender were booked for plate removal.

Exclusion criteria were as follows: insufficient data; patients lost to follow up; patients followed up in a different hospital.

For each patient we obtained the following information: age at injury; date of injury; gender; type of injury; Rockwood classification in ACJ dislocation, time from injury to surgery; time from inserting to removal of hook plate; examination on discharge and complications. Patient's plain radiographs were reviewed retrospectively by the senior author (upper limb surgeon) to assess for osteolysis in the subacromial area. We obtained the patient reported outcome measures using The American Shoulder and Elbow Surgeons (ASES) shoulder assessment and the Simple Shoulder Test (SST). The ASES questionnaire contains ten questions which purely assesses shoulder function in activities of daily living. Each activity is graded as either unable to do, difficult, somewhat difficult or not difficult and the scores obtained for each activity are added up to a maximum best outcome of 30. The SST contains twelve yes or no questions assessing both shoulder pain and function. The maximum score was 12 with each yes response given an additional point. Both questionnaires have been shown to demonstrate reliable and valid outcomes^[9,10]. These questionnaires were posted to all patients identified in the study. A second questionnaire was sent to patients who failed to respond to the first.

Gathered data was entered into a Microsoft Excel database. The patients were divided into two groups based on time from insertion to removal of hook plate. Patients who have the hook plate removed before 6 months were categorised into group A and patients who have the hook plate removed after 6 months were categorised into group B. Simple analysis of each patient group was performed using Microsoft Excel. Complications, ASES score and Simple Shoulder Test score were compared in order to determine whether there is a significant difference in these outcomes between the two groups. An unpaired *t*-Test was used to compare continuous variables and a Chi-squared test was used to compare categorical variables. A *p* value of < 0.05 was deemed significant.

Our study was fully compliant with all relevant ethical guidelines.

RESULTS

64 patients were treated using a hook plate in our institute between January 2005 and October 2015. Full data sets were available on 52 patients; 12 patients who had incomplete data sets were excluded from the study. These 12 patients were either lost to follow up, were

from out of the region and followed up in their local hospital or did not have all of the required information in their notes.

48 patients (92%) were male and 4 (8%) were female. The majority of patients (75%) were between the ages of 20 and 49 (Figure 1).

Of the patients treated with a hook plate, 15% (8 patients) had a clavicular fracture, 25% (13 patients) had Rockwood grade III dislocation, 27% (14 patients) had Rockwood grade IV dislocation and 33% (17 patients) had Rockwood grade V dislocation (Figure 2).

The mean time for hook plate removal was 214 days (median 175 days). The range was 56-770 days. 30 patient (58%) had their hook plate removed within six months. 22 patients (42%) had their hook plate removed after six months. The reasons for the varying lengths of time that the plate remained in situ were multifactorial. A number of patients failed to attend their follow up appointments with many appointments having to be rescheduled. As plate removal was an elective procedure patients also had a choice of a time within reason that suited them for removal.

With regards to complications, 5 patients had pain around the ACJ, 2 patients developed an infection, 10 patients had osteolysis seen on plain radiograph, 3 patients had a problem with their scar, 1 patient had delayed union, 1 patient had none union and 1 patient had calcific tendonitis (Figure 3).

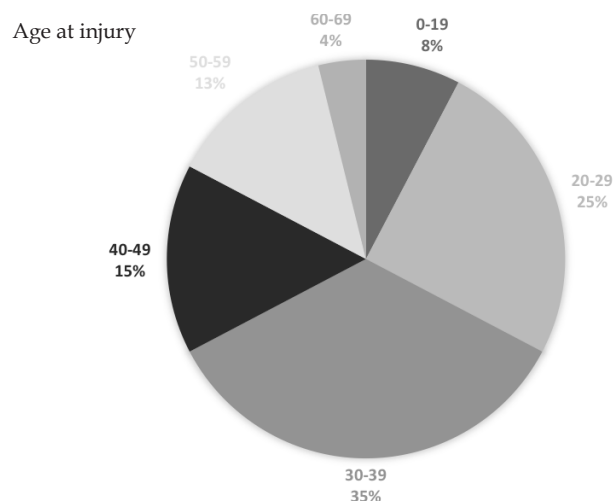


Figure 1 A pie chart demonstrating the ages of patients within the study.

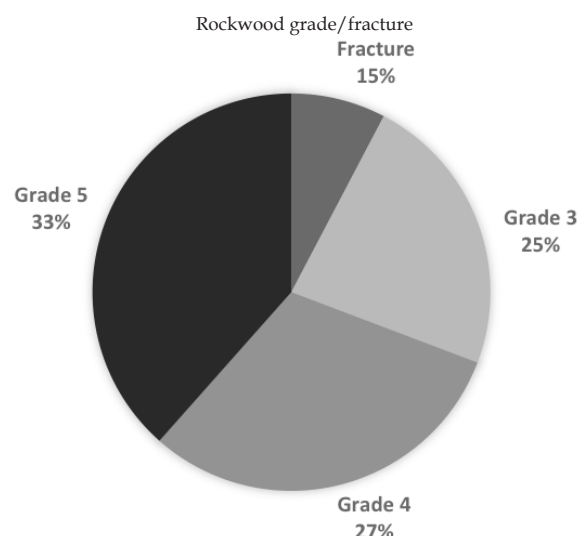


Figure 2 A pie chart demonstrating the injuries sustained by patients within the study.

The ASES and Simple Shoulder test questionnaires were sent to all 52 patients. 11 patients who had their hook plate removed within six months responded (group A). 10 patients who had their hook plate removed after six months responded (group B).

There were no significant differences in demographics (sex, age, type of injury or time from injury to surgery between group A and group B. There was however a significant difference between group A and group B in the mean time taken to remove the hook plate (Table 1).

The reason for the length of time between date of injury and date of surgery is due to the fact that these injuries are not seen as urgent. They are operated on an elective basis as opposed to within a trauma theatre on an urgent basis.

The scores from each questionnaire were obtained and the median score of each group was calculated. The median score for the ASES shoulder assessment was 28 for group A and 29 for group B ($p = 0.52$). The median score for the Simple Shoulder Test was 11 for group A and 12 for group B ($p = 0.33$). There were 6 complications in group A and 5 complications in group B ($p = 0.83$). In group A: 1 patient had ACJ pain and 5 had osteolysis. In group B: 1 had ACJ pain, 2 had problems with their scars, 1 had a non-union and 1 had osteolysis. These results are shown in table 2.

DISCUSSION

The clavicular hook plate has been shown to provide satisfactory clinical outcomes coupled with low complication rates for the treatment of unstable distal clavicle fractures and acromioclavicular joint dislocations (Rockwood grade III-VI)^[1,2,3].

There have been a number of studies that suggest leaving the plate in for a prolonged period of time can lead to complications such as bony erosion, plate displacement, impingement and rotator cuff tear. Lin et al. found that 37.5% of patients treated with a hook plate developed subacromial impingement syndrome and that 40% of these had an associated rotator cuff tear^[7]. They recommend removal as soon as bony and ligamentous healing is achieved. Other studies also advocate early removal of the hook plate^[4,8]. Tan et al. demonstrate that there was a reduction in ACJ pain and an improvement in shoulder function after the removal of a hook plate^[8]. There are currently no studies that evaluate whether leaving the hook plate in for a prolonged period of time results in reduced shoulder function and an increased incidence of complications compared to early removal.

Our study aimed to determine whether leaving the hook plate in for a period of time longer than six months is associated with a greater incidence of complications and reduced function compared to when removed within six months.

We found that only 58% of patients within our series were having their hook plate removed within six months compared to 42% that were having it removed after a period of six months. The delays for removal were multifactorial. A number of patients failed to attend their follow up appointments with many appointments having to be rescheduled. There was also an unavoidable delay between listing for removal and elective operating.

Our study included the entirety of patients treated in our institute by one of five upper limb surgeons. Although it could be argued that different surgeons may have different practices resulting in differences in the length of time taken for hook plate removal, we felt that this gave the study a more pragmatic assessment of the plate in the hands of several surgeons rather than the limitation of single surgeon results. This also makes the study more useful when applied

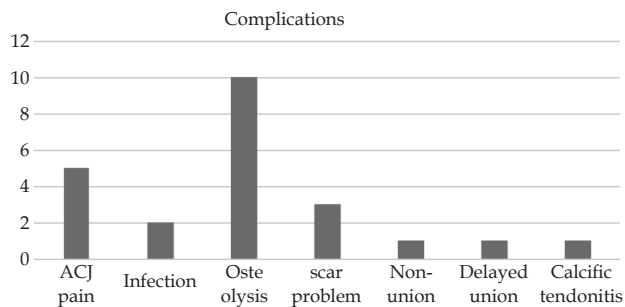


Figure 3 A bar chart demonstrating the number of complication.

Table 1 A table demonstrating data collected from group A and group B.

Demographic	Group A	Group B	Statistical Analysis
Sex	M 9 / F 2	M 9 / F 1	$p = 0.59$
Age (years)	43 (16 - 57)	37.5 (19 - 64)	$p = 0.39$
Rockwood grade (if not fracture)	3 : 40%	3 : 30%	
	4 : 20%	4 : 40%	
	5 : 30%	5 : 20%	
	Fracture: 10%	Fracture: 10%	
Time from injury to surgery (days)	42 (5 - 191)	90 (2 - 511)	$p = 0.38$
Time from initial surgery to removal (days)	141 (57 - 179) SD 36	305 (196 - 770) SD 169	$p = 0.005$

Table 2 A table demonstrating the questionnaire results and complication rate of patients in group A and group B.

Type of Questionnaire	Group A	Group B	Statistical Analysis
ASES (out of 30) median score	28	29	$p = 0.52$
SST (out of 12) median score	11	12	$p = 0.33$
Complications	6	5	$p = 0.83$

to a different institute.

Our study showed that the average scores of both functional questionnaires were better in the patients in group B compared to patients in group A, however this was not statistically significant. This suggests that leaving the hook plate in for a longer period of time did not have any significant impact on shoulder function after hook plate removal in our group of patients.

Our study also showed a larger number of complications in group A when compared to group B. Statistical analysis again showed no significant difference between the two groups. This suggests that leaving the hook plate in for a longer period of time is not associated with an increased incidence of complications in our group of patients.

Out of the 6 patients who had complications in group A, 5 of them had osteolysis. This compared to only one patient who had osteolysis in group B. Osteolysis is a well-known complication following the use of a hook plate and has been shown to be over 30% in some studies^[11]. It is uncertain whether osteolysis itself results in a reduction in shoulder function. A recent study showed no significant difference in shoulder function when comparing patients with osteolysis following hook plate fixation with patients who did not have osteolysis^[12].

As mentioned previously Lin et al. conclude that the hook plate should be removed as soon as bony and ligamentous healing is achieved. Our study however suggests that there are no adverse effects on function or increased complications when left in for a longer period of time. It also suggests that there are as many complications occurring within the first six months when using a

hook plate. Patients were discouraged from abducting their shoulder above 90 degrees when the hook plate was in situ and it is possible that the rate of early complications were higher if patients chose to ignore this advice. Studies have shown that high reaching and heavy activity with the hook plate in situ increases the risk of bony erosion and fixation failure^[11].

As this was a retrospective study over a ten year period our study has some limitations. The response rate that we obtained was low as patients contact information had changed over that period. It was also not possible to thoroughly assess the medical co-morbidities of all patients at the time of the injury and the follow up appointment. 12 patients were excluded from our study as they were either lost to follow up, were followed up out of area or did not have all required information available in their notes.

The parameters used when assessing function were subjective and are based on patient assessment and evaluation using the ASES and SST questionnaires. They assess the general function of the upper limb rather than focusing on the ACJ in particular.

Additionally, it was not possible to thoroughly assess the radiological result of AC joint fixation after hook plate removal as the majority of patients failed to attend follow up after removal. In our series only 10 patients had a check x-ray after the removal of the metal work and none of them showed any evidence of significant subluxation or dislocation.

CONCLUSION

We demonstrated that there was no significant difference between shoulder function and incidence of complications when the hook plate was left in situ for a period of more than six months.

These results need to be collaborated through further studies. We recognise that our response rate was low (40%) and therefore more studies need to be undertaken to further evaluate the effect on shoulder function and complications when leaving a hook plate in for a prolonged period of time.

REFERENCES

- De Baets T, Truijen J, Driesen R, Pittevels T. The treatment of acromioclavicular joint dislocation Tossy grade III with a clavicle hook plate. *Acta Orthop Belg* 2004; **70**: 515-519. [PMID: 15669449]
- Faraj AA, Ketzner B. The use of a hook-plate in the management of acromioclavicular injuries. Report of ten cases. *Acta Orthop Belg* 2001; **67**: 448-451. [PMID: 11822073]
- Flinkkilä T, Ristiniemi J, Hyvönen P, Hämäläinen M. Surgical treatment of unstable fractures of the distal clavicle: a comparative study of Kirschner wire and clavicular hook plate fixation. *Acta Orthop Scand* 2002; **73**: 50-53. [PMID: 11928911]; [DOI: 10.1080/000164702317281404]
- Kashii M, Inui H, Yamamoto K. Surgical treatment of distal clavicle fractures using the clavicular hook plate. *Clin Orthop Relat Res.* 2006; **447**: 158-64. [PMID: 16505714]; [DOI: 10.1097/01.blo.0000203469.66055.6a]
- Tiren D, van Bommel AJ, Swank DJ, van der Linden FM. Hook plate fixation of acute displaced lateral clavicle fractures: mid-term results and a brief literature overview. *J Orthop Surg Res.* 2012; **7**: 2. [PMID: 22236647]; [PMCID: PMC3313877]; [DOI: 10.1186/1749-799X-7-2]
- Chen CH, Dong QR, Zhou RK, Zhen HQ. Effects of hook plate on shoulder function after treatment of acromioclavicular joint dislocation. *Int J Clin Exp Med* 2014; **7**: 2564-70. [PMID: 25356110]
- Lin HY, Wong PK, Ho WP, Chuang TY, Liao YS, Wong CC. Clavicular hook plate may induce subacromial shoulder impingement and rotator cuff lesion--dynamic sonographic evaluation. *J Orthop Surg Res* 2014; **9**: 6. [PMID: 24502688]; [DOI: 10.1186/1749-799X-9-6]
- Tan HL, Zhao JK, Qian C, Shi Y, Zhou Q. Clinical results of treatment using a clavicular hook plate versus a T-plate in near type II distal clavicle fractures. *Orthopaedics* 2012; **35**: 1191-7. [PMID: 22868604]; [DOI: 10.3928/01477447-20120725-18]
- Godfrey J, Hamman R, Lowenstein S, Briggs K, Kocher M. Reliability, validity, and responsiveness of the simple shoulder test: psychometric properties by age and injury type. *J Shoulder Elbow Surg.* 2007; **16**: 260-7. [PMID: 17188906]; [DOI: 10.1016/j.jse.2006.07.003]
- Michener LA, McClure PW, Sennett BJ. American Shoulder and Elbow Surgeons Standardized Shoulder Assessment Form, patient self-report section: reliability, validity, and responsiveness. *J Shoulder Elbow Surg.* 2002; **11**: 587-94. [PMID:12469084]; [DOI: 10.1067/mse.2002.127096]
- Charity RM, Haidar SG, Ghosh S, Tillu AB. Fixation failure of the clavicular hook plate: a report of three cases. *J Orthop Surg (Hong Kong).* 2006; **14**: 333-5. [PMID: 17200540]; [DOI: 10.1177/230949900601400320]
- Sun S, Gan M, Sun H, Wu G et al. Does Subacromial Osteolysis Affect Shoulder Function after Clavicle Hook Plating? *BioMed research International.* [DOI: 10.1155/2016/4085305]