

Management of Calcific Tendinitis of the Long Head of Biceps – Lessons learned

Karthik Karuppaiah, David Elias, Adel Tavakkolizadeh

Karthik Karuppaiah, MS (Ortho), MRCSEd, MCh, MSc, FRCS (T&O), Consultant Orthopaedic Surgeon, King's College Hospital, Denmark hill, London, SE59RS, the United Kingdom

David Elias, FRCR, Consultant Musculo-Skeletal Radiologist, King's College Hospital, Denmark hill, London, SE59RS, the United Kingdom

Adel Tavakkolizadeh, FRCS (T&O), Consultant Orthopaedic Surgeon, King's College Hospital, Denmark hill, London, SE59RS, the United Kingdom

Conflict-of-interest statement: The author(s) declare(s) that there is no conflict of interest regarding the publication of this paper.

Open-Access: This article is an open-access article which was selected by an in-house editor and fully peer-reviewed by external reviewers. It is distributed in accordance with the Creative Commons Attribution Non Commercial (CC BY-NC 4.0) license, which permits others to distribute, remix, adapt, build upon this work non-commercially, and license their derivative works on different terms, provided the original work is properly cited and the use is non-commercial. See: <http://creativecommons.org/licenses/by-nc/4.0/>

Correspondence to: Karuppaiah Karthik MS (Ortho), MRCSEd, MCh, MSc, FRCS (T&O), Consultant Orthopaedic Surgeon, King's College Hospital, Denmark hill, London – SE59RS, the United Kingdom

Email: karthi97@gmail.com

Telephone: +44-7542011723

Received: July 29, 2018

Revised: September 18, 2018

Accepted: September 21 2018

Published online: December 28, 2018

ABSTRACT

CASE: A 55-year-old lady presented with acute right shoulder pain. Investigations, confirmed calcific tendinitis of extra-articular long head of Biceps (LHB). Patient had steroid injection and the symptoms persisted with positive Biceps provocative-tests. We proceeded with surgical exploration for possible biceps tenodesis. Intra-operatively, despite fluid and increased vascularity, there was no calcific lesion and was confirmed

by radiograph. Postoperatively, the symptoms resolved within 4 weeks.

CONCLUSION: The clinical presentation in calcific tendinitis of extra-articular LHB is acute and responds well to steroid injection. Radiographs to confirm the continued presence of the lesion immediately before surgery is essential.

Key words: Biceps tendonitis; Long head of biceps tendonitis; Calcific tendonitis; Shoulder pain

© 2018 The Author(s). Published by ACT Publishing Group Ltd. All rights reserved.

Karthik K, Elias D, Tavakkolizadeh A. Management of Calcific Tendinitis of the Long Head of Biceps – Lessons learned. *International Journal of Orthopaedics* 2018; **5(6)**: 985-988 Available from: URL: <http://www.ghrnet.org/index.php/ijo/article/view/2389>

INTRODUCTION

Calcific tendinitis of the shoulder is a painful condition related to the deposition of calcium carbonate apatite crystals in the tendons around shoulder joint^[1]. The disease most commonly affects supraspinatus and infraspinatus tendons in the shoulder, however involvement of long head of Biceps (LHB) tendon is uncommon. Literature review identified a retrospective radiological review recognising calcific tendinitis of extra-articular LHB^[2], however there were no clinical studies. We report a case of acute calcific tendinitis of extra articular LHB and its management strategy.

STATEMENT OF INFORMED CONSENT

The patient was informed and agreed that the data concerning her case would be submitted for publication, verbally and in writing.

CASE REPORT

A 55-year-old female consultant physician presented to emergency department with an acute onset of right shoulder pain. The intensity of pain was severe and significantly affected her sleep and the function of her dominant upper limb. There was no history of trauma or previous shoulder pathology although she had been gardening three days prior to presentation. She had no significant medical, personal or family history of note and was not on any regular

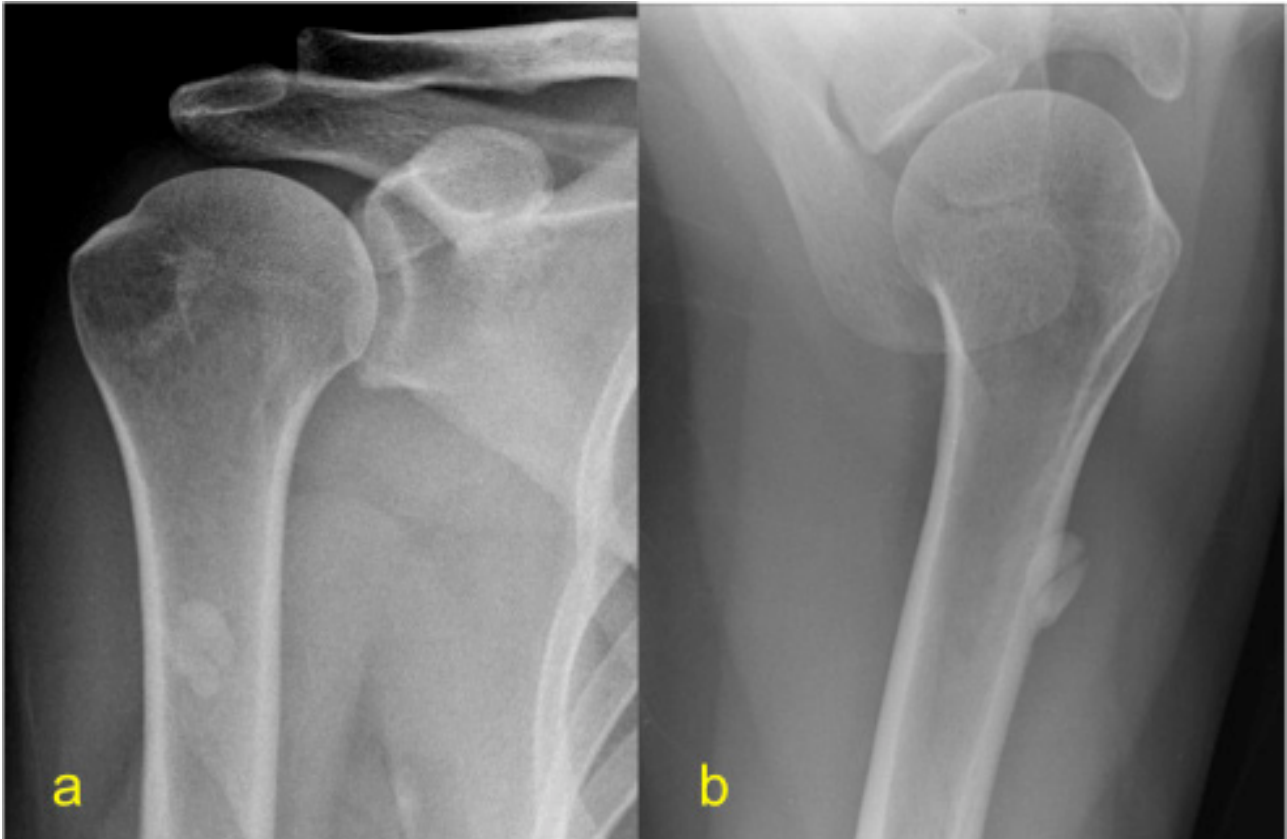


Figure 1 a. Antero-posterior (a) and Axillary (b) radiograph of the proximal humerus demonstrating a 2cm bilobulated calcific lesion over the LHB tendon.

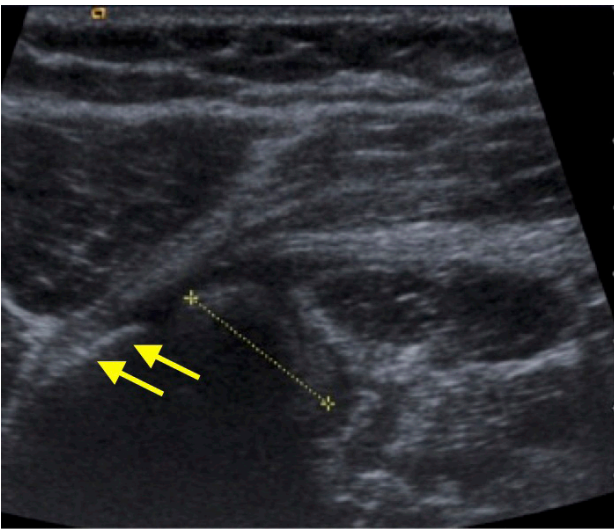


Figure 2 Transverse sonographic image of the upper arm demonstrating the calcific loose body (calipers) within the inferior biceps tendon sheath. Note the humeral cortex (arrows).

medications. Examination of her shoulder revealed exquisite point tenderness over the anterior aspect of the arm (approximately 6-8 cm distal to the antero-lateral acromion) but elsewhere she was non-tender. Her range of movement at the shoulder was limited with forward elevation and abduction of 120° , external rotation of 30° and internal rotation to sacro-iliac joint. Except for strongly positive provocative tests for biceps tendinitis^[3], all other observations and blood tests were unremarkable.

Shoulder radiographs demonstrated a homogenous, well-defined, bilobulated calcific lesion (smooth and oval in shape and approximately 2cm \times 1.5cm) projected over the anterior proximal

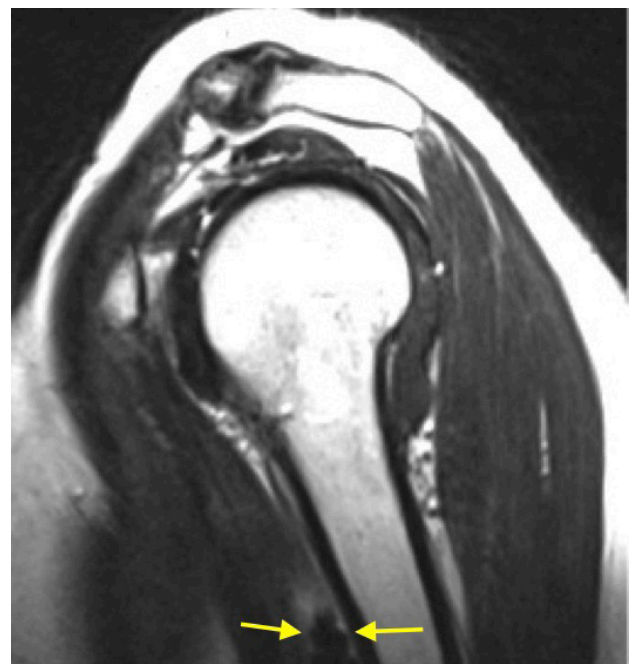

Figure 3 Sagittal oblique T2 weighted MR image of the shoulder demonstrating the calcific lesion within the biceps tendon sheath (arrows).

humerus. The underlying cortex was intact and both the glenohumeral and acromio-clavicular joints appeared normal (Figure 1). Ultrasound examination confirmed the presence of a 2cm bilobulated calcific mass within the long head of biceps tendon sheath (Figure 2). Due to the severity of the pain the patient had an ultrasound guided steroid injection (40 mg Depomedrone and 4mls 0.25% Marcaine) into the sheath adjacent to the calcification. One week later, inspite of

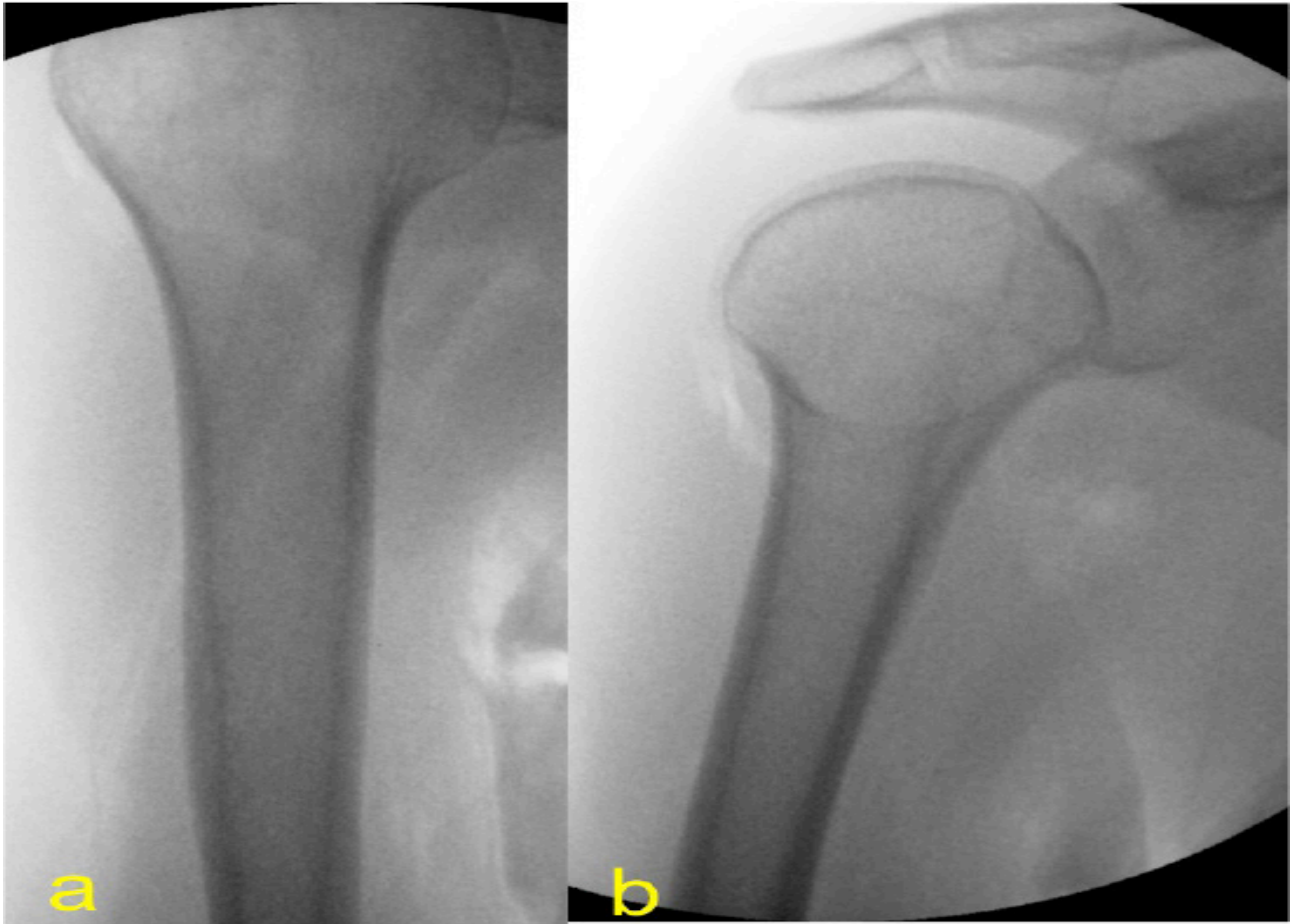


Figure 4 Intra-operative antero-posterior(a) and lateral(b) radiographs of the proximal humerus, revealing the absence of calcific deposit.

conservative treatment with analgesics, rest and steroid injection, the patient continued to suffer with pain. An MRI scan was performed to confirm the extent of the lesion, relationship and integrity of LHB and to rule out other shoulder pathologies. The scan demonstrated a calcific lesion in the intact inflamed LHB tendon in an otherwise normal shoulder joint (Figure 3). As the symptoms persisted and there were concerns about mechanical damage to the LHB leading to rupture of the biceps tendon, a decision was made to excise the calcification surgically and if needed to proceed to biceps tenodesis.

Three weeks following the presentation and steroid injection the intensity of the pain had reduced, however the symptoms and concerns over tendon rupture persisted. Surgery was performed under general anaesthetic using a low deltopectoral approach to expose the long head of biceps tendon. However, when the long head of biceps tendon sheath was incised, despite significant fluid and increased vascularity, there was no calcific lesion. An image intensifier was utilised intraoperatively to locate the lesion but failed to show any calcification (Figure 4). Postoperatively, the patient's symptoms improved and she became completely asymptomatic with full resolution of symptoms within 4 weeks. At the final follow-up of one year there were no recurrence of symptoms and shoulder function was normal.

DISCUSSION

Calcific tendinitis of the long head biceps tendon is uncommon^[4]. Though there are reports about calcific tendinitis at the origin of LHB^[4-7], no clinical studies has been reported in the English literature on the management of extra-articular LHB calcific tendinitis. Our case

report describes an unusual location of calcific tendinitis within the extra-articular portion of the long head of biceps tendon sheath and its management.

The clinical presentation of extra-articular LHB calcific tendinitis is acute and is similar to the calcific tendinitis of the rotator cuff. However the clinical presentation of the intra-articular biceps/labral complex calcific tendinitis is chronic shoulder pain and all except one patient⁴ needed arthroscopic surgical debridement^[5-7]. A literature review only revealed one study, by Goldman, that reported calcific tendinitis in this region. Goldman reviewed 119 radiographs of shoulder calcific tendinitis and described for the first time calcific tendinitis within the proximal biceps tendon distal to the glenohumeral joint^[2]. This was a radiological study and the diagnosis was made using radiographs. There were no clinical details about the patients and there was no confirmation with further imaging to rule out heterotopic ossification or loose body. The average size of the lesions in their study was four millimetre and is much smaller than our case.

The tendon muscle junction is approximately 6.6cm below the lesser tuberosity, at the junction between the upper and middle thirds of the humerus^[8]. Why calcific tendinitis should occur within the biceps tendon at this level is unclear but it has been hypothesised that compression of the tendon, in this region, by two strong fascial bands (the proximal lateral intramuscular septum and brachial fascia) may cause hypoperfusion, decreased oxygen tension and thus calcific tendinitis^[2]. Risk factors for biceps tendonitis per se comprise rotator cuff disease, glenohumeral arthritis, bone spur formation or deformation of the tuberosities (following trauma,) a prominent supratubercular ridge or shallow bicapital groove^[3-7]. However, our patient had normal bony anatomy, no significant degenerative

changes and an intact rotator cuff.

First line treatment in symptomatic calcific tendonitis of the shoulder is non-operative and this comprises rest, non-steroidal anti-inflammatories, steroid injections and physiotherapy^[3]. In our patient, after conservative treatment, there was marginal improvement of symptoms around three weeks later. As the patient had persistent pain and calcification in their LHB, along with concern about tendon rupture guided us to proceed with surgery. Intraoperatively, after thorough exploration of the biceps sheath and use of image intensifier we found the calcific deposit was resorbed. Looking back at this case, if we had repeated the radiograph before proceeding with the surgery, in absence of any calcification, we would have continued with conservative treatment.

CONCLUSION

Our case highlights an unusual cause of acute anterior shoulder pain due to calcific tendinitis of extraarticular LHB. Unlike the calcific tendinitis at the origin of LHB, the clinical presentation is acute and responds well to conservative treatment with steroid injection. Before embarking on surgery for removal of calcific deposits, continued presence of the lesion should be confirmed with radiographs and we have incorporated this change in our practise.

REFERENCES

1. J. Hamada, K. Tamai, W. Ono, K. Saotome, "Does the nature of deposited basic calcium phosphate crystals determine clinical

- course in calcific peri-arthritis of the shoulder?" *J Rheumatol.* 2006 Feb; **33**(2): 326-32. [PMID: 16465665]
2. A. B. Goldman, "Calcific tendinitis of the long head of the biceps brachii distal to the glenohumeral joint: plain film radiographic findings," *AJR Am J Roentgenol.* 1989 Nov; **153**(5): 1011-6. [PMID: 2801418]; [DOI: 10.2214/ajr.153.5.1011]
3. Churgay CA. Diagnosis and treatment of biceps tendinitis and tendinosis. *Am Fam Physician.* 2009 Sep 1; **80**(5): 470-6. [PMID: 19725488]
4. Amri A, Yukata K, Nakai S, Hara M, Yamanaka I, Hamawaki J. Spontaneous resorption of calcification at the long head of the biceps tendon. *Shoulder Elbow.* 2015 Jul; **7**(3): 190-2. [PMID: 27582978]; [PMCID: PMC4935155]; [DOI: 10.1177/1758573214567559]
5. Ji JH, Shafi M, Kim WY. Calcific tendinitis of the biceps-labral complex: a rare cause of acute shoulder pain. *Acta Orthop Belg.* 2008 Jun; **74**(3): 401-4. [PMID: 18686469]
6. Cho NS, Rhee YG. Calcification in superior glenoid labrum of the shoulder: a case report. *J Shoulder Elbow Surg.* 2007 Nov-Dec; **16**(6): e35-7. Epub 2007 May 16. [PMID: 17509902]; [DOI: 10.1016/j.jse.2006.11.002]
7. Kim KC, Rhee KJ, Shin HD, Kim YM. A SLAP lesion associated with calcific tendinitis of the long head of the biceps brachii at its origin. *Knee Surg Sports Traumatol Arthrosc.* 2007 Dec; **15**(12): 1478-81. Epub 2007 Apr 25. [PMID: 17457577]; [DOI: 10.1007/s00167-007-0323-y]
8. Gray H, Goss CM. Anatomy of the human body, 7th ed. Philadelphia: *Lea & Febiger*, 1965: 483-499

Peer Reviewer: Anestis Iossifidis