

Arthroscopic Transosseous Suture Without Implant for Rotator Cuff Tears: Absorbable Mattress Sutures Versus Non-Absorbable Sutures

Shigehito Kuroda, Noriyuki Ishige, Shuhei Ogino, Takeo Ishii

Shigehito Kuroda, Noriyuki Ishige, Shuhei Ogino, Takeo Ishii, Matsudo Orthopaedic Hospital, 1-161 Asahi-cho, Matsudo, Chiba 271-0043, Japan

Conflict-of-interest statement: The author(s) declare(s) that there is no conflict of interest regarding the publication of this paper.

Open-Access: This article is an open-access article which was selected by an in-house editor and fully peer-reviewed by external reviewers. It is distributed in accordance with the Creative Commons Attribution Non Commercial (CC BY-NC 4.0) license, which permits others to distribute, remix, adapt, build upon this work non-commercially, and license their derivative works on different terms, provided the original work is properly cited and the use is non-commercial. See: <http://creativecommons.org/licenses/by-nc/4.0/>

Correspondence to: Shigehito Kuroda, MD, 1-161 Asahi-cho, Matsudo, Chiba 271-0043, Japan.

Email: kenzan@matsudoseikei.jp

Telephone: +81-47-344-3171

Fax: +81-47-330-4630

Received: September 5, 2018

Revised: October 31, 2018

Accepted: November 2 2018

Published online: December 28, 2019

ABSTRACT

AIM: In 2005, we developed an anchorless technique for arthroscopic transosseous rotator cuff repair without implant. We aimed to clarify the differences in clinical outcomes and retear rates between patients receiving absorbable mattress sutures and those receiving non-absorbable sutures.

MATERIALS AND METHODS: In this retrospective cohort study, we analyzed 131 cases in which absorbable mattress sutures were used and 384 cases in which only non-absorbable sutures were used. Three 2-mm Kirshner wires with perforated tips were inserted through the inferior margin of the greater tuberosity into the medial edge of the footprint. After pulling the rotator cuff stump laterally, 3 Kirshner wires were threaded through the rotator cuff and skin. Five

threads were passed through 3 bone tunnels using the perforated tips of the Kirshner wires. The surgery was completed by inserting 2 mattress sutures and 3 bridging sutures. In addition to retear rates, the surgical cost of other transosseous methods was investigated.

RESULTS: The retear rate was 3.1% using absorbable mattress sutures and 6% using non-absorbable suture only. It was 12% using the hollow needle method and 3.7% using the ArthroTunneler method. The surgical cost was \$9–12 for our procedure, \$121 for the hollow needle method, and \$600 for the ArthroTunneler method.

CONCLUSIONS: We found that using absorbable thread for mattress sutures reduced the retear rate. A big advantage of our technique is that it is inexpensive because the only surgical materials required are suture threads.

Key words: Shoulder joint, Rotator cuff, Arthroscopy, Suture techniques

© 2019 The Author(s). Published by ACT Publishing Group Ltd. All rights reserved.

Kuroda S, Ishige N, Ogino S, Ishii T. Arthroscopic Transosseous Repairs without Implant for Rotator Cuff Tears. *International Journal of Orthopaedics* 2019; 6(1): 1003-1012 Available from: URL: <http://www.ghrnet.org/index.php/ijo/article/view/2414>

INTRODUCTION

Although anchor sutures are the mainstay of arthroscopic rotator cuff repair, their limitations include high cost and difficulty in reoperating on patients with retears. Since 2005, we have performed arthroscopic transosseous rotator cuff repairs without using implants, this procedure being inexpensive and having good clinical outcomes. When performing this procedure, we aim to duplicate the open rotator cuff repair.

In 2013 we reported in detail the technique and clinical outcomes of 384 shoulders undergoing arthroscopic transosseous suture repair of the rotator cuff without the use of anchors using 3 linear bone tunnels and 5 non-absorbable polyester threads^[1]. In that study we suggested that the use of absorbable mattress sutures should be considered to obtain satisfactory initial fixing power without applying excessive tension on the rotator cuff. Since May 2015, we have used absorbable

polyglycolic acid (PGA) thread for mattress sutures in all patients. The clinical outcomes and retear rate of 131 shoulders in which PGA threads were used for mattress sutures who were observed for more than 2 years were compared with 384 shoulders in which only polyester threads were used in the same procedure. In addition, other arthroscopic transosseous suture techniques for the rotator cuff repair were examined.

The aim of this study was to determine the outcomes and surgical costs of a cohort with absorbable mattress sutures, a cohort with all non-absorbable sutures, and evaluate other arthroscopic transosseous suture techniques.

METHODS

Surgical Technique

The patient is placed in the lateral position under 2-kg indirect arm traction. We use five portals for this procedure: anterior ([A] in Figure 1), antero-lateral [AL], postero-lateral [PL], Posterior [P] and lower [Lo] (Figure 1). After subacromial decompression and adequate footprint decortication, the aiming tip of a drill guide is passed through the anterolateral portal and placed on the medial edge of the footprint. Three Kirshner wires (2 mm) with perforated tips are inserted from the inferior margin of the greater tuberosity into the medial edge of the footprint at a superiorly directed angle of 60-65° (Figure 2A). Pulling the rotator cuff stump peripherally with a grasper, 3 Kirshner wires are threaded through the rotator cuff and skin (Figure 2B). When the rotator cuff stump cannot be pulled to the footprint, expanding decortication of the footprint to 1 cm medially enables repair of large rotator cuff tears.

A nylon thread attached to the 65-cm PGA thread for the mattress suture and 65-cm polyester thread for the bridging suture is passed through the perforations of the anterior and posterior Kirshner wires. Then nylon loops connected doubly in series are passed through the central Kirshner wire (Figure 3A). To clarify suture management, the thread ends are added according to alphabetical symbols, [m]: mattress suture, [n]: nylon loops connected doubly in series, [ab]: anterior bridging suture, [pb]: posterior bridging suture. The sutures are then pulled out through the lower portal, passing through the rotator cuff and the bone tunnels in the greater tuberosity (Figure 3B). The anterior and posterior PGA and polyester threads, which have been pulled out through the lower portal, are knotted after which the distal part of the PGA thread is cut and pulled up. The knots

are anchored at the inferior margin of the greater tuberosity (Figure 4). The central nylon loops and 2 PGA threads inserted through the rotator cuff are then are pulled out through the anterolateral portal (Figure 5A, B). Next, the 2 PGA threads extracted through the anterolateral portal are drawn through the lower portal passing through the central bone tunnel using the nylon loops (Figure 6A). These 2 PGA threads are used for the mattress suture. After returning the nylon loops to the starting position, a 65-cm polyester thread for the central bridging suture is inserted into the nylon loop (Figure 6B) and drawn through the central bone tunnel and lower portal (Figure 6C). Then, the 2 PGA threads are tied with polyester thread using square knots and this polyester ligature is twisted around the mattress sutures and ligated using square knotting. This process is repeated once and the resulting knot is inserted into the inferior margin of the greater tuberosity and tightened using a knot pusher (Figure 7). The upper limb of the central bridging suture attached to the rotator

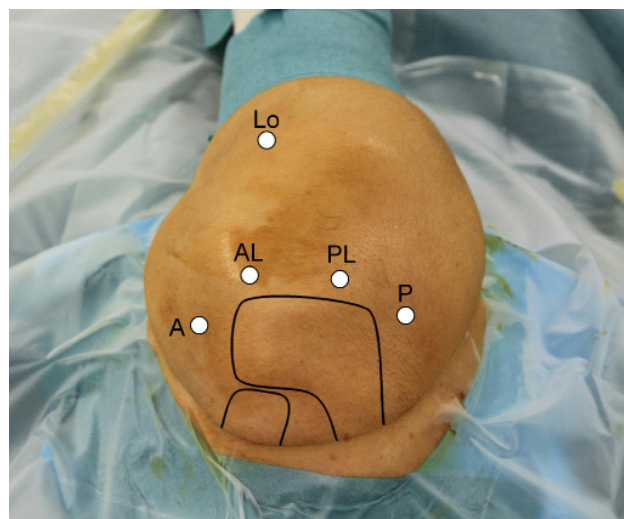


Figure 1 Portals.

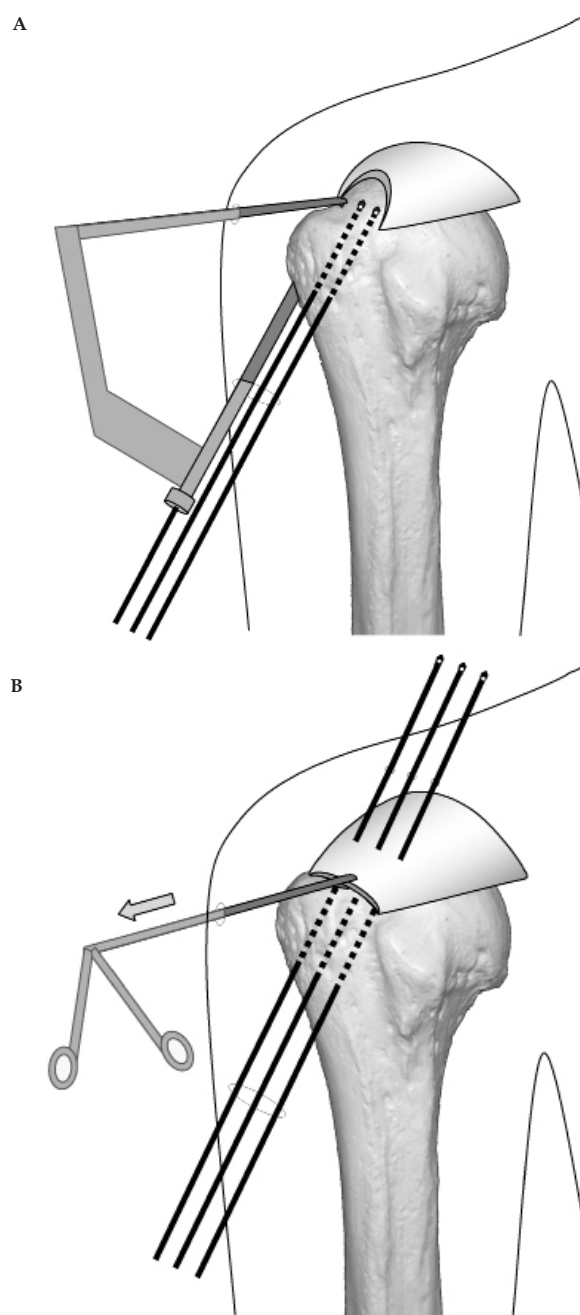


Figure 2 Insertion of Kirshner wire.

cuff is then pulled out through the lower portal (Figure 8A). This limb is tied to the other limb traversing the central bone tunnel in the same manner as the mattress suture (Figure 8B). Because the

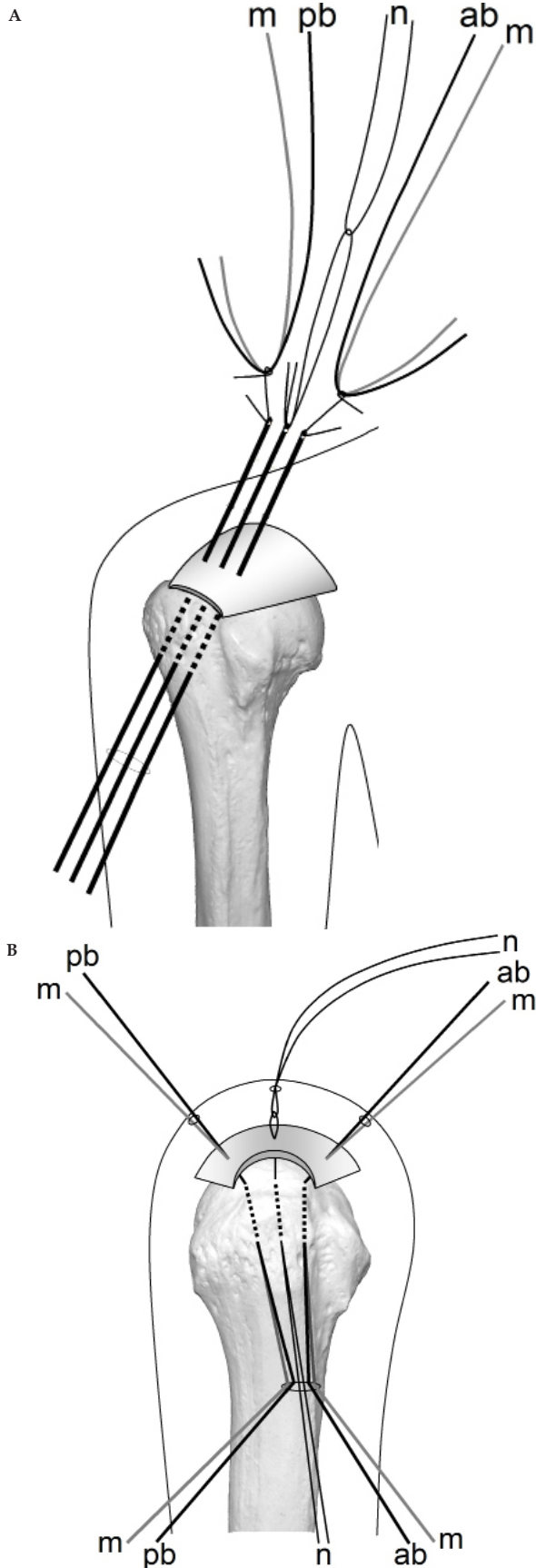


Figure 3 Downward pull out of sutures.

anterior and posterior limbs bound to the bridging suture cannot be pulled out directly through the lower portal, they are first pulled out via the anterolateral portal (Figure 9A) and then the lower portal (Figure 9B). The limb extracted through the lower portal and the other limb passing through the anterior bone tunnel are similarly tied (Figure 9C). For the posterior bridging suture, the same process was repeated. The mattress and bridging sutures are further tightened and secured with 3 half-hitch knots. In sum, the torn rotator cuff is pulled to the footprint by 2 PGA mattress sutures (purple threads in Figure 10A) and compressed tightly to the footprint with 3 polyester bridging sutures (green threads in Figure 10A). Extra mattress and bridging sutures can easily be added by placing the aiming tip of the drill guide on the rotator cuff after suturing. When the AP diameter of the rotator cuff tear exceeds 3 cm, 2 extra bridging sutures are added (Figure 11). Tenotomy and tenodesis of the long head of the biceps brachialis were not performed in any of the patients.

A soft brace holding the arm in 45° of flexion and 45° of internal rotation is used for 3 weeks. Passive elevation is started 2 weeks after surgery by a physiotherapist. Active elevation is permitted at 4 weeks and the patients are permitted to drive 6 weeks after surgery. In shoulders with tears greater than 3 cm, the duration of postoperative fixation and start times of passive elevation, active elevation, and driving are each extended by 2 weeks.

Study Methods

This was a retrospective cohort study. Between April 2015 and May 2016, we performed operations on 161 consecutive patients (161 shoulders) with complete rotator cuff tears. Indications for the operation were (1) a complete rotator cuff tear and (2) a tear less than 5 cm in medial-to-lateral diameter. The technique was contraindicated if the stump of the torn rotator cuff did not emerge across the top of the humeral head under traction. Criteria for inclusion in this study were: (1) UCLA assessment 2 years after surgery, (2) magnetic resonance imaging (MRI) performed 1 to 1.5 years after surgery, and (3) complete surgical records including accurate intraoperative measurement of the rotator cuff tear size. Exclusion criteria were: (1) previous fracture, (2) revision rotator cuff repair, and (3) preoperative cervical radiculopathy or axillary nerve palsy. Ultimately 131 patients (131 shoulders; 81 right and 50 left) (64 women and 67 men) were

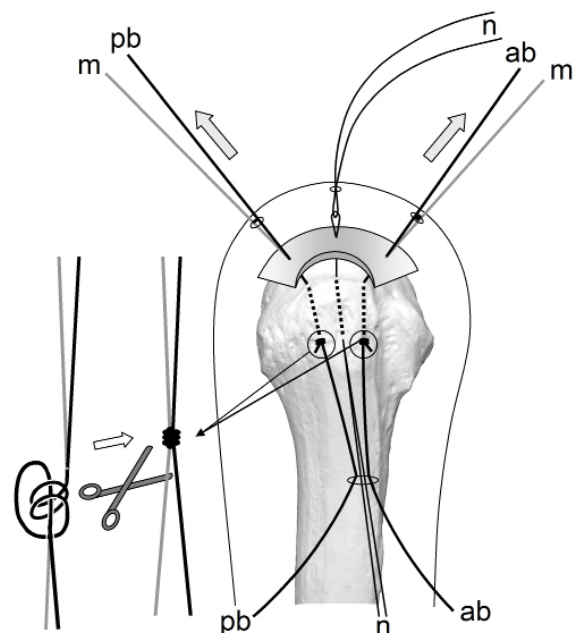


Figure 4 Anchoring of sutures.

included in the study. The follow-up rate was 81.4%. Average patient age at the time of surgery was 66 years (range, 39-84 years). The medial-to-lateral diameter of the tear was < 1 cm in 25 shoulders, 1-3 cm in 83 shoulders, and 3-4.8 cm in 23 shoulders (Table 1).

This was a single center study. The procedure was performed by 3 different surgeons. Minimum follow-up duration was 2.1 years (mean, 2.6 years; range, 2.1-3.2 years). The 30 excluded patients (30 shoulders) did not have a 1-year postsurgical MRI, 2-year UCLA evaluation, or intraoperative tear measurement or they met the exclusion criteria or were lost to follow-up. MRI of the rotator cuff suture site 1 year after surgery was used to assess for retears, which were classified according to the system of Sugaya *et al*^[2]. Sugaya Type IV denotes the presence of a minor discontinuity in the oblique coronal and oblique sagittal views on T2-weighted images and suggests a small tear. Type V denotes the presence of a major

discontinuity and suggests a medium or large tear. Before and 2 years after surgery we evaluated the shoulders using total scores on the UCLA Shoulder Rating Scale^[3] with 35 being the best possible score. To assess for axillary nerve damage, electromyography (EMG) of the deltoid muscle was performed before and 1 month after surgery in all patients. We watched carefully for any problems with the bone tunnels throughout surgery.

The comparison cohort comprised 380 patients (384 shoulders; 258 right and 126 left) 174 women and 206 men) in whom polyester threads had been used for all sutures; this cohort was reported in 2013. Criteria for inclusion and exclusion were the same as for this study. Average patient age at the time of surgery was 67 years (range, 35-86 years). The medial-to-lateral diameter of the tears was < 1 cm in 95 patients (96 shoulders), 1-3 cm in 216 patients (219 shoulders), and 3-4.7 cm in 69 patients (69 shoulders) (Table 1).

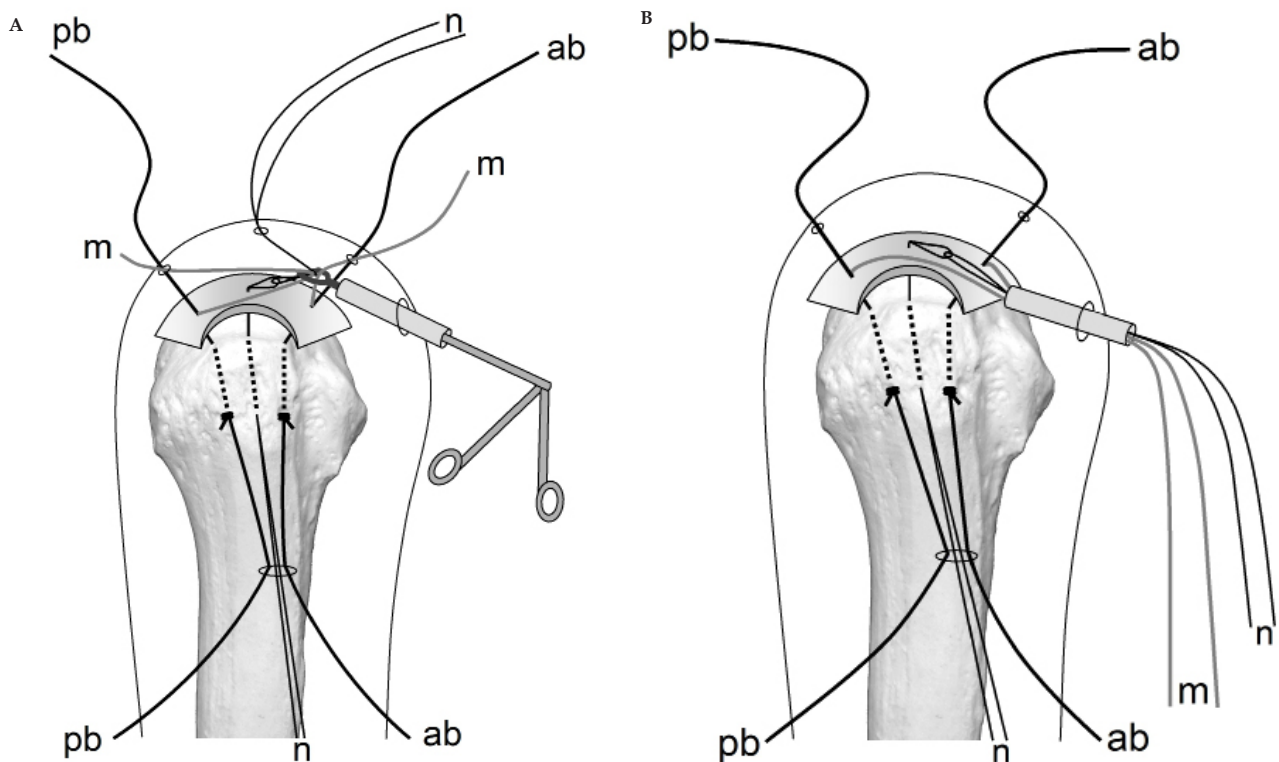


Figure 5 Lateral pull out of mattress sutures and nylon loops.

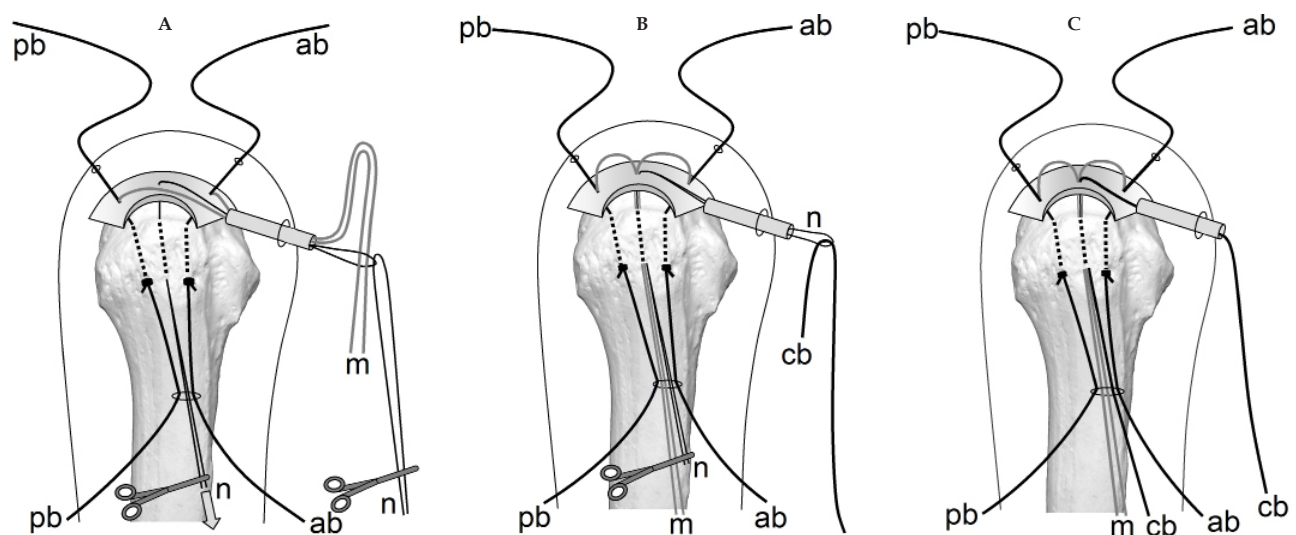


Figure 6 Relay of mattress and central bridging sutures.

We compared the outcomes of our procedure using PGA threads for mattress sutures with those of the same procedure using only polyester threads with Mann-Whitney and Chi square tests (EZR on R commander Version 1.37). Significance was set at $p < 0.05$

RESULTS

In the cohort in which PGA thread was used for mattress sutures, the preoperative mean UCLA total shoulder score was 19 (range, 6-27) and the postoperative score was 32.7 (range, 13-35) (Table 1, 2). Postoperative results were excellent (34-35) in 57.3%, good (29-33) in 35.1%, and poor (< 29) in 7.6%. The mean preoperative UCLA score was 20 and postoperative score 34.3 for small tears. They were 19.1 and 32.5, respectively for medium tears (1-3 cm), and 17.3 and 31.4, respectively for large tears (> 3 cm). Using MR images for screening, we identified Sugaya Type IV and V tears in 4 patients (4 shoulders) (3.1%). These were considered retears. Based on the size of the original tear, the incidence of re-tear was 0% (0/25) for small tears (< 1 cm), 2.4% (2/83) for medium tears (1-3 cm), and 8.7% (2/23) for large tears (3-4.8 cm) (Table 2). In all 4 cases of re-tear, pain was mild and the patients did not want revision surgery. No damage to the axillary nerve was detected by postoperative EMG in any patient. No breakage of the bone tunnel by the suture was encountered. The mean operating time was 111 minutes (range, 56-176).

In the cohort in which polyester threads were used for all sutures, the preoperative mean UCLA total shoulder score was 19.1 (range, 5-30) and the postoperative score was 32.7 (range, 15-35) (Table 1, 2). Postoperative results were excellent in 55%, good in 33%, and poor in 12%. The mean preoperative UCLA score was 21.6 and postoperative score 34.3 for small tears. They were 20.2 and 33.5, respectively for medium tears, and 12.1 and 28, respectively for large tears. Postoperative MR images showed Sugaya Type IV and V tears in 24 patients (24 shoulders) (6%). The incidence of re-tear was 4% (4/96) for small tears, 5% (11/219) for medium tears, and 13% (9/69) for large tears (Table 1). The mean operating time was 105 minutes.

DISCUSSION

First described by Codman in 1911^[4], open rotator cuff repair using transosseous sutures has been considered the gold standard of rotator cuff repair because of good long-term postoperative results. In 2005, we developed an anchorless technique for arthroscopic transosseous suture rotator cuff repair. It is economical because the only extra cost involved is that of the suture materials. In addition, problems related to anchors such as anchor dislodgement, expensive costs, and difficult reoperation are eliminated. In 2013 we reported the postoperative outcomes of the arthroscopic transosseous suture repair of the rotator cuff using 3 linear bone tunnels from the inferior

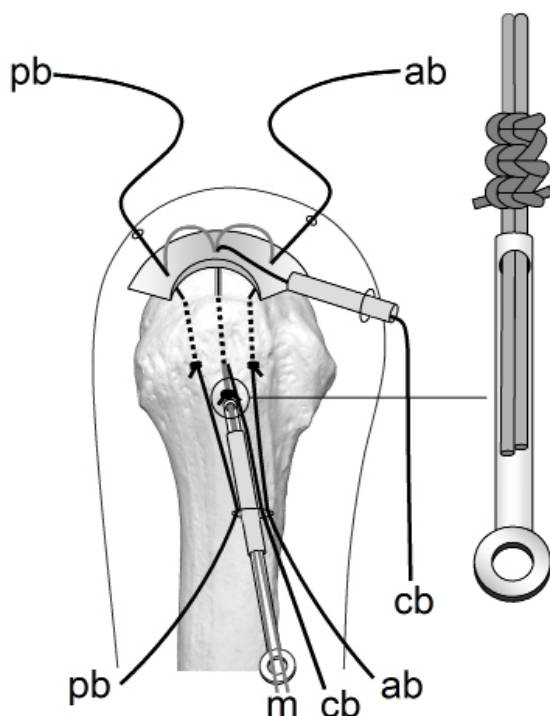


Figure 7 Knot tying of mattress sutures.

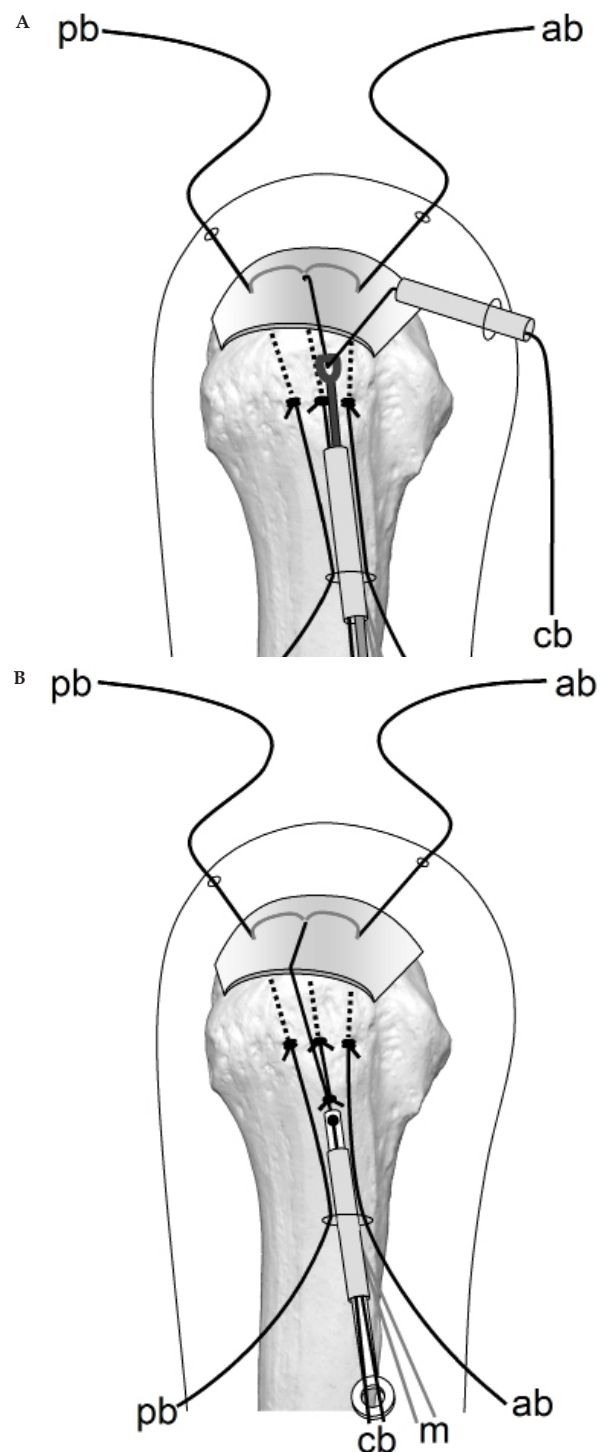


Figure 8 Central bridging suture.

margin of the greater tuberosity to medial edge of the footprint [1]. In that study, we used all polyester threads for mattress and bridging sutures. Since April 2015, we have used PGA threads for mattress sutures to gain the initial cuff securing force and avoid excessive tension on the rotator cuff. In addition to our method, other methods for arthroscopic transosseous repair of the rotator cuff without implant using an ArthroTunneler[®] [5-10], hollow needle [11-13], special equipment [14-15], and anterior cruciate ligament guide [16] have been reported. However, there have been on 4 reports describing clinical outcomes from arthroscopic transosseous repair of the rotator cuff without implant in more than 50 patients [1,10,11,13].

We compared relevant patient characteristics, UCLA score, and retear rate between our technique using polyester thread for all sutures and using PGA thread for mattress sutures. There was no significant difference in age at surgery, sex, affected side, tear size, and preoperative UCLA score between the cohorts using PGA threads for mattress sutures and the cohort using all polyester threads. These 2 cohorts matched perfectly (Table 1). There were no significant differences in postoperative UCLA scores between these cohorts. However, the retear rate was significantly lower in the cohort used

PGA threads for mattress sutures (Table 2).

We compared the retear rate and surgical cost of 3 other arthroscopic transosseous repair techniques. The age at the surgery and the sex were similar in these 3 cohorts; however, there were no specific descriptions of tear size. The retear rate was 12% in Matis's report [11] using a hollow needle and 3.7% in Flanagin's report [10] using an ArthroTunneler[™] (Tornier, Edina, MN, USA) (Table 3). Hubert *et al* reported that the retear rate is equivalent to open transosseous repair [13]. In a review of 1252 cases in 2010, Duquin *et al* stated that the recurrence rate of open transosseous repair was 17% for small tears, 20% for medium tears, 18% for large tears, and 44% for global tears. In the same paper they state that the retear rate of the double row anchor method ranged from 7% for tears < 1 cm to 41% for tears > 5 cm [17]. With our method using PGA threads for mattress sutures, there were no retears for tears < 1 cm and the retear rate was 2.4% for 1-3 cm tears and 8.7% for 3-4.8 cm tears.

In our procedure, mattress sutures are required to draw the cuff stump peripherally and apply adequate initial fixing power to the footprint. Mattress sutures are used to firmly secure the rotator cuff at the inner edge of the footprint. As a result, the cuff is subjected to a

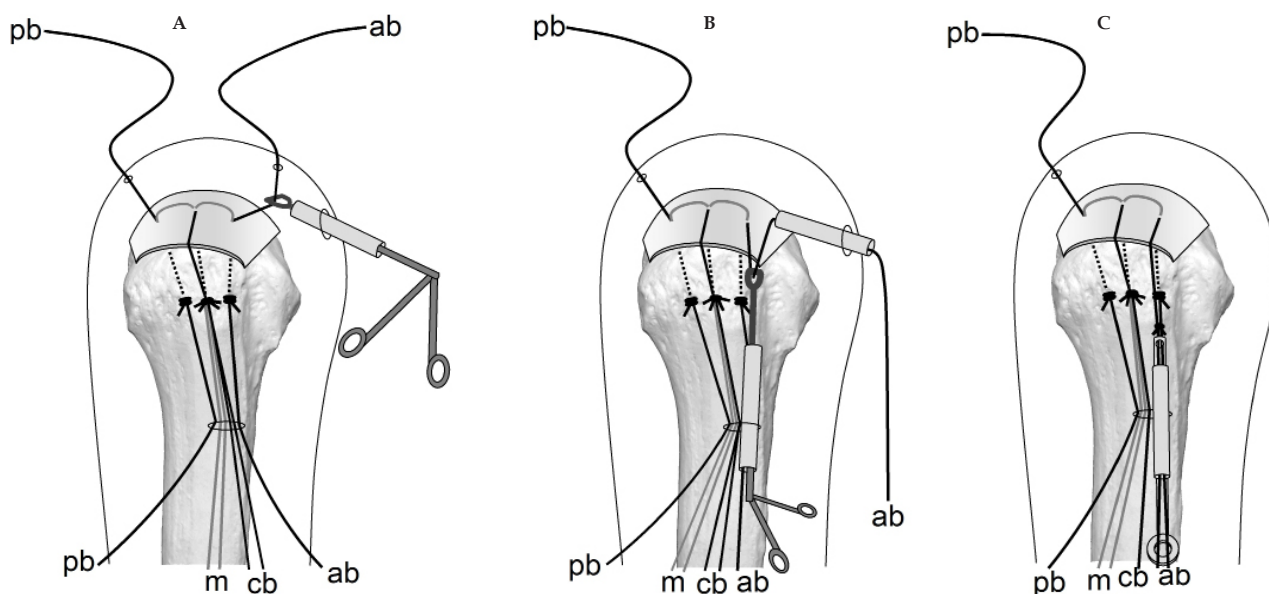


Figure 9 Anterior bridging suture.

Table 1 Two cohorts of our method using PGA mattress sutures or only polyester sutures.

Suture material	Cohort Size	Age	Male	Right	Small	Medium	Large	Pre-op UCLA score
All non-absorbable polyester	384	67	54.2%	67.2%	25.0%	57.0%	18.0%	19.1
Absorbable PGA mattress	131	66	51.1%	61.8%	19.1%	63.4%	17.5%	19

Table 2 Retear rate, UCLA score, and surgical cost in two cohorts of our method.

Suture material	Retear rate				Post-op UCLA score	Surgical cost
	Small	Medium	Large	Overall		
All non-absorbable polyester	4%	5%	13%	6%	32.7	\$9
Absorbable PGA mattress	0%	2.4%	8.7%	3.1%	32.7	\$12

Table 3 Published method of transosseous rotator cuff repair reporting clinical outcomes of more than 50 cases.

First Author	Year	Technique	Shape of Bone Tunnel	Cohort Size	Age	Male	Right	Retear Rate	Surgical cost
Matis, N	2006	Hollow Needle	Curved	75	58.2	68%		12%	
Hubert, F	2010	Hollow Needle	Curved	60	61	62.1%	59.1%	Equivalent to Open Transosseous Suture	\$ 121
Flanagin, B	2016	Arthro Tunneler	L-shaped	109	56.3	54.0%	73.4%	3.7%	\$ 600

strong compressive stress at the outer edge of the humeral head. We believe that the physiological attachment structure of the rotator cuff cannot be reconstructed if compression and restraint of the rotator cuff by non-absorbable mattress sutures continues for more than 3 weeks, after which the bonding process has progressed sufficiently to achieve adequate stability. However, we do not have histological evidence for this hypothesis, which constitutes a limitation of this study.

We hypothesized that the long-lasting strong anchoring force of the non-absorbable mattress sutures could rather inhibit cuff healing. For this reason, we used absorbable threads for the mattress sutures. The absorbable thread we used is PGA. The features of PGA threads are predictable absorption and outstanding tensile strength. It is absorbed

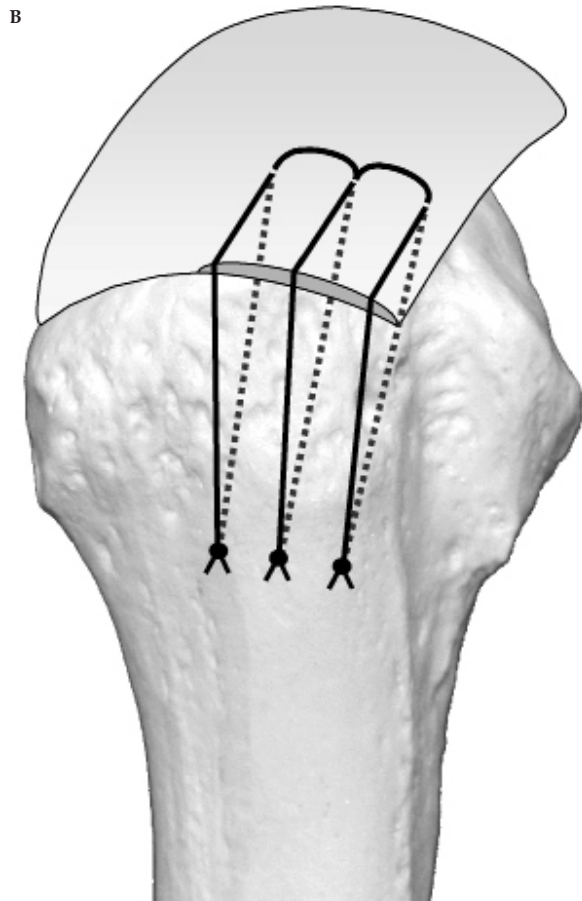
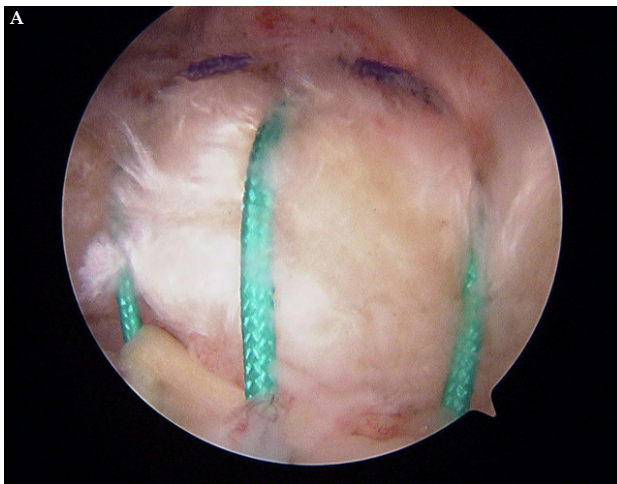


Figure 10 Postoperative arthroscopic view and schematic drawing.

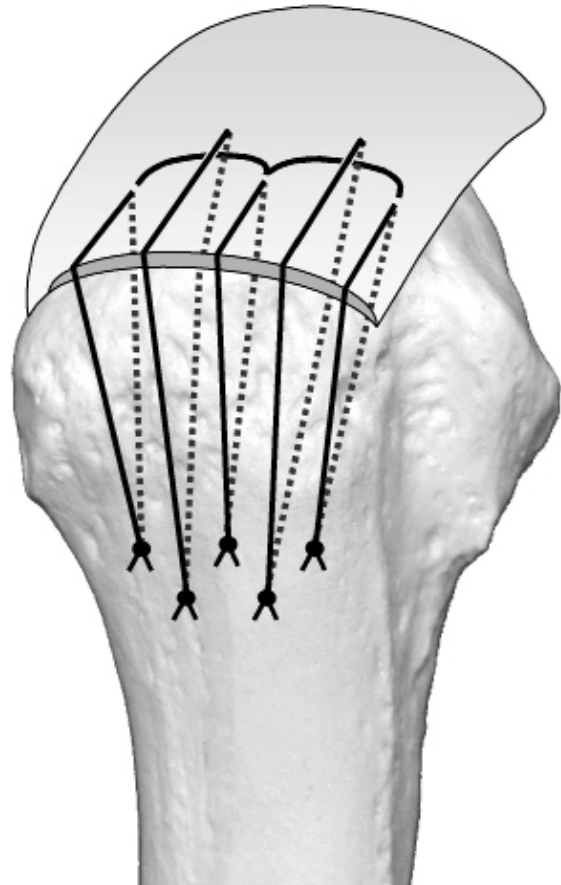


Figure 11 Additional bridging sutures.

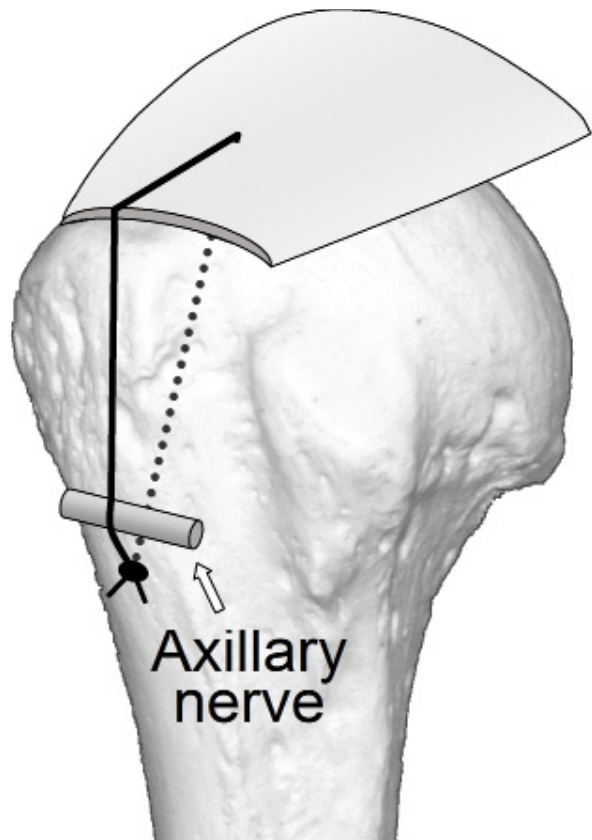


Figure 12 Possibility of axillary nerve entrapment by bridging sutures.

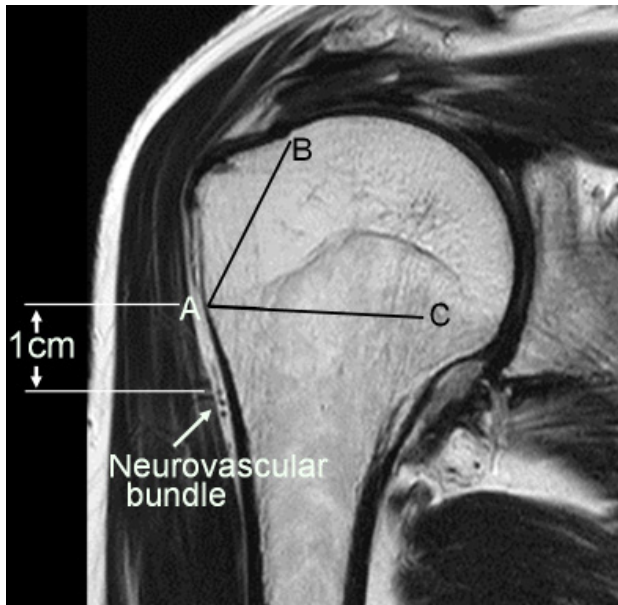


Figure 13 Insertion point and angle of Kirshner wire.

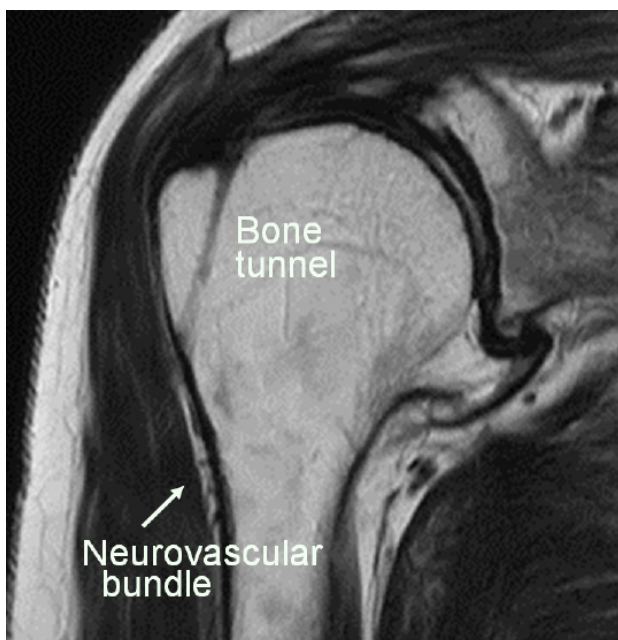


Figure 14 Postoperative MRI.

in the body by a simple hydrolytic mechanism. The PGA mattress sutures retain their original tensile strength until the rotator cuff attains adequate stability. In our technique, we draw the torn rotator cuff to the footprint with 2 absorbable PGA mattress sutures and press it down to the footprint with 3 non-absorbable polyester bridging sutures. Mattress sutures are needed to pull the torn rotator cuff to the footprint and avoid excessive tension during the initial healing period until stability between the torn rotator cuff and footprint is obtained. After stability is achieved, the non-absorbable mattress sutures suppress cuff movement excessively and inhibit healing. The tensile strength of the PGA thread becomes 65% after 2 weeks and 35% after 3 weeks. We suggest that avoiding the unnecessary suppression of rotator cuff movement caused by non-absorbable mattress sutures reduced the retear rate.

In our technique, the strength of the rotator cuff fixation does not

depend on the bone quality of the footprint. Instead, it relies on the durable cortical bone of the inferior margin of the greater tuberosity. The strong fixing force of mattress sutures restrict cuff movement and bridging sutures generate a greater bonding force between the rotator cuff and footprint. Furthermore, 3 bone tunnels with a diameter of 2 mm maximize the cuff-to-footprint contact area and create a wide cuff-to-bone healing area compared with that using larger anchor holes. Rotator cuff tears frequently occur in elderly people with osteoporosis. Therefore, problems with bone tunnels are a theoretical concern with the transosseous techniques. Liu *et al* reported that the frequency of intraoperative bone laceration was 44% with the ArthroTunneler method^[8]. No problems related to bone tunnels were identified using our procedure in which linear long bone tunnels from the inferior margin of the greater tuberosity to the medial edge of footprint were used. Utilizing the distal durable cortical bone of the greater tuberosity is one of the advantages of our method.

Protection of the axillary nerve is critically important in this procedure in which Kirshner wires are inserted from the inferior margin of the greater tuberosity. When Kirshner wires are inserted from the periphery of the axillary nerve, axillary nerve entrapment by bridging sutures can occur (Figure 12). To avoid axillary nerve injury, we identify the neurovascular bundle using preoperative MRI and set the insertion angle of the aiming guide so the Kirshner wire is inserted 1 cm above the neurovascular bundle (Figure 13, [A]). The intersection of the line connecting the medial edge of the footprint [B], the Kirshner wire insertion point [A], and the line [AC] perpendicular to the humeral long axis is the proper insertion angle (Figure 13, angle BAC). Usually this angle is 60°–65°. Postoperative MRI shows that the neurovascular bundle and Kirshner wire insertion point are sufficiently far apart (Figure 14). Postoperative EMG of the deltoid muscle detected no axillary nerve damage in any patient.

The presence of anchors in the greater tuberosity makes reoperation difficult. This problem is especially obvious when numerous metal anchors have been used. Because our anchorless technique uses only sutures and 3 bone tunnels with a diameter of 2 mm, it offers the added advantage of facilitating revision surgery.

In 2013, we calculated the cost, including surgical time and personnel expenses, and found that our procedure is cheaper than the anchor method, unless the latter is completed within 6 minutes^[18]. The only surgical material used is polyester thread and PGA thread. Since we do not use disposable surgical instruments, the surgical cost is only \$12 (Table 2). The surgical cost of the ArthroTunneler method is \$600 and that of Hubert's hollow needle method is \$121 (Table 3). Much less expensive surgical costs compared with other transosseous methods and the anchor method is an enormous advantage of our technique. In addition to the merit of the medical economy, we found that using PGA thread for mattress sutures reduced the retear rate.

ACKNOWLEDGEMENTS

We thank Nancy Moyer, MD, from Edanz Group (www.edanzediting.com/ac) for proofreading of this manuscript.

REFERENCES

1. Kuroda S, Ishige N, Mikasa M. Advantages of arthroscopic transosseous suture repair of the rotator cuff without the use of anchors. *Clin Orthop Relat Res.* 2013; **471(11)**: 3514-3522. [PMID: 23836242]; [PMCID: PMC3792255]; [DOI: 10.1007/s11999-013-3148-7]
2. Sugaya H, Maeda K, Matsuki K, Moriishi J. Repair integrity and

- functional outcome after arthroscopic double-row cuff repair: a prospective outcome study. *J Bone Joint Surg Am.* 2007; **89**: 953-960. [PMID: 17473131]; [DOI: 10.2106/JBJS.F.00512]
3. Ellman H, Hanker G, Bayer M. Repair of the rotator cuff: endresult study of factors influencing reconstruction. *J Bone Joint Surg Am.* 1986; **68**: 1136-1144. [PMID: 3771595]
 4. Codman EA. Complete rupture of the supraspinatus tendon. Operative treatment with report of two successful cases. *Boston Med Surg J.* 1911; **164**: 708-710. [PMID: 21288744]; [DOI: 10.1016/j.jse.2010.10.031]
 5. Garrigues GE, Lazarus MD. Arthroscopic bone tunnel augmentation for rotator cuff repair. *Orthopedics.* 2012; **35(5)**: 392-397. [PMID: 22588393]; [DOI: 10.3928/01477447-20120426-04]
 6. Garofalo R, Castagna A, Borroni M, Krishnan SG. Arthroscopic transosseous (anchorless) rotator cuff repair. *Knee Surg Sports Traumatol Arthrosc.* 2012; **20(6)**: 1031-1035. [PMID: 22011882]; [DOI: 10.1007/s00167-011-1725-4]
 7. Randelli P, Stoppani CA, Zaolino C, Menon A, Randelli F, Cabitza P. Advantages of Arthroscopic Rotator Cuff Repair With a Transosseous Suture Technique: A Prospective Randomized Controlled Trial. *Am J Sports Med.* 2017; **45(9)**: 2000-2009. [PMID: 28339286]; [DOI: 10.1177/0363546517695789]
 8. Liu XN, Yang CJ, Lee GW, Kim SH, Yoon YH, Noh KC. Functional and Radiographic Outcomes After Arthroscopic Transosseous Suture Repair of Medium Sized Rotator Cuff Tears. *Arthroscopy.* 2018; **34(1)**: 50-57. [PMID: 29079262]; [DOI: 10.1016/j.arthro.2017.07.035]
 9. Black, EM, Lin, A, Srikumaran, U, Jain, N, Freehill, MT. Arthroscopic transosseous rotator cuff repair: technical note, outcomes, and complications. *Orthopedics.* 2015; **38**: e352-e358. [PMID: 25970360]; [PMCID: PMC4712630]; [DOI: 10.3928/01477447-20150504-50]
 10. Flanagan BA, Garofalo R, Lo EY, Feher L, Castagna A, Qin H, Krishnan SG. Midterm clinical outcomes following arthroscopic transosseous rotator cuff repair. *Int J Shoulder Surg.* 2016; **10(1)**: 3-9. [PMID: 26980983]; [PMCID: PMC4772414]; [DOI: 10.4103/0973-6042.174511]
 11. Matis N, Hübner C, Aschauer E, Resch H. Arthroscopic Transosseous Reinsertion of the Rotator Cuff. *Operat Orthop Traumatol* 2006; **18**: 1-18. [PMID: 16534558]; [DOI: 10.1007/s00064-006-1159-1]
 12. Tauber M, Koller H, Resch H. Transosseous arthroscopic repair of partial articular-surface supraspinatus tendon tears. *Knee Surg Sports Traumatol Arthrosc.* 2008; **16**: 608-613. [PMID: 18418574]; [DOI: 10.1007/s00167-008-0532-z]
 13. Hubert F, Manuel H, Martin V, Jens S. Arthroscopic Bone Needle: A New, Safe, and Cost-effective Technique for Rotator Cuff Repair. *Techniques in Shoulder & Elbow Surgery.* 2010; **11(4)**: 107-112.; [DOI: 10.1097/BTE.0b013e3181fdb375]
 14. Chillemi C and Mantovani M. Arthroscopic trans-osseous rotator cuff repair. *Muscles Ligaments Tendons J.* 2017; **7(1)**: 19-25. [PMID: 28717607]; [PMCID: PMC5505589]; [DOI: 10.11138/mltj/2017.7.1.019]
 15. Chillemi C, Mantovani M, Osimani M and Castagna A. Arthroscopic transosseous rotator cuff repair: the eight-shape technique. *Eur J Orthop Surg Traumatol.* 2017; **27**: 399-404. [PMID: 28124131]; [DOI: 10.1007/s00590-017-1906-z]
 16. Gutiérrez MA, Mendiña AM, Mora MV, and Boyle S. All-Suture Transosseous Repair for Rotator Cuff Tear Fixation Using Medial Calcar Fixation. *Arthroscopy Techniques.* 2015; **4(2)**: e169-e173. [PMID: 26052495]; [PMCID: PMC4454820]; [DOI: 10.1016/j.eats.2015.01.001]
 17. Duquin TR, Buyea C, Bisson LJ. Which method of rotator cuff repair leads to the highest rate of structural healing? A systematic review. *Am J Sports Med.* 2010 Apr; **38(4)**: 835-841. [PMID: 20357403]; [DOI: 10.1177/0363546509359679]
 18. Kuroda S, Ishige N, Mikasa M. Reply to the Letter to the Editor. Advantages of Arthroscopic Transosseous Suture Repair of the Rotator Cuff without the Use of Anchors. *Clin Orthop Relat Res* 2014; **472**: 1044-1045. [PMID: 24363188]; [PMCID: PMC3916621]; [DOI: 10.1007/s11999-013-3435-3]

Peer Reviewer: Amr Abdelhady; Emmanouil Brilakis