

Prospective Study of Outcome of Minimally Invasive Open Discectomy in Single Level Lumbar Disc Herniation

Prakriti Raj Kandel¹, Dipendra Chhetri², Gyaneshwar Prasad Singh³

1, Associate Professor, Department of Orthopedics, Universal College of Medical Sciences & Teaching Hospital, Bhairahawa, Nepal;

2 Universal College of Medical Sciences & Teaching Hospital, Bhairahawa, Nepal;

3 Professor & Head of Department of Orthopedics, Universal College of Medical Sciences & Teaching Hospital, Bhairahawa, Nepal.

Conflict-of-interest statement: The author(s) declare(s) that there is no conflict of interest regarding the publication of this paper.

Open-Access: This article is an open-access article which was selected by an in-house editor and fully peer-reviewed by external reviewers. It is distributed in accordance with the Creative Commons Attribution Non Commercial (CC BY-NC 4.0) license, which permits others to distribute, remix, adapt, build upon this work non-commercially, and license their derivative works on different terms, provided the original work is properly cited and the use is non-commercial. See: <http://creativecommons.org/licenses/by-nc/4.0/>

Correspondence to: Prakriti Raj Kandel, Associate Professor, Department of Orthopaedics, Universal College of Medical Sciences & Teaching Hospital, Bhairahawa, Nepal.

Email: pratul22@gmail.com

Telephone: +9779858023357

Received: August 16, 2019

Revised: October 25, 2019

Accepted: November 3 2019

Published online: December 28, 2019

ABSTRACT

AIMS: To study the functional outcome, incidence, degree of pain improvement, neurological improvement and complication following Minimal invasive open lumbar discectomy in single level lumbar disc herniation.

METHOD: This prospective study was carried out at Department of Orthopedics of UCMS-TH between November 2016 to July 2017

with symptomatic lumbar disc herniation with failed conservative treatment and who have fulfilled the inclusion criteria were enrolled into this study. Evaluations of the patients were done post-operatively at fourteen post operative day, one month and three months. At each assessment detail clinical and neurological examination was done with ODI and VAS assessment

Results: In our study sample size was 30 in which the mean age was 41.7 years ranging from 20 to 65 years. Among 30 patients, 18 were male and 12 were female. 17 patients (56.7%) were of self employed group, 8 patients (26.7%) were housewife, 2 patients (6.7%) were farmer, 2 patients (6.7%) were public servant and 1 patients (3.3%) was ex army. Average blood loss was 93.9 ml. minimum 70 ml to maximum 120 ml. The mean operative time duration was 90 minutes, minimum 58 to maximum 120 minutes. Pre operative mean ODI score was 46.06, one month mean ODI was 33.73 and on three month mean ODI was 22.93. Mean for VAS for leg pain pre operatively was 7.43, one month follow up score was 5.06 and lastly three month score was 3.43. One patient had dura tear as intra-operative and two patients had discitis as late complication.

CONCLUSION: Minimal invasive open discectomy is best treatment for symptomatic lumbar disc herniation who had failed conservative treatment in our locality and developing country like Nepal.

Key words: Intervertebral disc disease; Prolapse intervertebral disc (PIVD); Minimal invasive open discectomy

© 2019 The Author(s). Published by ACT Publishing Group Ltd. All rights reserved.

Kandel PR, Chhetri D, Singh GP. Prospective Study of Outcome of Minimally Invasive Open Discectomy in Single Level Lumbar Disc Herniation. *International Journal of Orthopaedics* 2019; 6(6): 1211-1216 Available from: URL: <http://www.ghrnet.org/index.php/ijo/article/view/2426>

INTRODUCTION

Intervertebral disc disease refers to a set of structural changes resulting from the disruption of the integrity of elements that form the intervertebral disc and the vertebral canal^[1].

The 2010 Global Burden of Disease Study estimated that low back pain is among the top 10 diseases that account for the highest number of Disability Adjusted Life Years (DALYs) worldwide^[2]. Lumbar disc disease forms the second most common cause for medically authorized absence from work^[3]. Low-back pain incurs an annual cost exceeding \$100 billion in the USA^[4]. The economical and social burden of this disease remains unclear in our country due to lack of systematic data.

The term “intervertebral disc disease” covers various types and degrees of disc disorders leading to nucleus pulposus herniation known as Prolapse intervertebral disc (PIVD)^[1,5]. Prolapse intervertebral disc is an important cause of spondylogenic backache that occurs mainly between the fourth and fifth decades of life (mean age of 37 years), although it has been described in all age groups^[6]. Ninety five percent of lumbar disc herniation occurs at either L4-L5 or L5-S1 level^[7] because of weak reinforcement of posterior longitudinal ligament at L4-L5 and L5-S1 level where it is a midline narrow unimportant structure attached to annulus^[8]. Greatest motion in the L4-L5 and L5-S1 articulations at lumbar spine is another factor. Greater motion causes an increased potential for instability, degeneration and breakdown and therefore the incidence of herniated discs is greater at L4-L5 and L5-S1 level than at any other lumbar disc space^[9]. The estimated annual prevalence of disc related radiculopathy in the general population is 2.2%, although reports in the literature range from 1.2% to 43%^[10]. Study done in Finland and Italy shows the prevalence of symptomatic herniated lumbar disc was about 1-3%^[11].

Initial episode of lumbar radiculopathy can be managed by rest, physical therapy, appropriate use of pain medication and finally Epidural steroid injection in nonresponding cases. In most instances, radicular symptoms will abate or resolve within six weeks. In patients with demonstrable MRI disc pathology, if symptoms persist for more than 6 weeks despite conservative treatment and epidural steroid injection, those patients can be considered for surgical interventions^[12,13].

Spinal surgery in selected patients can significantly improve quality of life^[1,14]. There are different surgical intervention for lumbar disc herniation ranging from open disc surgeries to standard micro surgeries. The time proven golden micro surgeries are endoscopic laminectomy and discectomy, chemonucleolysis and laser disc surgeries.

Although Microsurgical discectomy remains the gold standard treatment^[15], but in developing countries like Nepal and average city like Bhairahawa microsurgical discectomy remains a real challenge due to its costly and sophisticated instrument, high operative charges and lack of super-specialized training of surgeons. As a comparable alternative, Minimally Invasive Open Lumbar Discectomy (MIOLD) can be a better option to micro lumbar discectomy^[16] which is more accessible and cost effective than other procedures.

Minimally invasive open lumbar discectomy spine surgery has minimal muscle injury while achieving good clinical outcome comparable to conventional open surgery and micro lumbar discectomy. Patients are expected to have less low-back pain, shorter hospital stay, faster mobilization, quicker resumption of work and daily activities and moreover, it is cost effective^[17] among other surgeries. Considering the high incidence rate of lumbar disc herniation and its physical, psychological and economical burden to the patients, it is worthy to select an operative procedure that would be safe, less traumatic and cost effective to the patients.

Minimal invasive lumbar discectomy is a procedure that meets all of these criteria and would be a real fit in our locality. So,

undoubtedly we can say that MIOLD is the ideal treatment for PIVD in developing countries like Nepal where microsurgical procedure are not that accessible.

So, studying the functional outcome of MIOLD in PIVD cases will help us to analyze the real benefit of this procedure which will further help us to adapt this procedure and give appropriate care to our patient.

MATERIAL AND METHOD

Patients admitted to Department of Orthopedics of UCMS-TH between November 2016 to July 2017 with symptomatic lumbar disc herniation with failed conservative treatment and who have fulfilled the inclusion criteria were enrolled into this study.

Inclusion criteria

(1) Patients over Twenty years old who had radicular pain for at least four-six weeks with positive nerve root tension sign & who had no relief after non-operative treatment like bed rest, analgesics, traction and epidural steroid injection for 4-6weeks^[12,13]. (2) Confirmatory cross-sectional MRI imaging study demonstrating intervertebral disc herniation at a level and side corresponding to their symptoms. (3) Patients lying in ODI scoring group III (severe) or above were only included

Exclusion criteria

(1) Disc herniation at multiple level; (2) Spondylodiskitis; (3) Segmental instability with prolapse disc; (4) Psychogenic disorder; (5) Previous lumbar surgery; (6) Bilateral radiculopathy; (7) Age less than 20 years.

After taking written informed consent from patient and fitness given for anesthesia, all patients were pre-medicated with Tablet Lorazepam 1 mg a night before surgery and then Nil per Oral. All the patients were operated in G.A and lateral knee chest position, the affected side being in the upper side. Every patient was given prophylactic i.v Cefuroxime 1.5 gm 15 minutes before skin incision. After painting and draping, exact level of disc herniation was identified by C-arm guidance followed by a mid-line vertical incision of 3-4 cm over the affected inter-space was made. The incision was deepened to the subcutaneous tissue and deep fascia. The thoraco-lumbar fascia was divided along the line of incision and reflected. Para-spinal musculature was dissected off laterally till the medial facet was exposed and the muscle was held back with William's retractor, thereby exposing the ligamentum flavum. This was followed by flavotomy, thus exposing the thecal sac. A bit of lamina was taken to expose the root. The root as well as the thecal sac was retracted medially with two cotton pledgets to expose the disc. A number 4 Penfield dissector was used to pierce the annulus after which the disc was delivered out. All the loose disc material was removed with pituitary rongeur upto mid vertebral body level or upto 30 gm of disc had been removed. Curetting the disc space was avoided as far as possible. The dorso-lumbar fascia was closed with around three stitches and the wound was closed in layers without a drain.

Evaluations of the patients were done post-operatively at fourteen post operative day, one month and three months. At each assessment detail clinical and neurological examination was done with ODI and VAS assessment. Bending of spine, squatting, sitting, weight lifting were restricted till 2 months.

Clinical evaluation (post operative): (1) Straight leg raising test of bilateral lower limb; (2) Cross leg raising test; (3) Sensory and motor

examination of bilateral lower limb; (4) Deep tendon reflex (knee, ankle); (5) Planter response.

Scoring system (post operative): (1) ODI score; (2) VAS score for leg pain.

RESULTS

Based on Demographic profile

Out Of the 30 patients in this study the mean age was 41.7 years, ranging from 20 to 65 years of age.

Gender wise male constituted 18(60%) and female 12 (40%) of total patients.

Out of 30 patients, 17 (56.7%) were of self employed group, 8 (26.7%)were housewife, 2 (6.7%) were farmer and public servant respectively lastly 1 (3.3%) was of ex army.

Maximum number of disc herniation was at level of L4-L5 with 15(50%), 12(40%) at level of L5-S1 and 3(10%) at level of L3-L4.

Of the 30 patients, 17 (56.6%) have pain of duration less than 12 month and 13(43.3%) have pain of duration more than 12 months. Mean month for duration of pain was 17.2 month.

Out of 30 patients, equal number of people have pain on their limb (left, right).

Out of 30 patients, 30 patients had SLRT positive in pre operative examination. Equal number of patients compare to preoperative i.e 30 were positive in 14 post operative day. 23 patient had SLRT positive in one month follow up and 6 patients have positive SLRT on three month.

Average blood loss was 93.9 ml. minimum 70 ml to maximum 120 ml.

The mean time duration was 90 minutes, minimum 58 to maximum 120 minutes.

Average hospital stay was 8.33 days, minimum 6 days to maximum 14 days.

FUNCTIONAL OUTCOME

Mean ODI of 46.06 was in pre operative cases, mean of 33.73 in one month follow up and mean of 22.93 in three month follow up. In pre operative cases highest frequency of ODI felled into group severe, On one month follow up highest frequency felled in group moderate and lastly on three month follow up highest frequency of patients felled in minimal group. On comparing the ODI score of pre operative vs one month and one month vs three month follow up functional outcome was statistically significant ($p < 0.001$).

Visual analogue score for leg pain of 30 patients in pre operative was mean of 7.43. Mean of 6.06 was at 14 post operative day. On 1 month follow up mean score was 5.06 and lastly on 3 month follow up was 3.43. one comparing VAS for pre operative vs 14 post operative, 14 post operative vs 1 month, 1 month vs 3 month decrease in mean value shows statistically significant ($p < 0.001$).

DISCUSSION

Lumbar disc herniation is a prevalent condition and symptomatic patients present a significant socioeconomic health burden. Spinal surgery in selected patients who have failed conservative treatments of 4-6 week can have significant improvement in quality of life. Minimally invasive open discectomy decreases surgical exposure, gives less trauma and have success rate of approximately 90%^[16].

Demographic Profile

Age/sex

Mean age of our patients with lumbar disc Prolapse was 41.7 years

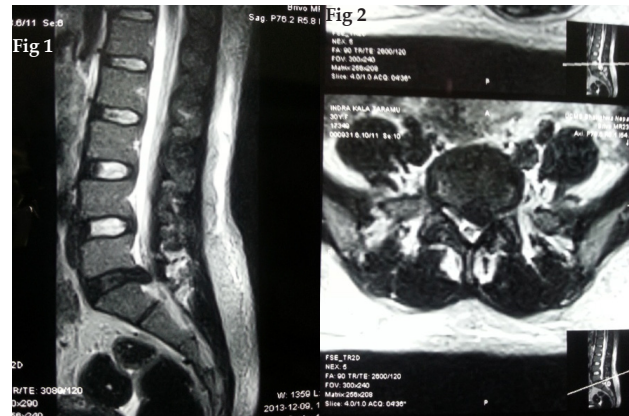


Figure 1 and 2 MRI Sections.

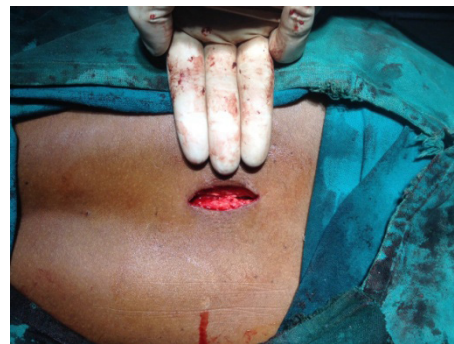


Figure 3 Midline Vertical Incision.

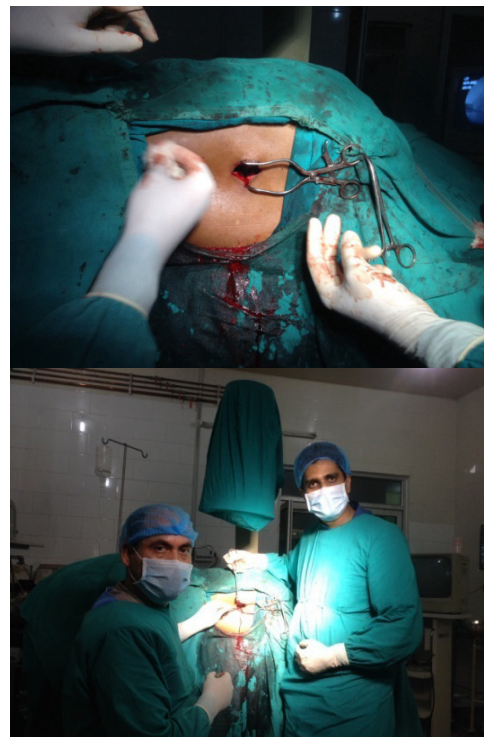

Figure 4 and 5 Retractor and C-arm used.

and more than half of them were ≥ 40 years which was similar to Grag B *et al*^[18]. (38.7 ± 8 years), Jaff, H *et al*^[19] (40 years) and Weir BK *et al*^[20] (41.7 years).

Sex distribution of Males and females in our study was 60 % male and 40 % female which was similar to Wankhade, UG *et al*^[21] (56% male, 46% female). Dewing CB *et al*^[22] also found high incidence

rate in male patients over female patients. Hence most of the studies showed that male are more prone for prolapse intervertebral disc than female.

Occupation

Regarding occupation 56.7% of patients in this study were self-employed with history of heavy works which was similar to Seidler A *et al*^[23]. This showed that there is significant relationship between lumbar disc prolapse and cumulative exposures to weight lifting.

Level of lumbar disc prolapse

Out of 30 patients, maximum number (15 patients, 50%) of disc herniation was at L4-L5 level and 12 patients (40%) at L5-S1 level which was similar to Findlay GF *et al*^[24] and Devkota UP *et al*^[16]. This may be due to greater motion and weak reinforcement of posterior longitudinal ligament over L4-L5 and L5-S1 level.

Duration of symptoms

Mean duration of symptoms in our study was 17.1 month. Majority of patient had symptoms of more than 12 month (17 patients, 56.6%) which was similar to Jaff H *et al*^[19] and Findly GF *et al*^[24].

Side of leg pain

Regarding side involvement, there was equal frequencies between both sides (15 (50%) left leg, 15 (50%) right leg). We didn't find any significant study to compare this data to rule out which side was more frequently involved.

Clinical evaluation (SLRT)

In this study, all 30 patients had positive SLRT in 14 post operative day. But, only 23 patients had positive SLRT at 1 month and only 6 patients had positive SLRT at 3 months. This data showed that SLRT improves gradually over time although SLRT may be positive at initial postoperative days. Our result was similar to study done by WIER BK *et al*^[20] where 83% of positive SLRT in pre operative period improved to 2% positive SLRT at one month. Similar study done by Mittal A *et al*^[25] also have similar result. Another study done by Jonsson B *et al*^[26] also found 86% of positive SLRT in pre operative patient improved to 22% positive SLRT at 4 month and 18% positive SLRT at one year.

VAS For leg pain

In this study the mean VAS for leg pain in pre operative cases was 7.43. But, at subsequent follow up we found improvement in VAS score which was 6.06, 5.06 and 3.43 at 14 post operative day, 1 month and 3 months respectively. Similar study done by Swamy A. *et al*^[27] found that mean pre operative VAS score of leg pain was 7.00, at one week VAS was 0.81 and at one month follow VAS was 0.6 which is similar to our study. Owens RK 2nd *et al*^[28] reported

VAS at preoperative period, 3 months and 12 months postoperatively to be 7.5 to 2.3 to 2.5 ($p < 0.000$). Hence, most of the studies showed gradual improvement in VAS for leg pain over time following MIOLD.

ODI

In this study, the mean ODI in pre operative period, at 1 month and at 3 month was 46.06, 33.73 and 22.73 respectively which was similar to Luri J.D *et al*^[29] where he found improving ODI score following lumbar discectomy in 6 week, 3 month, 6 month and one year. Swamy A *et al*^[27] also found pre operative ODI score of 50.28, that reduced to 20.94 at 1 month and 6.28 at 3 month. This showed that, there is dramatic improvement in ODI score following MIOLD.

Neurological Evaluation

Regarding neurological evaluation, there was no improvement in deep tendon reflex and sensory deficit till 3 months. But, regarding motor deficit out of 10 patients only 3 patients had improvement at 3 month. Righesso O *et al*^[30] also did not find satisfactory outcome regarding neurological improvement which was similar to our study.

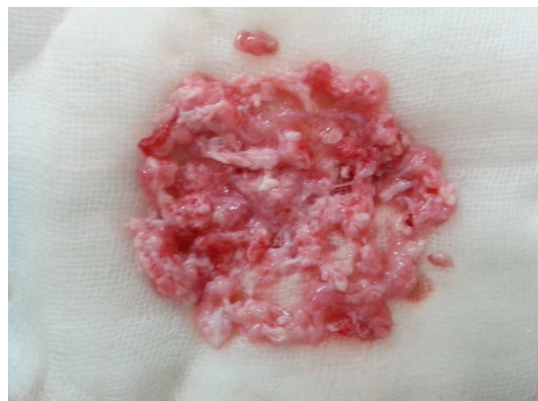

Figure 6 Disc delivered out.

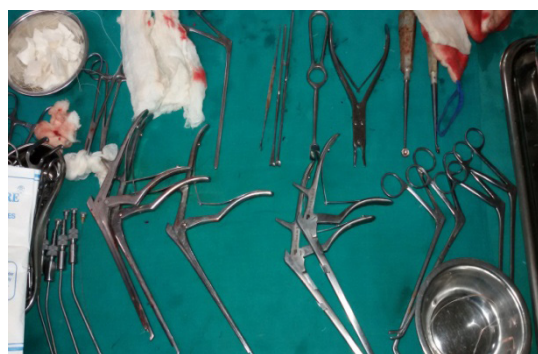

Figure 7 Instruments used.

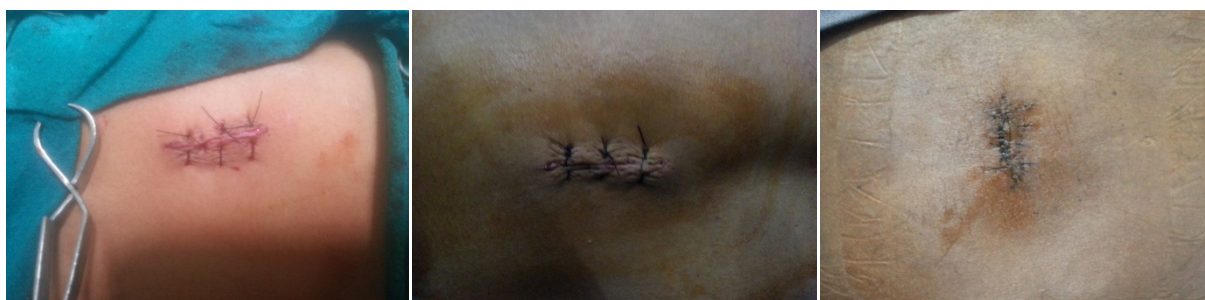

Figure 8, 9, 10 Suture applied and removed after 2wks.

Complication

We found minimal complication for minimal invasive open discectomy in our study. The intra-operative complication for studied patients was dural tear in 1 patient and late complication with discitis in 2 patients. Albayrak S *et al*^[31] also found dural tear in open discectomy procedure and other procedures for disc surgeries. We managed dural tear with autologous fat pad packing which is one of the option for dural tear. Devkota P *et al*^[16] reported complication rate of less than 1.5% in his study that ranges from dural tears, nerve root injury, and discitis.

Duration of surgery and blood loss and hospital stay

In our study, the average hospital stay was 8.33 days. The average hospital stay in study performed by WIER BK *et al*^[20] was average of 4.5days which was not similar to our study. The longer duration of hospital stay in our study was mainly due to the fact that most of our patients were from remote and hilly areas who wanted their discharge only after suture removal which was done at around 14 post operative days.

The average intra-operative blood loss in our study was 93.9 ml, minimum 70 ml to maximum 120 ml. The mean operative time was 90 minutes, with a minimum of 58 minutes to maximum of 180 minutes. These results are coherent with an observational study conducted by Garg b *et al*^[18].

CONCLUSION

From this study, we conclude that Minimal invasive open lumbar discectomy in single level lumbar disc herniation is one of the best approaches for surgical management in symptomatic patient who had failed conservative treatment for at least 4-6 week. Since it has small incision (less than 4 cm), small scar, less damage to muscle, minimum blood loss and good functional outcome; it can be considered as a best operative procedure for disc prolapse where micro-discectomy procedure are not feasible.

Moreover this procedure is safe and helps in early mobilization of the patient. Considering these facts, we can clearly say that minimally invasive open lumbar discectomy is one of the best treatment modality in developing country like Nepal where more advance techniques are still lacking.

REFERENCE

- Jabłońska R, Ślusarz R, Królikowska A, Haor B and Zając M. Assessment and Determinants of Spinal Pain in the Course of Disc Disorders Treated Surgically. *Medical Science Monitor: International Medical Journal of Experimental and Clinical Research*. 2016; **22**: 4446-54. [PMCID: PMC5119686]; [PMID: 27865095]; [DOI: 10.12659/MSM.898252]
- Vos T, Flaxman AD, Naghavi M, Lozano R, Michaud C, Ezzati M. Years lived with disability (YLDs) for 1160 sequelae of 289 diseases and injuries 1990-2010: a systematic analysis for the Global Burden of Disease Study 2010. *Lancet (London, England)*. 2012; **380**: 2163-96. [PMID: 23245607]; [PMCID: PMC6350784]; [DOI: 10.1016/S0140-6736(12)61729-2]
- Cypress BK. Characteristics of physician visits for back symptoms: a national perspective. *American journal of public health*. 1983; **73**: 389-95. [PMID: 6219588]; [PMCID: PMC1650784]; [DOI: 10.2105/ajph.73.4.389]
- Katz JN. Lumbar disc disorders and low-back pain: socioeconomic factors and consequences. *The Journal of bone and joint surgery American volume*. 2006; **88 Suppl 2**: 21-4. [PMID: 16595438]; [DOI: 10.2106/JBJS.E.01273]
- Byvaltsev V, Kalinin A, Khachikyan AF and i.S m. THE NEW

ARMENIAN MEDICAL JOURNAL SURGICAL INTERVENTIONS IN UNSTABLE FORMS OF DEGENERATIVE LUMBOSACRAL SPINE. 2016, p.p. 34-48.

- Vialle LR, Vialle EN, Suárez Henao JE and Giraldo G. LUMBAR DISC HERNIATION. *Revista Brasileira de Ortopedia*. 2010; **45**: 17-22. [PMCID: PMC4799068]; [PMID: 27019834]; [doi: 10.1016/S2255-4971(15)30211-1]
- Williams KD PALbpado, intervertebral disc In: S. Terry Canale JHB, (eds). *Campbell's and Operative Orthopaedics*: Mosby Elsevier P, USA. pp: 17-29.
- Gkasdaris G, Tripsianis G, Kotopoulos K and Kapetanakis S. Clinical anatomy and significance of the thoracic intervertebral foramen: A cadaveric study and review of the literature. *Journal of Craniovertebral Junction & Spine*. 2016; **7**: 228-35. [PMCID: PMC5111324]; [PMID: 27891032]; [DOI: 10.4103/0974-8237.193266]
- Hoppenfeld S HROnL and Williams and Wilkins P, USA. pp: 66.
- Konstantinou K and Dunn KM. Sciatica: review of epidemiological studies and prevalence estimates. *Spine*. 2008; **33**: 2464-72. [PMID: 18923325]; [DOI: 10.1097/BRS.0b013e318183a4a2]
- Jordan J, Konstantinou K and O'Dowd J. Herniated lumbar disc. *BMJ Clin Evid*. 2009 Mar 26; 2009. pii: 1118. [PMID: 19445754]; [PMCID: PMC2907819]
- Schoenfeld AJ and Weiner BK. Treatment of lumbar disc herniation: Evidence-based practice. *International Journal of General Medicine*. 2010; **3**: 209-14. [PMID: 20689695]; [PMCID: PMC2915533]
- Carragee E. Surgical treatment of lumbar disk disorders. *Jama*. 2006; **296**: 2485-7. [PMID: 17119147]; [DOI: 10.1001/jama.296.20.2485]
- Weinstein JN, Lurie JD, Tosteson TD, Tosteson AN, Blood EA, Abdu WA, Herkowitz H, Hilibrand A, Albert T, Fischgrund J, Blood EA, Abdu WA, *et al.* Surgical versus, Trial NTLDFHF-YRftSPOR and (SPORT). *Spine* 2008; 2789-2800. [PMID: 19018250]; [PMCID: PMC2756172]; [DOI: 10.1097/BRS.0b013e31818ed8f4]
- Maroon JC. Current concepts in minimally invasive discectomy. *Neurosurgery*. 2002; **51**: S137-45. [PMID: 12234441]
- Devkota UP, Lohani S and Joshi RM. Minimally invasive open lumbar discectomy: An alternative to microlumbar discectomy. *Kathmandu University medical journal (KUMJ)*. 2009; **7**: 204-8. [DOI: 10.3126/kumj.v7i3.2724]
- Peul WC, van Houwelingen HC, van den Hout WB, Brand R, Eekhof JA, Tans JT, Thomeer RT, Koes BW;. Surgery versus prolonged conservative treatment for sciatica. *The New England journal of medicine*. 2007; **356**: 2245-56. [PMID: 17538084]; [DOI: 10.1056/NEJMoa064039]
- Garg B, Nagraja UB and Jayaswal A. Microendoscopic versus open discectomy for lumbar disc herniation: a prospective randomised study. *Journal of orthopaedic surgery (Hong Kong)*. 2011; **19**: 30-4. [PMID: 21519072]; [DOI: 10.1177/230949901101900107]
- Jaff H, Amin B, Fatah R, Husein H. The Outcome of Minimally Invasive Discectomy in Single Level Lumbar Disc Prolapse. *Open Journal of Orthopedics*, 2016; **6**: 211-220. [DOI: 10.4236/ojo.2016.67028].
- Weir BK. Prospective study of 100 lumbosacral discectomies. *Journal of neurosurgery*. 1979; **50**: 283-9. [PMID: 422980]; [DOI: 10.3171/jns.1979.50.3.0283]
- Wankhade UG, Umashankar MK and Reddy BS. Functional Outcome of Lumbar Discectomy by Fenestration Technique in Lumbar Disc Prolapse - Return to Work and Relief of Pain. *Journal of clinical and diagnostic research: JCDR*. 2016; **10**: Rc09-13. [PMID: 27134956]; [PMCID: PMC4843341]; [DOI: 10.7860/JCDR/2016/16607.7512]
- Dewing CB, Provencher MT, Riffenburgh RH, Kerr S and Manos RE. The outcomes of lumbar microdiscectomy in a young,

- active population: correlation by herniation type and level. *Spine*. 2008; **33**: 33-8. [PMID: 18165746]; [DOI: 10.1097/BRS.0b013e31815e3a42]
23. Seidler A, Bolm-Audorff U, Siol T, Henkel N, Fuchs C, Schug H, Leheta F, Marquardt G, Schmitt E, Ulrich PT, Beck W, Missalla A, Elsner G. Occupational risk factors for symptomatic lumbar disc herniation; a case-control study. *Occupational and environmental medicine*. 2003; **60**: 821-30. [PMID: 14573712]; [PMCID: PMC1740425]; [DOI: 10.1136/oem.60.11.821]
 24. Findlay GF, Hall BI, Musa BS, Oliveira MD and Fear SC. A 10-year follow-up of the outcome of lumbar microdiscectomy. *Spine*. 1998; **23**: 1168-71. [PMID: 9615370]; [DOI: 10.1097/00007632-199805150-00019].
 25. (IOSR-JDMS) IJoDaMS and e-ISSN: 2279-0853 p-I-V, Issue 5 Ver. VI (May. 2015), PP 73-80.
 26. Jonsson B and Stromqvist B. Significance of a persistent positive straight leg raising test after lumbar disc surgery. *Journal of neurosurgery*. 1999; **91**: 50-3. [PMID: 10419368]; [DOI: 10.3171/spi.1999.91.1.0050]
 27. Swamy A SA, Sharma K, Khirsagar A, and Patel AA. Functional Outcome of Discectomy for Lumbar Disc Prolapse. *J Spine* (2017) **6**: 382. [DOI: 10.4172/2165-7939.1000382]
 28. Owens RK, 2nd, Carreon LY, Bisson EF, Bydon M, Potts EA and Glassman SD. Back pain improves significantly following discectomy for lumbar disc herniation. *The spine journal: official journal of the North American Spine Society*. 2018. [PMID: 29454134]; [DOI: 10.1016/j.spinee.2018.02.014]
 29. Lurie JD, Fauceit SC, Hanscom B, Tosteson TD, Ball PA, Abdu WA, Frymoyer JW, Weinstein JN. Lumbar discectomy outcomes vary by herniation level in the Spine Patient Outcomes Research Trial. *The Journal of bone and joint surgery American volume*. 2008; **90**: 1811-9. [PMID: 18762639]; [PMCID: PMC2657310]; [DOI: 10.2106/JBJS.G.00913]
 30. Righesso O, Falavigna A and Avanzi O. Correlation between persistent neurological impairment and clinical outcome after microdiscectomy for treatment of lumbar disc herniation. *Neurosurgery*. 2012; **70**: 390-6; discussion 396-7. [PMID: 21841524]; [DOI: 10.1227/NEU.0b013e318231da4c]
 31. Albayrak S, Ozturk S, Ayden O and Ucler N. Dural Tear: A Feared Complication of Lumbar Discectomy. *Turkish neurosurgery*. 2016; **26**: 918-21. [PMID: 27560527]; [DOI: 10.5137/1019-5149.JTN.14065-15.2]