

## Shortening and Varus Collapse of Femoral Neck Fractures in Young Patients (<55 Years): Percutaneous Cannulated Screws vs. Dynamic Hip Screw

Rafael Carbonell-Escobar, MD, Ricardo Fernandez-Fernandez, MD, PhD, E. Carlos Rodriguez-Merchan, MD, PhD, Aitor Ibarzabal-Gil, MD, Enrique Gil-Garay, MD, PhD

Rafael Carbonell-Escobar, Ricardo Fernandez-Fernandez, E. Carlos Rodriguez-Merchan, Aitor Ibarzabal-Gil, Enrique Gil-Garay, Department of Orthopedic Surgery, La Paz University Hospital-IdiPaz, Madrid, Spain

**Conflict-of-interest statement:** The author(s) declare(s) that there is no conflict of interest regarding the publication of this paper.

**Open-Access:** This article is an open-access article which was selected by an in-house editor and fully peer-reviewed by external reviewers. It is distributed in accordance with the Creative Commons Attribution Non Commercial (CC BY-NC 4.0) license, which permits others to distribute, remix, adapt, build upon this work non-commercially, and license their derivative works on different terms, provided the original work is properly cited and the use is non-commercial. See: <http://creativecommons.org/licenses/by-nc/4.0/>

**Correspondence to:** E. Carlos Rodriguez-Merchan, Department of Orthopedic Surgery, La Paz University Hospital-IdiPaz, Madrid, Spain.

**Email:** [ecrmerchan@hotmail.com](mailto:ecrmerchan@hotmail.com)

**Received:** September 30, 2018

**Revised:** October 31, 2018

**Accepted:** November 2 2018

**Published online:** December 28, 2018

### ABSTRACT

**BACKGROUND:** The treatment of femoral neck fractures in younger patients is controversial. The objective of this study is to compare varus collapse and shortening of the femoral neck in young patients (<55 years) with femoral neck fracture treated with three percutaneous cannulated screws (PCS) or with open reduction and internal fixation (ORIF) using a dynamic hip screw (DHS).

**METHODS:** In a university hospital 66 consecutive patients with a femoral neck fracture were evaluated in a prospective way. Inclusion criteria included every femoral neck fracture aged < 55 years old attended at our department during the study period and treated by bone

fixation (ORIF with a DHS or with three PCS). Fractures were classified according to Orthopedic Trauma Association (OTA), Garden and Pauwels classifications. We divided the degree of shortening into two groups: moderate (< 5 mm) or severe (> 5 mm), and the degree of varus collapse into two groups: moderate (< 7°) or severe (> 7°) with relation to the unfractured hip. Euroqol-5D (EQ5D) questionnaires were employed to evaluate clinical results.

**RESULTS:** Mean age was 44.1 years (range, 22-55) and mean follow-up 3.2 years (range, 2-5). Thirty-seven fractures were treated with three PCS and twenty nine with ORIF using a DHS. There were 34 undisplaced fractures and 32 displaced fractures. 21 fractures showed comminution of the medial cortex and 14 of the posterior cortex. The rate of avascular necrosis (AVN) was 9.1% (6 cases). There were no cases of nonunion. Mean femoral neck shortening was 6.2 mm (range, 1-13) and mean varus collapse was 8.1° (range, 1-15°). Patients following AVN or with severe shortening and varus collapse presented lower quality of life scores.

**CONCLUSION:** We found a higher degree of varus collapse and shortening in patients treated with PCS.

**Key words:** Femoral neck; Fractures; Osteosynthesis; Percutaneous cannulated screws; Dynamic hip screw; Comparative results

© 2018 The Author(s). Published by ACT Publishing Group Ltd. All rights reserved.

Carbonell-Escobar R, Fernandez-Fernandez R, Rodriguez-Merchan EC, Ibarzabal-Gil A, Gil-Garay E. Shortening and Varus Collapse of Femoral Neck Fractures In Young Patients (< 55 Years): Percutaneous Cannulated Screws vs. Dynamic Hip Screw. *International Journal of Orthopaedics* 2018; **5(6)**: 979-984 Available from: URL: <http://www.ghrnet.org/index.php/ijo/article/view/2433>

### INTRODUCTION

The treatment of femoral neck fractures in younger patients is controversial. Avascular necrosis (AVN) of the femoral head and nonunion are potential complications especially in displaced fractures. Nevertheless, functional results in these patients are based

on the restoration of the anatomy of the proximal femur.

Femoral neck fractures in the younger population are frequently associated with high-energy trauma. In this age group treatment is focussed on reduction and fixation of the fracture with preservation of the hip joint. Common complications include AVN of the femoral head, nonunion or shortening of the femoral neck<sup>[1]</sup>. Multiple percutaneous cannulated screws (PCS) have been historically the treatment of choice<sup>[2]</sup>. Nevertheless, in recent years controversies concerning reduction and fixation techniques have arisen<sup>[3,4]</sup>.

A certain amount of fracture compression is needed for the fracture to be heal. Excessive shortening or varus collapse can affect hip joint biomechanics, reducing the momentum of the abductor mechanism. These result in impaired hip function and significantly lower quality of life (QoL) index scores<sup>[5,6]</sup>.

In the present study we compared two different types of fixation devices in the young population (< 55 years). We also analyzed femoral neck shortening and secondary varus collapse with both kinds of treatment. Finally, we also compared results to find if there was any correlation between clinical outcome and secondary displacement.

## PATIENTS AND METHODS

Sixty-six consecutive patients with a femoral neck fracture between January 2008 and January 2016 were prospectively evaluated. Inclusion criteria included every patient with femoral neck fracture < 55 years old attended at our department during the study period and treated by bone fixation. The senior surgeon in each case made the decision regarding which type of fixation was required by each patient. Exclusion criteria included all patients treated with an arthroplasty or presenting a pathologic fracture.

All fractures underwent closed reduction under spinal anesthesia on a fracture table with a maneuver of traction and internal rotation. Most of patients were operated within 24 hours of admission but there were patients that it could not be possible because they had another associated fractures. Fractures were fixed under fluoroscopy guidance either by three 7.3 mm PCS (Depuy Synthes, Oberdorf, Switzerland) in an inverted triangle configuration (Figure 1) or by a Dynamic Hip Screw (DHS, Depuy Synthes, Oberdorf, Switzerland) (Figure 2) by means of open reduction and internal fixation (ORIF). Weight bearing was not allowed for 8 to 12 weeks. Thromboprophylaxis with a low weight heparin for 30 days was carried out. Postoperative antimicrobial prophylaxis with cefazolin (vancomycin if allergic) for 48 hours was employed.

Anteroposterior and lateral radiographs of the pelvis with a standard technique at the time of fracture were used to evaluate fracture pattern. Fractures were classified according to the Orthopaedic Trauma Association (OTA) classification<sup>[7]</sup>. Garden's and Pauwels' classifications were also used to describe the different fracture patterns<sup>[8,9]</sup>. Medial or posterior femoral neck cortex comminution was also recorded.

Anteroposterior and lateral radiographs of the pelvis at the time of follow-up were used to evaluate quality of reduction, secondary displacement, bone healing and presence of degenerative changes in the hip joint. The contralateral hip was used to assess femoral neck shortening and secondary varus collapse.

We divided the degree of shortening into two groups: moderate (< 5 mm) or severe (> 5 mm), and the degree of varus collapse into two groups: moderate (< 7°) or severe (> 7°). The known diameter of the fixation devices was used as internal validation measures.

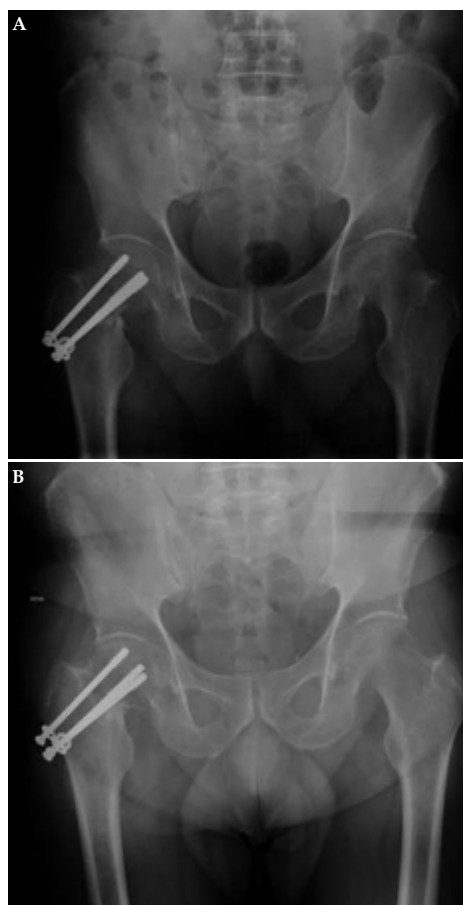
Patients were evaluated clinically and radiographically by an independent orthopaedic surgeon who was not involved in the surgery

at one month, three months, six months, one year and two years after surgery. Reduction of the fracture was classified as optimal (< 2 mm of displacement, a fracture gap < 2 mm and anatomical or slight valgus angulation) suboptimal (if only two items were achieved), or deficient. The quality of the fixation was also assessed<sup>[10]</sup>. We used the Harris Hip Score for clinical assessment<sup>[11]</sup>. Euroqol-5D (EQ5D) scores were employed to report QoL following the fracture. Categories of the EQ5D included mobility, self-care, usual activities, anxiety/depression and pain/discomfort.

The fracture was considered healed when radiographs showed three cortices of bony bridging or trabecula trespassing the fracture site and weight bearing was possible without significant pain. Radiographs were examined for signs of AVN or nonunion. Union was considered to be delayed if time to bone healing was greater than 6 months from the time of injury. There was considered to be nonunion if bone healing had not occurred after 9 months following injury.

Malunion was defined as femoral neck shortening greater than 5 mm or if there was a varus angulation of more than 7 degrees. The presence of posttraumatic osteoarthritis of the hip was evaluated according to Kellgren and Lawrence criteria<sup>[12]</sup>.

We compared any grade of varus collapse and shortening of the femoral neck with regards to age, gender, energy, associated fractures, side, fracture classification (Garden, Pauwels and OTA), medial or posterior comminution, type of fixation, quality of reduction and fixation, functionality according to the Harris scale and QoL according to the EQ5D scale. Statistical Package for Social Sciences (SPSS 12.0, Chicago, IL) was used for analysis in this study. The level of statistical significance was set at  $p < 0.05$ .



**Figure 1 (A-B)** Patient treated with three percutaneous cannulated screws (PCS) (A). Radiographs showed shortening after 2 years (B).

## RESULTS

Mean age at the time of the fracture was of 44.1 years (range, 25-55). Fractures were followed up for a mean of 3.2 years (range, 2-5). No patient was lost to follow-up during the study period. There were 41 men (62.1%) and 25 women (37.9%) involving 36 right hip fractures (54.6%) and 30 left fractures (45.4%). Out of a total of 66 fractures, 49 were high-energy fractures (74.2%) and 17 low-energy ones (25.8%). Twenty patients (30.6%) sustained one or more additional fractures. There were 11 polytrauma patients (7 with pelvic fractures and 5 with an associated fracture of the upper extremity). Fifteen (22.7%) patients presented associated injuries (5 distal radius fractures, 4 rib fractures, 3 ankle fractures, 2 proximal humeral fractures, and 1 tibial shaft fracture). At the time of the injury, ten patients were taking corticosteroids, 14 were smokers, 4 had diabetes mellitus and 15 were consuming alcohol (Table 1).

The radiographic classification included: 28 Garden I fractures, 17 Garden II, 15 Garden III and 6 Garden IV fractures. There were 22 Pauwels I, 24 Pauwels II and 20 Pauwels III (Table 1). Thus, there were 32 displaced fractures and 34 undisplaced fractures (Table 2).

Mean time to surgery following injury was of 1.2 days (range, 1-2). 37 patients (56.1%) were managed with PCS (Depuy Synthes, Oberdorf, Switzerland) after closed reduction of the fracture. 29 fractures (43.9%) were managed by DHS (Depuy Synthes, Oberdorf, Switzerland) and an additional cannulated screw in the upper third of the femoral head for rotational stability (Table 1).

There was no statistically significant difference regarding the type of fracture (type, mechanism, associated lesions) or patient demographics between both groups.

Forty-three patients had optimal reduction, 19 suboptimal, and 4 unsatisfactory. According to the quality of the fixation, in 43 cases was optimal, 20 suboptimal and in 3 unsatisfactory (Table 1).

There were no statistically significant differences regarding age, gender, mechanism, associated lesions, the type of fracture (Garden, Pauwels, OTA), fracture comminution, quality of the reduction, quality of the osteosynthesis and collapse or degree of varus deformity (Table 3).

Mean varus collapse was 8.1° (range, 1-15°). 40 fractures (60.6%) showed severe varus collapse and 26 fractures (39.4%) showed moderate varus collapse (Table 4).

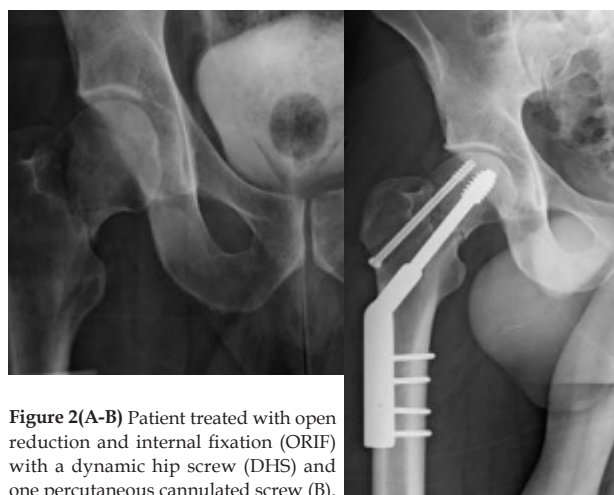
Of the 40 fractures showing severe varus collapse, 10 (of the 29 treated with this system) were treated with DHS and 30 patients (of the 37) were treated with PCS (Table 5).

Mean femoral neck shortening was 6.2 mm (range, 1-13). Thirty-nine hips (59.1%) presented severe shortening of the femoral neck and 27 hips (40.9%) presented moderate shortening (Table 6).

Of the 39 fractures with evidence of severe shortening, 9 were treated with DHS (23.1%) and 30 using PCS (76.9%) (Table 7).

Severe varus collapse ( $> 7^\circ$ ) was more frequent in fractures fixed with PCS than fractures fixed with DHS (75% CS vs 25% DHS) ( $p = 0.002$ ). Odds ratio was of 8.14 (CI 95% 2.64-25.5). Severe femoral neck shortening ( $> 5$  mm) was also higher in the PCS group (76.9% CS vs 23.1% DHS) ( $p = 0.001$ ). Odds ratio was of 9.52 (CI 95% 3.05-29.73) (Table 3).

Mean Harris Hip Score was of 84 points at the end of the follow-up. The distribution included 6 patients having a poor result, 21 patients fair, 29 patients good and 10 patients excellent. Forty-nine patients (66%) showed good functional results according to EQ5D, and 17 patients showed fair or poor results (34 %) (Table 1). Patients following AVN or with severe shortening and varus collapse presented lower QoL scores, but the difference was not statistically



**Figure 2(A-B)** Patient treated with open reduction and internal fixation (ORIF) with a dynamic hip screw (DHS) and one percutaneous cannulated screw (B).

significant, probably due to the small sample size.

Complications included one loss of reduction after PCS that required a new fixation with a DHS.

There was one peri-implant fracture that required revision to an arthroplasty and 6 cases (9.1%) of AVN of the femoral head (three with PCS, that appeared at 15 months, 18 months and 20 months after the surgery and three with DHS, 36 months, 38 months and 40 months after the surgery). All cases of AVN required a total hip arthroplasty. There were no cases of nonunion. In total there were 7 re-interventions, four were Garden III fractures and three Garden IV.

## DISCUSSION

Femoral neck fracture remains as the unsolved fracture. Its management remains controversial especially in the young age group where the more predictable result of an arthroplasty is not recommended. PCS remains as the preferred method of treatment in undisplaced fractures. DHS and PCS are used equally in displaced fractures<sup>[2]</sup>.

PCS fixation offers a less invasive procedure with reduced blood loss, surgical time and soft tissue damage. Screws offer compression of the fracture site, but anatomic reduction is essential. In our series, most of the fractures were anatomically reduced by closed means. The quality of the osteosynthesis was also good and most of the fractures healed well. A wide distance between the anterior and posterior screws in the lateral X-ray is necessary to provide a rotationally stable construct<sup>[13]</sup>.

DHS provides better stability than multiple PCS in vertically unstable fractures. DHS transfer bending moments from the head and neck of the femur to the screw, barrel and the plate fixed at the femoral shaft cortex<sup>[14]</sup>. This has not been tested clinically yet. DHS offers a more stable construct but requires extensive soft tissue dissection and a longer surgical time with greater blood loss. The DHS with an additional screw showed the lowest femoral head displacement and interfragmentary movement for stabilizing a vertical femoral neck fracture<sup>[15]</sup>. Siavashi comparing prospectively PCS vs DHS found better results with less failure of fixation with the DHS<sup>[16]</sup>. When we compared both fixation methods, secondary displacement was most frequent with PCS. In our practice, vertically unstable femoral neck fractures are managed with DHS+one PCS. One case treated with PCS became displaced in the first 24 hours and was managed with DHS+one PCS<sup>[16]</sup>. It seems that DHS is a better option in femoral neck fractures in young patients<sup>[17]</sup>. New implants have tried to fix these fractures percutaneously with angular stability.

**Table 1** Distribution of variables depending on the type of implant in this series (N=66).

Parameters	Dynamic hip screw (DHS) n=29	Percutaneous cannulated screws (PCS) n=37
Age	42.6 years (35-50)	45.6 years (25-55)
Gender	20 male, 9 female	21 male, 16 female
Side	20 right, 9 left	16 right, 21 left
Associated fractures	19 yes, 10 no	7 yes, 30 no
Energy	28 high, 1 low	21 high, 16 low
Garden	8 I, 8 II, 8 III, 5 IV	20 I, 9 II, 7 III, 1 IV
Pauwels	12 I, 12 II, 5 III	10 I, 12 II, 15 III
OTA (Orthopaedic Trauma Association)	5 (31B1), 10 (31B2), 11 (31B3)	4 (31B1), 22 (31B2), 11 (31B3)
Medial comminution	12 yes, 17 no	9 yes, 28 no
Posterior comminution	7 yes, 22 no	7 yes, 30 no
Reduction	22 optimal, 5 suboptimal, 2 unsatisfactory	21 optimal, 14 suboptimal, 2 unsatisfactory
Osteosynthesis	21 optimal, 8 suboptimal	22 optimal, 12 suboptimal, 3 deficient
Euroqol-5D (E5D) scale	23 good, 6 fair-poor	26 good, 11 fair-poor
Harris scale	7 excellent, 18 good, 2 fair, 2 poor	3 excellent, 11 good, 19 fair, 4 poor

**Table 2** Type of implant based on the type of femoral neck fracture.

	DISPLACED	UNDISPLACED
PCS	15	22
DHS (ORIF)	17	12

PCS: percutaneous cannulated screws; DHS (ORIF): dynamic hip screw (open reduction and internal fixation).

**Table 3** Statistical analysis between each variable and grade of varus collapse and shortening of the femoral neck.

Parameters	Varus collapse (<7° / >7°)	Shortening (< 5 mm / > 5 mm)
Implant (PCS, DHS)	S ( $p = 0.002^*$ )	S ( $p = 0.001^*$ )
Age	NS ( $p = 0.56$ )	NS ( $p = 0.36$ )
Gender	NS ( $p = 0.65$ )	NS ( $p = 0.63$ )
Side	NS ( $p = 0.21$ )	NS ( $p = 0.36$ )
Associated fractures	NS ( $p = 0.23$ )	NS ( $p = 0.32$ )
Energy	NS ( $p = 0.31$ )	NS ( $p = 0.21$ )
Garden	NS ( $p = 0.8$ )	NS ( $p = 0.23$ )
Pauwels	NS ( $p = 0.88$ )	NS ( $p = 0.95$ )
OTA	NS ( $p = 0.69$ )	NS ( $p = 0.94$ )
Medial comminution	NS ( $p = 0.41$ )	NS ( $p = 0.1$ )
Posterior comminution	NS ( $p = 1$ )	NS ( $p = 0.21$ )
Reduction	NS ( $p = 0.92$ )	NS ( $p = 0.2$ )
Osteosynthesis	NS ( $p = 0.53$ )	NS ( $p = 0.8$ )
Euroqol-5D (E5D) scale	NS ( $p = 0.41$ )	NS ( $p = 0.23$ )
Harris scale	NS ( $p = 0.23$ )	NS ( $p = 0.54$ )

PCS: percutaneous cannulated screws; DHS (ORIF): dynamic hip screw (open reduction and internal fixation). OTA: Orthopaedic Trauma Association. Statistically significant differences with  $p < 0.05$  \* (S: Significant; Ns: Not significant)

Nevertheless they have not improved the rate of AVN<sup>[18]</sup>.

Few studies compare PCS vs DHS. PCS showed less reduction in femoral head vascularization than DHS<sup>[19]</sup>. Parker and Blundell analyzed the use of these implants for internal fixation. They reviewed 25 randomized trials and concluded that most studies have had an insufficient number of subjects to permit a valid comparison. Most of the data came from retrospective studies in elderly populations following falls with low energy trauma<sup>[20]</sup>.

Femoral neck fractures in young patients show a more vertical and unstable pattern and are caused by high-energy trauma. In this group of unstable fractures fixed angle devices present less mechanical

**Table 4** Distribution of varus collapse in this series.

Varus collapse	< 7°	> 7°	Mean (range)
	26	40	8.1° (1-15°)

**Table 5** Distribution of shortening in this study.

Shortening	< 5mm	> 5 mm	Mean (range)
	27	39	6.2 mm (1-13 mm)

**Table 6** Severity of varus collapse based on the type of implant.

	< 7°	> 7°	TOTAL
DHS (ORIF)	19	10	29
PCS	7	30	37

PCS: percutaneous cannulated screws; DHS (ORIF): dynamic hip screw (open reduction and internal fixation).

**Table 7** Severity of shortening based on the type of implant in this study.

	< 5 mm	> 5 mm	TOTAL
DHS (ORIF)	20	9	29
PCS	7	30	37

PCS: percutaneous cannulated screws; DHS (ORIF): dynamic hip screw (open reduction and internal fixation).

failures<sup>[3]</sup>. The most stable implants for vertical neck fractures are proximal locking plates but they have catastrophic failures in clinical practice<sup>[21,22]</sup>. These fractures require compression to heal. However, the exact amount of compression needed to heal without excessive shortening is not known. We found a mean femoral neck collapse of almost 6 mm with no cases of nonunion. The fracture tends to collapse during the first postoperative months<sup>[23]</sup>.

The goal in every hip fracture, especially in this age group, is to restore patient function. In spite of fracture healing these patients can present a poor clinical outcome due to excessive femoral neck shortening or distorted anatomy and altered hip mechanics<sup>[5,6]</sup>.

Rotational stability of this fracture pattern has not been well documented so far. The rotational stability is difficult to assess using plain X-ray and techniques such as RSA (radiostereometric analysis, a special way of taking two X-rays from different directions at the same time, creating a "stereo" image) are difficult to use in fractures. Different fixation methods provide similar rotational stability<sup>[23,24]</sup>. We found greater axial displacement in fractures treated with PCS. Nevertheless, this was not correlated with clinical results. Patients

with shortening and varus collapse did not present differences with regards to their clinical results. A worse clinical outcome was correlated with the appearance of AVN or other complications. The amount of femoral neck shortening or varus displacement needed to affect hip function is not clearly defined. Zlowodzki in a group of 127 patients treated with PCS found shortening in 66% of the patient and varus in 39%. Severe shortening ( $> 10$  mm) was correlated with a lower SF-36<sup>[5]</sup>. In our study we found less shortening and varus collapse, the particular group of patients treated with a DHS might explain this difference.

The main predictors of AVN of the femoral head following subcapital fractures are the patient's age, the amount of fracture displacement and the configuration of fracture fixation. The rate of AVN is higher in the younger age group, but the cause remains unclear<sup>[25,26]</sup>. The incidence of AVN is higher in the young adult group. One prospective study involving 1023 patients with hip fractures found the incidence of AVN to be 20.6% for patients under the age of 60 and 12.5% for those between 60 and 80 years old<sup>[27]</sup>. The incidence of AVN in the present study was of 9.1%, which is less than the 10% to 30% reported prevalence in the literature<sup>[1,28-31]</sup>. We found no difference in the rate of AVN when we comparing both fixation methods. The extra tissue damage associated with a DHS did not influence fracture healing or the incidence of AVN. No posttraumatic osteoarthritis was found in this series.

There is a lack of consensus and limited clinical evidence in the management of femoral neck fractures in younger patients. The main limitations of our study are the following: (1) the reduced number of patients with different fracture patterns; (2) treatment was not randomized but based on surgeon choice; (3) the incidence of AVN in the present study was of 9.1%, which is less than the 10% to 30% reported prevalence in the literature with large samples; therefore, the extra tissue damage associated with a DHS did not influence fracture healing or the incidence of AVN. We believe that these results are due to our limited patients.

In conclusion, bone fixation with PCS of femoral neck fractures in young patients ( $< 55$  years) provided reliable results. However, we found less secondary displacement with DHS compared to PCS. All the above shortcomings will lead to that our conclusion is not fully reliable. Therefore, larger cohorts with randomization of the fixation method would be necessary to improve and add further weight to our conclusions.

## REFERENCES

- Damany DS, Parker MJ, Chojnowski A. Complications after intracapsular hip fractures in young adults: a meta-analysis of 18 published studies involving 564 fractures. *Injury* 2005; **36(1)**: 131-41.
- Slobogean GP, Sprague SA, Scott T, McKee M, Bhandari M. Management of young femoral neck fractures: is there a consensus?. *Injury*. 2015; **46(3)**: 435-40.
- Liporace F, Gaines R, Collinge C, Haidukewych GJ. Results of internal fixation of Pauwels type-3 vertical femoral neck fractures. *J Bone Jt Surg Am* 2008; **90-A(8)**: 1654-9.
- Gardner S, Weaver MJ, Jerabek S, Rodriguez E, Vrahas M, Harris M. Predictors of early failure in young patients with displaced femoral neck fractures. *J Orthop*. 2015; **12(2)**: 75-80.
- Zlowodzki M, Brink O, Switzer J, Wingert S, Woodall Jr J, Petrisor BA, et al. The effect of shortening and varus collapse of the femoral neck on function after fixation of intracapsular fracture of the hip: a multi-centre cohort study. *J Bone Joint Surg Br* 2008; **90-B(11)**: 1487-94.
- Zlowodzki M, Ayieni O, Petrisor BA, Bhandari M. Femoral neck shortening after fracture fixation with multiple cancellous screws: incidence and effect on function. *J Trauma* 2008; **64(1)**: 163-9.
- Marsh JL, Slongo TF, Agel J, Broderick JS, Creevy W, DeCoster TA, et al. Fracture and dislocation classification compendium - 2007: Orthopaedic Trauma Association classification, database and outcomes Committee. *J Orthop Trauma*. 2007; **21(Suppl 10)**: S1-S163.
- Van Embden D, Rhemrev SJ, Genelin F, Meylaerts SA, Roukema GR. The reliability of a simplified Garden classification for intracapsular hip fractures. *Orthop Traumatol Surg Res*. 2012; **98(4)**: 405-8.
- Schwarz N. Actual relevance of Pauwels' classification of femoral neck fractures a critical review. *Z Orthop Unfall*. 2010; **148 (2)**: 191-7.
- Baumgaertner MR, Curtin SL, Lindskog DM, Keggi JM. The value of the tip-apex distance in predicting failure of fixation of displaced intracapsular fractures of the hip. *J Bone Joint Surg Am*. 1995; **77-A(7)**: 1058-64.
- Harris WH. Traumatic arthritis of the hip after dislocation and acetabular fractures: Treatment by mold arthroplasty. An end result study using a new method of result evaluation. *J Bone Joint Surg Am* 1969; **51(4)**: 737-55.
- Kellgren JH, Lawrence JS. Radiological assessment of osteoarthritis. *Ann Rheum Dis* 1957; **16(4)**: 494-502.
- Gurusamy K, Parker MJ, Rowlands TK. The complications of displaced intracapsular fractures of the hip. The effect of screw positioning and angulation on fracture healing. *J Bone Joint Surg Br* 2005; **87-B(5)**: 632-4.
- Deneka DA, Simonian PT, Stankewich CJ, Eckert D, Chapman JR, Tencer AF. Biomechanical comparison of internal fixation techniques for the treatment of unstable basicervical femoral neck fractures. *Journal of orthopaedic trauma*. 1997; **11(5)**: 337-43.
- Samsami S, Saberi S, Sadighi S, Rouhi G. Comparison of three fixation methods for femoral neck fracture in young adults: Experimental and numerical investigations. *J Med Biol Eng*. 2015; **35(5)**: 566-79.
- Siavashi B, Aalirezaei A, Moosavi M, Golbakhsh MR, Savadkoobi D, Zehtab MJ. A comparative study between multiple cannulated screws and dynamic hip screw for fixation of femoral neck fracture in adults. *Int Orthop*. 2015; **39(10)**: 2069-71.
- Gardner S, Weaver MJ, Jerabek S, Rodriguez E, Vrahas M, Harris M. Predictors of early failure in young patients with displaced femoral neck fractures. *J Orthop*. 2014; **12(2)**: 75-80.
- Osarumwense D, Tissingh E, Wartenberg K, Aggarwal S, Ismail F, Orakwe S, Khan F. The Targon FN system for the management of intracapsular neck of femur fractures: minimum 2-year experience and outcome in an independent hospital. *Clin Orthop Surg*. 2015; **7(1)**: 22-8.
- Linde F, Andersen E, I-bass I, Madsen F, Pallesen R. Avascular femoral head necrosis following fracture fixation. *Injury* 1986; **17(3)**: 159-63.
- Parker MJ, Blundell BR. Choice of implants for internal fixation of femoral neck fractures: meta analysis of 25 randomized trials including 4,925 patients. *Acta Orthop Scand* 1998; **69(2)**: 138-43.
- Aminian A, Gao F, Fedoriw WW, Zhang LQ, Kalainov DM, Merk BR. Vertically oriented femoral neck fractures: mechanical analysis of four fixation techniques. *J Orthop Trauma* 2007; **21(8)**: 544-8.
- Berkes MB, Little MT, Lazaro LE, Cymerman RM, Helfet DL, Lorich DG. Catastrophic failure after open reduction internal fixation of femoral neck fractures with a novel locking plate implant. *J Orthop Trauma* 2012; **26(10)**: e170-6.
- van Embden D, Stollenwerck GA, Koster LA, Kaptein BL, R. Nelissen RG, Schipper IB. The stability of fixation of proximal femoral fractures a radiostereometric analysis. *Bone Joint J* 2015; **97-B(3)**: 391-7.
- Blair B, Koval KJ, Kummer F, Zuckerman JD. Basicervical

- fractures of the proximal femur. A biomechanical study of 3 internal fixation techniques. *Clin Orthop Relat Res* 1994; **306**: 256-63.
25. Loizou CI, Parker MJ. Avascular necrosis after internal fixation of intracapsular hip fractures; a study of the outcome for 1023 patients. *Injury* 2009; **40(11)**: 1143-6.
  26. Yang JJ, Lin LC, Chao KH, Chuang SY, Wu CC, Yeh TT, et al. Risk factors for nonunion in patients with intracapsular femoral neck fractures treated with three cannulated screws placed in either a triangle or an inverted triangle configuration. *J Bone Joint Surg Am* 2013; **95-A(1)**: 61-9.
  27. Ly TV, Swiontkowski MF. Treatment of femoral neck fractures in young adults. *J Bone Joint Surg Am* 2008; **90-A(10)**: 2254-66.
  28. Duckworth AD, Bennet SJ, Aderinto J, Keating JF. Fixation of intracapsular fractures of the femoral neck in young patients. Risk factors for failure. *J Bone Joint Surg Br* 2011; **93-B(6)**: 811-6.
  29. Haidukewych GJ, Rothwell WS, Jacofsky DJ, Torchia ME, Berry DJ. Operative treatment of femoral neck fractures in patients between the ages of fifteen and fifty years. *J Bone Joint Surg Am* 2004; **86-A(8)**: 1711-6.
  30. Talboys R, Pickup L, Chojnowski A. The management of intracapsular hip fractures in the 'young elderly': Internal fixation or total hip replacement? *Acta Orthop Belgica* 2012; **78(1)**: 41-8.
  31. Asnis SE, Wanek-Sgaglione L. Intracapsular fractures of the femoral neck. Results of cannulated screw fixation. *J Bone Joint Surg Am* 1994; **76-A(12)**: 1793-803.

**Peer Reviewer:** Wei Sun