

Principles of the Superior Capsule Reconstruction of the Shoulder

Jose Carlos Garcia Jr., Matheus R. Barcelos, Felipe Machado do Amaral, Mauricio de Paiva Raffaelli, Álvaro Motta Cardoso Jr.

Jose Carlos Garcia Jr., Matheus R. Barcelos, Felipe Machado do Amaral, Mauricio de Paiva Raffaelli, Álvaro Motta Cardoso Jr., NAEON Institute São Paulo- Brazil

Conflict-of-interest statement: The author(s) declare(s) that there is no conflict of interest regarding the publication of this paper.

Open-Access: This article is an open-access article which was selected by an in-house editor and fully peer-reviewed by external reviewers. It is distributed in accordance with the Creative Commons Attribution Non Commercial (CC BY-NC 4.0) license, which permits others to distribute, remix, adapt, build upon this work non-commercially, and license their derivative works on different terms, provided the original work is properly cited and the use is non-commercial. See: <http://creativecommons.org/licenses/by-nc/4.0/>

Correspondence to: Jose Carlos Garcia Jr., NAEON Institute São Paulo, Brazil.

Email: josecarlos@naeon.org.br

Received: September 14, 2018

Revised: November 18, 2018

Accepted: November 20, 2018

Published online: February 28, 2019

ABSTRACT

Massive rotator cuff tears, involving the posterosuperior rotator cuff, remain difficult to treat particularly in the younger population. Fatty infiltration of the muscle, excessive chronic tendon retraction, and degeneration are the main irreversible factors predisposing to high failure rates of direct repair. There are many techniques for Superior Capsular Reconstruction (SCR) mainly using allograft. However low accessibility to the dermal grafts in many countries led the authors to use and suggest autograft of the fascia lata as other option for the reconstruction of the superior capsule of the shoulder. The SCR have presented good functional and biomechanical results. These techniques are reliable options for irreparable lesions of the rotator cuff.

Key words: Rotator cuff; Shoulder pain; Tendon injuries; Superior capsular reconstruction

© 2019 The Author(s). Published by ACT Publishing Group Ltd. All rights reserved.

Garcia JC, Barcelos MR, Amaral FM, Raffaelli MP, Cardoso AM. Principles of the Superior Capsule Reconstruction of the Shoulder. *International Journal of Orthopaedics* 2019; 6(1): 1012-1015 Available from: URL: <http://www.ghrnet.org/index.php/ijo/article/view/2437>

INTRODUCTION

Massive rotator cuff tears, involving the posterosuperior rotator cuff, remain difficult to treat particularly in the younger population.

With an arthroscopic, or open approach, rotator cuff repair is possible in the majority of cases and functional outcomes are improved.

The term “irreparable” has been used with different meanings in the past. For example, the term was frequently used when partial repair of the rotator cuff was performed^[1].

More recently, a subtle change in meaning was adopted. The term “irreparable” began to be used to describe a rotator cuff that was either (1) predicted to be irreparable based on preoperative characteristics; or (2) predicted to have a poor outcome from rotator cuff surgery, regardless of the possibility of achieving current intraoperative repair^[2].

Fatty infiltration of the muscle, excessive chronic tendon retraction, and degeneration are the main irreversible factors predisposing to high failure rates of direct repair. Some authors say that the term irreparable should only be applied intraoperatively^[1].

Hanada et al first described a “superior capsular reconstruction” of the glenohumeral joint as a revision operation in a paraplegic patient with an irreparable supraspinatus tendon tear^[1,3]. During a postoperative follow-up, 1.2 years after the surgery, pain persisted as well loss of function. Muscle strength and endurance deteriorated to “fair”. In summary, the overall result was unsatisfactory^[3].

During cadaveric studies of patch graft surgery, for irreparable rotator cuff tears, Mihata et al discovered that the graft should be attached

medially to the superior glenoid and laterally to the greater tuberosity in order to restore superior stability of the humeral head^[4].

After clinical studies, Mihata *et al* reported on the use of fascia lata autograft to arthroscopically reconstruct the superior capsule of twenty-four shoulders, in twenty-three patients, all with large, irreparable rotator cuff tears. Reported outcomes of this study were excellent, with significant improvements in pain, function, and range of motion in forward flexion and abduction, beside the increase of the subacromial space shown in radiography^[5].

While reported outcomes were favorable, it is important to note this technique increases surgical time and carries donor-site morbidity. Hirahara and Adams subsequently proposed the use of dermal allograft for Superior Capsular Reconstruction (SCR) as opposed to fascia lata^[6,7]. Dermal allografts limit donor-site morbidity, have been used previously in augmentation of rotator cuff repairs, and have been used clinically for SCR^[6].

Despite growing interest in the use of these techniques with the dermal allograft technology, their cost is a potential impediment^[8].

It is important to note that other new techniques, which use the Long Head of the Biceps Tendon (LHBT) as autologous graft, with partial repair of the rotator cuff or side-by-side suture, have also been described by several authors^[8-11].

ANATOMY AND BIOMECHANICS

The anatomy of the glenohumeral joint capsule is not uniform for all^[12]. The cuff and superior capsule are a mix of blended fibers^[13]. Thus, the superior capsule serves to transmit force from the cuff musculature to the bone, and to reinforce tendon insertions. In this manner, the superior capsular complex contributes to active glenohumeral stability.

Anatomical studies have revealed a larger insertional footprint of the superior capsule than had previously been recognized: from 5 to 9 mm in medial–lateral width at the anterior and posterior margins^[14,15]. The superior capsule is connected to 30% and 61% of the greater tuberosity and can have a larger footprint on the greater tuberosity than the supraspinatus. Therefore demonstrating that the superior capsular complex is critical for passive glenohumeral stability^[15].

INDICATIONS

Indications for Superior Capsule Reconstruction (SCR) surgery, are those patients with irreparable rupture of the rotator cuff, those with pseudoparalysis, those who may have already undergone treatment or not, upper instability that can be observed as ascending humeral head, and/or young patients who are not candidates for reverse shoulder arthroplasty^[1,9,16,17]. Patients presenting with evidence of a Hamada IV classification (or greater), advanced arthritic changes, and poor deltoid function are all relative contraindications to this procedure^[16].

DIAGNOSIS

Magnetic Resonance Imaging should be consistent with an irreparable rotator cuff tendon tear and demonstrate a retraction greater than 3 cm, along with Grade 3 changes of the supraspinatus or Grade 2 changes of the infraspinatus on sagittal oblique imaging^[18]. Plain radiographs also need to be obtained to rule out significant arthritis, confirm superior instability, and superior dislocation of the humeral head.

PHYSICAL EXAMINATION

Rotator cuff strength is assessed initially by testing the resisted external rotation (to detect tears of the supraspinatus, infraspinatus, and

teres minor). A positive Hornblower's Test and Lag Sign indicate involvement of the supraspinatus, infraspinatus, and teres minor. In addition, subscapularis function is tested by means of the Bear Hug, Belly Press, and Lift-Off Tests^[19].

SURGICAL TECHNIQUES

These techniques require an experienced surgeon and surgical team, in addition to the appropriate (sometimes considerable) time needed to complete the procedure. Preparation of the joint, before beginning the reconstruction of the upper capsule, is of the utmost importance.

Acromioplasty can be performed to improve visualization of the subacromial space, but some authors preserve the coracoacromial ligament in massive cuff surgery^[1].

Biceps tenotomy for elder and tenodesis of the biceps for the younger patients can be performed according to the surgeon's preference.

Partial cuff repair is almost always possible and should be performed routinely to improve the forward range of motion^[1], and avoid possible suprascapular nerve compression.

The subscapularis tendon should be sutured in the minor tubercle, according to the surgeon's technical preference, as it plays an important role in the static and dynamic stability of the shoulder. Without a functional subscapularis suture, the reconstruction of the upper capsule may fail.

Release of the teres minor and infraspinatus should be done to cover as much area as possible during the repair. The posterior interval slide technique is a viable option to improve tendon mobility. Good postero-lateral coverage improves the prognosis of external rotation in the postoperative period, since the upper capsule will be the stabilizer that will make the fulcrum of the glenohumeral joint, while the remaining tendons move the joint.

Exposure of the glenoid should be extensive, with removal of all tissue from the supraglenoid tubercle for easy identification of future anchor location.

Mihata *et al.* inserted the anchors into the superior glenoid at the 10 to 11 o'clock and 11 to 12 o'clock positions on the glenoid of the right shoulder (or the 1 to 2 o'clock and 12 to 1 o'clock positions of the left shoulder)^[5].

The Nevasier Portal and accessory portals anterior and posterolateral should be used when necessary. Angle placement of the anchor is critical, as there must be no invasion of the joint. If the distance between the anchors is greater than 35 mm a third anchor may be used.

The major tuberosity of the humerus is prepared by removing all remaining tissue leaving a propitious and scarified bone area.

A millimetered probe is used to measure the anteroposterior distance to the glenoid, the anteriorposterior distance to the great tubercle, and the medial lateral distances. A made-to-measure graft is then fashioned based on these specific measurements.

To provide tissue for fixation, 5 mm is added to the medial, anterior, and posterior dimensions and 15 mm is added to the lateral dimension, to account for the rotator cuff footprint^[17,20].

A vertical skin incision is made, over the lateral thigh and around the greater trochanter of the femur. A section of fascia lata 2 to 3 times the size of the superior capsular defect is harvested, after which a graft 6 to 8 mm thick is fashioned by folding the fascia Lata twice or thrice as necessary (Figures 1 and 2).

The glenoid anchor wires should be arranged on the graft before the latter is transported through the cannula in the lateral portal and guided to its location in the glenoid. There are successful several variations of this strategy, which depend on the choice of glenoid an-

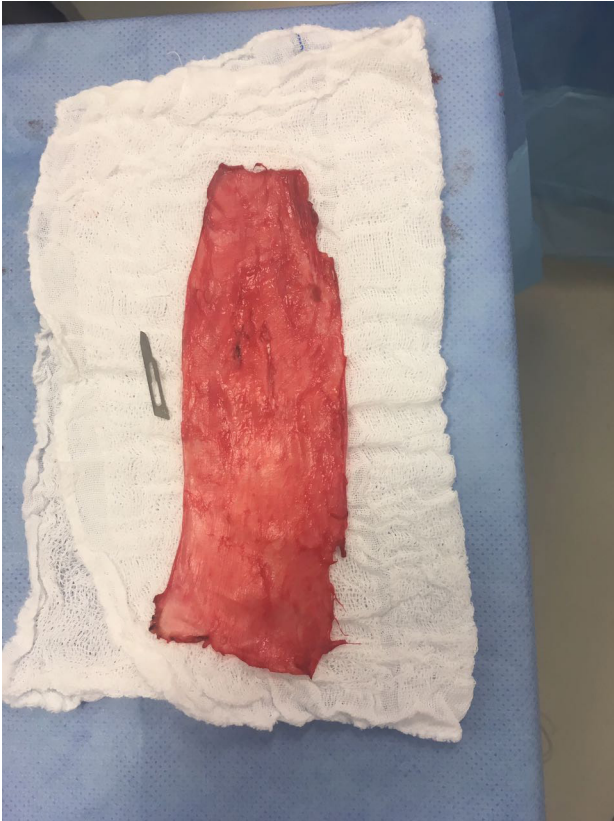


Figure 1 Fascia Latagraft.

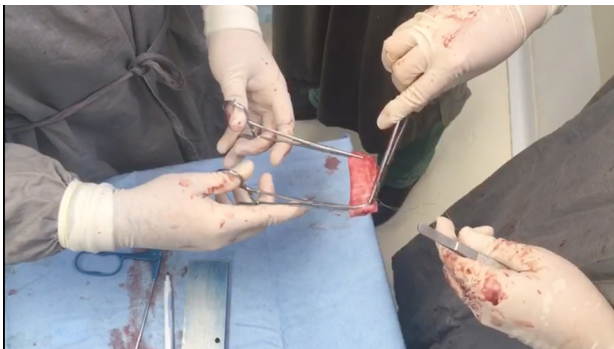

Figure 2 Fascia Lata preparation for superior capsular reconstruction.

chor and the size of the graft.

Insertion of the graft into the joint is the most challenging part of the procedure (Figure 3). Several technical tips can help to prevent complications^[1].

The sutures in the medial row of the greater tuberosity are crossed over the graft and secured with 2 additional lateral suture anchors in a transosseous-equivalent style repair (Figure 4). This is done with 20° to 30° of arm abduction. Mihata, however, in his original paper references the use of 45° of abduction^[5].

The important concept to note is that, the graft should not be placed with laxity.

The graft is then sutured to the infraspinatus using 2 or 3 sutures in a simple fashion. This is not an optional step^[1,6,21].

Reconstruction of the upper capsule using the LHBT, consists of preserving the previously integrated bicipital insertion, evaluating the viability of the remaining LHBT with no excessive tendinitis or partial tears.

Repairable partial and/or full infraspinatus and subscapularis ten-

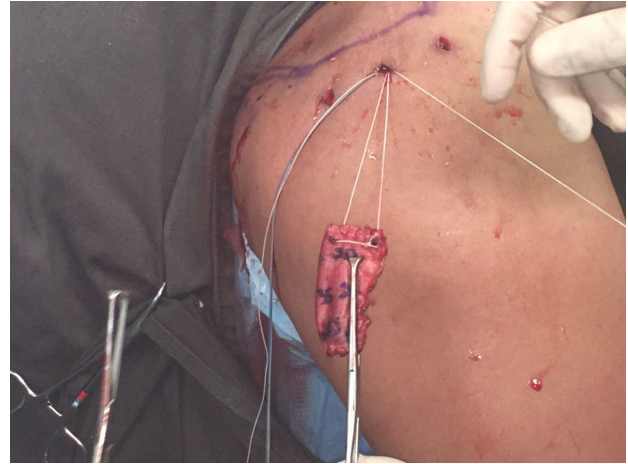

Figure 3 Insertion of the Graft.

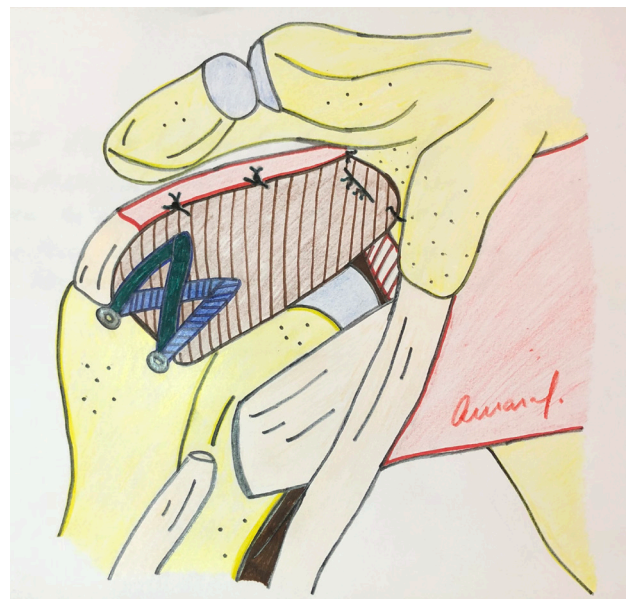


Figure 4 Capsular Superior Reconstruction scheme. (created by Dr Felipe do Amaral one of the authors).

don tears must be reconstructed to ensure the stabilizing force couple in the transverse plane^[8].

A 5.5 mm suture anchor is inserted approximately in the middle of the greater tuberosity (just behind the bicipital groove). The surgeon then passes all sutures through the intact LHBT, performing a “lasso-loop” configuration^[8]. (Figure 5).

After this, tenotomy with or without tenodesis is performed on the biceps distal to the suture. Sutures are then pulled and tied by placing the tendon in the desired position.

Side-to-side fixation of the infraspinatus and subscapularis with the LHBT is performed.

Postoperative radiographs should show down-migration of the humeral head after procedure^[7].

POSTOPERATIVE PROTOCOL

The use of an abduction pillow, for 4 weeks after the reconstruction surgery, is recommended. After the immobilization period, passive and active-assisted exercises were initiated.

Eight weeks after surgery, patients begin to perform exercises in order to strengthen the rotator cuff and scapula stabilizers with the as-

sistance of physical therapists^[5].

Active overhead motion strengthening exercises are not advised in the period up to four months after surgery. Thus allowing adequate time for allograft incorporation and cuff healing. High-demand activities are restricted for 1 year after surgery^[1].

Hirahara *et al*^[6] use musculoskeletal ultrasound to evaluate the dermal allograft. Subsequently showing that the graft is incorporated into the patient's body and transformed into host tissue. Vascularization was found using a Doppler 4-8 months after surgery, thus proving incorporation of the tissue.

CONCLUSION

The SCR technique has shown very good functional and biomechanical results. In the body of this article, several technical options are described using either a Dermal graft or less expensive alternatives such as fascia lata and LHB. As surgeons become more familiar with the SCR technique, the use of this surgery, as an option for irreparable lesions of the rotator cuff, will significantly increase.

REFERENCES

- Hartzler RU, Burkhart SS. Superior Capsular Reconstruction. *Orthopedics*. 2017; **40**(5): 271-280. [PMID: 29039871]; [DOI: 10.3928/01477447-20170920-02]
- Ek ET, Neukom L, Catanzaro S, Gerber C. Reverse total shoulder arthroplasty for massive irreparable rotator cuff tears in patients younger than 65 years old: results after five to fifteen years. *J Shoulder Elbow Surg*. 2013; **22**(9): 1199-1208. [PMID: 23385083]; [DOI: 10.1016/j.jse.2012.11.016]
- Hanada K, Fukuda H, Hamada K, Nakajima T. Rotator cuff tears in the patient with paraplegia. *J Shoulder Elbow Surg*. 1993; **2**(2): 64-69. [PMID: 22971671]; [DOI: 10.1016/1058-2746(93)90002-X]
- Mihata T, McGarry M, Pirolo J, Lee M. Superior Capsule Reconstruction to Restore Superior Stability in Irreparable Rotator Cuff Tears: A Biomechanical Cadaveric Study. *Am J Sports Med* 2012; **40**(10): 2248-55. [PMID: 22886689]; [DOI: 10.1177/0363546512456195]
- Mihata T, Lee TQ, Watanabe C, et al. Clinical results of arthroscopic superior capsule reconstruction for irreparable rotator cuff tears. *Arthroscopy* 2013; **29**(3): 459-70. [PMID: 23369443]; [DOI: 10.1016/j.arthro.2012.10.022]
- Hirahara AM, Adams CR. Arthroscopic superior capsular reconstruction for treatment of massive irreparable rotator cuff tears. *Arthrosc Tech* 2015; **4**(6): e637-e641. [PMID: 26870638]; [DOI: 10.1016/j.eats.2015.07.006]
- Denard PJ, Brady PC, Adams CR, Tokish JM, Burkhart SS. Preliminary Results of Arthroscopic Superior Capsule Reconstruction with Dermal Allograft. *Arthroscopy*. 2018; **34**(1): 93-99. [PMID: 29146165]; [DOI: 10.1016/j.arthro.2017.08.265]
- Boutsiadis A, Chen S, Jiang C, Lenoir H, Delsol P, and Barth J. Long Head of the Biceps as a Suitable Available Local Tissue Autograft for Superior Capsular Reconstruction: "The Chinese Way". *Arthroscopy Techniques* 2017; **6**(5): e1559-e1566. [PMID: 29354474]
- Hermanowicz K, Góralczyk A, Malinowski K, Jancewicz P, Domzalski M. Long Head Biceps Tendon Natural Patch for Massive Irreparable Rotator Cuff Tears. *Arthroscopy Techniques*, 2018; **7**(5): e473-e478. [PMID: 29868421]; [DOI: 10.1016/j.eats.2017.11.008]
- Chillemi C, Mantovani M, Gigante A. Superior capsular reconstruction of the shoulder: the ABC (Arthroscopic Biceps Chillemi) technique. *European Journal of Orthopaedic Surgery & Traumatology*. 2018; **28**(6): 1215-1223. [PMID: 29564612]; [DOI: 10.1007/s00590-018-2183-1.
- Kim YS, Lee HJ, Park I, Sung GY, Kim DJ, Kim JH. Arthroscopic In Situ Superior Capsular Reconstruction Using the Long Head of the Biceps Tendon. *Arthrosc Tech*. 2018; **7**(2): e97-e103. [PMID: 29354447]; [DOI: 10.1016/j.eats.2017.05.020]
- Adams CR, DeMartino AM, Rego G, Denard PJ, Burkhart SS. The Rotator Cuff and the Superior Capsule: Why We Need Both. *Arthroscopy*. 2016; **32**(12): 2628-2637. [PMID: 27916191]; [DOI: 10.1016/j.arthro.2016.08.011]
- Clark JM, Harryman DT II. Tendons, ligaments, and capsule of the rotator cuff: gross and microscopic anatomy. *J Bone Joint Surg Am*. 1992; **74**(5): 713-725. [PMID: 1624486]
- Nimura A, Kato A, Yamaguchi K, et al. The superior capsule of the shoulder joint complements the insertion of the rotator cuff. *J Shoulder Elbow Surg*. 2012; **21**(7): 867-872. [PMID: 21816631]; [DOI: 10.1016/j.jse.2011.04.034]
- Ishihara Y, Mihata T, Tomboli M, et al. Role of the superior shoulder capsule in passive stability of the glenohumeral joint. *J Shoulder Elbow Surg*. 2014; **23**(5): 642-8. [PMID: 24388150]; [DOI: 10.1016/j.jse.2013.09.025]
- Sethi P, Franco G. The Role of Superior Capsule Reconstruction in Rotator Cuff Tears. *Orthop Clin North Am*. 2018; **49**(1): 93-101. [PMID: 24388150]; [DOI: 10.1016/j.jse.2013.09.025]
- Sutter EG, Godin JA, Garrigues GE. All-Arthroscopic Superior Shoulder Capsule Reconstruction With Partial Rotator Cuff Repair. *Orthopedics*. 2017; **40**(4): e735-e738. [PMID: 28632288]; [DOI: 10.3928/01477447-20170615-01]
- Yoo JC, Ahn JH, Yang JH, Koh KH, Choi SH, Yoon YC. Correlation of arthroscopic reparability of large to massive rotator cuff tears with preoperative magnetic resonance imaging scans. *Arthroscopy* 2009; **25**(6): 573-82. [PMID: 19501285]; [DOI: 10.1016/j.arthro.2008.12.015]
- Burkhart SS, Denard PJ, Adams CR, Brady PC, and Hartzler RU. Arthroscopic Superior Capsular Reconstruction for Massive Irreparable Rotator Cuff Repair. *Arthrosc Tech*. 2016; **5**(6): e1407-e1418. [PMID: 28149739]; [DOI: 10.1016/j.eats.2016.08.024]
- Sanchez G, William H, Kyle P. Arthroscopic Superior Capsule Reconstruction Technique in the Setting of a Massive, Irreparable Rotator Cuff Tear. *Arthroscopy Techniques*. 2017; **6**(4): e1399-e1404. [PMID: 29354447]; [DOI: 10.1016/j.eats.2017.05.020]
- Mihata T, McGarry MH, Kahn T, et al. Biomechanical role of capsular continuity in superior capsule reconstruction for irreparable tears of the supraspinatus tendon. *Am J Sports Med*. 2016; **44**(6): 1423-30. [PMID: 26944572]; [DOI: 10.1177/0363546516631751]