

Surgical Treatment Options for Partial Rotator Cuff Tears: A Review of the Literature

Paul Borbas, MD, Greg Hoy, MBBS, FRACS, FAOrthA, FACSP

Paul Borbas, Greg Hoy, Melbourne Orthopaedic Group, Windsor, Victoria, Australia

Greg Hoy, Hand and Upper Limb Surgeon, Adjunct Associate Clinical Professor, Department of Surgery, Monash University, Victoria, Australia

Conflict-of-interest statement: The author(s) declare(s) that there is no conflict of interest regarding the publication of this paper.

Open-Access: This article is an open-access article which was selected by an in-house editor and fully peer-reviewed by external reviewers. It is distributed in accordance with the Creative Commons Attribution Non Commercial (CC BY-NC 4.0) license, which permits others to distribute, remix, adapt, build upon this work non-commercially, and license their derivative works on different terms, provided the original work is properly cited and the use is non-commercial. See: <http://creativecommons.org/licenses/by-nc/4.0/>

Correspondence to: Greg Hoy, Hand and Upper Limb Surgeon, Adjunct Associate Clinical Professor, Department of Surgery, Monash University, Victoria, Australia.

Email: gahoy@mog.com.au

Telephone: +61395251833

Received: September 30, 2018

Revised: November 18, 2018

Accepted: November 20 2018

Published online: February XX, 2019

ABSTRACT

Partial-thickness rotator cuff tears (PTRCT) can be articular-sided, bursal-sided or intratendinous. New research suggests that a considerable proportion (up to 30%) of cuff thickness on the articular side is taken up histologically by the superior joint capsule conjoined to the rotator cuff tissue. This means that newer reviews of the surgical options may be required to complement the Ellman classification which grades lesions as grade 1 (less than 25% of tendon thickness involved), grade 2 (25 – 50%) or grade 3 (greater than 50% of tendon thickness). If primary non-operative treatment fails, many surgical options can be considered. The

surgical technique chosen has been based on depth of the tear and the tear location. Surgical treatment can be distinguished between debridement and repair of PTRCT's, as well as biologically active experimental techniques showing some promise. Debridement can be successfully performed for bursal-sided Ellman grade 1 tears and articular-sided grade 1 and 2 tears. All other techniques show better results with a repair technique, which can be either performed with an in-situ or trans-cuff repair technique (leaving the intact rotator cuff portion intact) or with tear conversion to a full-thickness cuff tear and subsequent repair. Successful functional and structural outcome after repair of Ellman grade 3 tears can be shown with both repair techniques. The current literature also suggests evidence for inferior outcomes and higher failure rates after arthroscopic debridement of bursal-sided partial-thickness rotator cuff tears compared to articular-sided lesions, which may reflect the contribution of capsule to the tear. Articular-sided partial cuff tears are frequently seen in overhead athletes and should be treated non-operatively whenever possible. If conservative treatment fails, debridement seems to be a better surgical choice in most cases, as only a half of professional athletes return to the same level of play after repair of partial-thickness rotator cuff tears.

Key words: Partial-thickness; rotator cuff tears; Arthroscopic rotator cuff repair; Debridement; Conversion to full-thickness; Transtendon repair

© 2019 The Author(s). Published by ACT Publishing Group Ltd. All rights reserved.

Borbas P, Hoy G. Surgical Treatment Options for Partial Rotator Cuff Tears: A Review of the Literature. *International Journal of Orthopaedics* 2019; 6(1): 1032-1038 Available from: URL: <http://www.ghrnet.org/index.php/ijo/article/view/2438>

INTRODUCTION

Partial-thickness rotator cuff tears (PTRCT) have been described with a prevalence ranging from 13% to 40%^[1,2], with increasing scientific publications focusing on current management options^[3]. In this review we are focusing primarily on the surgical treatment of articular-sided and bursal-sided PTRCTs of the supraspinatus and

infraspinatus tendon, with partial subscapularis tears considered a separate entity discussed in the last chapter.

ANATOMY

The rotator cuff shows a 5-layer histologic structure^[4] with an array of tendon, ligament and capsular tissue on the articular side that is less tolerant to stress than the bursal side^[5]. Furthermore, a zone of relative hypovascularity can be found on the articular surface of the supraspinatus tendon close to the insertion^[6]. This is a proposed intrinsic reason for development of articular-sided cuff tears. The histology of the rotator cuff has received considerable attention in recent literature with the realization that the superior capsule of the shoulder joint contributes a significant proportion of the thickness and footprint of the supraspinatus and infraspinatus in the shoulder joint (Figure 1)^[7]. Thus the “effective cuff ratio” of significant articular-sided tears means most active fibres of the rotator cuff are intact, whereas the “effective cuff ratio” of much lower grade bursal-sided cuff tears is compromised, rendering the current classifications of PTRCTs somewhat obsolete.

Better understanding of the anatomy of the contributions to the insertion of the supraspinatus and the infraspinatus tendons on the greater tuberosity^[7,8] have highlighted the relative importance of the infraspinatus and the smaller width of the supraspinatus footprint than previously considered (Figure 2). This may fuel the arguments of non-surgical advocates for leaving even high grade PTRCTs alone, despite evidence that progression to full thickness tears and poorer clinical outcomes found in longitudinal studies^[9,10].

PATHOLOGY

Three different tears can be distinguished depending on the location, which are articular-sided, bursal-sided or intra-tendinous. Ellman introduced a classification for PTRCT in 1990, based on their location and depth as measured during shoulder arthroscopy (Figure 3). In this classification, articular-sided (A) or bursal-sided (B) PTRCTs are classified as grade 1 for tears less than 3 mm thickness, as grade 2 if the tear is from 3 to 6 mm thickness, and as grade 3 for tears greater than 6 mm in depth. Ellman Grade 3 tears are representing PTRCTs greater than 50% of the tendon thickness, based on anatomic measurements of normal supraspinatus tendon thickness with a mean of about 12 mm^[11], although the previously noted research highlights the percentage of cuff tear thickness is much greater on the bursal side.

Another possible reason for development of a PTRCT is postero-superior impingement. This pathologic condition, better known as internal impingement, is commonly seen in the throwing overhead athlete and is associated with PASTA (partial articular supraspinatus avulsion) lesions and postero-superior labral tearing as well as SLAP (Superior Labral Anterior to Posterior) lesions^[12,13]. As proposed by Neer^[14,15], bursal-sided tears are generally considered to be a consequence of sub-acromial impingement. However, newer parameters as the critical shoulder angle^[16], the acromial index^[17] and the greater tuberosity angle^[18] seem to be more valid and real risk factors for rotator cuff tears compared to the acromion shape according to Bigliani^[19].

CLINICAL PRESENTATION

The most common symptom of PTRCTs is pain, which can be stronger than in full-thickness rotator cuff tears^[20]. Common imaging studies include ultrasonography and MRI or magnet resonance

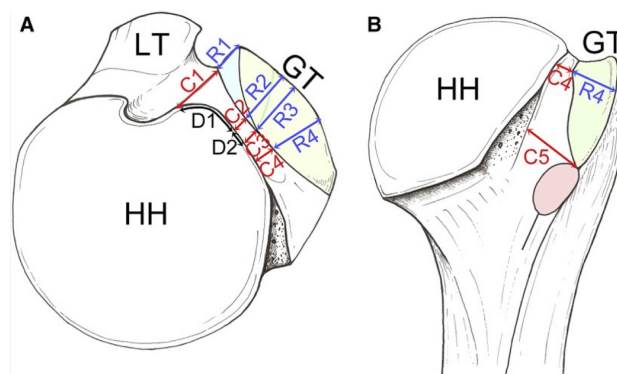


Figure 1 (out of Nimura *et al*)^[7]. Illustration of capsular (C) and rotator cuff (R) insertion area at the greater tuberosity.

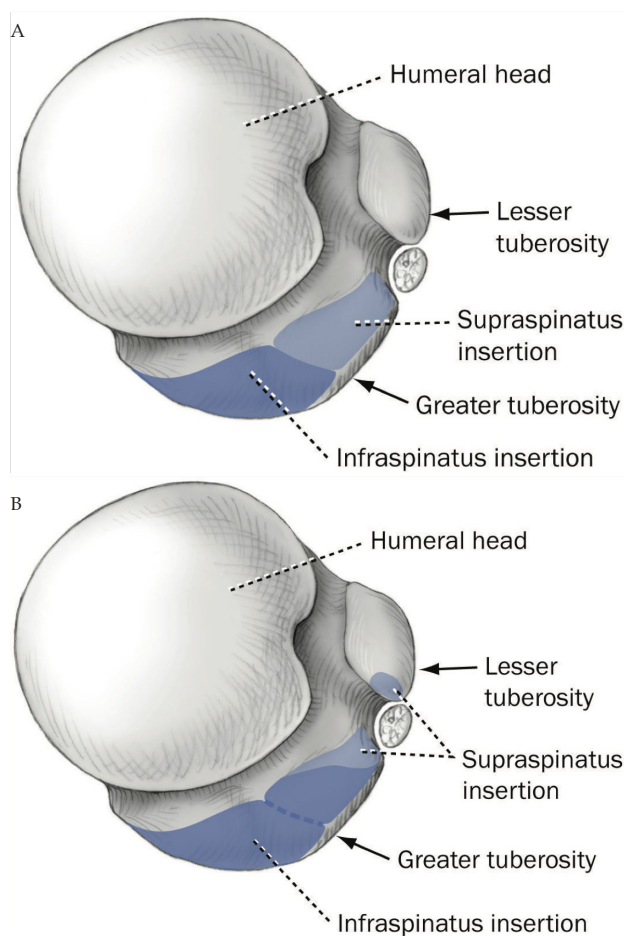


Figure 2 (out of Mochizuki *et al*)^[8]. Illustration of the humeral insertions of the supraspinatus and infraspinatus tendon. (A) Generally accepted anatomic concept of tendon insertions. (B) Tendon insertions based on the study by Mochizuki *et al*^[8].

arthrography, with similar accuracy according to the literature. The diagnostic gold standard remains arthroscopy with direct visualisation and probing of the bursal and articular surfaces of the rotator cuff with measurement of the tear size. However, this can be challenging sometimes and especially intratendinous tears are difficult to assess^[21].

Progression of symptomatic PTRCT to full-thickness cuff tears has been reported in 40% of cases^[22], whereas spontaneous healing has rarely been reported^[3].

In a patient with a symptomatic PTRCT a trial of at least 3 to

6 months of non-operative treatment is typically the first line. This includes activity modification and use of analgesic and anti-inflammatory medications. Corticosteroid injections are a further non-operative treatment adjunct, located into the subacromial space in case of a bursal lesion and into the glenohumeral joint for treating an articular-sided PTRCTs. If conservative treatment fails, operative treatment should be discussed.

SURGICAL TECHNIQUES

The decision, which surgical technique is chosen, is commonly based on the depth of the PTRCT. Generally, it can be distinguished between debridement and repair of PTRCTs. Repair of PTRCTs can either be performed with an in-situ (“trans-cuff”) repair technique (leaving the intact cuff portion intact) or with a tear conversion into a full-thickness cuff tear and subsequent repair. Successful functional and structural outcome^[23-26] after repair of Ellman grade 3 tears could be shown with both repair techniques.

Interestingly, current literature suggests an evidence for inferior outcomes and higher failure rates after arthroscopic debridement of bursal-sided PTRCTs compared to articular-sided lesions^[3].

Debridement

Most authors to date recommend debridement (combined with acromioplasty in case of bursal-sided tears) for tears involving less than 50% of tendon thickness, signifying Ellman grade 1 and 2 tears. However, as proposed in a recent systematic review by Katthagen *et al*^[3], some evidence suggests that repair of partial-thickness rotator cuff tears may be even beneficial over debridement for lower grade bursal-sided tears.

Weber^[27] reported on results of PTRCTs of > 50% of tendon thickness and found that bursal-sided tears had significantly inferior results compared to articular-sided tears after treatment with debridement and acromioplasty. With our “new” knowledge of the contribution of superior capsule to the articular side of the cuff, this would seem more logical as there is less true cuff destruction with a PASTA than a bursal tear. These findings were supported even in lower grade PTRCTs of Ellman grade 2 in a study by Cordasco *et al*^[28] and in Ellman grade 1 and 2 tears by Kartus *et al*^[29], who found – although statistically non-significantly – lower functional scores in bursal-sided tears.

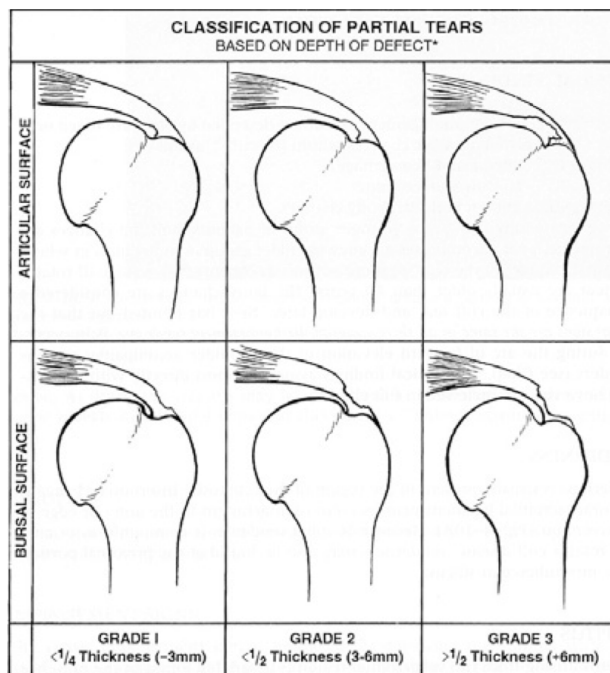
The authors’ preferred method

After failed conservative therapy, we treat articular-sided PRCTS Ellman grade 1 and 2 operatively with debridement of the cuff, together with arthroscopic subacromial decompression and bursectomy. However, for bursal sided tears we changed our approach over the last years. Whereas Ellman grade 1 tears are still treated with debridement of the bursal sided cuff tear of less than 25% tendon thickness involved, we complete both Ellman grade 2 and 3 tears to full-thickness tears and repair it similar to a standard full thickness cuff tear. Debridement is always combined with an anterolateral acromioplasty to reduce any spurs of the acromion as potential mechanic conflict and also to correct the critical shoulder angle^[16] if it is more than 35° on preoperative ap X-ray.

In-situ repair versus tear completion into full-thickness cuff tear and repair

Articular-sided partial-thickness rotator cuff tears

Several surgical techniques of in-situ repair have been described^[23-26,30-32], however, with no superiority of one specific



*Indicate AREA OF DEFECT: Base of tear × maximum retraction = mm²

Figure 3 (out of Habermeyer *et al*)^[47]. Illustration of the Ellman classification.

technique to the others (Figure 3). A proposed advantage of transtendinous repair techniques with preservation of the intact rotator cuff tendon integrity on the bursal side is the maintenance of the original footprint and therefore a more anatomic repair. Potential disadvantages are shoulder discomfort, slow recovery^[25,33] and medial cuff failures, as published in a study by Woods *et al*^[31].

Conclusions regarding the superiority of one technique to the other are controversial in the two most recent systematic reviews and meta-analysis^[3,34]. On the one hand, Sun *et al*^[34] suggested in 2015 in a questionable meta-analysis that transtendon repair techniques are better, because a significantly lower retear rate was found compared to full-thickness tear conversion techniques. However, that study has major limitations as also retrospective cohort studies were included and not sufficient details are provided about the re-tears in the result section. Both techniques provided similar functional results in that publication. Whereas on the other hand, Katthagen *et al*^[3] concluded in a systematic review in 2017 that no significant differences could be found in the three included studies that directly compared the structural outcomes of in-situ repair versus repair after conversion to full-thickness cuff tears of articular-sided^[23,25] and bursal-sided^[35] PRCTS.

The authors’ preferred method

Articular-sided partial rotator cuff tears with less than 50% tendon thickness involved (Ellman grade 1A and 2A) are treated with debridement in case of persistent symptoms after a trial of conservative treatment of at least 6 months. Ellman grade 3A tears are converted to a full-thickness cuff lesion and repaired in a standardized fashion. Small tears (< 1 cm) are treated with a single row repair, whereas tears larger than 1cm are repaired with a double row suture bridge.

In our personal experience, transtendon repairs are more likely to suffer from more and prolonged postoperative pain as well as a higher risk of postoperative stiffness. This is supported by a prospective comparative study by Shin^[25], who compared a transtendon in-situ

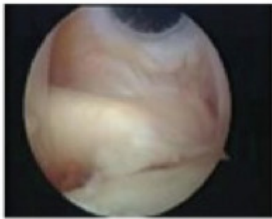
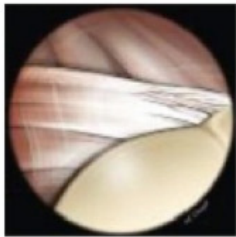


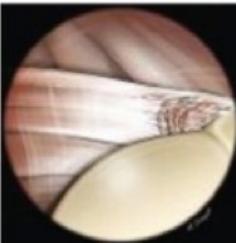

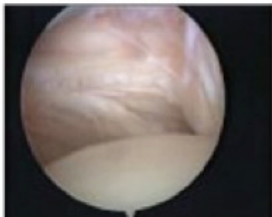
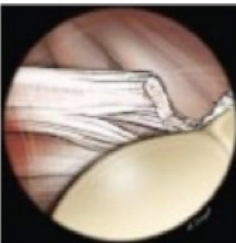


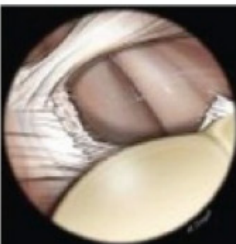


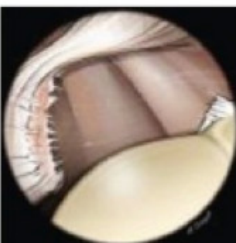

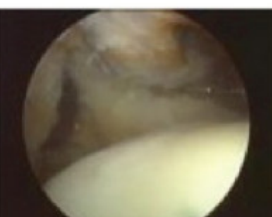


	Description	Arthroscopic image	Drawing of Arthroscopic view	Drawing of anterior Anatomic view
Grade Ia	Minor fraying at the insertion site			
Grade Ib	Partial tears of the deep fibers at the insertion onto the lesser tuberosity			
Grade II	Complete tear of superior 1/3			
Grade III	Complete tear of superior 2/3			
Grade IV	Complete tear with retraction, no subluxation of humeral head			
Grade V	Complete tear with retraction, anterior subluxation of humeral head			

Figure 4 (out of Caravaglia et al)^[43]. Illustration of the modified Lafosse classification for subscapularis tendon tears.

repair with a conversion technique in 48 patients and could show that patients in the transtendon repair group had significantly more pain and recovered faster with higher scores in the early postoperative period.

Bursal-sided partial thickness rotator cuff tears

Also for bursal-sided PRCTs, several different techniques of in-situ repair have been described^[35-37], with similar results. Tear conversions to full-thickness rotator cuff tears and repair can also be performed

with one of the various techniques for rotator cuff repair. Shin *et al*^[35] compared a modified Mason-Allen single row repair to a double row suture-bridge technique in 84 patients with Ellman grade 3B lesion and found similar results in both groups.

There is no clinical data showing any superiority for tear conversion and repair or in-situ repair to each other. However, one recent animal study by Gereli *et al*^[38] showed increased healing characteristics for a completion repair technique compared to an in-situ-repair in created bilateral bursal sided PRCTs of the supraspinatus tendon in rats. The authors are discussing the hypothesis that this response could be caused by the effect of debridement of the chronic degenerated tendon.

The authors' preferred method

As mentioned before, we complete bursal-sided partial cuff tears of more than 25% tendon thickness involved (Ellman grade 2B and 3B) to full-thickness tears and repair it as in a standard full thickness cuff tear. In most cases, this is combined with an anterolateral acromioplasty to reduce any spurs of the acromion as potential mechanic conflict and also to correct the critical shoulder angle.

In the authors' opinion, especially in chronic bursal-sided lesions caused by extrinsic factors as mechanical subacromial impingement, the tissue quality of the bursal sided cuff is often not good enough for an in-situ repair because of tendinosis.

Partial thickness rotator cuff tears in overhead athletes

Overhead athletes are more likely to have a rotator cuff pathology, as known especially in baseball pitchers^[2,39]. PRCTs are frequently seen in throwers, however, with poor correlation to symptoms in throwing shoulders^[2,40]. Internal impingement with glenohumeral internal rotation deficit, posterosuperior labral tears and articular-sided PRCTs is common in the thrower's shoulder^[41].

Special effort should be taken to treat this lesions non-operatively if possible, as only half of professional and competitive athletes return to an equivalent level of play after repair^[42]. On the other side, recreational athletes are more likely to return to the same level of play as before their injury^[42].

If conservative treatment fails, debridement alone seems to be superior compared to repair of PRCTs in the throwing athlete^[41,43].

The authors' preferred method

Symptomatic articular-sided partial cuff tears in the overhead athlete should be treated non-operatively with a reasonable outcome in most cases. If conservative treatment measures fail, our preferred surgical treatment is debridement alone, even for most Ellman grade 3 lesions. However, if the tear involves more than about 70% of the tendon thickness, we complete the tear and repair a full-thickness cuff tear in a standardized fashion.

Partial thickness subscapularis tears

Tears of the subscapularis tendon used to be underdiagnosed in the past and are more commonly diagnosed with arthroscopic techniques^[44]. The subscapularis is the strongest tendon of the rotator cuff and plays an important role in shoulder function as the only anterior tendon^[45].

The modified Lafosse classification of subscapularis tendon tears^[46] distinguishes not only between partial (grade I) and complete tears (grade II) of the upper third of the tendon, but also between minor fraying of the insertion site (grade Ia) and partial tears of the deep layer (grade Ib). (Figure 4)

Surgical options include debridement and repair, often combined

with either biceps tenotomy or tenodesis in case of instability of the long head of biceps tendon. Further additional procedures which can aid are anterior capsular release in case of capsular stiffness or inflammation and coracoplasty in case of subcoracoid impingement.

The authors' preferred method

Symptomatic upper third tears of the subscapularis tendon are debrided if there is only a fraying (grade Ia). If it is an upper angle tear either partially involving the deep layer (grade Ib) or complete in the upper third (grade II), it is repaired with a suture tape and a knotless anchor using a single anterolateral portal.

REFERENCES

- Matthewson G, Beach CJ, Nelson AA, Woodmass JM, Ono Y, Boorman RS, *et al.* Partial Thickness Rotator Cuff Tears: Current Concepts. *Adv Orthop.* 2015; **2015**: 458786. [PMID: 26171251]; [PMCID: PMC4480800]; [DOI: 10.1155/2015/458786]
- Connor PM, Banks DM, Tyson AB, Coumas JS, D'Alessandro DF. Magnetic resonance imaging of the asymptomatic shoulder of overhead athletes: a 5-year follow-up study. *Am J Sports Med.* 2003; **31(5)**: 724-7. [PMID: 12975193]; [DOI: 10.1177/03635465030310051501]
- Katthagen JC, Bucci G, Moatshe G, Tahal DS, Millett PJ. Improved outcomes with arthroscopic repair of partial-thickness rotator cuff tears: a systematic review. *Knee Surg Sports Traumatol Arthrosc.* 2018; **26(1)**: 113-24. [PMID: 28526996]; [DOI: 10.1007/s00167-017-4564-0]
- Clark JM, Harryman DT, 2nd. Tendons, ligaments, and capsule of the rotator cuff. Gross and microscopic anatomy. *J Bone Joint Surg Am.* 1992; **74(5)**: 713-25. [PMID: 1624486]
- Nakajima T, Rokuuma N, Hamada K, Tomatsu T, Fukuda H. Histologic and biomechanical characteristics of the supraspinatus tendon: Reference to rotator cuff tearing. *J Shoulder Elbow Surg.* 1994; **3(2)**: 79-87. [PMID: 22959646]; [DOI: 10.1016/S1058-2746(09)80114-6]
- Lohr JF, Uthoff HK. The microvascular pattern of the supraspinatus tendon. *Clin Orthop Relat Res.* 1990 May; **(254)**:35-8. [PMID: 2323147]
- Nimura A, Kato A, Yamaguchi K, Mochizuki T, Okawa A, Sugaya H, *et al.* The superior capsule of the shoulder joint complements the insertion of the rotator cuff. *J Shoulder Elbow Surg.* 2012; **21(7)**: 867-72. [PMID: 21816631]; [DOI: 10.1016/j.jse.2011.04.034]
- Mochizuki T, Sugaya H, Uomizu M, Maeda K, Matsuki K, Sekiya I, *et al.* Humeral insertion of the supraspinatus and infraspinatus. New anatomical findings regarding the footprint of the rotator cuff. *J Bone Joint Surg Am.* 2008; **90(5)**: 962-9. [PMID: 18451386]; [DOI: 10.2106/JBJS.G.00427]
- Fukuda H. The management of partial-thickness tears of the rotator cuff. *J Bone Joint Surg Br.* 2003; **85(1)**: 3-11. [PMID: 12585570]
- Yamanaka K, Matsumoto T. The joint side tear of the rotator cuff. A followup study by arthrography. *Clin Orthop Relat Res.* 1994 Jul; **(304)**:68-73. [PMID: 8020236]
- Ruotolo C, Fow JE, Nottage WM. The supraspinatus footprint: an anatomic study of the supraspinatus insertion. *Arthroscopy.* 2004; **20(3)**: 246-9. [PMID: 15007313]; [DOI: 10.1016/j.arthro.2004.01.002]
- Riand N, Boulahia A, Walch G. Posterosuperior impingement of the shoulder in the athlete: results of arthroscopic debridement in 75 patients. *Rev Chir Orthop Reparatrice Appar Mot.* 2002; **88(1)**: 19-27. [PMID: 11973531]
- Walch G, Boileau P, Noel E, Donell ST. Impingement of the deep surface of the supraspinatus tendon on the posterosuperior glenoid rim: An arthroscopic study. *J Shoulder Elbow Surg.* 1992; **1(5)**: 238-45. [PMID: 22959196]; [DOI: 10.1016/S1058-2746(09)80065-7]

14. Neer CS, 2nd. Anterior acromioplasty for the chronic impingement syndrome in the shoulder: a preliminary report. *J Bone Joint Surg Am.* 1972; **54(1)**: 41-50. [PMID: 5054450]
15. Neer CS, 2nd. Impingement lesions. *Clin Orthop Relat Res.* 1983; **173**: 70-7. [PMID: 6825348]
16. Moor BK, Bouaicha S, Rothenfluh DA, Sukthankar A, Gerber C. Is there an association between the individual anatomy of the scapula and the development of rotator cuff tears or osteoarthritis of the glenohumeral joint?: A radiological study of the critical shoulder angle. *Bone Joint J.* 2013; **95-B(7)**: 935-41. [PMID: 23814246]; [DOI: 10.1302/0301-620X.95B7.31028]
17. Nyffeler RW, Werner CM, Sukthankar A, Schmid MR, Gerber C. Association of a large lateral extension of the acromion with rotator cuff tears. *J Bone Joint Surg Am.* 2006; **88(4)**: 800-5. [PMID: 16595470]; [DOI: 10.2106/JBJS.D.03042]
18. Cunningham G, Nicodeme-Paulin E, Smith MM, Holzer N, Cass B, Young AA. The greater tuberosity angle: a new predictor for rotator cuff tear. *J Shoulder Elbow Surg.* 2018; **27(8)**: 1415-21. [PMID: 29703680]; [DOI: 10.1016/j.jse.2018.02.051]
19. Pandey V, Vijayan D, Tapashetti S, Agarwal L, Kamath A, Acharya K, *et al.* Does scapular morphology affect the integrity of the rotator cuff? *J Shoulder Elbow Surg.* 2016; **25(3)**: 413-21. [PMID: 26652696]; [DOI: 10.1016/j.jse.2015.09.016]
20. Fukuda H. Partial-thickness rotator cuff tears: a modern view on Codman's classic. *J Shoulder Elbow Surg.* 2000; **9(2)**: 163-8. [PMID: 10810700]
21. Lo IK, Gonzalez DM, Burkhart SS. The bubble sign: an arthroscopic indicator of an intratendinous rotator cuff tear. *Arthroscopy.* 2002; **18(9)**: 1029-33. [PMID: 12426548]
22. Mall NA, Kim HM, Keener JD, Steger-May K, Teefey SA, Middleton WD, *et al.* Symptomatic progression of asymptomatic rotator cuff tears: a prospective study of clinical and sonographic variables. *J Bone Joint Surg Am.* 2010; **92(16)**: 2623-33. [PMID: 21084574]; [PMCID: PMC2970889]; [DOI: 10.2106/JBJS.I.00506]
23. Franceschi F, Papalia R, Del Buono A, Vasta S, Costa V, Maffulli N, *et al.* Articular-sided rotator cuff tears: which is the best repair? A three-year prospective randomised controlled trial. *Int Orthop.* 2013; **37(8)**: 1487-93. [PMID: 23580030]; [PMCID: PMC3728419]; [DOI: 10.1007/s00264-013-1882-9]
24. Kim KC, Shin HD, Cha SM, Park JY. Repair integrity and functional outcome after arthroscopic conversion to a full-thickness rotator cuff tear: articular- versus bursal-side partial tears. *Am J Sports Med.* 2014; **42(2)**: 451-6. [PMID: 24318610]; [DOI: 10.1177/0363546513512770]
25. Shin SJ. A comparison of 2 repair techniques for partial-thickness articular-sided rotator cuff tears. *Arthroscopy.* 2012; **28(1)**: 25-33. [PMID: 22000411]; [DOI: 10.1016/j.arthro.2011.07.005]
26. Liu CT, Ge HA, Hu R, Huang JB, Cheng YC, Wang M, *et al.* Arthroscopic knotless single-row repair preserving full footprint versus tear completion repair for partial articular-sided rotator cuff tear. *J Orthop Surg (Hong Kong).* 2018; **26(2)**: 2309499018770897. [PMID: 29669443]; [DOI: 10.1177/2309499018770897]
27. Weber SC. Arthroscopic debridement and acromioplasty versus mini-open repair in the treatment of significant partial-thickness rotator cuff tears. *Arthroscopy.* 1999; **15(2)**: 126-31. [PMID: 10210067]; [DOI: 10.1053/ar.1999.v15.0150121]
28. Cordasco FA, Backer M, Craig EV, Klein D, Warren RF. The partial-thickness rotator cuff tear: is acromioplasty without repair sufficient? *Am J Sports Med.* 2002; **30(2)**: 257-60. [PMID: 11912097]; [DOI: 10.1177/03635465020300021801]
29. Kartus J, Kartus C, Rostgard-Christensen L, Sernert N, Read J, Perko M. Long-term clinical and ultrasound evaluation after arthroscopic acromioplasty in patients with partial rotator cuff tears. *Arthroscopy.* 2006; **22(1)**: 44-9. [PMID: 16399460]; [DOI: 10.1016/j.arthro.2005.07.027]
30. Shin SJ, Jeong JH, Jeon YS, Kim RG. Preservation of bursal-sided tendon in partial-thickness articular-sided rotator cuff tears: a novel arthroscopic transtendon anatomic repair technique. *Arch Orthop Trauma Surg.* 2016; **136(12)**: 1701-8. [PMID: 27498108]; [DOI: 10.1007/s00402-016-2546-1]
31. Woods TC, Carroll MJ, Nelson AA, More KD, Berdusco R, Sohmer S, *et al.* Transtendon rotator-cuff repair of partial-thickness articular surface tears can lead to medial rotator-cuff failure. *Open Access J Sports Med.* 2014; **5**: 151-7. [PMID: 25114604]; [PMCID: PMC4077873]; [DOI: 10.2147/OAJSM.S62885]
32. Tauber M, Koller H, Resch H. Transosseous arthroscopic repair of partial articular-surface supraspinatus tendon tears. *Knee Surg Sports Traumatol Arthrosc.* 2008; **16(6)**: 608-13. [PMID: 18418574]; [DOI: 10.1007/s00167-008-0532-z]
33. Castagna A, Delle Rose G, Conti M, Snyder SJ, Borroni M, Garofalo R. Predictive factors of subtle residual shoulder symptoms after transtendinous arthroscopic cuff repair: a clinical study. *Am J Sports Med.* 2009; **37(1)**: 103-8. [PMID: 19059897]; [DOI: 10.1177/0363546508324178]
34. Sun L, Zhang Q, Ge H, Sun Y, Cheng B. Which is the best repair of articular-sided rotator cuff tears: a meta-analysis. *J Orthop Surg Res.* 2015; **10**: 84. [DOI: 10.1186/s13018-015-0224-6]
35. Shin SJ, Kook SH, Rao N, Seo MJ. Clinical Outcomes of Modified Mason-Allen Single-Row Repair for Bursal-Sided Partial-Thickness Rotator Cuff Tears: Comparison With the Double-Row Suture-Bridge Technique. *Am J Sports Med.* 2015; **43(8)**: 1976-82. [PMID: 26055919]; [DOI: 10.1177/0363546515587718]
36. Koh KH, Shon MS, Lim TK, Yoo JC. Clinical and magnetic resonance imaging results of arthroscopic full-layer repair of bursal-side partial-thickness rotator cuff tears. *Am J Sports Med.* 2011; **39(8)**: 1660-7. [PMID: 21737830]; [DOI: 10.1177/0363546511412165]
37. Xiao J, Cui G. Clinical and structural results of arthroscopic repair of bursal-side partial-thickness rotator cuff tears. *J Shoulder Elbow Surg.* 2015; **24(2)**: e41-6. [PMID: 25240814]; [DOI: 10.1016/j.jse.2014.07.008]
38. Gereli A, Kocaoglu B, Ulku TK, Silay S, Kilinc E, Uslu S, *et al.* Completion repair exhibits increased healing characteristics compared with in situ repair of partial thickness bursal rotator cuff tears. *Knee Surg Sports Traumatol Arthrosc.* 2018; **26(8)**: 2498-504. [PMID: 29516123]; [DOI: 10.1007/s00167-018-4870-1]
39. Burkhart SS, Morgan CD, Kibler WB. The disabled throwing shoulder: spectrum of pathology Part I: pathoanatomy and biomechanics. *Arthroscopy.* 2003; **19(4)**: 404-20. [PMID: 12671624]; [DOI: 10.1053/jars.2003.50128]
40. Jost B, Zumstein M, Pfirrmann CW, Zanetti M, Gerber C. MRI findings in throwing shoulders: abnormalities in professional handball players. *Clin Orthop Relat Res.* 2005; **434**: 130-7. [PMID: 15864042]
41. Caldwell PE, 3rd, Dyer DC, Pearson SE. Arthroscopic Debridement of the Thrower's Shoulder: Less Is More. *Arthrosc Tech.* 2016; **5(6)**: e1381-e6. [PMID: 28149736]; [PMCID: PMC5263853]; [DOI: 10.1016/j.eats.2016.08.006]
42. Klouche S, Lefevre N, Herman S, Gerometta A, Bohu Y. Return to Sport After Rotator Cuff Tear Repair: A Systematic Review and Meta-analysis. *Am J Sports Med.* 2016; **44(7)**: 1877-87. [PMID: 26316611]; [DOI: 10.1177/0363546515598995]
43. Liu JN, Garcia GH, Gowd AK, Cabarcas BC, Charles MD, Romeo AA, *et al.* Treatment of Partial Thickness Rotator Cuff Tears in Overhead Athletes. *Curr Rev Physiol Musculoskelet Med.* 2018; **11(1)**: 55-62. [PMID: 29330670]; [PMCID: PMC5825340]; [DOI: 10.1007/s12178-018-9459-2]
44. Denard PJ, Burkhart SS. Arthroscopic recognition and repair of the torn subscapularis tendon. *Arthrosc Tech.* 2013; **2(4)**: e373-9. [PMID: 24400185]; [PMCID: PMC3882711]; [DOI: 10.1016/j.eats.2013.05.007]
45. Keating JF, Waterworth P, Shaw-Dunn J, Crossan J. The relative strengths of the rotator cuff muscles. A cadaver study. *J Bone Joint Surg Br.* 1993; **75(1)**: 137-40. [PMID: 8421011]
46. Garavaglia G, Ufenast H, Taverna E. The frequency of subscapu-

laris tears in arthroscopic rotator cuff repairs: A retrospective study comparing magnetic resonance imaging and arthroscopic findings. *Int J Shoulder Surg.* 2011; **5(4)**: 90-4. [PMID: 22223958]; [PMCID: PMC3249929]; [DOI: 10.4103/0973-6042.91000]

47. Habermeyer P, Magosch P, Lichtenberg S. Classifications and scores of the shoulder. Berlin u.a.: Springer; 2006. XIV, 297 S. p.

Peer Reviewer: Javier Muñoz-Marín