

## Successive Ipsilateral Atypical Fractures of the Left Femoral Neck and the Diaphysis: Case Report and Review of the Literature

Nieto Edgar, Uzcategui Jose, Ochoa Luis, Salinas Jose Rafael

Nieto Edgar, Uzcategui Jose, Ochoa Luis, Salinas Jose Rafael, Orthogeriatric Program, Institute of Osteoporosis and Bone Densitometry, Medical Surgical Clinical Institute CA, University of the Andes, Merida, Venezuela.

**Conflict-of-interest statement:** The author(s) declare(s) that there is no conflict of interest regarding the publication of this paper.

**Open-Access:** This article is an open-access article which was selected by an in-house editor and fully peer-reviewed by external reviewers. It is distributed in accordance with the Creative Commons Attribution Non Commercial (CC BY-NC 4.0) license, which permits others to distribute, remix, adapt, build upon this work non-commercially, and license their derivative works on different terms, provided the original work is properly cited and the use is non-commercial. See: <http://creativecommons.org/licenses/by-nc/4.0/>

**Correspondence to:** Nieto E, Home Address 12 Rue du Telegraph. Bat. F. Apt.02. Bayonne.64100. France.  
Email: [edgar.nieto@gmail.com](mailto:edgar.nieto@gmail.com)  
Telephone: +34626513475

Received: January 9, 2018

Revised: February 10, 2019

Accepted: February 12 2019

Published online: April 28, 2019

### ABSTRACT

We present the case of an elderly osteoporotic woman who for the second time and successively has atypical ipsilateral fractures of the left femur, the first one of the diaphysis (AO32A3) and the second basicervical (AO31A1) intracapsular neck of the femur. It is thought that the cause of diaphyseal fracture is by osteoporosis therapy with alendronic acid for 10 years, but for the one of the femoral neck we have several theories: the prolonged use of bisphosphonates, abnormal gait in abduction because the intramedullary nail to treat the diaphyseal fracture with technical failures, very prominent in the trochanter and the proximal anti-rotating pin at the base of the femoral neck. We present a non-frequent case of an atypical fracture of the femoral neck, subsequent to a diaphyseal fracture of the same femur in an osteoporosis patient treated with bisphosphonates.

**Key words:** Atypical femur fracture; Bisphosphonates; Femur stress-neck fractures; Abduction gait; Elderly; Osteoporosis

© 2019 The Author(s). Published by ACT Publishing Group Ltd. All rights reserved.

Nieto E, Uzcategui J, Ochoa L, Salinas JR. Successive ipsilateral atypical fractures of the left femoral neck and the diaphysis: Case report and review of the literature. *International Journal of Orthopaedics* 2019; 6(2): 1070-1073 Available from: URL: <http://www.ghrnet.org/index.php/ijo/article/view/2518>

### INTRODUCTION

Osteoporosis is the most common metabolic bone disease, which, in recent years, has received significant attention due to the magnitude and severity of the sequelae. It is a recognized public health problem and, in this sense, oral nitrogenous bisphosphonates have been able to reduce fractures risk of the femoral neck. But due to its prolonged use, since 2005, cases of “atypical” diaphyseal fractures of the diaphysis of the femur (AFF) have been published<sup>[1,2]</sup> for those who have consumed it for a long time, the statistical possibilities of this type of fracture would be ~ 113 cases per 100,000 people per year. The femur diaphysis is that area that goes from the bottom of the lesser trochanter, but above the supracondylar flare and the fracture line must originate at the lateral cortex and remain transverse across the cortex but permitted the fracture line to become oblique as it progressed medially across the femur (Figure 1)<sup>[2,3]</sup>.

Fatigue fractures are frequent and those of the neck of the femur in some statistics amount to 10% of them<sup>[4,5]</sup>. In young people they are produced as a result of repeated efforts and in elderly people they are due to minor traumas in poor quality bones, they cause high morbidity without increasing mortality, provided they receive the appropriate treatment<sup>[6]</sup>.

In this, information we present a previously unreported case of a patient with ipsilateral successive stress fractures, diaphyseal and left femoral neck associated with long-term alendronate use.

### CASE REPORT

It is a female patient, apparently healthy, but with osteoporosis diagnosed and treated since 1998, and in 2008, at the age of 84

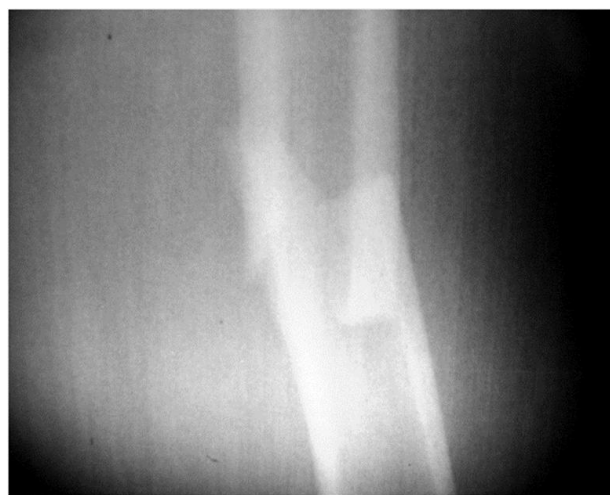years old, she presented prodromal pain and subsequently an insufficiency fracture (atypical) of the left femoral shaft in her lower third AO 32 A 3 (Figure 1)<sup>[6]</sup>, as a result to prolonged consumption of alendronate: it was that time it was treated by blocked intramedullary nail, with technical failures, because it was not introduced up to the recommended level in the greater trochanter, and the proximal cortical screw (anti-rotary) remained in the union between the neck and the trochanter (Figure 2). The patient did not accept to be reoperated and therefore decided to be treated with drugs by combining an anabolic (teriparatide for 18 months) and an anti-catabolic (zoledronic acid 5 mg, one dose). Once the diaphyseal fracture healed (Figure 3), the ambulation began, but due to the prominence of the nail, the patient suffered permanent discomfort in the gluteal region, which obliged her to walk with the hip in abduction. In 2012, she felt continuous pain at the level of the left inguinal fold and, in view of the fact that she did not improve with habitual therapy, a radiological study was indicated that revealed a trait of basicervical fracture AO 31B3 (Figure 4)<sup>[6]</sup>. The patient could not be operated immediately and since 2014 she has a great difficulty to mobilize because the femoral neck was reabsorbed and the greater trochanter rose causing a severe shortening of the limb (Figure 5). The decision was made in 2015 to place a total prosthesis of uncemented revision, at the time of surgery, bone of very poor quality was evidenced and the stem support was achieved in the diaphysis, with persistence of the elevation of the greater trochanter as shown in the postoperative radiology (Figure 6).

## DISCUSSION

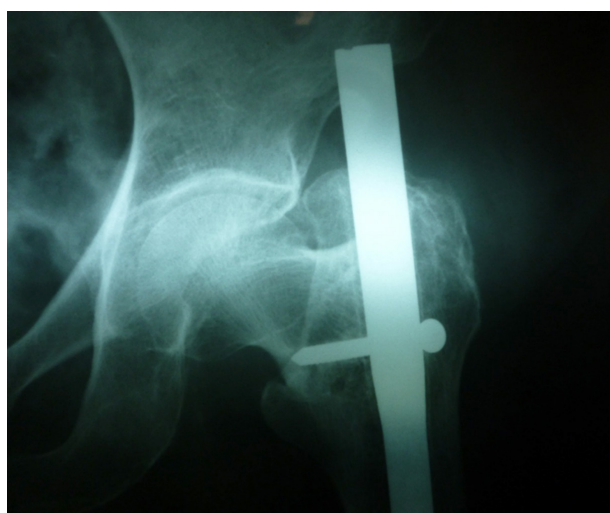The bisphosphonates, which are potent inhibitors of bone resorption and exert their effects by reducing the osteoclast activity and increasing apoptosis might eventually have a negative impact on bone quality by inhibiting repair mechanisms within the bone. It is known that they change the bone matrix composition, which lead to highly mineralized collagen. This may result in a generalized suppression of bone to remodel, leading to the accumulation of micro-damage, and this could affect the intracortical repair and ultimately lead to a complete stress fracture<sup>[7]</sup>.

In a whole, according to the American Society of Bone and Mineral Research (ASBMR) Task Force<sup>[5]</sup> the ‘atypical’ femoral diaphysis fracture<sup>[6]</sup> should be considered for “insufficiency” because there is a normal load on a bone of poor quality<sup>[8]</sup>. Our case meets four of the five major features that is, it starts in the lateral cortex, has a transverse line, takes both cortices and ends with a slight spike. The beginning in the lateral cortex is demonstrated in Figure 1, where it is clearly seen that there is a complete consolidation in the medial cortex, while a line persists: “the dreaded black line”<sup>[9]</sup>.

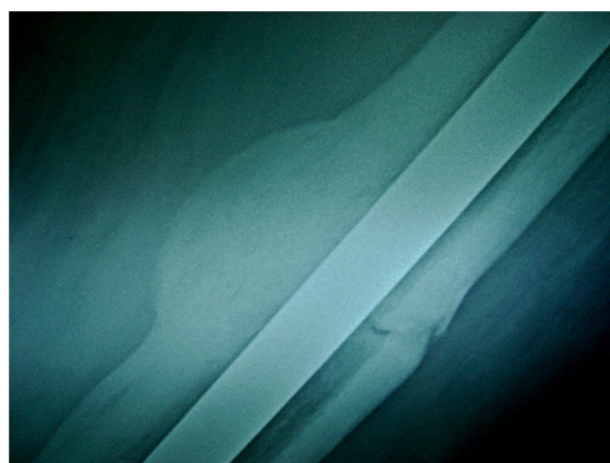
Intramedullary nailing is the first-line treatment for a complete femoral atypical fracture, although the risk of delayed healing and revision surgery seems to be higher than with a typical femoral fracture<sup>[10]</sup>. Orthopedists treating fractures of the femur have not agreed on the entry site of the anterograde femoral nail; studies done on cadaver bones remain inconclusive, because for some the ideal point is the medial edge of the trochanter near the insertion of the muscle piriform<sup>[11]</sup> while for others it is the trochanteric or piriform fossa, the latter with much controversy<sup>[12]</sup>. In any case, an incorrect entry point can lead to stresses between the implant and the bone, inducing other iatrogenic fractures<sup>[13]</sup>. In this particular case, the nail at the insertion site did not stay flush with the cortex of the greater trochanter (photo 2) because this fact allowed the gluteal muscles it’s irritating, generating limping in an abduction.



**Figure 1** Transverse fracture of the left femoral diaphysis in the lower third. It starts in the lateral cortex, has a transverse line, takes both cortices and ends at the medial cortex with a slight spike (AO-ASIF Classification. 32 A3)<sup>[5,6]</sup>.



**Figure 2** Technical failures are evident that it was not introduced flush with the trochanter. It gives the impression that the neck is in varus.



**Figure 3** One year later, an exuberant medial callus is evident but the fracture line in the lateral cortex persists (“the dreaded black line”).

There are studies that show that in humans the teriparatide<sup>[6]</sup> as anabolic allows a good consolidation of the fractures. But the combination with zoledronic acid has only been studied in animals,



especially in rats<sup>[14,15]</sup>. And the studies suggest that this association It could be valid. In our case, a callus of significant size was obtained to treat an “atypical” fracture of the femoral diaphysis with the combination of both therapeutic products.

One of the most important clinical signs<sup>[16]</sup> is the prodrome pain at the groin level, as in our case to tell us that a stress fracture has started. This type of fracture can happen in two ways: by compression and tension<sup>[17]</sup>; those of localized compression in the inferior cortical of the neck, below the periosteum or endosteal, that makes suspect bony callus formation with apparent indemnity of the trabecular pattern; while that of tension begins in the superior cortex with a line perpendicular that if it injures the trabeculae<sup>[18]</sup>. These are not frequent injuries, they often go unnoticed or are not thought of. They can represent between 5% and 10% of all fractures

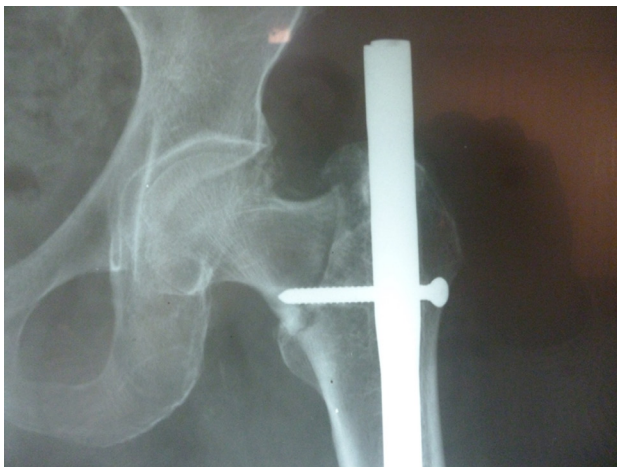

Figure 4 Basicervical fracture (AO 31B3).

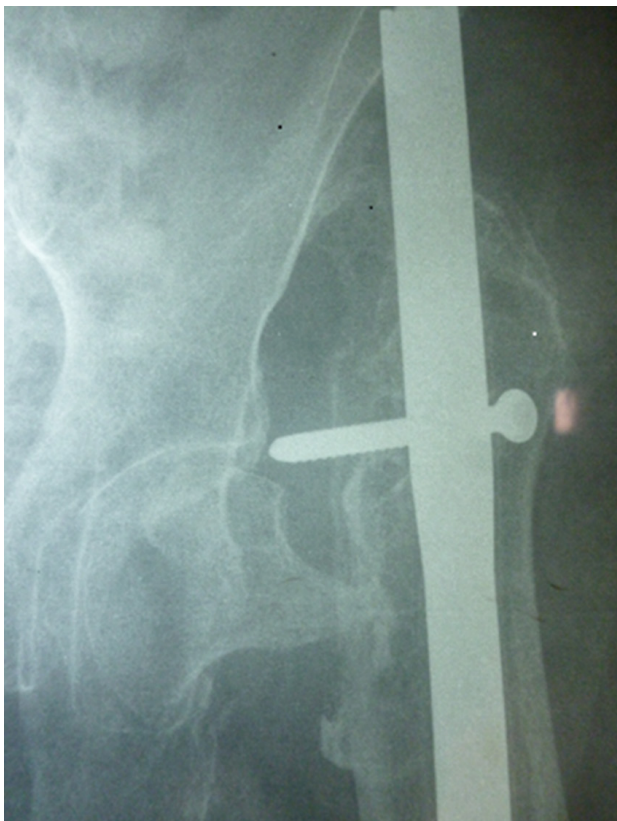


Figure 5 The resorption of the femoral neck with an elevation of the trochanteris evident.

of this modality with an incidence of 199/100,000 persons-year and it is a lesion with unpredictable postoperative results, because osteonecrosis as well as lack of union, bad union, and osteoarthritis. It is unknown what anatomical characteristics predispose to fatigue fractures<sup>[8,19]</sup>.

The geometry of the hip and proximal femur determines in part the stresses that are experienced on the lateral aspect of the femoral cortex and Figure 2 show clearly a coxa vara. In the bibliography analyzed, we did not find clinical references that the placed proximal anti-rotation screw or abduction limping could be the origin of the basicervical fracture<sup>[20]</sup>.

The present case of an osteoporotic elderly woman treated with bisphosphonates would be a basicervical fracture due to insufficiency, but by shearing and not by tension, which in our opinion should be a variant of the classification often reported fact. Osteolysis by avascular necrosis according to some statistics reaches 30% of cases<sup>[21]</sup>. Varus pseudarthrosis is typical of stress fractures, undiagnosed or not intervened on time, and the recommendation for this injury should be a joint replacement, total or partial, according to the patient’s conditions; the authors decide to install a total uncemented arthroplasty of the revision type<sup>[22,23]</sup>.

Elderly hip fractures until now have been considered as “typical”<sup>[4,5]</sup> of fragility arising from osteoporosis but the stress basicervical fractures of the femoral neck, secondary to the prolonged use of bisphosphonates, have been reported since 2002<sup>[24-28]</sup> and today this “atypical” variant has been reported in four opportunities one of them bilateral<sup>[24]</sup>. The basicervical fracture of our case is like one presented by two of these authors<sup>[25,26]</sup> the others correspond to the classic description of fractures of the femoral neck due to stress<sup>[27,28]</sup>.

In conclusion, we presented a case so far not reported, of successive atypical ipsilateral fractures of the diaphysis (this

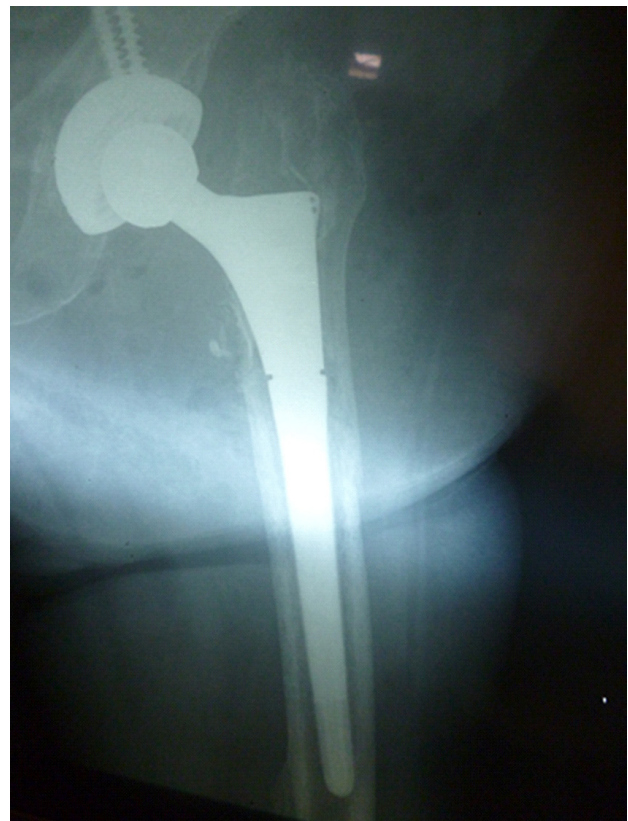

Figure 6 Hip prosthesis of the revision type is evident the bad bone quality, lack of medial support and a negative vos sign.

case fulfills 4/5 of the major ASBMR criteria for an AFF) and subsequently a basicervical fracture of the femur neck, both associated to the prolonged use of bisphosphonates, but the last one has to aggravate as the march in abduction due to the prominence of the femoral nail and the basicervical wrong place anti-rotary screw.

## ACKNOWLEDGMENTS

A Daniele Thonon for the assistance in grammar

## REFERENCES

1. Odvina CV, Zerwekh JE, Rao DS, Maalouf N, Gottschalk FA, Pak CYC. Severely suppressed bone turnover: a potential complication of alendronate therapy. *J Clin Endocrinol Metab.* 2005; **90**(3): 1294-1301. [DOI:10.1210/jc.2004-0952]
2. Shane E, Burr D, Abrahamsen B, Adler RA, Brown TD, Cheung AM, et al. Atypical subtrochanteric and diaphyseal femoral fractures: second report of a task force of the American Society for Bone and Mineral Research. *J Bone Miner Res.* 2014; **29**(1): 1-23. [DOI:10.1002/jbmr.1998]
3. Kellam JF, Meinberg EG, Agel J, Karam MD, Roberts CS. Fracture and Dislocation classification Compendium--2018. *J Orthop Trauma* Volume 32, Number 1 Supplement, January 2018. [DOI:10.1097/BOT.0000000000001063]
4. Erne P, Burckhardt A. Femoral neck fatigue fracture. *Arch Orthop Trauma Surg* 1980; **97**: 213-20.
5. Fullerton LR Jr, Snowdy HA. Femoral neck stress fractures. *Am J Sports Med.* 1988; **16**: 365-77.
6. Volpin G, Hoerer D, Groisman G, Zaltman S, Stein H. Stress fractures of the femoral neck following strenuous activity. *J Orthop Trauma* 1990; **4**: 394-8.
7. van de Laarschot DM, Somford MP, Jager A, Oei EH, Bos PK, Zillikens MC. "Atypical" atypical femur fractures and use of bisphosphonates. *Clin Cases Miner Bone Metab.* 2016 Sep-Dec; **13**(3): 204-208. [DOI: 10.11138/ccmbm/2016.13.3.204]
8. Egol KA, Koval KJ, Kummer F, Frankel VH (1998) Stress fractures of the femoral neck. *Clin Orthop Relat Res* 348, 72-78.
9. Mohan PC, Howe TS, Koh JS, Png MA. Radiographic features of multifocal endosteal thickening of the femur in patients on long-term bisphosphonate therapy. *Eur Radiol.* 2013; **23**: 222-7. [DOI: 10.1007/s00330-012-2587-y]
10. Koh A, Guerado E, Giannoudis PV. Atypical femoral fractures related to bisphosphonate treatment: issues and controversies related to their surgical management. *Bone Joint J.* 2017 Mar; **99-B**(3): 295-302. [DOI:10.1302/0301-620X.99B3.BJJ-2016-0276.R2].
11. Gausepohl T, Pennig D, Koebke J, Harnoss S. Antegrade femoral nailing: An anatomical determination of the correct entry point, *Injury* 2002; **33**(8): 701-5.
12. Grechenig W, Pichler W, Clement H, Tesch NP, Grechenig S. Anatomy of the greater femoral trochanter: clinical importance for intramedullary femoral nailing. Anatomic study of 100 cadaver specimens. *Acta Orthop.* 2006 Dec; **77**(6): 899-901. [DOI: 10.1080/17453670610013196]
13. Byun YS, Jung GH. Three-dimensional correlation between trochanteric fossa and the ideal entry point for antegrade femoral nailing. *Injury* 2016 Nov; **47**(11): 2539-2543. [DOI:10.1016 / j.injury.2016.09.026]
14. Murphy CM, Schindeler A, Cantrill LC, Mikulec K, Peacock L, Little DG.PTH(1-34) Treatment Increases Bisphosphonate Turnover in Fracture Repair in Rats. *J Bone Miner Res.* 2015 Jun; **30**(6): 1022-9. [DOI:10.1002/jbmr.2424]
15. Curtis RC, Custis JT, Ehrhart NP, Ehrhart EJ, Condon KW, Gookin SE, Donahue SW. Combination Therapy with Zoledronic Acid and Parathyroid Hormone Improves Bone Architecture and Strength following a Clinically-Relevant Dose of Stereotactic Radiation Therapy for the Local Treatment of Canine Osteosarcoma in Athymic Rats. *PLoS One.* 2016 Jun 22; **11**(6): e0158005. [DOI:10.1371/journal.pone.0158005]
16. Talbot JCJ, Cox GG, Townend MM, Langham M, Parker PJ . Femoral neck stress fractures in military personnel--a case series. *J R Army Med Corps* 2008; **154**: 47-50
17. Malhotra R, Meena S, Digge VK. Tensile type of stress fracture neck of femur: role of teriparatide in the process of healing in a high risk patient for impaired healing of fracture. *Clin Cases Miner Bone Metab.* 2013 Sep; **10**(3): 210-2.
18. Devas MB. Stress fractures of the femoral neck. *J Bone Joint Surg* 1965; **47B**: 728-737.
19. Niva MH, Kiuru MJ, Haataja R, Pihlajamaki HK. Fatigue injuries of the femur. *J Bone Joint Surg Br.* 2005; **87**: 1385-1390. [DOI:10.1302/0301-620X.87B10.16666]
20. Saita Y, Ishijima M, Mogami A, Kubota M, Kaketa T, Miyagawa K, Nagura N, Wada T, Sato T, Fukasaku S, Gen H, Obayashi O, Nemoto M, Kaneko K. Association between the fracture site and the mechanical axis of lower extremities in patients with atypical femoral fracture. *J Bone Miner Res.* 2012; **27**(Suppl 1).0.
21. Visuri T, Vara A, Meurman KOM. Displaced stress fractures of the femoral neck in young male adults: A report twelve operative cases. *J Trauma* 1988; **28**: 1562-1569.
22. Johansson C, Ekenman I, Tornkvist H, Eriksson E. Stress fractures of the femoral neck in athletes. *Am J Sports Med* 1990; **18**: 524-528. [DOI:10.1177/036354659001800514]
23. Blain-Paré E, Ehlinger M, Dosch JC, Moser T. Rapid osteolysis of the femoral neck: consequence of an insufficiency fracture of the hip? *Skeletal Radiol.* 2013 Aug; **42**(8): 1089-95. [DOI: 10.1007/s00256-013-1622-7]
24. Iwamoto J, Takeda T. Insufficiency fracture of the femoral neck during osteoporosis treatment: a case report. *J Orthop Sci.* 2002; **7**: 707-712. [DOI: 10.1007/s007760200126]
25. Ahn DK, Kim JH, Lee JI, Kim JW. Bilateral femoral neck insufficiency fractures after use of a long-term anti-resorptive drug therapy for osteoporosis: a case report. *Hip Pelvis.* 2015; **27**: 115-119. [DOI: 10.5371/hp.2015.27.2.115]
26. Kim DH, Lee EC, Kang SK. Insufficiency fracture of ipsilateral femur neck in patient treated with long term bisphosphonate treatment-a case report. *J Bone Metab.* 012; **19**: 159-162.[DOI: 10.11005/jbm.2012.19.2.159]
27. Khan SK, Savaridas T, Hemers JS, Maarouf Z, Orgee JM, Orr MM. Atraumatic intracapsular neck of femur fractures after prolonged bisphosphonate treatment: a new atypical variant? *Clin Cases Miner Bone Metab.* 2016; **13**: 38-41. [DOI:10.11138/ccmbm/2016.13.1.038]
28. Wilk R, Kusz D, Grygiel H, Grosiak M, Kamiński J, Kusz M. Atraumatic femoral neck fracture during bisphosphonate treatment: case report and review of the literature. *Aging Clin Exp Res.* 2018 Jul; **30**(7): 881-885. [DOI:10.1007/s40520-017-0846-]