

## Minimally Invasive Distal Biceps Tendon Repair

David Christopher Kieser<sup>1</sup>, Michael Charles Wyatt<sup>2</sup>, Scheherezade Soltani<sup>3</sup>, David Becker<sup>4</sup>, Francisco Antonio Lopez-Marambio<sup>5</sup>, Niels Hammer<sup>4,6,7</sup>

1 University of Otago, Department of Orthopaedics and Musculoskeletal Medicine, Christchurch, New Zealand;

2 Midcentral District Health Board, Department of Trauma and Orthopaedic Surgery, Palmerston North, New Zealand;

3 Oxford University NHS Foundation Trust, Division of Spinal Surgery, Oxford, England;

4 University of Otago, Anatomy Department, Dunedin, New Zealand;

5 Hamilton Hospital, Hamilton, New Zealand;

6 Department of Trauma, Orthopedic and Plastic Surgery, University Hospital of Leipzig, Germany;

7 Fraunhofer Institute for Machine Tools and Forming Technology, Dresden, Germany.

**Conflict-of-interest statement:** The author(s) declare(s) that there is no conflict of interest regarding the publication of this paper.

**Open-Access:** This article is an open-access article which was selected by an in-house editor and fully peer-reviewed by external reviewers. It is distributed in accordance with the Creative Commons Attribution Non Commercial (CC BY-NC 4.0) license, which permits others to distribute, remix, adapt, build upon this work non-commercially, and license their derivative works on different terms, provided the original work is properly cited and the use is non-commercial. See: <http://creativecommons.org/licenses/by-nc/4.0/>

**Correspondence to:** David Kieser, Department of Orthopaedic Surgery and Musculoskeletal Medicine, Canterbury District Health Board, 2 Riccarton Avenue, Christchurch, New Zealand.

Email: [kieserdavid@gmail.com](mailto:kieserdavid@gmail.com)

Telephone: +064 21 149 9829

Fax: +0064 3 467 9709

Received: March 1, 2019

Revised: April 6, 2019

Accepted: April 10 2019

Published online: August 28, 2019

### ABSTRACT

**AIM:** To describe a new modified technique for minimally invasive distal biceps tendon repairs.

**MATERIALS AND METHODS:** A case report and surgical

description are provided to illustrate the surgical technique and expected outcomes.

**RESULTS:** We used a 1.5cm ulna-based incision two fingerbreadths below the elbow flexion crease with blunt dissection of the subcutaneous tissue to avoid damage to the lateral cutaneous nerve of the forearm. We then incised the bicipital aponeurosis along its fibres and utilised blunt dissection radial to the brachial artery to access the native distal biceps tendon footprint on the radius and to retrieve the distal biceps tendon. Reinsertion of the tendon could then be performed with a number of existing techniques, however, this approach ensured optimal angle to insert the biceps tendon distal and posterior to the radial tuberosity and therefore into the native footprint for optimal biomechanical function of the repair.

**CONCLUSIONS:** We describe a minimally invasive approach for distal bicep repair that provides an excellent cosmesis, a low risk to the lateral cutaneous nerve of the forearm and an optimal angle for fixation of the distal biceps to its native footprint, which we believe optimises early functional outcomes.

**Key words:** Tendon; Biceps; Repair; Biomechanic; Cosmetic

© 2019 The Author(s). Published by ACT Publishing Group Ltd. All rights reserved.

Kieser DC, Wyatt MC, Soltani S, Becker D, Lopez-Marambio F, Hammer N. Minimally Invasive Distal Biceps Tendon Repair. *International Journal of Orthopaedics* 2019; 6(4): 1161-1164 Available from: URL: <http://www.ghrnet.org/index.php/ijo/article/view/2533>

### BACKGROUND

Distal biceps brachii tendon ruptures are an uncommon problem, typically affecting 1-2 patients per 100,000 per year and predominantly affecting males<sup>[1,2]</sup>. This predominantly occurs on the dominant arm and results from an excessive eccentric load to the flexed elbow<sup>[1]</sup>. While acute patients present with cubital fossa pain, bruising and swelling, distal bicep ruptures result in long-term weakness of forearm supination and to a lesser degree elbow flexion<sup>[2]</sup>. Thus, non-operative treatment is reserved for lower demand patients<sup>[2,3]</sup>.

Operative intervention for acutely ruptured distal bicep tendons involves reattachment of the bicep to the proximal radius. Many surgical techniques have been advocated, but broadly these are

single or double incision approaches and intra-osseous or peri-osseous repairs<sup>[4,5]</sup>. While there are proponents for either technique, a single incision improves the cosmetic result and reduces the risk of radio-ulna synostosis. Intra-osseous fixation potentiates tendon repair strength and healing capacity, but risks injury to the posterior structures, notably the posterior interosseous nerve, and risks proximal radial fractures<sup>[6]</sup>.

Irrespective of the technique used, all repairs require an anterior approach to retrieve the biceps tendon and to access the anterior radius. Thus, the most common neurological injury during distal biceps repair is damage to the lateral cutaneous nerve of the forearm which runs obliquely from the antecubital fossa to innervate the lateral forearm<sup>[7]</sup>. Other risks with the anterior approach include injury to the median nerve and brachial artery, infection and stiffness.

We present our surgical technique of minimally invasive distal biceps repair, which we believe reduces the risk of lateral cutaneous nerve palsy, improves the fixation position of the distal bicep on the radius, optimises the cosmetic outcome and enhances early functional rehabilitation.

## CASE

### Pre-operative

A 47-year-old right hand dominant manual labourer felt “something go” in his elbow when lifting a grand piano. He subsequently developed antecubital fossa pain, swelling and bruising. He had a classic positive hook test with asymmetry of his biceps muscle bulk. His neurological examination was normal, but he had pain and weakness with elbow flexion and supination. His vascular examination was normal. An ultra-sound scan confirmed a distal biceps avulsion with 8 cm retraction of the tendon.

After informed consent, a minimally invasive single incision distal biceps repair was undertaken.

### Surgical technique

The patient is positioned supine with the arm on an arm board. The arm is prepped and draped to the axilla. A sterile tourniquet is applied high on the arm, but not inflated. This is used if inhibitory bleeding is encountered during the operation or to prevent the biceps brachii tendon from retracting after it has been retrieved. The forearm is supinated and local anaesthesia with adrenaline (5ml of Marcaine 0.5% with adrenaline) infiltrated in the line of the incision. A transverse incision is then performed two fingerbreadths below the cubital fossa skin crease (Figure 1).

The incision is sized to accept the surgeon’s digit, usually 1.5cm with its most radial extent being in the midline of the skeletal forearm. It is important to note that patients often have variable sizes of the forearm musculature, particularly their brachio-radialis which may malposition the incision. We therefore use the easily palpable distal humeral epicondyles to determine the midline of the skeletal forearm.

After incision blunt dissection is used to access the antebrachial fascia. The superficial veins are preferentially swept off the bicipital aponeurosis (lacertus fibrosis) rather than coagulating them, as this tends to reduce venous ooze during the procedure. Bipolar cautery of cutaneous vessels is rarely required. A blunt self-retainer is inserted and the bicipital aponeurosis incised in line with its fibres to create a small window. Further blunt dissection sweeping the fat off the bicipital sheath, which in the acute rupture is easily identified, is used and the radial tuberosity palpated. Occasionally, ante-brachial veins are encountered. These may need to be ligated. The digit should

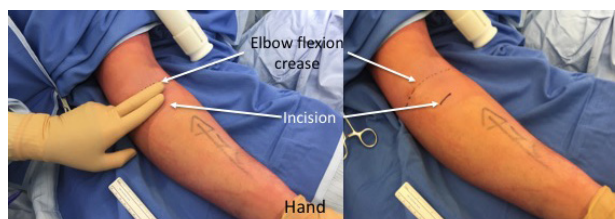


Figure 1 Determining the incision site for the minimally-invasive distal biceps repair on a left arm.

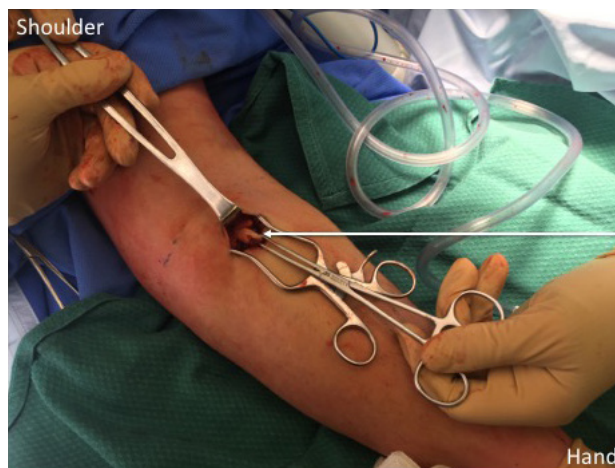

Figure 2 The distal biceps tendon delivered into the wound.

then be inserted and the position of the brachial artery determined. Dissection radial to the artery will protect the median nerve, which does not need to be exposed.

The biceps sheath is often disrupted and we utilise the breach in this sheath to gain access to the bicipital tunnel. However, occasionally it is not damaged, in which case we use a transverse incision of the biceps sheath around 4-5 cm above the radial tuberosity. This allows a gate style self-retainer, if operating without an assistant, or Langenbeck hooks, if operating with an assistant, to be inserted within the residual sheath distally and importantly, allows us to easily work within the biceps sheath to retrieve the ruptured tendon and prepare the biceps insertion site. Working within the sheath also affords protection from surrounding structures and may optimise biceps tendon gliding post-operatively.

The distal biceps footprint lies distal and posterior to the bicipital tuberosity<sup>[8]</sup>. This is either palpated as a raw area from which the tendon has avulsed or as a stump of residual tendon if rupture occurred through the tendon insertion. Once the native footprint is identified the digit is then used to sweep proximally within the plane of the biceps tunnel to palpate the distal biceps tendon. This can be aided by “milking” the arm to deliver the biceps tendon to the digit and by flexing the elbow. Once palpable the digit is removed and a curved clamp, such as a curved Kocher or Alice tissue holding forceps is inserted into the same plane as the digit and the distal biceps retrieved and delivered into the wound (Figure 2). The distal bicep tendon is then prepared according to the fixation method used.

Multiple fixation options are available and suitable for this minimally invasive technique. Our favoured option is an intra-osseous fixation with an endo-button and interference screw, because it offers excellent tendon bone contact and fixation strength as well as the addition of an interference screw that can further ulnarly deviate the biceps tendon for maximal biomechanical benefit of the repair<sup>[4]</sup>. This is performed in a standard manner. The ulnar-ward position

of the incision with the forearm in maximal supination, now offers excellent access to the ulna aspect of the radius and ensures that the distal bicep can be reinserted into its native footprint (Figure 3).

After the bone tunnel is prepared the endo-button is inserted and flipped. The tendon is then parachuted into the wound and inserted into the radial tunnel prior to the sutures being locked. The interference screw is inserted into the bone tunnel on the proximal radial aspect of the tendon. This advances and ulnarly deviates the tendon for optimal biomechanical advantage. The repair is tested, further local anaesthetic liberally applied and the wounds closed (Figure 4). We dress our wounds with simple dry dressings and the arm left without support.

### Post-operative

Post-operatively he was neurologically intact and was allowed a full range of motion without a sling but advised to avoid resisted elbow flexion and supination for six weeks. One week post-operatively he had achieved a full range of elbow flexion and extension as well as forearm supination and pronation (Figure 5).

By eight weeks he had returned to most activities including using a screw driver. By three months he had returned to full activities. At the two-year follow-up he has remained asymptomatic, continues to work as a manual labourer and has not experienced a re-prolapse.

## DISCUSSION

Distal biceps repair often represents an unfamiliar operation to less experienced surgeons, however the principals of fixation and the local anatomy is well established. Essentially, Langer's lines run transversely in the forearm, the lateral cutaneous nerve of the forearm runs obliquely in the proximal forearm after breaching the antebrachial fascia, the brachial artery lies immediately medial to the biceps tendon and the median nerve lies ulna to this artery and the distal biceps attaches to the radius at a point dorso-ulna to the radial tuberosity<sup>[8]</sup>.

The incision we utilise, which is oriented transversely follows Langer's lines and optimises the cosmetic outcome. Starting two fingerbreadths distal to the elbow crease affords the best position distally to easily trace the biceps tendon sheath and identify the radial tuberosity. If the incision is too distal the leash of cutaneous vessels hinders the dissection and also makes retrieving the ruptured biceps tendon end more challenging. Too proximal, an incision increases the risk of encountering the lateral cutaneous nerve of the forearm, makes the preparation of the bicep's insertion more difficult and the bone tunnels more oblique. The ulna-based incision allows the best protection of the lateral cutaneous nerve of the forearm, which is often not even visualised in the dissection. It also allows direct access to the bicep's tendon sheath allowing retrieval of the ruptured tendon. The insertion of the distal biceps is distal and posterior to the bicipital tuberosity<sup>[8]</sup>. The bicep therefore wraps around the radial tuberosity which optimises its supination torque. Unfortunately, attaining such an insertion is traditionally difficult when approaching the radius from a single incision anterior approach but the benefit of our ulna-based approach is that it aids in exposing the ulna aspect of the proximal radius to insure optimal position of the bicipital fixation. However, the surgeon must recognise the risk to the brachial artery and median nerve. Thus, it is important during the deeper dissection, to identify the brachial artery and remain radial to this structure in order to avoid damage to these neuro-vascular structures.

The other key features of the dissection are to dissect the superficial veins off the lacertus rather than coagulating them as this tends to reduce venous ooze during the procedure. Second, is to split the

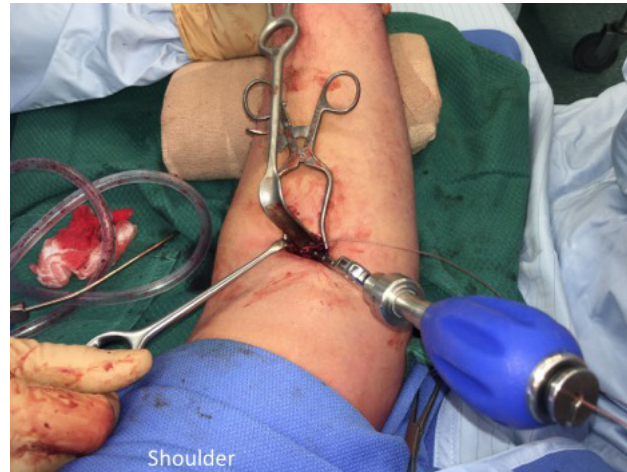


Figure 3 Inserting the biceps tendon repair.

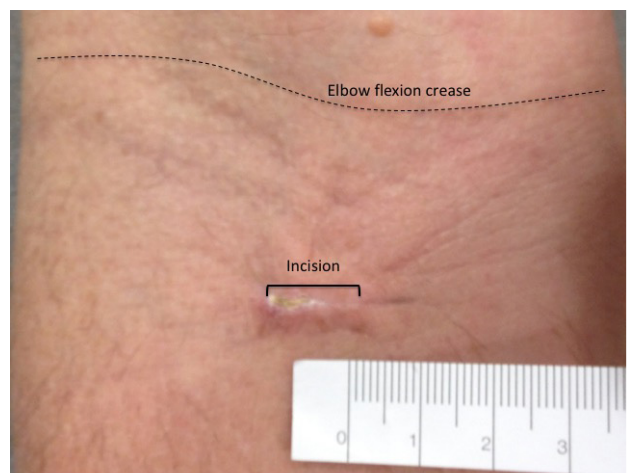


Figure 4 Photograph of the one-week post-operative incision site.

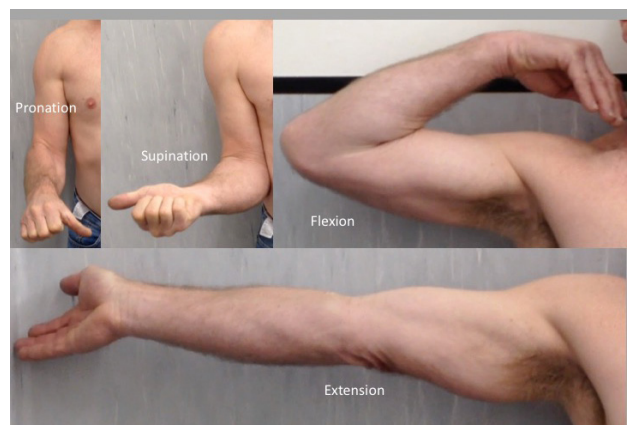


Figure 5 One-week post-operative range of motion.

bicipital aponeurosis in line with its fibres to create a small window, because this maintains retractors during the procedure and reduces the soft tissue trauma. Below this, one should simply sweep the fat off the bicipital sheath, which in the acute rupture is easily identified. We then enter the biceps sheath through its traumatic defect or with an incision 4-5cm above the radial tuberosity. This allows retractors to be inserted within the residual sheath distally. It also allows us to easily work within the biceps sheath to retrieve the ruptured tendon and prepare the biceps insertion site. We feel that working within the sheath affords protection from surrounding structures and may

optimise biceps tendon gliding post-operatively.

We favour the use of a combined suspension and interference screw fixation, which provides a secure fixation and optimises the position of the tendon by pushing the tendon ulnarly within the bone tunnel. However, alternative techniques, such as suture anchors, can also be used with this technique.

In conclusion, we describe a minimally invasive approach for distal bicep repair that provides an excellent cosmetic outcome, with a low risk to the lateral cutaneous nerve of the forearm and an optimal angle for fixation of the distal biceps to its native footprint, which we believe optimises early functional outcomes.

## ACKNOWLEDGEMENTS

Glynn Kieser for her editorial input.

## REFERENCES

1. Safran MR, Graham SM. Distal biceps tendon ruptures: Incidence, demographics and the effect of smoking. *CORR*. 2002; **404**: 275-283
2. Sarda P, Qaddori A, Nauschutz F, Boulton L, Nanda R, Bayliss N. Distal biceps tendon rupture: Current concepts. *Injury* 2013; **44**(4): 417-420. [PMID: 23199755]; [DOI: 10.1016/j.injury.2012.10.029]
3. Chillemi C, Marinelli M, De Cupis V. Rupture of the distal biceps brachii tendon: conservative treatment versus anatomical reinsertion -- clinical and radiological evaluation after 2 years. *Arch Orthop Traum Surg*. 2007; **127**(8): 705-708.
4. Greenberg JA. Endobutton repair of distal biceps tendon ruptures. *The J Hand Surg*. 2009; **34**(8): 1541-1548. [PMID: 19801110]; [DOI: 10.1016/j.jhbsa.2009.05.021]
5. El-Hawary R, MacDermid JC, Faber KJ, Patterson SD, King GJW. Distal biceps tendon repair: Comparison of surgical techniques. *J Hand Surg*. 2003; **28**(3): 496-502. [PMID: 12772111]; [DOI: 10.1053/jhsu.2003.50081]
6. Sotereanos DG, Pierce TD, Varitimidis SE. A simplified method for repair of distal biceps tendon ruptures. *JSES*. 2000; **9**(3): 227-233. [PMID: 10888168]
7. Bisson L, Moyer M, Laningham K, Marzo J. Complications associated with repair of a distal biceps rupture using the modified two-incision technique. *J Shoulder and Elbow Surg*. 2008; **17**(1): S67-71. [PMID: 17931894]; [DOI: 10.1016/j.jse.2007.04.008]
8. Hutchinson HL, Gloystein D, Gillespie M. Distal biceps tendon insertion: An anatomic study. *Surg*. 2008; **17**(2): 342-346. [PMID: 17931901]; [DOI: 10.1016/j.jse.2007.05.005]