

The Results of Anterior Open Reduction Approach for Developmental Dysplasia of the Hip in Children Under 12 Months Old

Nguyen Ngoc Hung¹, Nguyen Do Ngoc Hien², Hoang Hai Duc¹

1 Vietnam National Hospital for Pediatrics

2 Hanoi Medical University

Conflict-of-interest statement: The author(s) declare(s) that there is no conflict of interest regarding the publication of this paper.

Open-Access: This article is an open-access article which was selected by an in-house editor and fully peer-reviewed by external reviewers. It is distributed in accordance with the Creative Commons Attribution Non Commercial (CC BY-NC 4.0) license, which permits others to distribute, remix, adapt, build upon this work non-commercially, and license their derivative works on different terms, provided the original work is properly cited and the use is non-commercial. See: <http://creativecommons.org/licenses/by-nc/4.0/>

Correspondence to: Nguyen Ngoc Hung, head of Pediatric Orthopaedic Department in Vietnam National Hospital for Pediatric, President of Vietnam Pediatric Orthopaedic Association.

Email: Ngocyenhung@gmail.com

Telephone: +84 024 37841276

Received: May 27, 2019

Revised: May 30, 2019

Accepted: June 2 2019

Published online: August 28, 2019

ABSTRACT

BACKGROUND: This study aimed to evaluate the results of the previous method of anterior open reduction done in children <12 months of age.

METHOD: Patients who underwent an anterior open reduction in the typical hip dysplasia between 2012-2018 were screened retrospectively. The study included 12 hips of 12 patients. The corrected percentage of acetabular index is calculated by measurements of acetabular angles performed prior operation and at the final examination. Avascular necrosis (AVN) is classified according to the criteria of Kalamchi-MacEwen while X-ray and clinical evaluation is performed by Severin and McKay criteria.

RESULTS: The average age for surgery was 9.91 months (9-11

months) while the average follow-up time was found to be 52.75 months (43-64 months). According to the radiology criteria Severin, Evaluating patients after surgery with Excellence 5 (41.7%), Good 4 (33.3%), Mediation 2 (16.7%), Poor 1 (8.3%). Whereas, according to the rating based on McKay criteria, Excellent 8 (66.7%), Good 3 (25.0%) and Poor 1 (8.3%). Avascular necrosis (AVN) of the femoral head has been encountered in 1 (8.3%) of 12 hips. According to the criteria of Kalamchi-MacEwen Classification; 1 unveiled type I avascular necrosis, respectively.

CONCLUDE: We have encountered according to outcomes data of this study that open reduction technique by the anterior approach for treatment of developmental dysplasia of the hip (DDH) presented more successful clinical and radiological outcomes in the 9 - < 12 months old infants.

Key words: Decreased opening; Dysplasia of hip joint development; Avascular necrosis; Prior open reduction method

© 2019 The Author(s). Published by ACT Publishing Group Ltd. All rights reserved.

Hung NN, Hien NDN, Duc HH. The results of anterior open reduction approach for Developmental Dysplasia of the Hip in Children under 12 months old. *International Journal of Orthopaedics* 2019; 6(4): 1133-1140 Available from: URL: <http://www.ghrnet.org/index.php/ijo/article/view/2561>

INTRODUCTION

The main goal of treatment in developmental dislocation of hip joints is to obtain and maintain concentric reduction and stability for normal development of the hip joint. In young children, this can mostly be done by non-surgical methods. Reduced openness is necessary in children when concentric reduction and stability cannot be achieved by closed methods^[1-3].

The goal of treating congenital hip dislocation (CDH) is to return the femoral head in the acetabulum, and maintain this position until the pathological changes have reversed. Early reduction implies that there has been less adaptive change and reduced the time required for femoral head, acetabulum and capsule structure to return to normal

configuration^[4].

In general, everyone agrees that the closed reduction of hip joints in newborns should be tried first, but this will fail in a proportion of patients; some due to the intervention of soft tissue^[5,6]. Persistence with conservative therapy can then lead to permanent defect joints. The earliest age that open reduction can be safely done is controversial^[7,8]. Chuinard. 1972^[9] stated that the Law of Wolves withdraws from common operations; If this is true, the sooner the concentric reduction is, the better. In our unit, most patients were initially seen by one of us and treated in Stracathro braces^[10]. Any subsequent X-ray or clinical evidence of instability leads to hospitalization for arthroscopy and subcutaneous endoscopic surgery under general anesthesia. If concentric reduction is achieved, the patient is placed in a plaster tube, but X-ray evidence of soft tissue intervention is an indication for an open reduction, regardless of the patient's age or bone chemistry, of the capital femoral tip.

We have now reviewed these patients for the incidence and severity of avascular necrosis and the residual excess, which is related to the capitalization of the capital, the age of the patient. and use traction before surgery.

The age of the patient is one of the important factors to decide on treatment in dislocated joints of the hip joint. When surgery is indicated, while should only be reduced in children under 12 months of age (before walking)^[11,12], acetabular or femoral procedures have been proposed at the time of openness in patients, greater than 18 months^[12,13].

It is unclear in the literature whether a concomitant bone procedure is needed in children 12 years and 18 months and with dislocations of hip joints. Although only reduced is recommended by a number of authors^[4,11], others suggest bone surgery (acetabular, femoral or both) at the time of open reduction^[3,14,15].

We have reviewed our patients with developmental dislocation of the hip that has undergone open reduction. The purpose of this study is to evaluate the outcome of surgical patients Under 12 months of age at the time of reduction.

MATERIALS AND METHODS

After being approved by our Research Ethics Committee, a retrospective study was conducted on all patients under 12 months of age with treated DDH by reducing closure under general anesthesia. Body and hip arthroplasty surgery at our hospital between January

2012 and January 2018. Children under 12 months of age are treated by open reduction. Patients with dislocated or paralyzed dislocations and those with acetabular dysplasia without true dislocation (intact Shenton) or followed for less than two years were excluded from the study.

There were Fourteen hips of 14 patients (14 hips) were performed open reduction. The remaining two patients were lost to follow-up. Leaving 12 patients, with 12 hips with unilateral dislocations (Table 1). There are 3 boys and 9 girls.

This research group includes patients diagnosed with DDH Activities performed by a surgeon (Author) and evaluation of two independent orthopedic surgeons, not members of the department.

All members have confirmed their consent. The study was approved by the Institute of Ethical Evaluation of our Institute and carried out according to the principles of the Declaration of Helsinki.

No one has preoperative skin or skeletal traction, nor has varicose veins or skeletal deformities or shortening procedures. Patients were performed at an average age of 9.91 months, SD = 0.79 (9 to 11) and the average follow-up age was 62.5 months (58 to 72) and the average follow-up time was 52.6 months (43 to 68) (Table 1).

Operation

Indication

All sides cannot be reduced or reduced without maintenance if there is no mandatory position (> 90, 100)) or > 60 degrees of abduction) when examined without anesthesia. Twelve patients (12 hips) younger than 12 months or too large for a Pavlik harness, are not treated before surgery. Traction force is not used in any patient. All patients were tested under general anesthesia. An indication that open reduction is the inability to reduce the hip with gentle manipulation or the inability to maintain it without a required position.

Surgical techniques

During the anterior approach, following sterile staining and draping under general anaesthesia, the patient was laid down in the supine position while the hips were in flexion, abduction and external rotation. An approximately 4 cm long longitudinal incision was performed starting from 1.5-2.0 cm distal to the pubic tubercle and over adductor longus muscle.

Adductor tenotomy was performed passing through subcutaneous layers. A blunt entry was conducted through the muscle plane created placing adductor longus and brevis muscles in anterior and

Table 1 Data of Patients.

No	Sex	Age at surgery (months)	Follo.-up Duration (months)	Age La. F-U(months)	Operated side	Acetabular index		Complication		Additional Operation	Kalamchi's Criteria	McKey's Criteria
						Pre-Op.	Post-Op.	Re-Dis.	AVN			
1	F	9	45	54	L	40	24		-		1	1
2	F	10	43	53	L	32	24		+		-	2
3	F	11	62	73	L	40	25		-		-	2
4	M	10	52	62	L	34	23	+	-	+	-	3
5	M	9	47	56	R	34	22		-		-	1
6	F	10	46	56	L	40	24		-		-	1
7	F	11	54	65	L	38	22		-		-	1
8	F	9	61	70	L	32	22		-		-	1
9	F	9	47	56	L	41	24		-		-	1
10	M	10	58	68	R	40	23		-		-	2
11	F	10	64	74	L	42	24		-		-	1
12	F	11	54	64	L	40	25		-		-	1
	F/M:9/3	9.916 (SD=0.79)	52.75 (SD=7.25)		L/ R:(10/2)	37.75 (SD=3.67)	23.5SD=1.08)		8.20%	8.30%		

Pre-Op: Pre-Operation, Post-Op: Post-Operation; Re-Dis: Re-Dislocation; AVN: Avascular Necrosis.

with adductor magnus and gracilis muscles in posterior. In deep plane, Lesser trochanter was palpated and iliopsoas tendon was dissected from adhesion site to the lesser trochanter. Following, the joint capsule was exposed bluntly and revealed longitudinally from inferomedial aspect to expose the hip joint. At this stage, its avoided to injure medial circumflex artery and its branches. Ligamentum Teres tendon was excised and intra articular pulvinar tissue was removed. Following control of the reduction, only subcutaneous tissue and skin were sutured, the pelvipedal casting was applied to the hips in their most stable position. This stability was generally achieved in 30°-40° abduction, 90° flexion and 10°-15° internal rotation. Following totally 3 months application of casting, Dennis-Brown Bar was used during whole day and night for 3 months and then during only night time for 3 months.

If the hip was still unstable and in these Kirschner wires were used to maintain concentric reduction. The wire was passed through the greater trochanter and into the ilium above the capsule after capsulorrhaphy and was retained seven days (Figure 1).

Postoperative care.

The double spica cast was applied immediately after surgery, hip in 30°- 40° abduction, 90° flexion and 10°-15° of internal rotation.

Three months after surgery, the entire cast is removed, and Patients is gradually weaned haft spica cast it only at night and nap time until acetabular development is normal. The haft spica cast (cf. Figure 2) is usually worn for an average of 12 to 24 months after surgery.

Result evaluation

The patients were arranged to return to the outpatient clinic for a period of three months on the first day after surgery and after 3 months, 6 months, 1 year and 2 years after the surgery and then the interval year. The patients were evaluated clinically during each visit to the range of movement of the affected hip, gait quality, Trendelenburg test and the presence of any pain. Radiographs on each side are performed to assess the quality of reduction, acetabular index and the presence or absence of avascular necrosis. Each patient's preoperative radiographs were evaluated to determine the affected hip's acetabular index and station.

The difference in body length can be measured by a doctor during physical examination and through X-rays. Usually, a doctor measures the hip level when the child is standing barefoot. A series of measured wooden blocks can be placed under short legs until the hips are balanced. If the doctor believes that a more accurate measurement is needed, he or she can use X-rays. In developing children, a doctor may repeat physical exams and X-rays every six months up to a year to see if the difference in length is increased or not.

Evaluation of avascular necrosis (AVN) of the femoral head is performed according to the classification of Kalamchi and MacEwen^[16]: Grade 1: Changes affecting the ossific nucleus; Grade 2: Lateral physeal damage; Grade 3: Central physeal damage; Grade 4: Total damage to the head and physis.

Details of radiography according to Severin^[17] have been used to evaluate radiological results after surgery: Gade 1: Normal; Degree 2: Moderate deformation of the head or neck of the femoral or acetabulum; Grade 3: Dysplastic does not sublimate; Grade 4: Subluxed; Grade 5: Head coupling with secondary acetabulum at the top of the original acetabulum; Grade 6: Dislocated; Grade 7: Arthritic.

Barrett's modification of McKay's criteria^[13] was used for the clinical assessment of postoperative results: Excelent result: Stable, painless hip, no limp, negative Trendelenburg sign, full range of

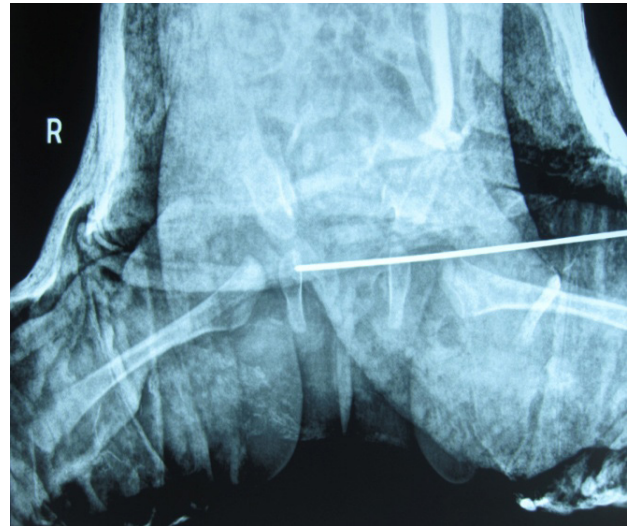


Figure 1 Kirschner wires was passed through the greater trochanter and into the ilium.

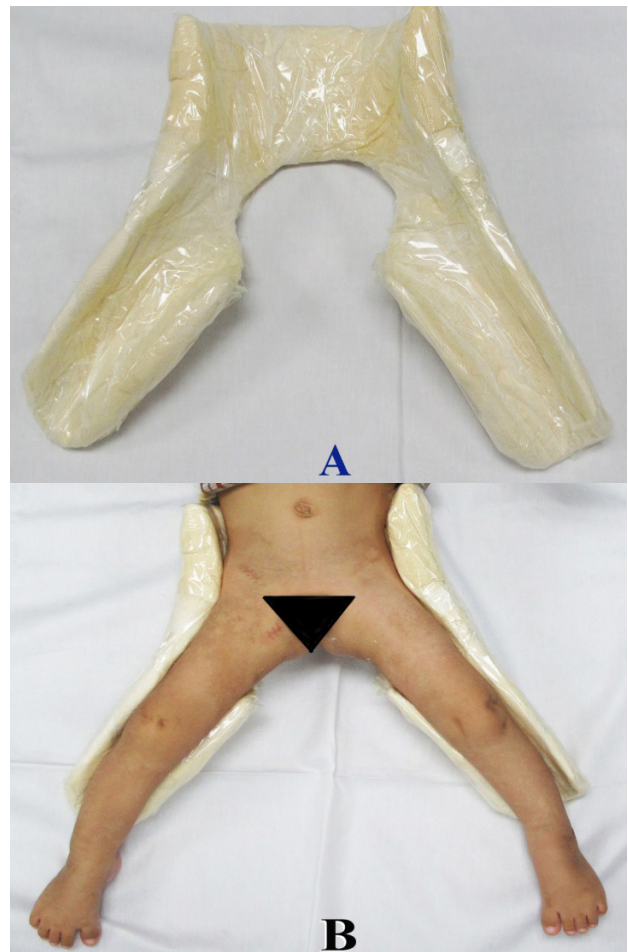


Figure 2 (A): The haft spica cast; (B): The patient is gradually weaned from the brace to wear haft spica cast it only at night.

motion. Goog result: Stable, painless hip, slight limp, slight degree in range of motion. Fair result: Stable, painless hip, limp, positive Trendelenburg sign, and limited range of motion, or a combination of these. Poor result: Unstable or painful hip, or both; positive Trendelenburg sign.

Statistical analysis

Data were analyzed using the Epi Info Software Public 6.04 for epidemiology, developed by the Centers for Disease Control and Prevention (CDC) in Atlanta, Georgia, USA, <http://www.ncdc.gov/epiinfo/html/prevVersion.htm>. We have taken the χ^2 quiz and the t-test to compare the average among the groups before and after surgery. P values below 0.05 are considered statistically significant.

RESULT

Between 2012 and 2018, 9 girls (75%) and 3 boys (25%) with DDH underwent open reduction. Age of Patients under 12 months (Table 1).

None had preoperative skin or skeletal traction, nor derotational varus or valgus osteotomies or shortening procedures for initially operation.

The anterior open reduction approach was used all patients.

The average operative time was 45 min (range 35 - 55 min). Radiographs were made preoperatively, and immediately postoperatively.

The blood loss from this procedure is acceptable. Post-operative blood transfusion was no required.

Sex: Female: 9. Male: 3; Age at Operation: 9.9 months (SD = 0.79); Follow-Up duration: 52.75 months (SD = 7.25); Side hips: Right 2, Left hips 10; Average Pre-Operative AI 37.75° (SD=3.67, Post-Operative AI: 23.5° (SD = 1.08); AVN: 1 (8.3%); Additional surgery: 1 (8.3%); AVN according to Kalamchi's Criteria: 1 (8.3%); Evaluating McKey's Criteria Excellent 8 (66.7%), Good 3 (25.0%) and Poor 1 (8.3%).

Illustration

A boy, 10 months old, with Developmental Dysplasia of the Left hip. Tönnis grade 4. Preoperative Acetabular Index was 42.9° (Figure 3), Femoral Neck Anteversion Angle was 33°. Shaft-Neck Angle was 135°. MRI with Acetabular anteversion 21.8°. The patient have been operated OR. Patient place bilateral hip spica cast with the hips in human position was applied at surgery. Hip spica was maintained for 3 months in a double hip spica cast with hip in 30°- 40° abduction, 90° flexion and 10°-15° of internal rotation. After removed spica cast, abduction brace was used for 3 months. Afterwards, the brace was worn at night for an additional 3 months for a total brace time of 6 months.

Post-operative 6 months AI was 25.5 degrees. Age at time Follow-up was 4 years-6 months with AI 24.3°, CEA 39.2° (Figures 4, 5). Result according to Barrett Modified McKay criteria for clinical evaluation was good and Deformity of femoral head or neck or acetabulum according to Severin was Type I.

Operative Incision (Figure 6), Scar incision 8 cm length (Figure 6). The patient had well functional result with patient sitting cross legged (Figure 7). The patient with Negative Trendelenburg gait (Figure 8).

DISCUSSION

Results and age at Operation

The results of operation performed before 12 months of age (before the appearance of the capital femoral epiphelium) were significantly better ($p = 0.01$) compared to surgeries between the ages of 12 and 24 months. (after the capital femur tricks). In 12 patients (12 hips) who had opened open before 12 months of age, only one hip joint had avascular necrosis. It appears that the results are better after earlier declines, not with the patient's age or the capital's ossification status^[30].

In the treatment of DDH, it is necessary to achieve stable and

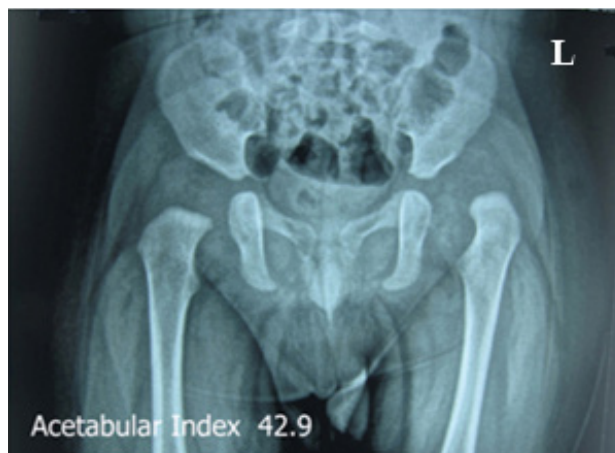


Figure 3 PreOperation.

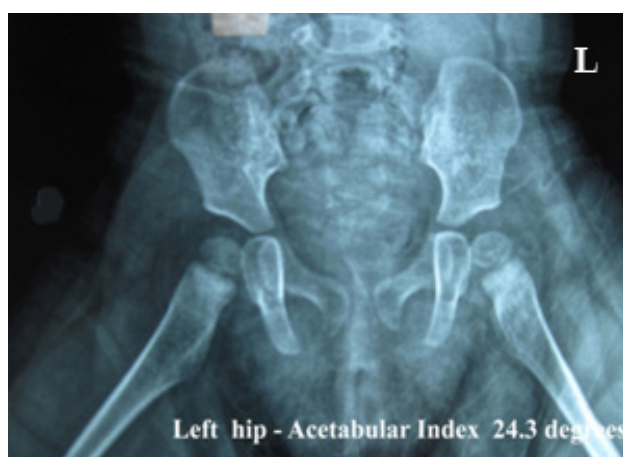

Figure 4 Latest Follow-Up of the roentgenography.

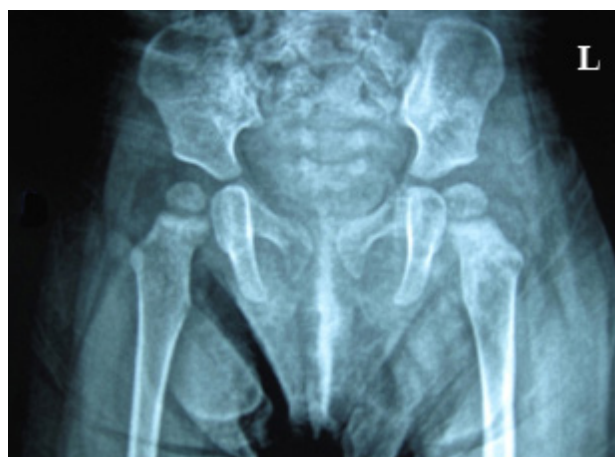

Figure 5 Latest Follow-Up of the roentgenography.

concentric reduction in early age. Development of the femoral head and acetabulum with normal values. Therefore, all structures. In which preventing reduction should be intervened to get concentric reduction. Medical approach facilitate and fasten to achieve these structures. Two major and critical complications which can be experienced by this approach are insufficient hip stability after reduction and avascular necrosis due to injury of medial circumflex femoral artery^[24]. It has been reported that this technique has been applied more successfully in infants under 12 months of age although it is usually performed in children under 18 months of age^[20,24,21,25]. Our findings also support data obtained from other studies in the

document. Castillo and Shearman^[21] have operated 26 hips in their series and obtained the most favorable results in children aged 5-14 months. We also observed in our study that the difference between acetabular preoperative and postoperative indicators was higher in operative hips between the ages of 3-12 months. We used the anterior open reduction approach for all patients in this study (Tables 1, 2, 5).

Additional surgery

The most common indications are reported on additional surgical interventions after open reduction for relocation, subluxation and acetabular dysplasia^[16,21,24,25]. In this study, additional surgical intervention is needed due to acetabular proliferation and dysplasia in 1 hip, respectively. Incidents of additional surgical interventions show diversity in the literature (Table 5)^[21,24,25].

Supplementary surgery is required only in 11% of hips in patients younger than 12 months of age at the time of decline, compared with 30% for those 24 to 36 months of age and 71% for those over 36 months of age. The increased rate of re-operation may be due to secondary adaptive changes caused by prolonged dislocation.

In our study, additional surgery was needed in 8.3% of 12 hips with DDH. The rate of additional surgery was found to be 7.15% between 3 and 12 months of age during surgery while the rate was determined to be 21.45% between the ages of 13-18 months at surgery by literature^[21,24,25]. (Table 3).

In 2018, we reported DDH with age at surgery Older than 12 months with accepted result 94.6 % of 129 hips^[31] and compared 91.7% of 12 hip in this study, and Pvaluated = 0.640012, no significance. statistical.

Redislocation of the Hip

Putti^[32] distinguishes subluxation with dislocations on the basis of the relationship between the joint surfaces of the femoral head and the acetabulum.

He notes that the femoral head in the sublimation is irregularly arranged in the socket, while in the dislocated position, the head is completely away from the acetabulum. Although the joint was exposed, the femoral head was heterogeneous or concentrated in the acetabulum. In the current study, two patients (4.5%) had recurrence of hip joints.

Repositioning in 3 of 54 hips with Rudolf *et al*^[33] reported, Grill^[34] reported 12 over 50 hips with redislocation and reshaping. Ruszkowski and Pucher^[35] with one of 33 hips in 26 redislocation children. Both Tachdjian^[36] and Fixsen^[37] confirmed that the reasons for not maintaining reduced hip bone were due to poor bone resection surgery, a loose capsulorrhaphy drug and anti-femoral fever. The capsulorrhaphy has helped to prevent later movement in the early postoperative period while the hip has been repaired. In this study, there was 1 (8.3%) hip with repositioning.

In 2016, we reported 18 hip dislocations after reducing open DDH in children aged one to three^[38], 18 re-Dislocations of 129 hips (9.4%) compared with 1 re-Dislocation of 12 hip (8.3%) in this study, Pvaluate = 0.700201 and not statistically significant.

We believe that technical problems are often the cause of dislocations with all of them having an intact capsule, an inverted ligament, tight psoas, limbus movement and densing anterior capsule. We have done with all hips that have been removed by scar tissue; adductor tenotomy; not required to release the psoas tendon, limbus transposition; Release of ligaments is required.

Avascular necrosis and age at operation

The most important complication observed during DDH treatment

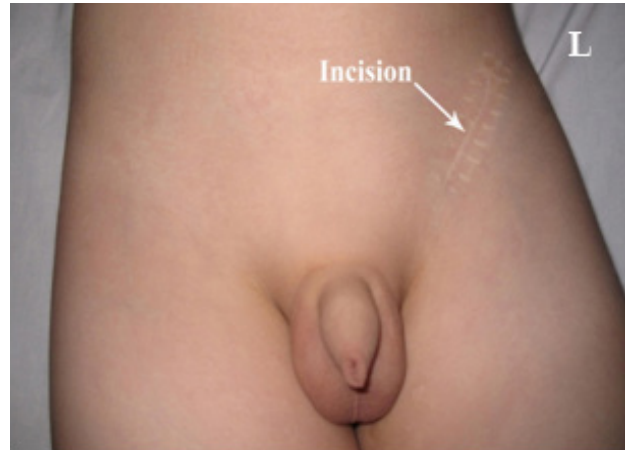

Figure 6 Anterior Open reduction approach Post-Operative Scar incision 8 cm.

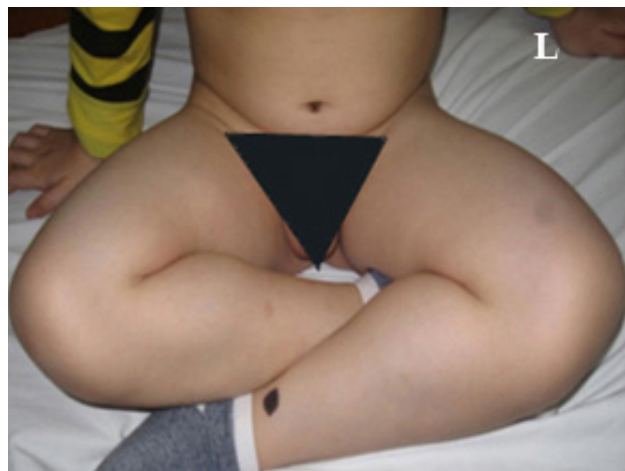

Figure 7 Well functional result with patient sitting cross legged.

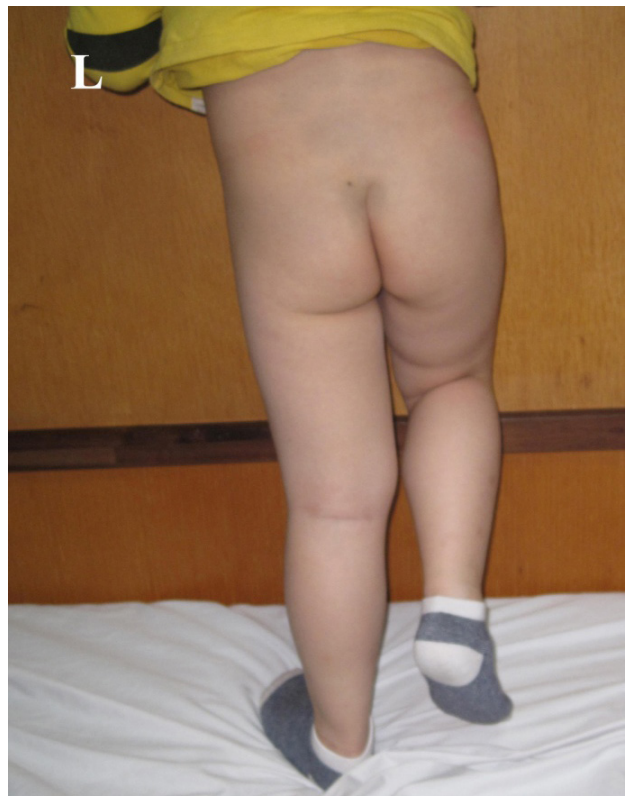


Figure 8 Negative Tredelenburg gait.

is AVN^[16]. A range of frequency values of AVN ranging from 0% to 67% have been reported in studies conducted to date in literature^[16,18,20] (Tables 4, 6).

In our study, the incidence of AVN was found to be 10.7%. Incident of AVN in age groups at 3-12 and 13-18 months surgery respectively are about 7.1% and 3.6%. Kiely *et al*^[39] reported 4.2 and 1 respectively, Type I, Class 2 and Type 3. We conclude that preserving the middle femoral artery and its branches by meticulous implementation. Dissection reduces the risk of avascular necrosis when considering narrow surgery.

In our entire series of avascular necrosis diseases have been seen at 2% and partly by 20%. Changing Kalamchi and MacEwen in groups II and III or IV is only seen in 10%, mainly in children over 24 months of age. The incidence of avascular necrosis significantly correlates with age: in the pre-chemistry group, this ratio is 14% (four hips), but three people are in group I and therefore have a great prognosis. Significant necrosis occurs only on one side (3%). Two of the four patients were under one year old, but with one nucleus, showed changes in blood vessels but the sample was too small for statistical analysis.

After 12 months of age, there was a steady increase in the rate of avascular necrosis: both sides with a total change of 19 months and 40 months left. Although level I changes prevail in the 12 to 24 months group and can recover almost completely, but in older age groups, level II and III changes predominate. Previous studies on age factors related to avascular necrosis have conflicted results. Kalamchi and MacEwen^[6] 1980 have found serious changes in blood vessels when starting treatment before six months of age and similar findings have been reported by Gregosiewicz and Wosko^[40] 1988. However, Grill *et al*^[35] 1988, analyzing the use of Pavlik mining, concluded that treatment began within the first three months of life, only producing 50% of the avascular necrosis rate seen when Treatment starts from Tuesday to Friday. This is supported by vascular studies of Ogden and Moss^[41] 1978 who demonstrated that partial necrosis after disruption of coronary arteries before the age of five, but overall necrosis later in life. In addition, chronic dislocated hip contractions may put vessels at risk of tension and compression, outside the joints (Hensing 1979^[41]). Surgical release of addictive substances and iliopsoas will significantly reduce this risk.

A comparison of our incidence of avascular necrosis with other series is difficult, because of the criteria for various avascular necrosis: some studies include only cases of avascular necrosis. Ross *et al*^[7] 1988, reported on 161 hips that were treated with an open reduction, found that the incidence of avascular necrosis was more serious when the open reduction was done before the capital fossil. They have used a similar activity to ours, regularly dividing psoas tendons. However, our series began much later, with the benefit of the reports emphasizing the need to avoid extreme kidnapping and external rotation during the real estate process (Salter, Kostuik and Dallas 1969^[42]; Gage and Winter 1972^[43]). The difference in stationary position can explain our declining vascular necrosis rate, Gibson and Benson^[44] 1982, reported incidence Avascular necrosis 5.4%,

Table 6 The results of previous studies.

	Mean follow-up	Age (months)	Number of hips	Subsequent bony surgery	Avascular necrosis	Severin 3 and 4
Koizumi <i>et al</i> [29]	18.7 years	< 12	14	28% (4/14)	64% (9/14)	71% (10/14)
Castillo <i>et al</i> [21]	81 months	< 12	13	0% (0/13)	8% (1/13)	8% (1/13)
Konigsberg <i>et al</i> [25]	11 years	< 12	34	15% (5/34)	23% (8/34)	20% (7/34)
Roose <i>et al</i> [19]	31 months	< 12	15	13% (2/15)	0%	NR
Hung (In this study)	52.75 months	< 12	12	8.3% (1/12)	8.3% (1/12)	8.3% (1/12)

Age at Operation: < 12 months; Number of Hips 12-34. Subsequent bony surgery: 0-28%; AVN: 8-64%; Severin 3 and 4: 8-71%

in 147 were not treated with surgical removal and bone resection, in the age of 12 months and three years Scaglietti and Calandriello, 1962^[45] reported 24% necrosis avascular after reducing openness in children under one year to five years, with 22% requiring secondary procedures, but not mentioning the criteria used for avascular necrosis.

In 2018, we reported DDH with age at surgery Older than 12 months with AVN 23.7%^[46] and compared 8.3% in this study and Pvaliated = 0.378044, no significance. statistical.

Table 2 The evaluation of the patients according to Severin's Classification.

Severin Class	Group 1 (Excellent)	Group 2 (Good)	Group 3 (Mediate)	Group 4 (Poor)	Group 5 (Poor)	Group 6 (Poor)
Number Hip	5	4	2	1	0	0
Percent	41.70%	33.30%	16.70%	8.30%		

Table 3 The rates of additional surgery in the literature^[2, 7-9, 12-16].

Additional surgical intervention	
Castillo and Sherman (5 and 14 months) [21]	35%
Mergen <i>et al</i> (3 to 33 months-mean 12.1 months) [20]	27.90%
Sosna <i>et al</i> [26]	85%
Matsushita <i>et al</i> (<36 months) [27].	34%
Danielsson <i>et al.</i> (2 to 64 months-mean 10 months) [28]	>50%
Di Mascio <i>et al.</i> (<12 months - mean 4.8 months) [24]	8%
Hung (In this study)	8.30%
The rates of additional surgery in the literature: 8-85%	

Table 4 The rates of avascular necrosis in the literature^[1, 2, 6-12].

Avascular Necrosis	
Ferguson [18]	0%
Roose <i>et al</i> [19]	0%
Kalamchi [16]	67%
Mergen <i>et al</i> [20]	9.30%
Castillo and Sherman [21]	15%
Weinstein [22]	13.60%
Şener <i>et al</i> [23]	26.50%
Di Mascio <i>et al</i> [24]	8.30%
Konigsberg <i>et al</i> [9]	27.50%
Hung (In this study)	8.30%
The rate of AVN in laterature: 0-67%	

Table 5 The measurements of acetabular index, center-edge angle, and Sharp's angle in children younger than 12 months throughout follow-up.

	Preoperative	2 years	4 years	6 years
Acetabular index	37.75 ± 5.6	25.6 ± 5.2	24.9 ± 4.6	23.5±108
Center-edge angle	N/A	10.2 ± 13.8	20.1 ± 16.4	24.3 ± 9.2
Sharp's angle	N/A	54.8 ± 5.6	51.5 ± 5.6	44.4 ± 5.1

N/A, not applicable.

Avascular necrosis and conservative management.

Two recent series report the incidence of avascular necrosis after conservative treatment. Grill *et al*^[46] 1988, report an incidence of 2.38% in 3611 hips of children less than 11 months old treated by the Pavlik harness. However, these included only total necrosis in Tonnis grades I, II and III. In Tonnis grade IV, the rate of avascular necrosis rose to 16%. Gregosiewicz and Wosko^[39] 1988 reported an incidence of 21% of avascular necrosis in 254 hips treated conservatively at various ages. They used the criteria of Kalamchi and MacEwen^[16], 1980.

It is evident that the iatrogenic complication of avascular necrosis in CDH occurs after all kinds of treatment. The goal is therefore to minimise it. Our study has made certain facts more clear. The age at early open reduction and the state of ossification of the capital epiphysis are not perhaps of great significance. What is more important is that the hip is reduced and maintained in reduction without putting undue tension on the surrounding soft tissues or undue pressure on the bony surfaces. Where closed reduction fails, the sooner this is done by an open operation, the more likely is a good result. Close attention to operative detail and technique is essential. Other factors which may help to minimize the risk of avascular necrosis after open reduction are pre-operative traction, division of the psoas tendon and adductor tenotomy.

CONCLUSION

In conclusion, the data obtained in this study showed positive results can be achieved by reducing previous access to DDH provided in newborns at age 12 months of age and lower at surgery.

Therefore, an anterior open reduction approach to hip dysplasia is a simple and safe technique with its advantages such as reduced blood volume, low avascular necrosis rate, and some other disadvantages including narrow and swollen surgery in the postoperative period. The results obtained in our study suggest that an anterior open reduction approach can lead to more favorable outcomes in children under and 12 months of age.

Limitations of research

The limitations of this study include small cohorts of patients and the results after surgery are too small to perform parametric statistical analysis. This is a report of interim results because most patients are not monitored until the skeleton matures. The subjects of this study are not identical in the data used.

REFERENCES

- Gabuzda GM, Renshaw TS. Reduction of congenital dislocation of the hip. *J Bone Joint Surg Am* 1992; **74A**: 624-631. [PMID: 24398153]
- Vitale MG, Skaggs DL. Developmental dysplasia of the hip from six months to four years of age. *J Am Acad Orthop Surg* 2001; **9**: 401-411. [PMID: 11730331]
- Weinstein SL, Mubarak SJ, Wenger DR. Developmental hip dysplasia and dislocation. Part II. *J Bone Joint Surg Am* 2003; **85A**: 2024-2035. [PMID: 15116642]
- Hensinger RN. Clinical dislocation of the hip. *CIBA* 1979; **3** 1(1).
- Leveuf J. Results of open reduction of "true" congenital luxation of the hip. *J Bone Joint Surg [Am]* 1948; **30-A**: 875-82. [PMID: 18887292]
- Somerville EW. Open reduction in congenital dislocation of the hip. *J Bone Joint Surg [Br]* 1953; **35-B**: 363-71. [PMID: 13084680]
- Ross ERS, Ford DJ, Evans GA. Factors influencing the incidence of avascular necrosis in anterior open reduction for the congenitally dislocated hip. *J Bone Joint Surg [Br]* 1988; **70-B**: 680.
- Zionts LE, MacEwen GD. Treatment of congenital dislocation of the hip in children between the ages of one and three years. *J Bone Joint Surg [Am]* 1986; **68-A**: 829-46. [PMID: 3733773]
- Chuinard EG. Femoral osteotomy in the treatment of congenital dysplasia of the hip. *Orthop C/in North Am* 1972; **3**: 1 57-74. [PMID: 5012579]
- MacKenzie IG. Congenital dislocation of the hip : the development of a regional service. *J Bone Joint Surg [Br]* 1972; **54-B**: 18-39. [PMID: 5062379]
- Harris NH, Lloyd-Roberts GC, Gallien R. Acetabular development in congenital dislocation of the hip. With special reference to the indications for acetabuloplasty and pelvic or femoral realignment osteotomy. *J Bone Joint Surg Br* 1975; **57B**: 46-52. [PMID: 1117022]
- Herring JA. Developmental dysplasia of the hip. In: Herring JA, editor. Tachdjian's pediatric orthopaedics. 3rd ed. Vol 1. Philadelphia: WB Saunders; 2002. pp. 513-654.
- Barrett WP, Staheli LT, Chew DE. The effectiveness of the Salter innominate osteotomy in the treatment of congenital dislocation of the hip. *J Bone Joint Surg Am* 1986; **68A**: 79-87. [PMID: 3941122]
- Berkeley ME, Dickson JH, Cain TE, Donovan MM. Surgical therapy for congenital dislocation of the hip in patients who are twelve to thirty-six months old. *J Bone Joint Surg Am* 1984; **66**: 412-420. [PMID: 6699058]
- Huang SC, Wang JH. A comparative study of nonoperative versus operative treatment of developmental dysplasia of the hip in patients of walking age. *J Pediatr Orthop* 1997; **17**: 181-188. [PMID: 9075093]
- Kalamchi A, MacEwen GD. Avascular necrosis following treatment of congenital dislocation of the hip. *J Bone Joint Surg Am* 1980; **62**: 876-888. [PMID: 7430175]
- Severin E. Contribution to knowledge of congenital dislocation of hip joint : late results of closed reduction and arthrographic studies of recent cases. *Acta Chir Scand* 1941; **84 Suppl 63**: 1-142.
- Ferguson AB. Primary open reduction of congenital dislocation of the hip using a median adductor approach. *J Bone Joint Surg Am* 1973; **55**: 671-689. [PMID: 4283740]
- Roose PE, Chingren GL, Klaaren HE, Broock G. Open reduction for congenital dislocation of the hip using the Ferguson procedure. A review of twenty-six cases. *J Bone Joint Surg Am* 1979; **61**: 915-921. [PMID: 479240]
- Mergen E, Adyaman S, Omeroglu H, Erdemli B, Isiklar U. Medial approach open reduction for congenital dislocation of the hip using the Ferguson procedure. A review of 31 hips. *Arch Orthop Trauma Surg* 1991; **110**: 169-172. [PMID: 2059544]
- Castillo R, Sherman FC. Medial adductor open reduction for congenital dislocation of the hip. *J Pediatr Orthop* 1990; **10**: 335-340. [PMID: 2355075]
- Weinstein SL, Ponseti IV. Congenital dislocation of the hip. Open reduction through a medial approach. *J Bone Joint Surg Am* 1979; **61**: 119-124.
- Sener M, Baki C, Aydin H, Yildiz M, Saruhan S. The results of open reduction through a medial approach for developmental dysplasia of the hip in children above 18 months of age. *Acta Orthop Traumatol Turc* 2004; **38**: 247-251. [PMID: 15618765]
- Di Mascio L, Carey-Smith R, Tucker K. Open reduction of developmental hip dysplasia using a medial approach: A review of 24 hips. *Acta Orthop Belg* 2008; **74(3)**: 343-348. [PMID: 18686459]
- Konigsberg DE, Karol LA, Colby S, O'Brien S. Results of medial open reduction of the hip in infants with developmental dislocation of the hip. *J Pediatr Orthop* 2003; **23**: 1-9. [PMID: 12499934]

26. Sosna A, Rejholec M. Ludloff's open reduction of the hip: long-term results. *J Pediatr. Orthop* 1992; **12**: 603-606. [PMID: 1517419]
27. Matsushita T, Miyake Y, Akazawa H, Eguchi S, Takahashi Y. Open reduction for congenital dislocation of the hip: comparison of the long-term results of the wide exposure method and Ludloff's method. *J Orthop Sci* 1999; **4**: 333-341. [PMID: 10542036]
28. Danielsson L. Late-diagnosed DDH: a prospective 11-year follow-up of 71 consecutive patients (75 hips). *Acta Orthop. Scand* 2000; **71**: 232-242. [PMID: 10919293]
29. Koizumi W, Moriya H, Tsuchiya K, Takeuchi T, Kamegaya M, Akita T. Ludloff's medial approach for open reduction of congenital dislocation of the hip. A 20-year follow-up. *J Bone Joint Surg Br* 1996; **78**: 924-929. [PMID: 8951008]
30. Dhar S, Taylor JF, Jones WA, Owen R. Early open reduction For Congenital Dislocation of the Hip. *J Bone Joint Surg* 1990; **72-B** : 175-80. [PMID: 2312552]
31. Hung NN. Comparative Study Age at Time Operation between Younger and Older than 18 Months for Development Dysplasia of the Hip in Children. *Open Access Library Journal* 2018; February 5(2).
32. Putti V. Early Treatment of Congenital Dislocation of the Hip. *Journal of Bone and Joint Surgery* 1965; **47**: 602-606
33. Rudolf G, Christof R, Gert P, Hans M, Gabriele K and Grill F. Treatment Options for Developmental Dislocation of the Hip after Walking Age. *Journal of Pediatric Orthopaedics* 2005; **14**: 139-150.
34. Grill F. Treatment of Hip Dislocation after Walking Age. *Archives of Orthopaedic and Trauma Surgery* 1984; **102**: 148-153.
35. Ruskowski K and Pucher A. Simultaneous Open Reduction and Degatransiliac Osteotomy for Developmental Dislocation of the Hip in Children under 24 Months of Age. *Journal of Pediatric Orthopaedics* 2005; **25**: 695-701
36. Tachdjian MO. Congenital Dislocation of the Hip. Churchill Livingstone, New York. 1982
37. Fixsen JA. Anterior and Posterior Subluxation of the Hip Following Innominate Osteotomy. *Journal of Bone and Joint Surgery* 1987; **69**: 361-364. [PMID: 3584185]
38. Hung NN. Redislocation Following Zigzag Osteotomy Combined with Fibular Allograt for Dislocation of the Hip in Children. *Open Journal of Orthopedics* 2016; **6(4)**: 86-97
39. Kiely N, Younis U, Day JB, Meadows TM. The ferguson medial approach for open reduction of developmental dysplasia of the hip. A clinical and radiological review of 49 hips. *J Bone Joint Surg Br* 2004; **86**: 430-433. [DOI: 10.1302/0301-620X.86B3.14064]
40. Gregosiewicz A, Wosko I. Risk factors of avascular necrosis in the treatment of congenital dislocation of the hip. *J Pediatr Orthop* 1988; **8**: 17-9. [PMID: 3335615]
41. Ogden JA, Moss HL. Pathological anatomy of congenital hip disease. In : Weil UH, ed. Progress in orthopaedic surgery Vol. 2. Acetabular dysplasia. skeletal dysplasias in childhood. Berlin, etc: Springer-Verlag, 1978:1-45.
42. Salter RB, Kostuik J, Dallas S. Avascular necrosis of the femoral head as a complication of treatment for congenital dislocation of the hip in young children : a clinical and experimental investigation. *Can J Surg* 1969; **12**: 44-61. [PMID: 5762671]
43. Gage JR, Winter RB. Avascular necrosis of the capital femoral epiphysis as a complication of closed reduction of congenital dislocation of the hip. A critical review of twenty years' experience at Gillette Children's Hospital. *J Bone Joint Surg Am.* 1972; **54(2)**: 373-88. [PMID: 4651266]
44. Gibson PH, Benson MKD. Congenital dislocation of the hip : review at maturity of 147 hips treated by excision of the limbus and derotation osteotomy. *J Bone Joint Surg [Br]* 1982; **64-B**: 169-75. [PMID: 7068735]
45. Scaglietti 0, Calandriello B. Open reduction of congenital dislocation of the hip. *J Bone Joint Surg [Br]* 1962; **44-B**: 257-83. [PMID: 14038987]
46. Grill F, Bensahel H, Canadell J *et al.* The Pavlik harness in the treatment of congenital dislocating hip: report of a multicenter study of the European Paediatric Orthopaedic Society. *J Pediatr Orthop* 1988; **8**:1-8. [PMID: 3335614]