

## Classifications in Brief: Fernandez Classification of Distal Radius Fractures

Brian H. Goldman<sup>1</sup>, DO; Abby L. Halpern<sup>1</sup>, DO; Matthew J. Deal<sup>2</sup>, BS; Menar Wahood<sup>1</sup>, DO

<sup>1</sup> Department of Orthopaedic Surgery, Larkin Community Hospital, South Miami, FL, USA

<sup>2</sup> University of Central Florida College of Medicine, Orlando, FL, USA

**Conflict-of-interest statement:** The author(s) declare(s) that there is no conflict of interest regarding the publication of this paper.

**Open-Access:** This article is an open-access article which was selected by an in-house editor and fully peer-reviewed by external reviewers. It is distributed in accordance with the Creative Commons Attribution Non Commercial (CC BY-NC 4.0) license, which permits others to distribute, remix, adapt, build upon this work non-commercially, and license their derivative works on different terms, provided the original work is properly cited and the use is non-commercial. See: <http://creativecommons.org/licenses/by-nc/4.0/>

**Correspondence to:** Brian H. Goldman, Department of Orthopaedic Surgery, Larkin Community Hospital, South Miami, FL, USA.  
Email: [bgoldman689@gmail.com](mailto:bgoldman689@gmail.com)  
Telephone: +1-305-284-7761

Received: June 11, 2019

Revised: July 16, 2019

Accepted: July 18 2019

Published online: August 28, 2019

### ABSTRACT

**AIM:** Assess the scientific value and validity of the Fernandez classification to treat and study distal radius fractures.

**METHODS:** A review article evaluated current and past literature to determine the interobserver reliability of the Fernandez classification and its application in distal radius fractures. A literature review was performed using search engines including PubMed.

**RESULTS:** The literature demonstrated kappa scores of initial distal radius fracture evaluation 0.39 and for a second look 3 months later to be 0.15. Intra-class correlations were 0.4 and 0.12 respectively demonstrating poor intra and interobserver reliability. Additionally, CT scans utilized after initial assessment via radiographs did not improve identification.

**CONCLUSION:** This classification has only moderate reliability

that was not improved by the addition of CT scans. When this classification was specifically tested in the clinical setting, it showed no reliability when predicting associated soft tissue or structure injury. The Fernandez classification system intention was to provide a treatment algorithm, it does not serve much use outside of its historical context in the understanding of distal radius fractures.

**Key words:** Radius Fractures; Radius; Radiography; Reproducibility of Results; Observer Variation

© 2019 The Author(s). Published by ACT Publishing Group Ltd. All rights reserved.

Goldman BH, Halpern AL, Deal M, Wahood M. Classifications in Brief: Fernandez Classification of Distal Radius Fractures. *International Journal of Orthopaedics* 2019; 6(4): 1129-1132 Available from: URL: <http://www.ghrnet.org/index.php/ijo/article/view/2613>

### HISTORY

Distal radius fractures are one of the most common fracture types representing 17.5% of all fractures in adults<sup>[1,2]</sup>. Managing these fractures depends on the fracture pattern, either intra or extra articular, as well as the presence of concomitant bony or ligamentous injury<sup>[3]</sup>. Classification systems are important for guiding management of specific fractures. In 1967, Frykmann established a classification for distal radius fractures that incorporated radiocarpal, radioulnar, and ulnar styloid involvement<sup>[4]</sup>. In 1986, the AO classification system was established with a revision (1995) that focuses on extra- or intra-articular fractures and the direction of the fracture line<sup>[5]</sup>. The Universal classification (Cooney *et al* 1993) is a treatment-based system that categorizes fractures on extra- or intra-articular involvement, displacement and whether it is reducible or not<sup>[6]</sup>. The Fernandez classification was first introduced in 1993 and is based on the mechanism of injury<sup>[3,6]</sup>.

### PURPOSE

The Fernandez classification aimed to provide a system that primarily focused on the mechanism of injury in order to accurately classify injuries in an attempt to standardize treatment, while also suggesting stability, associated lesions, and identify children's equivalent

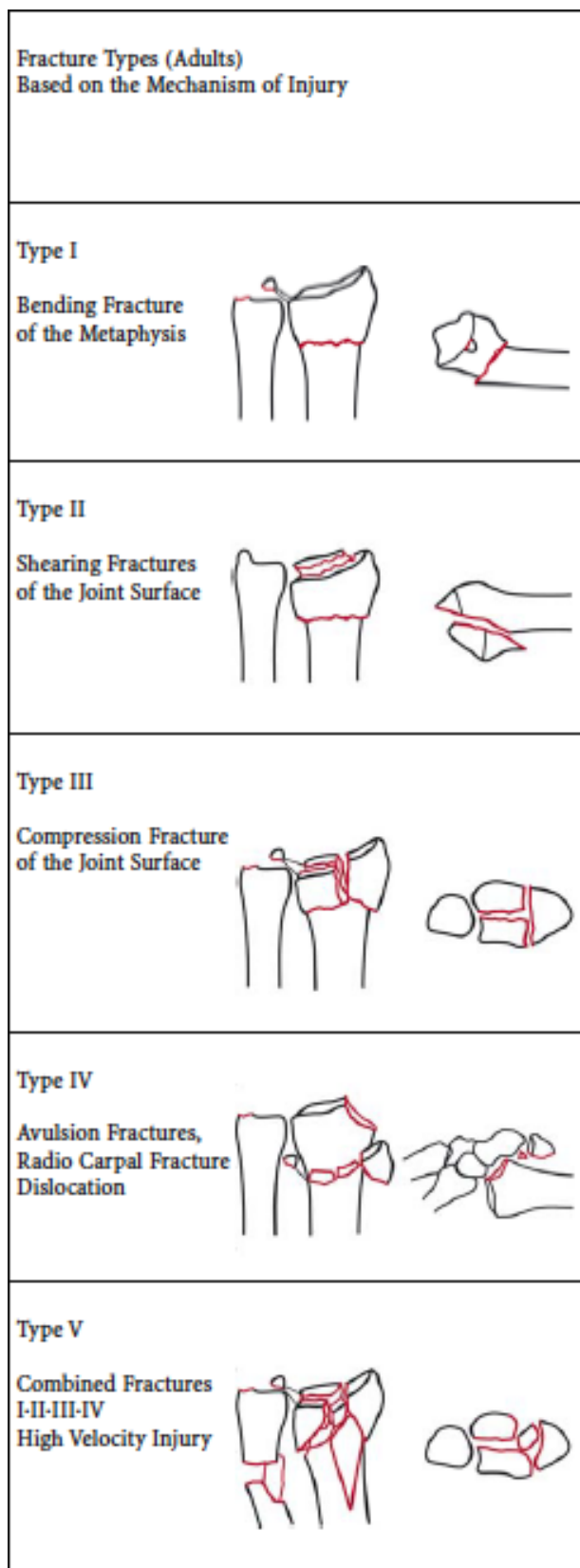
injuries<sup>[3]</sup>. Type I is treated conservatively, if deemed stable, or with percutaneous pinning or external fixation if unstable<sup>[3,7]</sup>. Type II is managed with open reduction internal fixation (ORIF)<sup>[3]</sup>. Type III is managed conservatively, limited open reduction or arthroscopically assisted extensile ORIF, or percutaneous pins combined with internal and external fixation<sup>[3,7]</sup>. Type IV is managed with closed or open reduction with pinning, screw fixation or tension wiring<sup>[3,7]</sup>. Type V is treated with a combination of all other methods<sup>[3,7]</sup>.

## DESCRIPTION

The Fernandez classification catalogues distal radius fractures into one of five mechanisms of injury (Figure 1). The predictability of associated soft tissue injury is ranked from uncommon, less uncommon, common, frequent, and is always present from Type I to Type V injury patterns respectively<sup>[3,7]</sup>. Type I is a metaphyseal bending fracture that results in two fragments with varying degrees of metaphyseal comminution. A type I injury is equivalent to a Salter Harris (SH) II injury in children<sup>[3,7]</sup>. Type II is a shearing fracture of the joint surface and can present in 2-parts, 3-parts, or with comminution. This is equivalent to a SH IV injury in children<sup>[3,7]</sup>. Type III is a compression fracture caused by axial loading of the joint surface by the scaphoid and lunate bones<sup>[8]</sup>. This can result in 2-parts, 3-parts, 4-parts, or with comminution and is equivalent to SH III, IV, or V injury in children<sup>[3,7]</sup>. Type IV is an avulsion fracture or radiocarpal fracture dislocation. This results in two parts with radial or ulnar styloid involvement, 3-parts with volar or dorsal margin involvement, or with comminution and very rarely occurs in children. Type V occurs with high velocity injuries resulting in a combination of fracture types with comminution and may have associated bone loss. They are frequently open intra-articular fractures and very rarely occur in children<sup>[3,7]</sup>. In 2015 Fakoor *et al* compared closed reduction and external fixation to open reduction and internal fixation (ORIF) in patients with type III, IV, or V fractures they found that ORIF provided significantly better range of motion, shorter return to work time, and improved anatomic radiologic criteria<sup>[9]</sup>. The Fernandez classification did not guide treatment in this study but demonstrated that although external fixation has historically been the recommended treatment for distal radius fractures, it may not provide the best possible outcome. In fact, distal radius ORIF with plates is the ideal treatment for displaced fractures, metaphyseal instability, bilateral fracture, associated carpal fractures, and intra-articular involvement<sup>[9]</sup>. In 2015 Javed *et al* studied the Fernandez classification where they designated Type I and II as low risk and types III, IV, and V as high risk with respective complication rates of 18% and 33% ( $p = 0.75$ )<sup>[10]</sup>. Each patient was treated with volar locking plates. However, the complication outcomes of stiffness, median nerve symptoms, malunion, complex regional pain syndrome, carpal arthritis does not support the expected complications of associated soft tissue disruption seen with the high-risk fractures (Type III, IV, and V) of the Fernandez classification<sup>[10]</sup>. This showed that the Fernandez classification lacked the clinical predictive value that would otherwise be expected with Type III, IV, and V injuries.

## VALIDATION

Additional studies have compared the Fernandez classification to other widely used systems. These studies used agreement based on the kappa coefficient. This coefficient assessed if the findings of the observers was significant or if they were due to chance alone. Kappa values range from 0 to 1 with a value of 0 demonstrating random chance and 1 representing significant agreement between observers.



**Figure 1** In the Fernandez (1995) classification of distal radius fractures, each type is classified based on mechanism of injury. Reproduced with permission from Axelrod T.S. (2005) Fractures of the Distal Radius. In: The Rationale of Operative Fracture Care. Springer, Berlin, Heidelberg.

Kappa values of  $< 0.5$  are considered poor, 0.51 to 0.74 good, and  $> 0.75$  an excellent level of agreement<sup>[11]</sup>. Interobserver agreement refers to the agreement between different observers and intra-observer

agreement is the measure of repeated agreement of the same observer at different time points. A study by Naqvi *et al* evaluated 25 sets of distal radius fractures treated by hand fellowship trained surgeons who were provided a detailed description of the classification prior to their evaluation. Once the results were recorded, the sets of fractures were reexamined 3 months later and compared with their original results as a group and individually. The kappa score for the first round was 0.39 and for the second round 0.15. Intra-class correlations were 0.4 and 0.12 respectively demonstrating poor intra and interobserver reliability<sup>[6]</sup>. Similar results were found by Kucuk *et al* in 2013. They examined 4 major classifications which they compared between residents and attending surgeons. This demonstrated that the Fernandez classifications had fair reproducibility among surgeons and moderate among residents<sup>[12]</sup>. Kural *et al* found similar findings of Fernandez being superior in terms of kappa coefficient but still insufficient in terms of metrical studies<sup>[13]</sup>.

In a study by Arealis *et al* the reliability of the Fernandez classification was assessed with X-rays and compared to supplemental CT scans. There was moderate inter-observer reliability when utilizing X-rays and the intra-observer reliability did not improve with the use of CT scans. With poor reproducibility of this classification system, only experienced hand surgeons benefit from utilizing CT scans to guide treatment of distal radius fractures.<sup>[14]</sup> Existing studies have already shown that the Fernandez classification has poor reproducibility indicating low reliability which can generate misleading results<sup>[6,7,12-15]</sup>.

## LIMITATIONS

The Fernandez Classification has limitations despite being commonly referred to in literature and the in clinical setting. Of note, the Fernandez Classification has poor reproducibility and reliability in the clinical setting as demonstrated in the abovementioned studies<sup>[6,7,12-15]</sup>.

Although the classification advises treatments for each type of fracture, the inability to reliably identify the fracture type makes it difficult to reliably choose a treatment option. This may explain why there so few clinical studies that utilize the Fernandez classification and provide clinical outcomes based on the treatments that the classification advises. Furthermore, the classification and its associated treatment strategies were formulated prior to the wide adopted use of the volar locking plates for surgical fixation of unstable distal radius fractures. The great clinical outcomes and anatomic reductions with this technology avoid complications associated with violating dorsal and radial soft tissues<sup>[16]</sup>.

## CONCLUSION

The Fernandez classification was initially created to provide a reliable method for assessing distal radius fractures and their associated soft tissue injuries based on the mechanism of injury. At first glance, this classification pattern seems intuitive and straightforward as it includes pediatric fracture equivalents, stability, and fracture patterns involving articular fragments. However, this classification has only moderate reliability that was not improved by the addition of CT scans<sup>[6,7,12-15]</sup>. When this classification was specifically tested in the clinical setting, it showed no reliability when predicting associated soft tissue or structure injury<sup>[10]</sup>. Additionally, this classification system has proven to be outdated as it does not include locking plates which is currently the treatment method of choice for distal radius fractures. When treated with distal locking plates patients have less pain, improved range of motion, and improved anatomic alignment on postoperative X-rays<sup>[9]</sup>.

The most recent classification system for distal radius fractures was

created by Yang *et al* in 2018. This system was based on intermediate column fractures of the distal radius and has demonstrated to have near perfect inter- and intra-observer agreement<sup>[17]</sup>. Additionally, this classification system has had excellent clinical results on both the Gartland and Werley scoring systems<sup>[17]</sup>. Unlike the classification system created by Yang, the Fernandez classification lacks comprehensibility and is unable to effectively guide treatment options with known clinical outcomes. Although the intended goal for the Fernandez classification system is to provide a treatment algorithm, it does not serve much use outside of its historical context in the understanding of distal radius fractures.

## REFERENCES

1. Court-Brown CM, Caesar B. Epidemiology of adult fractures: A review. *Injury*. 2006; **37**: 691-697. [PMID: 16814787]
2. Karl JW, Olson PR, Rosenwasser MP. The Epidemiology of Upper Extremity Fractures in the United States, 2009. *Journal of orthopaedic trauma*. 2015; **29**: e242-244. [PMID: 25714441]
3. Fernandez DL. Distal radius fracture: the rationale of a classification. *Chirurgie de la main*. 2001; **20**: 411-425. [PMID: 11778328]
4. Frykman G. Fracture of the distal radius including sequelae-shoulder-hand-finger syndrome, disturbance in the distal radioulnar joint and impairment of nerve function. A clinical and experimental study. *Acta orthopaedica Scandinavica*. 1967; **Suppl 108**: 103+. [PMID: 4175195]
5. Cooney WP. Fractures of the distal radius. A modern treatment-based classification. *The Orthopedic clinics of North America*. 1993; **24**: 211-216. [PMID: 8479719]
6. Naqvi SG, Reynolds T, Kitsis C. Interobserver reliability and intraobserver reproducibility of the Fernandez classification for distal radius fractures. *The Journal of hand surgery, European volume*. 2009; **34**: 483-485. [PMID: 19321533]
7. Jupiter JB, Fernandez DL. Comparative classification for fractures of the distal end of the radius. *The Journal of hand surgery*. 1997; **22**: 563-571. [PMID: 9260608]
8. Koshkin AB, Sergeev SV, Matveev VS, Grishanin OB. Distal forearm fractures: the analytical approach for treatment. *Ortopedia, traumatologia, rehabilitacija*. 2008; **10**: 324-330. [PMID: 18779765]
9. Fakoor M, Fakoor M, Mohammadhoseini P. Displaced Intra-Articular Fractures of the Distal Radius: Open Reduction With Internal Fixation Versus Bridging External Fixation. *Trauma monthly*. 2015; **20**: e17631. [PMCID: PMC4630594]
10. Javed S, Shahid R, Thimmiah R, El-deen M. Volar locking plate osteosynthesis for distal radial fractures. *Journal of orthopaedic surgery*. 2015; **23**: 323-326. [PMID: 26715710]
11. Viera AJ, Garrett JM. Understanding interobserver agreement: the kappa statistic. *Family medicine*. 2005; **37**: 360-363. [PMID: 15883903]
12. Kucuk L, Kumbaraci M, Gunay H, Karapinar L, Ozdemir O. Reliability and reproducibility of classifications for distal radius fractures. *Acta orthopaedica et traumatologica turcica*. 2013; **47**: 153-157. [PMID: 23748613]
13. Kural C, Sungur I, Kaya I, Ugras A, Erturk A, Cetinus E. Evaluation of the reliability of classification systems used for distal radius fractures. *Orthopedics*. 2010; **33**: 801. [PMID: 21053882]
14. Arealis G, Galanopoulos I, Nikolaou VS, Lacon A, Ashwood N, Kitsis C. Does the CT improve inter- and intra-observer agreement for the AO, Fernandez and Universal classification systems for distal radius fractures? *Injury*. 2014; **45**: 1579-1584. [PMID: 25042062]
15. Ploegmakers JJ, Mader K, Pennig D, Verheyen CC. Four distal radial fracture classification systems tested amongst a large panel of Dutch trauma surgeons. *Injury*. 2007; **38**: 1268-1272. [PMID: 17643439]

16. Jose A, Suranigi SM, Deniese PN, Babu AT, Rengasamy K, Najimudeen S. Unstable Distal Radius Fractures Treated by Volar Locking Anatomical Plates. *Journal of clinical and diagnostic research: JCDR*. 2017; **11**: RC04-RC08. [PMID: 28274009]
17. Yang Y, Yin Q, Li D, Rui Y, Wu Y, Ding Y, Jiang Y. A new classification and its value evaluation for intermediate column fractures of the distal radius. *Journal of orthopaedic surgery and research*. 2018; **13**: 221. [PMID: 30176895]