

Posterior Shoulder Fracture Dislocations Associated With Seizure Disorders

Opondo Everisto¹, MbChb, Mmed, FCS (Cosecsa), PhD

¹ Senior lecturer and Consultant Orthopaedic Surgeon, Department of Surgery, Jomo Kenyatta University of Agriculture and Technology.

Conflict-of-interest statement: The author(s) declare(s) that there is no conflict of interest regarding the publication of this paper.

Open-Access: This article is an open-access article which was selected by an in-house editor and fully peer-reviewed by external reviewers. It is distributed in accordance with the Creative Commons Attribution Non Commercial (CC BY-NC 4.0) license, which permits others to distribute, remix, adapt, build upon this work non-commercially, and license their derivative works on different terms, provided the original work is properly cited and the use is non-commercial. See: <http://creativecommons.org/licenses/by-nc/4.0/>

Correspondence to: Dr. Opondo Everisto, Department of Surgery, Jomo Kenyatta University of Agriculture and Technology, P.o Box 105, 002, 02, Nairobi, Kenya.

Email: opondodr@gmail.com

Telephone: +254 722475767

Received: June 23, 2019

Revised: July 10, 2019

Accepted: July 17 2019

Published online: August 31, 2019

ABSTRACT

BACKGROUND: Posterior fracture dislocation of the shoulder is an extremely rare injury and is associated with poor outcomes if not managed properly and in a timely manner. When associated with seizure disorders the injuries are likely to be more serious a compared to simple posttraumatic cases. Only about 4% of glenohumeral dislocations are posterior and 1% have an associated fracture of the humeral head.

METHODS: This case report is about posterior shoulder fracture dislocations associated with first seizure disorders in previously normal young adult patients aged 21 and 38 years who were not on treatment for seizure disorders. Both patients were treated by open reduction and internal fixation using proximal humerus locking

plates after failed attempted closed reduction.

RESULTS: Both patients had a good outcome with fracture healing and good range of motion at one year of follow up.

CONCLUSION: Computed Tomography Scanning (CT Scan) is useful in pre operative assessment of the injury pattern since upto 50% of the posterior dislocations are missed on plain AP X-ray of the shoulder. Open reduction via the deltopectoral approach offers the best chance of anatomic reduction with better outcomes in young patients with a posterior fracture dislocation especially the locked ones.

Key words: Posterior, Fracture Dislocation, Seizure disorder

© 2019 The Author(s). Published by ACT Publishing Group Ltd. All rights reserved.

Everisto O. Posterior Shoulder Fracture Dislocations Associated With Seizure Disorders. *International Journal of Orthopaedics* 2019; 6(4): 1165-1168 Available from: URL: <http://www.ghrnet.org/index.php/ijo/article/view/2594>

INTRODUCTION

Fracture dislocations of the shoulder are complex injuries that need timely diagnosis and appropriate management for optimal results. Of all shoulder dislocations only 1.5-4.3% are posterior in direction. A posterior dislocation with fracture is very rare and more difficult to treat. In the reported literature 50-80% of all cases is the dislocation recognized after initial assessment. This means a posterior dislocation and/or fracture is often missed by the initial emergency doctor evaluation^[1-4].

The main causes of a posterior dislocation fracture of the shoulder are either seizures or a direct trauma on the anterior side of the shoulder or indirect trauma by falling on the outstretched arm. Muscular forces generated during a seizure can lead to various fractures and dislocations including those of the shoulder, hip and jaw. Reports of fractures following seizures without direct trauma appear almost exclusively in the context of electroconvulsive therapy and as case reports in the orthopaedic literature in association with shoulder fractures^[1,3,5-7].

In this paper patients who were seen with fracture dislocations

and managed surgically after seizure disorders are presented. They presented with complaints of pain in the shoulder and inability to externally rotate the shoulder after a seizure.

CASE REPORTS

Case 1: Left Locked Posterior Shoulder Fracture Dislocation

A 38-year-old Male presented at the emergency department after having seizures earlier that evening. His wife described the seizure attack as follows: he started to roll his eyes, stiffened, convulsed and became unconscious while sitting on the couch in his leaving room. The duration of the seizures was very brief but she didn't record it. He did not fall on his right shoulder nor out of the seat. Further medical history was not relevant and the patient had no prior history of epilepsy. On arrival the patient was semi-conscious and looked anxious. Cardiovascular examination was normal. He had undergone attempted closed reduction in another hospital that failed to reduce the shoulder.

The neurovascular status of the right arm and forearm was normal. An X-ray and CT Scan of the shoulder showed a locked posterior dislocation fracture of the right shoulder (Figures 1-4). He was operated on the same evening: the dislocation fracture was reduced and fixed using a Philos locking plate and modified Mc Laughlins procedure

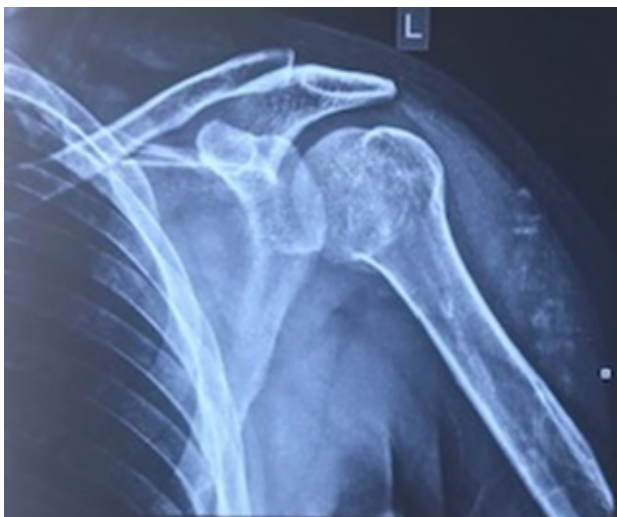

Figure 1 Initial AP X ray of the shoulder.

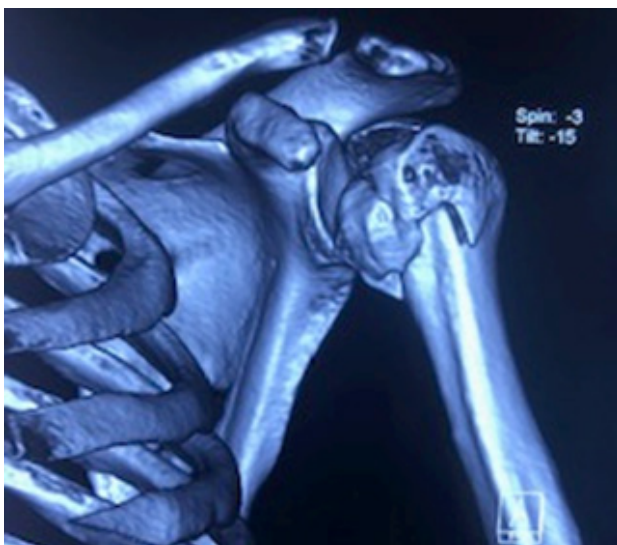

Figure 2 Pre operative CT Scan of the shoulder.

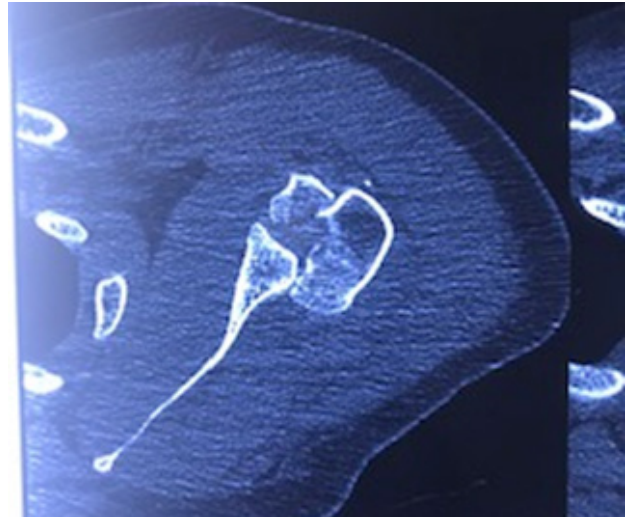


Figure 3 Per operative CT Scan.

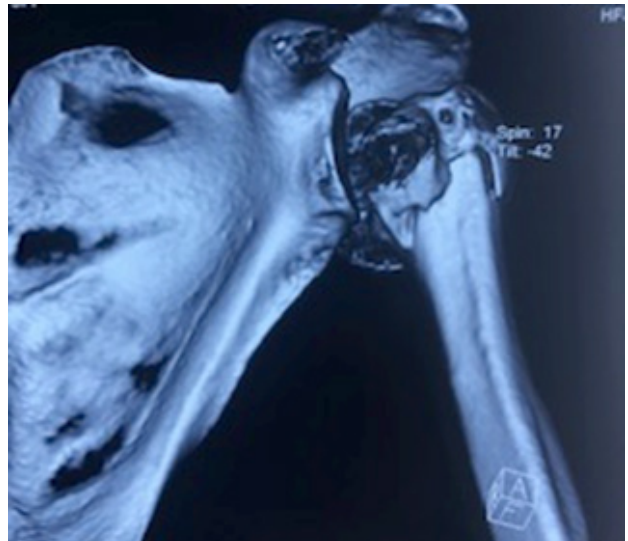


Figure 4 Pre operative CT Scan showing fracture dislocation.

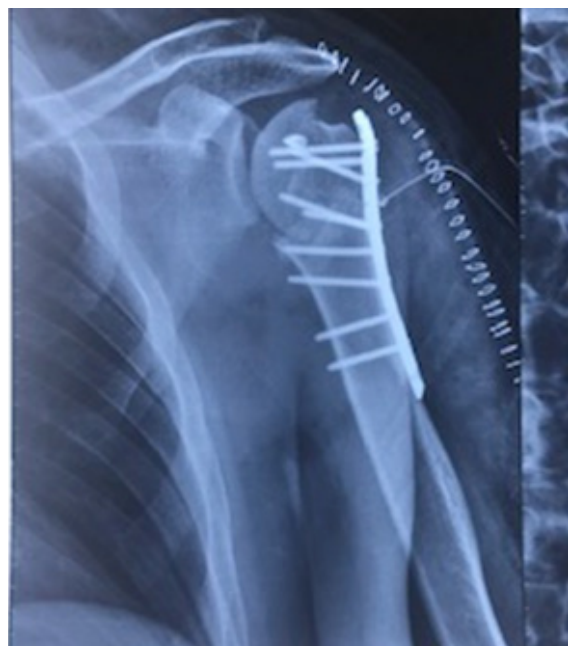

Figure 5 Immediate post operative X ray.

(Figure 5). A cerebral CT scan showed no fractures or soft tissue abnormalities. An electroencephalogram (EEG) showed no clear epileptic activity. Cerebral MRI showed no abnormalities. He was reviewed by a neurophysician and started on prophylactic anti epileptics.

He was discharged in an abduction brace and followed up as an outpatient with regular physiotherapy. One year after the operation the range of movement of his shoulder is approximately 70 degrees abduction and 90 degrees forward flexion.

Case II: Left Posterior Shoulder Fracture Dislocation And Right Undisplaced 3 Part Proximal Humerus Fracture

21 year old alcoholic was seen at the emergency department with a history alcoholic withdrawal and delirium tremens. He had history of convulsion one hour prior to review and he convulsed again at casualty and injured the opposite shoulder. He then had continuous tonic clonic seizures and was initially sedated and admitted to the HDU for management. Pre operative X ray of the left shoulder revealed a posterior fracture dislocation (Figures 6 and 7) and the right shoulder revealed undisplaced proximal humerus fractures (Figure 8). After control of the seizure disorder he was taken to theatre for open reduction and internal fixation of the right shoulder. The dislocation was reduced and the fracture fixed using a proximal humerus locking plate (PHILOS plate). The opposite shoulder was managed conservatively in an arm sling. On follow up both injuries healed well and at one year follow up had full recovery and normal range of motion.

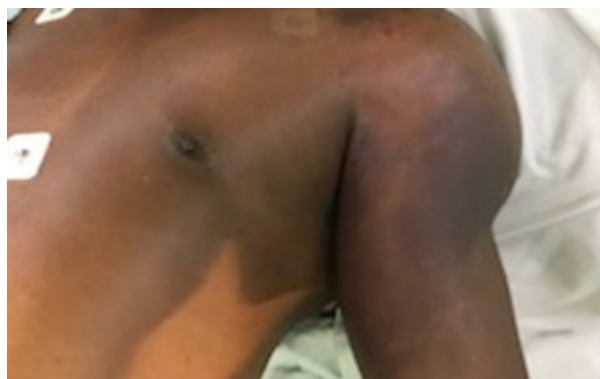

Figure 6 Picture of the left shoulder.

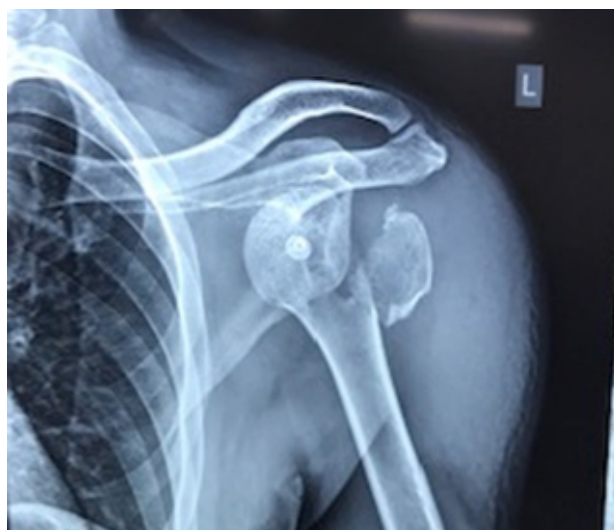

Figure 7 X ray of the Left shoulder showing a posterior fracture / dislocation.

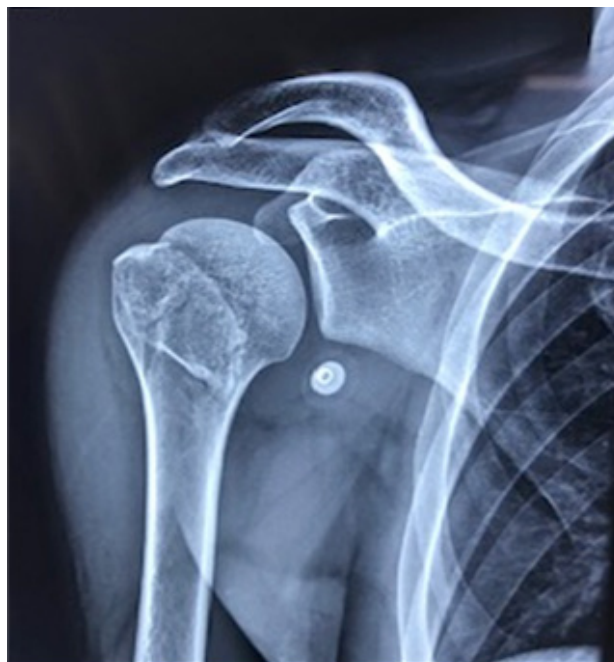

Figure 8 X ray of the right shoulder showing an undisplaced 3 part fracture.

DISCUSSION

Traumatic posterior and anterior shoulder dislocation (with or without fracture) can be caused by uncontrolled muscular contractions in an epileptic attack. This injury pattern can be attributed to a fall on the outstretched arm or a direct blow on the anterior side of the shoulder. In the absence of an electrical shock or direct trauma in a patient with a posterior shoulder dislocation fracture, epilepsy or another seizure disorder should be suspected. Bilateral posterior dislocation fractures of the shoulder as in the second case presented here are very suggestive, if not pathognomonic, of a seizure disorder. Epileptic seizure associated with brain tumours can result in a posterior shoulder fracture dislocation^[5].

A unilateral posterior dislocation of the shoulder without a fracture is missed after trauma in 50-80% of all posterior dislocations at the first examination^[1-4]. During physical examination a suspicion of posterior shoulder dislocation should be given priority in patients with pain or stiffness of the shoulder after a seizure. In cases with fracture and dislocation the pain is very severe and associated with complete inability to move the shoulder. Timely diagnosis and management of the seizures recognition is important for a good outcome.

The mechanism for a posterior dislocation with fracture of the shoulder during a seizure was described by Shaw in the 70s and remains valid to date^[3]. The position of the shoulder during a seizure is one of adduction, internal rotation and flexion. In this position the humeral head is drawn cranially and posteriorly against the acromion and medially against the glenoid fossa by generalized contraction of the shoulder muscles. The infraspinatus, teres minor, deltoid, latissimus dorsi and teres major provide sufficient power to dislocate the humerus posteriorly. When a seizure has ended the head of the humerus is behind the glenoid fossa, often with a large impression fracture of the head just medially to the minor tubercle near the anatomical neck of the humerus (reversed Hill-Sachs lesion). With an ongoing seizure the anatomical neck of the humerus will be drawn to the rim of the glenoid fossa and becomes impacted and is eventually fractured. The subscapular and infraspinatus muscles draw the two

fragments from each other, resulting in the typical ‘four-part fracture’ according to Neer^[7]. Further comminution can occur by forceful contraction of the triceps, the coracobrachialis, the biceps and the

deltoid muscles, which will pull the head of the humerus cranially to the acromion. This mechanism is likely to be the case in the first and second patient presented in this case series.

Cases of posterior fracture dislocation can easily be missed on standard X rays of the shoulder. In a study by Hawkins only 50% of posterior dislocations were recognized with a standard AP and lateral X-ray. With the addition of axillary X-rays the diagnosis is usually made in most cases^[6]. However it is very difficult to take an axillary X-ray in a patient with pain and the inability to abduct the shoulder. A CT scan is therefore key in making the diagnosis of posterior fracture dislocation and in planning of the subsequent surgery.

The management of locked posterior fracture dislocation in majority of cases is by open reduction and internal fixation^[8,9,10]. In the first case attempted closed reduction failed but good results were achieved by open reduction. Historically good outcomes follow open reduction and osteosynthesis using proximal humerus plates^[9].

CONCLUSION

Although a posterior fracture dislocation of the shoulder is rare it is an important differential in a patient who presents with a generalized seizure disorder and shoulder injuries. It's also important in all cases of shoulder dislocation with fracture to do a Computed Tomography prior to surgery. A good surgical and functional outcome can be achieved using a proximal humerus locking plate.

Ethical stanadrds

The patient gave the informed consent to the publication of the case study.

REFERENCES

1. McLAUGHLIN HL. Posterior dislocation of the shoulder. *J Bone Joint Surg Am.* 1952 Jul; 24 A(3): 584-90. [PMID: 14946209]
2. Parrish GA, Skiendzielewski JJ. Bilateral posterior fracture-dislocations of the shoulder after convulsive status epilepticus. *Ann Emerg Med.* 1985; 14: 264-266. [PMID: 3977152]; [DOI: 10.1016/s0196-0644(85)80453-4]
3. Shaw JL. Bilateral posterior fracture-dislocation of the shoulder and other trauma caused by convulsive seizures. *Journal of Bone and Joint Surgery* 1971; 53-A: 1437-1440. [PMID: 5000418]
4. Rockwood, C. A. Fractures and dislocations of the shoulder. In: *Fractures in Adults.* 2nd Edition (Eds C. A. Rockwood and D. P. Green). Volume 1, Chapter 11. Philadelphia, JB Lippincott, 1984: pp. 1-810.
5. Ellior DS. Brain tumor presenting as a dislocated shoulder. *Journal of Bone and Joint Surgery* 1990; 72-B: 925. [PMID: 2211787]
6. Hawkins RJ, Neer CS 2nd, Pianta RM, Mendoza FX. Locked posterior dislocation of the shoulder. *Journal of Bone and Joint Surgery* 1987; 69-A: 9-18. [PMID: 3805075]
7. Neer CS. Displaced proximal humeral fractures. *Journal of Bone and Joint Surgery* 1970; 52 A: 1077-1103.
8. Stableforth PG, Sarangi PP. Posterior fracture-dislocation of the shoulder. A superior subacromial approach for open reduction. *J Bone Joint Surg Br.* 1992; 74: 579-84. [PMID: 1624520]
9. O'Connor SJ, Jacknow AJ. Posterior dislocation of the shoulder. In: *Proceedings of the American Medical Association Section on Orthopaedic Surgery.* *J Bone Joint Surg Am.* 1955; 37: 1122.
10. Knight RA, Mayne JA. Comminuted fractures and fracture-dislocations involving the articular surface of the humeral head. *J Bone Joint Surg Am.* 1957; 39: 1343-55. [PMID: 13481048]