

Ankle Arthroscopy after Ankle Sprains

Manuel Bondi¹, Antonio Zanini¹, Andrea Pizzoli¹

¹ ASST - Mantova, Carlo Poma, Department of Orthopaedic and Traumatology, Strada Lago Paiolo 10, 46100 Mantova, Italy

Conflict-of-interest statement: The author(s) declare(s) that there is no conflict of interest regarding the publication of this paper.

Open-Access: This article is an open-access article which was selected by an in-house editor and fully peer-reviewed by external reviewers. It is distributed in accordance with the Creative Commons Attribution Non Commercial (CC BY-NC 4.0) license, which permits others to distribute, remix, adapt, build upon this work non-commercially, and license their derivative works on different terms, provided the original work is properly cited and the use is non-commercial. See: <http://creativecommons.org/licenses/by-nc/4.0/>

Correspondence to: Manuel Bondi, MD, ASST - Mantova, Carlo Poma, Department of Orthopaedic and Traumatology, Strada Lago Paiolo 10, 46100 Mantova, Italy.

Email: bondimanuel@gmail.com

Telephone: +390376201606

Received: August 10, 2019

Revised: September 4, 2019

Accepted: September 7 2019

Published online: October 28, 2019

ABSTRACT

INTRODUCTION: Anterior ankle impingement is a syndrome characterized by pain during movement, mainly dorsiflexion, and sometimes by functional restriction. This syndrome predominantly affects athletes, but could be found also in people with lower functional demands with an history of previous untreated or poorly treated ankle sprain. The study aim is to evaluate the results of arthroscopic therapy of the ankle impingement syndrome for grades I-III lesions in Scranton's score.

MATERIAL AND METHODS: 42 patients (24 men and 18 women) have undergone ankle arthroscopy for chronic ankle pain impingement. The mean age was 34.62 years. The average follow-up (FU) was 24.93 months. Clinical outcomes were assessed at the time of FU using the American Orthopaedic Foot and Ankle Society (AOFAS) score, a self-administered Foot and Ankle Disability Index

(FADI) score, the VAS scale and patients satisfaction.

RESULTS: The AOFAS mean score was 96,09, the average FADI score was 131,48, the average VAS score was 0,76. Forty (95%) patients reported their outcome as excellent or very good.

CONCLUSION: The results of the study show that ankle arthroscopy with resection of hypertrophic synovium and fibrous bands after an ankle sprain haven proven to be a reliable therapy for a posttraumatic impingement syndrome of the ankle that does not respond to conservative treatment. Ankle arthroscopy is an excellent diagnostic tool in order to find specific lesions which have been undetected in previous instrumental investigations; at the same time it enables to perform surgery bringing the benefits of minimal invasiveness, low post-surgical rate complications and early recovery to rehabilitation treatment.

Key words: Ankle sprain; Ankle arthroscopy; Ankle impingement; Impingement syndrome; Arthroscopic synovectomy

© 2019 The Author(s). Published by ACT Publishing Group Ltd. All rights reserved.

Bondi M, Zanini A, Pizzoli A. Ankle Arthroscopy after Ankle Sprains. *International Journal of Orthopaedics* 2019; 6(5): 1183-1188 Available from: URL: <http://www.ghrnet.org/index.php/ijo/article/view/2679>

INTRODUCTION

Ankle sprains are the most common type of ankle injury^[1].

Ankle pain by foot dorsal flexion movements is the typical anterior ankle impingement symptom. Often it appears with analgesic and/or functional range of motion limitation.

Sometimes an ankle sprain may lead to long lasting pain compromising the athlete's performance. This is mostly due to a post-traumatic impingement syndrome and the development of intraarticular fibrous scars inhibiting the joint movement. These scars can result from chronic hypertrophic synovitis or the dislocation of the anterior part of the tibiofibular ligament. In severe cases or due to repetitive trauma, this may result in the development of tibiotalar spurs.

Many athletes especially football, basket and soccer players suffer from ankle sprains. In most cases, the athlete's convalescence can

be achieved with standard conservative therapy. Within 3 years of their first ankle-sprain incident, 34% of those injured incur a residual problem^[2].

Anterolaterally localized hypertrophic synovitis was demonstrated arthroscopically in patients suffering from repetitive ankle sprains^[3-6]. In 1950, Wolin first described what he called a lateral meniscoid (Figure 1). The finding of these intraarticular fibrous cords was correlated to an injury of the talofibular ligaments^[7]. The anterolateral ankle impingement was due to this lateral meniscoid.

A chronic synovitis may be found as well^[8] and the anterior part of the tibiofibular syndesmosis can cause an ankle impingement^[9]. An ankle impingement syndrome can also be combined with a lesion of the medial and lateral malleolus or the posterior part of the tibial inferior epiphysis^[10].

Good-to-excellent results following arthroscopic synovectomy have been demonstrated for the treatment of ankle instability and related impingement syndromes^[3,4,6,11]. Different studies showed the clinical effectiveness of arthroscopic synovectomy in decreasing the number and severity of recurrent hemarthroses^[12-14].

In 1992, Scranton and Mc Dermott presented a grading system of the impingement syndrome according to X-ray image findings^[15].

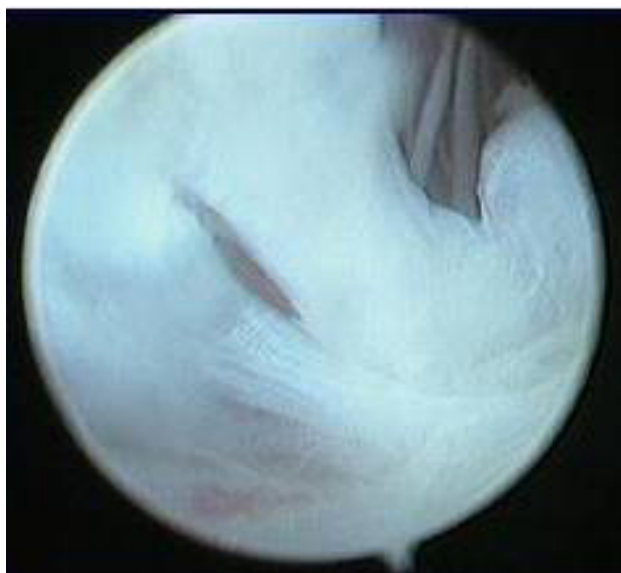

Figure 1 Hypertrophic scar tissue with a fibrous band appearance called lateral meniscoid.

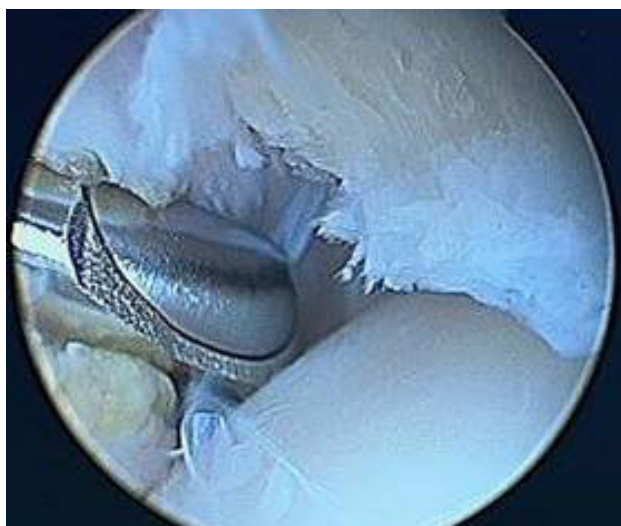

Figure 2 Anterior impingement removal with motorized oscillating shaver.

It ranks from grades I to IV. If there are only soft-tissue lesions the morphologic alternations are subject to MRI or surgical intervention. Synovectomy of joints in patients with rheumatoid arthritis (RA), helps reduce pain and prevent or delay articular cartilage destruction^[16-18]. Arthroscopic synovectomy is associated with a low rate of complications and is often successfully performed in the knee and other joints^[16-18]. Currently, few published data exist concerning arthroscopic synovectomy of the ankle joint in patients with RA^[19].

This kind of surgery is useful with synovial chondromatosis too, that can be a chronic and debilitating disease if left untreated. Joint damage results from progressive degeneration of articular structures secondary to loose, neoplastic cartilaginous nodules in the joint space^[20]. The knee joint is the most commonly involved and presents in up to 60-70% of cases, followed by the hip, elbow, shoulder and sometimes ankle. The stages of synovial chondromatosis include the early stage without loose bodies, a transitional stage with intrasynovial nodules, and the late stage with multiple intra-articular loose bodies^[21,22].

Pigmented villonodular synovitis (PVNS) is a rare, locally aggressive benign proliferative pathology of synovial tissue. The World Health Organisation (WHO) has classified these lesions separately as PVNS and giant cell tumour of tendon sheath (GCTTS) and reported that the distinction is based on the behaviour of the

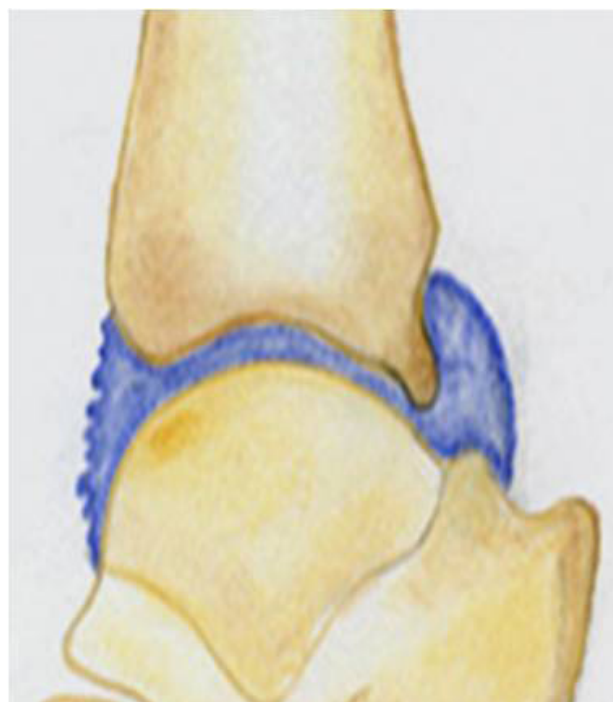

Figure 3 The neutral position in mild dorsiflexion increases the capsular distension facilitating the anterior pathologies treatment.

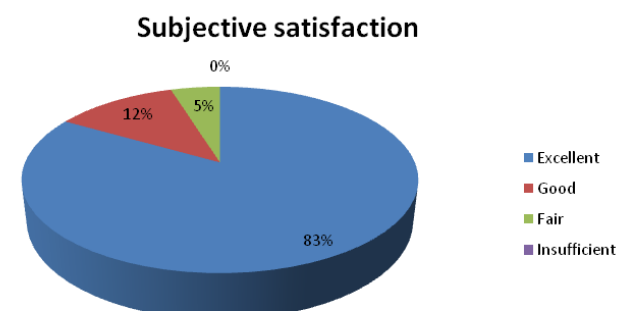


Figure 4 Subjective satisfaction at the follow up time.

tumour^[23]. The definitive aetiology is unclear. Chronic inflammation, recurrent hemarthrosis following trauma, and abnormal lipid metabolism are the topics of debate^[24].

The magnetic resonance imaging (MRI) is usually sufficient for diagnosis and shows intra-articular masses with low signal intensity^[25], and also in this case ankle arthroscopy is useful for pain relief.

The study aim is to evaluate the results of arthroscopic therapy of the ankle impingement syndrome for grades I-III lesions in Scranton's score.

MATERIALS AND METHODS

From January 2015 to December 2018, 42 patients have undergone ankle arthroscopy for chronic ankle pain impingement of I - III grade according to Scranton's score.

The patients age ranged between 23 and 55 years (average age 34.6) at the time of ankle arthroscopy (Table 1).

Twenty four patients were male and eighteen patients were female. Twenty six of the ankles were the right and sixteen the left.

The impingement syndrome was caused by a supination ankle trauma in 28 cases and by a pronation trauma in 14.

Criterion for inclusion was an ankle impingement syndrome due to ankle sprain graded I-III, the presence of unilateral, ongoing pain when bearing weight, palpatoric pain of the anterior talocrural joint space and pain provoked by dorsiflexion of the ankle, recurrent swelling, a feeling of the ankle giving way, and weakness. Before surgery all patients were subject to conservative treatment with non-steroid drugs (only if VAS > 4), heel lifting and physiotherapy without success for at least 3 months^[26].

Patients with a manifest tibiotalar osteoarthritis (grade IV) or malalignment of the ankle in X-ray due to a fracture or with vestibular or neurological disorders leading to balance problems, were not included in the study.

The program then provides for the recovery of the full range of motion and of the muscle proprioception. No additional physical therapy was required for patients.

Clinical data were collected at the time of follow-up with the American Orthopaedic Foot and Ankle Society (AOFAS) scale, with the Foot and Ankle Disability Index (FADI) scale and VAS.

Patients were asked to express their degree of satisfaction to the post-operative on a 5-point scale (0 = unsatisfied, 1 = barely satisfied, 2 = satisfied, 3 = very satisfied, 4 = excellent).

Preoperative data were then compared with those at follow-up using a T-Student test. A value of $p < 0.05$ was considered as significant. Statistical analysis was performed using Microsoft Office Excel 2007.

Surgical treatment

All patients were subject to arthroscopy. Operation was done with a 4 mm 30° lens system arthroscope using an anterolateral and anteromedial portal. Distraction of the joint was done by an assistant. Ankle arthroscopy was performed under regional or general anesthesia and with a tourniquet. After diagnostic arthroscopy, debridement of hypertrophic synovial tissue was conducted using an oscillating shaver and a cautery/ablation device (Figures 2 and 3).

Rough articular cartilage was shaved, and loose debris was removed. Attempts were made to perform a complete synovectomy of all tissue that appeared pathologic, and hemostasis was achieved before completion of the surgery. After 7 days surgery, weight bearing, as tolerated, was permitted using crutches. ROM and

Table 1 Patients data.

	Data
Age (years)	34.62 ± 9.06
Weight (kg)	74.07 ± 9.41
Gender (M/F)	24/18
Side (R/L)	26/16
Traumatic event	28 supination
	14 pronation

Table 2 Results at follow up.

	Data
Follow up	24.93 ± 13.88
AOFAS score	96.09 ± 2.39
FADI score	131.48 ± 1.85
VAS	0.76 ± 1.12
Fair results	2

muscle-strengthening exercise were initiated as soon as possible, and a supervised physical therapy program was prescribed in all cases.

Other probable causes of chronic ankle pain, such as osteochondral lesions of the talus, peroneal tendon pathologies, arthritis, medial ligament injuries, and subtalar pathologies, were excluded through MRI verification.

RESULTS

The average follow-up for the 42 patients consisted in 24,93 months (ranged from 6 to 48) after arthroscopic surgery.

The AOFAS mean score was 96,09 (ranged from 89 to 98), the mean value of the FADI score was 131,48 (ranged from 126 to 134) and the mean value of VAS score was 0,76 (ranged from 0 to 5) (Table 2).

Thirty five patients (83,3%) provided an excellent or very good opinion on the success of the surgery, five patients (11,9%) expressed good satisfaction and only two patients (4,8%) reported an fair opinion (Figure 4).

In the case of the unsatisfied patients we noticed no return to sport due to post-operative lack physiotherapy.

No neurovascular disorder have occurred.

DISCUSSION

In most cases, the typical ankle sprain leading to an impingement syndrome is a supination-inversion trauma, whereas in some cases a pronation injury can be found as well^[27,28].

According to McMurray, the typical tibiotalar anterior spurs to be seen in X-ray are due to repetitive micro-trauma of the ankle leading to traction spurs^[29]. Tol *et al*, however, in a cadaver study, found that these spurs were situated distal to the tibial insertion of the joint capsule. Contrasting to McMurray's opinion, they find these spurs to be the result of a metaplastic change of preexistent connective tissue^[30].

Pain typically is provoked by the dorsiflexion of the foot and palpation of the anterolateral or anteromedial ankle joint space.

Kynsburg and van Dijk developed a standard protocol of clinical examination leading to the diagnosis of an ankle impingement^[27]. In the case of soft-tissue lesions the morphologic findings however are often subject to surgical intervention.

The therapy of an ankle impingement syndrome can start with conservative treatment such as the application of non-steroid drugs,

some local corticoid injections, heel lifting and physiotherapy^[26]. If there are persisting ankle troubles however surgery should be discussed.

Arthroscopy is less invasive and the rehabilitation period is shorter compared to open arthrotomy.

In literature, authors report good results after arthroscopic treatment of the ankle impingement as well. Kim found in his study the combination of chronic ligament instability with an ankle impingement syndrome. Nearly one half of the patients recruited for his study suffered from ankle instability with positive stress X-ray results^[31]. As Cannon sees it in this case always a ligament reconstruction is necessary to avoid bad results if only an arthroscopic debridement is performed^[32,33].

These findings and the consequences derived of them are confirmed by Scranton and Di Giovanni as well^[34,35]. In this article we excluded patients with the combination of an ankle impingement and ankle instability. It has been described in another study^[33].

As to the complications the problems mostly are reported about neurovascular lesions^[8,36]. Here the anteromedial and anterolateral portal is recommended presenting an access with low risks for the neurovascular bundle. This could be confirmed by the results of this study.

Plica syndrome classically presents with either snapping, joint crepitus, joint effusion, or any combination of the 3^[37]. It most commonly affects the knee joint, but has been reported in the elbow, hip, shoulder and ankle^[8,38].

The progression from normal synovial anatomy to pathological plica is poorly understood. There have been several suggestions postulated including hypertrophy secondary to trauma, idiopathic adhesions, and chronic impingement syndromes^[39]. All appear to have a role, to varying degrees, in the progression to the clinical syndrome.

In patients with persistent synovitis, arthroscopic synovectomy is indicated, but in patients with RA this method remains controversial^[16-18].

In most studies, a considerable improvement in pain, swelling, and function has been reported with the use of arthroscopic synovectomy^[16,17]. Over a long-term period, however, the radiologic outcomes of joints gradually worsen^[16,17,40,41].

Several researchers have concluded that early synovectomy leads to better results compared with late synovectomy^[42].

In literature, this kind of surgery is indicated also for treating septic arthritis includes the removal of all inflammatory cells, enzymes, debris, and foreign bodies, elimination of destructive pannus, and functional recovery.

Surgical evacuation of an ankle joint with extensile incisions, continuous irrigation, and daily needle aspiration have been evaluated and discussed in many studies^[43-46]. Arthroscopy will allow for a direct magnified view of the intra-articular anatomy, joint lavage, synovectomy of the septic pannus formation without the morbidity of extensile surgical incisions, quicker recovery, and a lower incidence of iatrogenic injury^[47,48]. The most common organism found and reported in literature was methicillin-sensitive *S. aureus*^[49-53].

Freeman first described “functional instability” (FI) and introduced his articular deafferentation theory in which FI is attributable to proprioceptive deficits^[54]. A more recent definition of FI is “the occurrence of recurrent ankle instability and the sensation of joint instability due to the contributions of proprioceptive and neuromuscular deficits”^[55]. However, mechanical instability (MI) can be defined with clinical findings such as pathological laxity and a 5° difference in the talar test^[56].

Impingement and ankle instability are associated pathologies, only 3% of all inversion injuries result in anterolateral soft tissue impingement^[57]. Ferkel *et al* performed synovectomy and debridement of scar tissue for patients who experienced pain following inversion injury with negative stress radiographs suggesting the FI^[3].

While the deficits in ankle proprioception have been attributed to damage of the joint capsule, ligaments, and their associated mechanoreceptors; hypertrophic synovitis may alter the mechanoreceptors of the ankle joint, leading to an impaired ankle proprioception^[54].

Recurrent hemarthroses have a known deleterious effect on the synovium and the articular cartilage.

Persistent bleeding causes synovial hypertrophy and areas of villous formation of the inflamed and friable synovium^[58]. Fibrinolytic and other hydrolytic enzymes released from lysosomal stores degrade the organized clot and articular cartilage^[59]. According to this fact we considered to do ambulatory ankle joint arthrocentesis, to contrasting hemarthroses and his organization in fibrous tissue and consequent painfull anterior impingement.

Lastly the worth of MRI should be discussed. In all cases this showed no further information to the extent of the soft-tissue lesions in this study. In literature, this topic is controversial. Kynsburg and van Dijk point out that the MRI is not worth being performed in the diagnosis of an ankle impingement syndrome^[27]. In contrast to this, both Schaffler and Lee agree on the importance of MRI^[28,60]. To qualify this it has to be mentioned that they were using especially large-scale protocols and sequences.

CONCLUSIONS

Patient’s medical history and clinical examination are essential for a correct diagnosis. According to this we do not consider correct to use analgesic therapies during conservative treatment, because they could delay the surgical indication, causing more serious anatomical pathological conditions, such as osteochondral pathologies.

Ankle arthroscopy is very useful in patients with chronic injuries, who have already performed conservative treatment without result^[3,4,6]. It is essential for impingement removal to prevent the subsequent chondral lesions formation. In literature it has been shown that the removal of impingement in patients with chondral lesions, compared with others without chondral lesions, there is no difference in the ankle function at the follow up^[61].

Compliance with Ethical Standards

The authors certify that they have no affiliations with or involvement in any organization or entity with any financial interest or non-financial interest (such as personal or professional relationships, affiliations, knowledge or beliefs) in the subject matter or materials discussed in this manuscript.

The study concerns human patients who have signed an informed consent allowing data collection. Everything was approved by the corporate ethics committee.

REFERENCES

1. Berlet GC, Saar WE, Ryan A, Lee TH. Thermal-assisted capsular modification for functional ankle instability. *Foot Ankle Clin* 2002; **7**: 567-576. [PMID: 12512410]
2. Caulfield B, Garrett M. Changes in ground reaction force during jump landing in subjects with functional instability of the ankle joint. *Clin Biomech (Bristol, Avon)* 2004; **19**: 617-621. [PMID:

- 15234486]; [DOI: 10.1016/j.clinbiomech.2004.03.001]
3. Diop M, Rahmani A, Calmels P, Gautheron V, Belli A, Geysant A, Cottalorda J. Influence of speed variation and age on the intrasubject variability of ground reaction forces and spatiotemporal parameters of children's normal gait. *Ann Readapt Med Phys* 2004; **47**: 72-80. [PMID: 15013601]; [DOI: 10.1016/j.annrmp.2003.09.006]
 4. Docherty CL, Arnold BL, Gansneder BM, Hurwitz S, Gieck J. Functional performance deficits in volunteers with functional ankle instability. *J Athl Train* 2005; **40**: 30-34. [PMID: 15902321]
 5. Drewes LK, McKeon PO, Kerrigan DC, Hertel J. Dorsiflexion deficit during jogging with chronic ankle instability. *J Sci Med Sport* 2009; **12**: 685-687. [PMID: 18835218]; [DOI: 10.1016/j.jsams.2008.07.003]
 6. Fong DT, Hong Y, Chan LK, Yung PS, Chan KM. A systematic review on ankle injury and ankle sprain in sports. *Sports Med* 2007; **37**: 73-94. [PMID: 17190537]; [DOI: 10.2165/00007256-200737010-00006]
 7. Wolin I, Glassman F, Sideman S. Internal derangement of the talofibular component of the ankle. *Surg Gynecol Obstet* 1950; **91**: 193-200. [PMID: 15442838]
 8. Amendola A, Petrik J, Webster-Bogaert S. Ankle arthroscopy: outcome in 79 consecutive patients. *Arthroscopy* 1996; **12**: 565-573. [PMID: 8902131]
 9. Bassett FH, Gates HS, Billys JB, Morris HB, Nikolaou PK. Talar impingement by the anteroinferior tibiofibular ligament. A cause of chronic pain in the ankle after inversion sprain. *J Bone Joint Surg Am* 1990; **72**: 55-9. [PMID: 2295673]
 10. van Dijk CN, Verhagen RA, Tol JL. Arthroscopy for problems after ankle fracture. *J Bone Joint Surg B* 1997; **79**: 280-4. [PMID: 9119857]
 11. Groeters S, Groen BE, van Cingel R, Duysens J. Double-leg stance and dynamic balance in individuals with functional ankle instability. *Gait Posture* 2013. [PMID: 23810093]; [DOI: 10.1016/j.gaitpost.2013.05.005]
 12. Gilbert M, Radomisl T. Therapeutic options in the management of hemophilic synovitis. *CORR* 1997; **343**: 88-92. [PMID: 9345212]
 13. Triantafyllou S, Hanks G, Handal J, Greer R. Open and arthroscopic synovectomy in hemophilic arthropathy of the knee. *CORR* 1992; **283**: 196-204. [PMID: 1395245]
 14. Eickhoff H, Koch W, Raderschadt G, Brackmann H. Arthroscopy for chronic hemophilic synovitis of the knee. *CORR* 1997; **343**: 58-62. [PMID: 9345207]
 15. Scranton PE, Mc Dermott JE. Anterior tibiotalar spurs: a comparison of open versus arthroscopic debridement. *Foot Ankle* 1992; **13**: 125-9. [PMID: 1601339]
 16. Tanaka N, Sakahashi H, Hirose K, Ishima T, Ishii S. Arthroscopic and open synovectomy of the elbow in rheumatoid arthritis. *J Bone Joint Surg Am* 2006 Mar; **88(3)**: 521-5. [PMID: 16510817]; [DOI: 10.2106/JBJS.E.00472]
 17. Kim SJ, Jung KA, Kim JM, Kwun JD, Kang HJ. Arthroscopic synovectomy in wrists with advanced rheumatoid arthritis. *Clin Orthop Relat Res* 2006; **449**: 262-266. [PMID: 16691137]; [DOI: 10.1097/01.blo.0000218732.44591.c9]
 18. Klug S, Wittmann G, Weseloh G. Arthroscopic synovectomy of the knee joint in early cases of rheumatoid arthritis: follow-up results of a multicenter study. *Arthroscopy* 2000; **16**: 262-267. [PMID: 10750006]
 19. Takagi T, Koshino T, Okamoto R. Arthroscopic synovectomy for rheumatoid arthritis using a holmium: YAG laser. *J Rheumatol* 2001; **28**: 1518-1522. [PMID: 11469456]
 20. Murphey MD, Vidal JA, Fanburg-Smith JC, Gajewski DA. Imaging of synovial chondromatosis with radiologic-pathologic correlation. *Radiographics* 2007; **27**: 1465-1488. [PMID: 17848703]; [DOI: 10.1148/rg.275075116]
 21. Adelani MA, Wupperman RM, Holt GE. Benign synovial disorders. *J Am Acad Orthop Surg* 2008; **16**: 268-275. [PMID: 18460687]
 22. Ozmeric A, Aydogan NH, Kocadal O, Kara T, Pepe M, Gozel S. Arthroscopic treatment of synovial chondromatosis in the ankle joint. *Int J Surg Case Rep* 2014; **5**: 1010-1013. [PMID: 25460460]; [DOI: 10.1016/j.ijscr.2014.10.083]
 23. de St Aubain Somerhausen N, Dal Chin P. So-called fibrohistiocytic tumours. In: Fletcher CDM, Unni KK, Mertens F, editors. World Health Organization classification of tumours: pathology and genetics of tumours of soft tissue and bone. Lyon: IARC Press 2002; p. 109-26.
 24. Ottaviani S, Ayrar X, Dougados M, Gossec L. Pigmented villonodular synovitis: a retrospective single-center study of 122 cases and review of the literature. *Semin Arthritis Rheum* 2011; **40**: 539-46. [PMID: 20884045]; [DOI: 10.1016/j.semarthrit.2010.07.005]
 25. Murphey MD, Rhee JH, Lewis RB, Fanburg-Smith JC, Flemming DJ, Walker EA. Pigmented villonodular synovitis: radiologic-pathologic correlation. *Radio-graphics* 2008; **28**: 1493-518. [PMID: 18794322]; [DOI: 10.1148/rg.285085134]
 26. Zanini A., Bondi M., Bettinsoli PF, Benedini M., Pizzoli A., Renzi Brivio L. "Return to Sport After Ankle Lesions" in Arthroscopy and Sport Injuries: Applications in High-level Athletes. Springer International Publishing Switzerland 2015; pp 425-431. ISBN 978-3-319-14815-1. [DOI: 10.1007/978-3-319-14815-1_54]
 27. Kynsburg A, van Dijk CN. Schritte zur Diagnosestellung des ventralen Knochel -Impingementsyndroms. *Arthroscopie* 2005; **18**: 119-24; [DOI: 10.1007/s00142-005-0295-1]
 28. Schaffler GJ, Tirmann PFJ, Stoller DW, Genant HK, Ceballos C, Dillingham MF. Impingement syndrome of the ankle following supination external rotation trauma: MR imaging findings with arthroscopic correlation. *Eur Radiol* 2003; **13**: 1357-62. [PMID: 12764653]; [DOI: 10.1007/s00330-002-1661-2]
 29. Mc Murray TP. Footballer's ankle. *J Bone Joint Surg Am* 1950; **32**: 68-9.
 30. Tol JL, van Dijk CN. Etiology of the anterior ankle impingement syndrome: a descriptive anatomical study. *Foot Ankle* 2004; **25**: 382-6. [PMID: 15215021]; [DOI: 10.1177/107110070402500603]
 31. Kim SH, Ha KI. Arthroscopic treatment for impingement of the anterolateral soft tissues of the ankle. *J Bone Joint Surg B* 2000; **82**: 1019-21. [PMID: 11041593]
 32. Cannon LB, Hackney RG. Anterior tibiotalar impingement associated with chronic ankle instability. *J Foot Ankle Surg* 2000; **39**: 383-6. [PMID: 11131475]
 33. Zanini A, Bondi M, Pizzoli A. Il trattamento dell'instabilità di caviglia: le plicature. *Medicina e chirurgia della caviglia e del Piede*. December 2017; **41(3)**: 53-60; [DOI: 10.23736/S2284-2993.17.01771-X]
 34. diGiovanni BF, Fraga CJ, Cohen BE, Shereff MJ. Associated injuries found in chronic lateral ankle instability. *Foot Ankle* 2000; **21**: 809-15. [PMID: 11128010]; [DOI: 10.1177/107110070002101003]
 35. Scranton PE, Mc Dermott JE, Rogers JV. The relationship between chronic ankle instability and variations in mortise anatomy and impingement spurs. *Foot Ankle* 2000; **21**: 657-64. [PMID: 10966363]; [DOI: 10.1177/107110070002100805]
 36. Strecker W, Eisele R, Fritz M, Kinzl L, Hehl G. Value of arthroscopy in the treatment of upper ankle arthritis. *Unfallchirurg* 2005; **108**: 461-9. [PMID: 15778829]; [DOI: 10.1007/s00113-004-0904-x]
 37. O'Dwyer KJ, Peace PK. The plica syndrome. *Injury* 1988; **19(5)**: 350-352. [PMID: 3255717]; [DOI: 10.1016/0020-1383(88)90111-8]
 38. Athihan D, Jones DC, Guanache CA. Arthroscopic treatment of a symptomatic hip plica. *Clin Orthop Relat Res* 2003; **411**: 174-177. [PMID: 12782873]; [DOI: 10.1097/01.blo.0000065841.77325.c6]
 39. Banks AS, Downey MS, Martin DE, Miller SJ. McGlamry's Comprehensive Textbook of Foot and Ankle Surgery 2001. p 1126, Lippincott Williams & Wilkins, Philadelphia.
 40. Nemoto K, Arino H, Yoshihara Y, Fujikawa K. Arthroscopic

- synovectomy for the rheumatoid elbow: a short-term outcome. *J Shoulder Elbow Surg* 2004; **13**: 652-655. [PMID: 15570234]; [DOI: 10.1016/S1058274604001284]
41. Smith AM, Sperling JW, O'Driscoll SW, Cofield RH. Arthroscopic shoulder synovectomy in patients with rheumatoid arthritis. *Arthroscopy* 2006; **22**: 50-56. [PMID: 16399461]; [DOI: 10.1016/j.arthro.2005.10.011]
 42. Jensen CM, Poulsen S, Østergren M, Hansen KH. Early and late synovectomy of the knee in rheumatoid arthritis. *Scand J Rheumatol* 1991; **20**: 127-131. [PMID: 2031157]; [DOI: 10.3109/03009749109165288]
 43. Manadan AM, Block JA. Daily needle aspiration versus surgical lavage for the treatment of bacterial septic arthritis in adults. *Am J Ther* 2004; **11**: 412-415. [PMID: 15356433]
 44. Kang SN, Sanghera T, Mangwani J, Paterson JM, Ramachandran M. The management of septic arthritis in children. *J Bone Joint Surg Br* 2009; **91-B**: 1127-1133. [PMID: 19721035]; [DOI: 10.1302/0301-620X.91B9.22530]
 45. Stuz G, Kuster MS, Kleinstück F, Gächter A. Arthroscopic management of septic arthritis: stages of infection and results. *Knee Surg Sports Traumatol Arthrosc* 2000; **8**: 270-274. [PMID: 11061294]; [DOI: 10.1007/s001670000129]
 46. Field M. Optimum therapy in septic arthritis: to cut or not to cut? *Nat Rev Rheumatol* 2010; **6**: 8-10. [PMID: 20046201]; [DOI: 10.1038/nrrheum.2009.256]
 47. Ayril X. Arthroscopy and joint lavage. *Best Pract Res Clin Rheumatol* 2005; **19**: 401-415. [PMID: 15939366]; [DOI: 10.1016/j.berh.2004.11.007]
 48. Morgan DS, Fisher D, Merianos A, Currie BJ. An 18 year clinical review of septic arthritis from tropical Australia. *Epidemiol Infect* 1996; **117**: 423-428. [PMID: 8972665]; [DOI: 10.1017/S0950268800059070]
 49. Shadrack D, Mendicino RW, Catanzariti AR. Ankle joint sepsis with subsequent osteomyelitis in an adult patient. *J Foot Ankle Surg* 2011; **50**: 354-360. [PMID: 21459626]; [DOI: 10.1053/j.jfas.2011.02.005]
 50. Salliot C, Desplaces N, Boisrenoult P, Koeger AC, Beaufils P, Vincent V, Mamoudy P, Ziza JM. Arthritis due to Mycobacterium xenopi: a retrospective study of 7 cases in France. *Clin Infect Dis* 2006; **43**: 987-993. [PMID: 16983609]; [DOI: 10.1086/507631]
 51. Titov AG, Nakonechniy GD, Santavirta S, Serodobintzev MS, Mazurenko SI, Kontinen YT. Arthroscopic operations in joint tuberculosis. *Knee* 2004; **1**: 57-62. [PMID: 14967330]; [DOI: 10.1016/S0968-0160(03)00035-8]
 52. Nagaya-Waguri Y, Goto H, Kobayashi M, Hisazaki S, Otsuka T, Tsuchiya A. Septic arthritis of the right ankle caused by Staphylococcus aureus infection in a rheumatoid arthritis patient treated with etanercept. *Mod Rheumatol* 2007; **17**: 338-340. [PMID: 17694271]; [DOI: 10.1007/s10165-007-0581-z]
 53. Seara JV, Barthel T, Schmitz H, Eulert J. Arthroscopic treatment of septic joints: prognostic factors. *Arch Orthop Trauma Surg* 2002; **122**: 204-211. [PMID: 12029509]; [DOI: 10.1007/s00402-001-0386-z]
 54. Delahunt E, Monaghan K, Caulfield B. Altered neuromuscular control and ankle joint kinematics during walking in subjects with functional instability of the ankle joint. *Am J Sports Med* 2006; **34**: 1970-1976. [PMID: 16926342]; [DOI: 10.1177/0363546506290989]
 55. Delahunt E, Monaghan K, Caulfield B. Ankle function during hopping in subjects with functional instability of the ankle joint. *Scand J Med Sci Sports* 2007; **17(6)**: 641-648. [PMID: 17331087]; [DOI: 10.1111/j.1600-0838.2006.00612.x]
 56. Brown C, Padua D, Marshall SW, Guskiewicz K. Individuals with mechanical ankle instability exhibit different motion patterns than those with functional ankle instability and ankle sprain copers. *Clin Biomech (Bristol, Avon)* 2008; **23**: 822-83. [PMID: 18400347]; [DOI: 10.1016/j.clinbiomech.2008.02.013]
 57. van Rijn RM, van Os AG, Bernsen RM, Luijsterburg PA, Koes BW, Bierma-Zeinstra SM. What is the clinical course of acute ankle sprains? A systematic literature review. *Am J Med* 2008; **121**: 324-331. [PMID: 18374692]; [DOI: 10.1016/j.amjmed.2007.11.018]
 58. Arnold W, Hilgartner M. Hemophilic arthropathy. *J Bone Joint Surg Am* 1977; **59**: 287-305. [PMID: 849938]
 59. Hilgartner M, Arnold W, Granda J. Acid phosphatase levels in synovial tissue and fluid in patients with hemophilia. Proceedings of the Fourteenth International Congress of Hematology, San Paulo, Brazil 1972.
 60. Lee JW, Suh JS, Huh Y-M, Moon E-S, Kim SJ. Soft tissue impingement syndrome of the ankle: diagnostic efficacy of MRI and clinical results after arthroscopic treatment. *Foot Ankle* 2004; **25**: 896-902. [PMID: 15680103]; [DOI: 10.1177/107110070402501209]
 61. Mardani-Kivi M, Mirbolook A, Khajeh-Jahromi S, Hassanzadeh R, Hashemi-Motlagh K, Saheb-Ekhtiari K. Arthroscopic treatment of patients with anterolateral impingement of the ankle with and without chondral lesions. *J Foot Ankle Surg* 2013 Mar-Apr; **52(2)**: 188-91; [DOI: 10.1053/j.jfas.2012.10.017]