

Outcome of Percutaneous Reduction and Fixation of Displaced Calcaneal Fractures: Our Experience

Muhammad Zubair Javaid¹, Junaid Khan², Muhammad Mohsin Javaid³, Sana Zubair⁴, Hizra Farrukh⁵, Raja Umar Liaquat⁶

1 Associate Professor, Department of Orthopaedics, HolyFamily Hospital, Rawalpindi, Pakistan;

2 Registrar, Department of Orthopaedics, HolyFamily Hospital, Rawalpindi, Pakistan;

3 Post-graduate Trainee, Department of Orthopaedics, HolyFamily Hospital, Rawalpindi, Pakistan;

4 House Officer, Shifa Medical College, Islamabad, Pakistan;

5 House Officer, Rawalpindi Medical University, Rawalpindi, Pakistan;

6 Senior Registrar, Department of Orthopaedics, Benazir Bhutto Hospital, Rawalpindi, Pakistan.

Conflict-of-interest statement: The author(s) declare(s) that there is no conflict of interest regarding the publication of this paper.

Open-Access: This article is an open-access article which was selected by an in-house editor and fully peer-reviewed by external reviewers. It is distributed in accordance with the Creative Commons Attribution Non Commercial (CC BY-NC 4.0) license, which permits others to distribute, remix, adapt, build upon this work non-commercially, and license their derivative works on different terms, provided the original work is properly cited and the use is non-commercial. See: <http://creativecommons.org/licenses/by-nc/4.0/>

Correspondence to: Muhammad ZubairJavaid, Associate Professor, Department of Orthopaedics, HolyFamily Hospital, Rawalpindi, Pakistan
Email: drzubairortho@hotmail.com
Telephone: +92-333-5106566

Received: September 7, 2019

Revised: November 4, 2019

Accepted: November 7 2019

Published online: December 28, 2019

ABSTRACT

OBJECTIVES: To determine the functional outcome of percutaneous reduction and fixation of calcaneal fractures in terms of visual analog pain score (VAS).

METHODS: This descriptive study was done from 10th January

2016 to 9th January 2019. All patients presenting to the Orthopaedic emergency with displaced calcaneal fractures belonging to either gender aged between 20 to 65 years presenting within 1 week of injury were included. All patients underwent percutaneous reduction and fixation under C-arm fluoroscope. Functional outcome at 3-months post-operatively was assessed in terms of VAS. Data regarding age, gender, mechanism of injury, fractured side, time since injury, type of fracture, VAS and any complication was noted and analyzed using SPSS version 23.

RESULTS: 50 patients were included in the study. 40 (80%) were males and 10 (20%) females. Mean age was 41.3 ± 10.0 years. Average time to surgery since injury was 5.1 ± 1.1 days. Most of the patients had Sanders-II (44%) type of fracture. Most common complication was sub-talar arthritis which was found in 6 (12%) patients. Mean VAS score at 3-months post-operatively was 2.5 ± 0.9 .

CONCLUSION: The study concludes that percutaneous reduction and fixation of calcaneal fractures has good functional outcome.

Key words: Calcaneal fracture; Percutaneous reduction; Visual analog pain score

© 2019 The Author(s). Published by ACT Publishing Group Ltd. All rights reserved.

Javaid MZ, Khan J, Javaid MM, Zubair S, Farrukh H, Liaquat RU. Outcome of Percutaneous Reduction and Fixation of Displaced Calcaneal Fractures: Our Experience. *International Journal of Orthopaedics* 2019; 6(6): 1217-1220 Available from: URL: <http://www.ghrnet.org/index.php/ijo/article/view/2681>

INTRODUCTION

Calcaneum is the commonest tarsal bone to be fractured in adults, accounting for an estimated 60% of all tarsal bones^[1]. The incidence is highest in young males^[2]. Axial loading resulting from a fall is the mechanism of injury in majority of the cases^[3]. Calcaneal fractures can be classified into intra-articular and extra-articular^[4]. Mostly these are displaced intra-articular fractures^[5]. According to one of the study, their incidence is 11.5 per 100,000^[6]. Various treatment options from conservative to operative have been described over the past several decades. The earliest minimally invasive technique of managing

these fractures was mentioned by Clark in 1855, who used a pulley for reducing the fracture^[7]. Bohler in 1920, then managed these with traction and screw fixation, if required^[8]. Later on, treating these with open reduction and internal fixation (ORIF) with a plate became the standard^[9].

ORIF is associated with a higher incidence of wound infection, up to 27%. These include superficial and deep infections^[10]. Cost of managing these complications is not only a burden on the patient, but on the health care system as well^[11]. Patients with co-morbid conditions like Diabetes Mellitus, obesity, immunocompromised, etc have a higher chance of getting wound infection^[12]. In order to reduce these complications, minimally invasive methods of reduction and fixation of these fractures were introduced^[13]. Initially these were employed only for tongue-type calcaneal fractures as they might lead to less favorable intra-articular reduction^[14]. In 1999, percutaneous reduction and fixation with screws was introduced for all types of calcaneal fractures^[15].

As there are many treatment options available for managing these fractures, there is no consensus regarding the optimal treatment option. Arastu et al reported excellent results while using minimally invasive technique for displaced intra-articular fractures while jordan et al. found excellent results and lower wound infection rates with ORIF^[16,17]. So this study was done to determine the outcome of managing calcaneal fractures percutaneously in terms of visual analog pain scale (VAS) at 3 months post-operatively.

MATERIAL AND METHODS

This descriptive study was done from 10th January 2016 to 9th January 2019 at the Department of Orthopaedics, Benazir Bhutto Hospital and Holy Family hospital, Rawalpindi, Pakistan. The inclusion criteria were patients aged between 20 to 65 years with displaced calcaneal fractures belonging to either gender presenting within 1 week of injury. The exclusion criteria were open fractures, poly trauma, bilateral calcaneal fractures, intraarticular comminution, congenital anomalies of the foot and leg, previous surgery of foot, Neurological & psychiatric illnesses, fracture more than 1 week old. All patients presenting to the emergency department and fulfilling the inclusion criteria were made a part of the study using non-probability convenient sampling. Fractures were classified using radiographs - antero-posterior and lateral views and CT scan of the foot.

All patients underwent percutaneous reduction and fixation under C-arm fluoroscope by the same consultant Orthopaedic surgeon. The technique involved placing the patient in lateral position, with the fracture side facing upwards above the normal foot. Under aseptic measures, tourniquet applied but not inflated. Fluoroscope was inverted so that the foot rest on the receiver site in a true lateral view. A line drawn on the posterior border of lateral malleolus about one-thumb breadth below the tip of lateral malleolus, a stiemann pin 3-4 mm was introduced between the fragments to a depth of at least 1 inch (Figure 1). Force was generated towards the heel side to disimpact the fragments. As sufficient force was required and k-wires would bend, hence stiemann pin used for disimpaction and its tip was directed towards the impacted segment, which was pushed superiorly so that our sub-talar angle was regained. A 2 mm k-wire was placed on the skin to determine the position under C-arm fluoroscope, where this elevated fragment can be held. Then this k-wire was inserted from the lateral aspect of tendoachilles in the same direction that we determined (Figure 2). This wire held the fragment and it was advanced distally up to the normal tarsal bone. Another k-wire was passed parallel to it at the same level to hold the same fragment. A third k-wire was inserted to hold the extra-articular fragment under

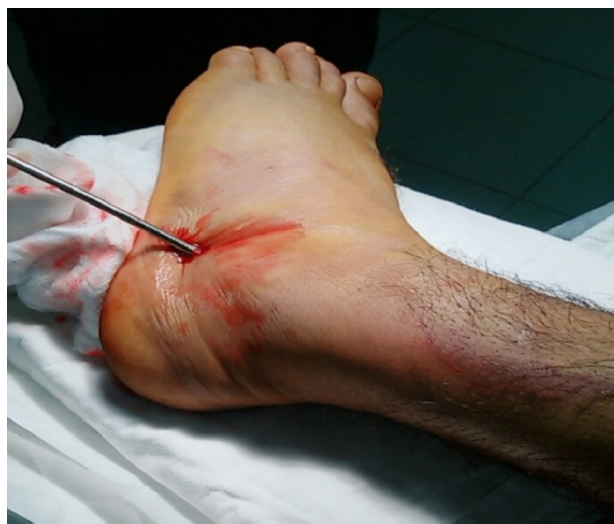

Figure 1 Our technique of percutaneous reduction and fixation of calcaneal fractures.

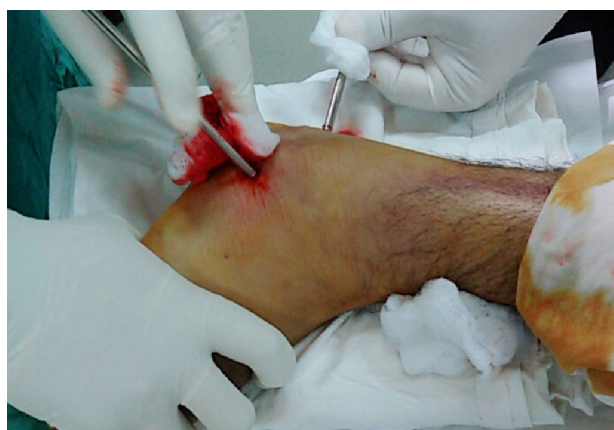

Figure 2 Our technique of percutaneous reduction and fixation of calcaneal fractures.

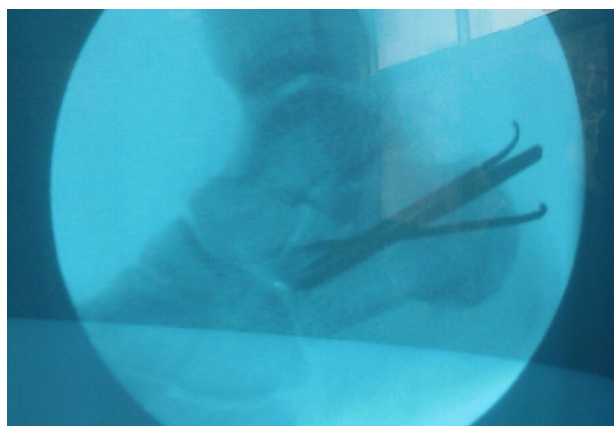


Figure 3 Our technique of percutaneous reduction and fixation of calcaneal fractures.

C-arm fluoroscope (Figure 3).

K-wires were bent posteriorly and padded. Below knee backslab was applied with ample cotton. Patient was discharged the next day. Each patient was given a single dose 1st generation Cephalosporin 15 minutes before the start of surgical procedure and two doses post-operatively.

The rehabilitation protocol involved keeping the patient non-weight bearing for at least 6 weeks. Range of motion exercises started at knee, and toe movements allowed. First follow-up at 2 weeks post-

operatively to remove the backslab and wound inspected and then below knee POP was applied. Touch down weight-bearing on toes was allowed at this stage, which was continued till 6 weeks. Second follow-up at 6 weeks post-operatively, to remove the k-wires in order to avoid infection and touch down weight-bearing of toes continued. Reduction of fracture fragments confirmed using radiographs of foot - anteroposterior and lateral view with Bohler's angle and mean length. Third follow-up at 12 weeks, to assess the outcome in terms of VAS and complications using radiographs of foot. Full weight-bearing started at this stage. VAS had a scale of 0 to 10, where 0 indicated no pain and 10 for maximum pain^[18].

Table 1 Characteristics of children with BA.

Characteristics	BA children (n = 64)
Age at KPE procedure, mean ± SD (days)	105.28 ± 39.28
Gender, n (%)	
Male	34 (53)
Female	30 (47)
Gestational age, n (%)	
Full-term	57 (89)
Premature	7 (11)
Birth weight, n (%)	
Normal	55 (86)
Low	9 (14)
Type of biliary atresia, n (%)	
Type 1	2 (3)
Type 2	33 (52)
Type 3	29 (45)
Cholangitis, n (%)	
Yes	38 (59)
No	26 (41)
Recurrent cholangitis, n (%)	
Yes	10 (26)
No	28 (74)

Note: KPE, Kasai hepatopertoenterostomy.

Data regarding age, gender, mechanism of injury, fractured side, time since injury, type of fracture, visual analog pain scale (VAS) and any complication was noted on proformas. Data was analyzed using SPSS version 23. Qualitative variables including gender, fractured side and mechanism of injury were measured in terms of frequency and percentage. Quantitative variables including age and VAS were measured in terms of means and standard deviations (SD). A *p*-value < 0.05 was considered statistically significant.

RESULTS

A total of 50 patients were included in the study. Majority (80%) were males. Average BMI was 23.5 ± 2.1 Kg/m². Demographic details are shown in table-1.

Most common complication was sub-talar arthritis which was found in 6 (12%) of patients. Mean VAS score was 2.5 ± 0.9 (Table 2). None of the patient had loss of reduction at 6 and 12 weeks post-operatively.

DISCUSSION

Percutaneous reduction and fixation of displaced calcaneal fractures has gained popularity in recent times as it is a minimally invasive technique. In our study, the mean age was 41.3 ± 10.0 years which was comparable to a study done by Vasukutty *et al.* in which mean age was 49 years^[19]. Majority of the patients in our study were males (n = 40, 80%). Gender statistics were in accordance with a study undertaken by Haapasalo *et al.* which comprised of 76% males^[20]. Mean BMI of patients was 23.5 ± 2.1 Kg/m² in our study which was comparable to a study done by Jun *et al.* in China, in which it was 22.5 ± 3.6 Kg/m²^[21]. In majority of the cases there was a fracture of right calcaneum (n = 35, 70%) in our study. This side of involvement statistics were similar to a study by Tantavisut *et al.* which had 56.8% patients with right sided fracture^[22]. 44% patients had Sanders-II fracture type in our study. These fracture statistics were in accordance to a study undertaken by Arastu *et al.* in which 38.7% had Sanders-II, 29% had Sanders-III and 32.2% with Tongue-type fracture^[16].

Table 2 Bivariate and multivariate analyses of predictors of cholangitis after KPE procedure in children with BA.

Predictors	Cholangitis		Bivariate analyses		Multivariate analyses	
	Yes [n=...(%)]	No [n=...(%)]	RR (95% CI)	p value	Adjusted OR (95% CI)	p value
Age at surgery						
>60 days	34 (60)	23 (40)	1.04 (0.53 to 2.05)	1.00f		
≤60 days	4 (57)	3 (43)				
Gender						
Male	16 (47)	18 (53)	0.64 (0.42 to 0.97)	0.03	0.17 (0.04 to 0.87)	0.03
Female	22 (73)	8 (27)				
Nutritional status at surgery						
Malnourished	20 (69)	9 (31)	1.34 (0.89 to 2.01)	0.15	5.97 (0.86 to 41.45)	0.07
Well-nourished	18 (51)	17 (49)				
Direct bilirubin levels before surgery						
>10mg/dL	8 (40)	12 (60)	0.59 (0.33 to 1.04)	0.03	0.15 (0.02 to 0.97)	0.04
≤10mg/dL	30 (68)	14 (32)				
Liver fibrosis						
Yes	31 (63)	18 (37)	1.36 (0.76 to 2.43)	0.25		
No	7 (47)	8 (53)				
Liver cirrhosis						
Yes	20 (74)	7 (26)	1.52 (1.02 to 2.27)	0.04	9.11(1.31 to 63.23)	0.02
No	18 (49)	19 (51)				

Note: CI, Confidence Interval; OR, Odds Ratio; RR, Relative Risk.

Various functional outcome measures have been employed by different researchers like foot and ankle scoring, SF-36, VAS, etc. In our study VAS was determined at 3-months post-operatively which showed excellent results. The mean VAS was 2.5 ± 0.9 . This was similar to a study done by Park *et al.* in South Korea^[23]. Most common post-operative complication was sub-talar arthritis found in 12% of patients. 4% had superficial pin tract infection while 4% had wire irritation. These statistics were in accordance with the study by Tantavisut *et al.* which had 9.3% screw irritation, 6.5% sub-talar arthritis and 0.9% deep infection as complication^[22]. In our technique, k-wire was introduced from posterior to the anterior side. At least 2 k-wires were passed to make a platform and prevent fragment from collapsing, which becomes likely if k-wires are inserted from heel to fragment, as according to us is not sufficient to prevent collapse^[16]. We did not employ screws in our cases rather k-wires were used. K-wires have the advantage of early and easy removal percutaneously, and mostly patients were laborers in our study, so for them affording a revision surgery would have been difficult.

The results of our study are in favor of percutaneous minimally invasive reduction and fixation of calcaneal fractures. Our study had certain limitation as well. Firstly, it was done on a small sample size. Large sample and long duration studies with an extended follow-up can be done. Secondly, this was a descriptive study. Studies can be done comparing the open reduction internal fixation of calcaneal fractures in terms of functional outcome to determine the gold standard management technique. Future implications regarding calcaneal fractures can be use of a specific trocar-cannula system for disimpaction and application of synthetic graft for filling of gap between the fragments. For this arthroscopic cannula system should not be used as a lot of forces are required, which is likely to deform it.

CONCLUSION

The study concludes that percutaneous reduction and fixation of calcaneal fractures has good functional outcome.

REFERENCES

- Galluzzo M, Greco F, Pietragalla M, De Renzis A, Carbone M, Zappia M, Maggialelli N, D'andrea A, Caracchini G, Miele V. Calcaneal fractures: radiological and CT evaluation and classification systems. *Acta Biomed* 2018;**89**(1-5):138-150. doi: 10.23750/abm.v89i1-S.7017.
- Leite CBG, Macedo RS, Saito GH, Sakaki MH, Kojima KE, Fernandes TD. Epidemiological study on calcaneus fractures in a tertiary hospital. *Rev Bras Ortop* 2018;**53**(4):472-476. doi: 10.1016/j.rboe.2018.05.014.
- Razik A, Harris M, Trompeter A. Calcaneal fractures: Where are we now? *Strategies in Trauma and Limb Reconstruction* 2018;**13**(1):1-11. Doi: 10.1007/s11751-017-0297-3
- Singh A, Narsaria N, Verma I. Effect of bone grafting in short and long term outcomes of displaced intra-articular calcaneal fractures: A prospective comparative study. *International Journal of Orthopaedics* 2016;**3**(1):505-511.
- Wei N, Zhou Y, Chang W, Zhang Y, Chen W. Displaced Intra-articular Calcaneal Fractures: Classification and Treatment. *Orthopedics* 2017;**40**(6): e921-e929. doi: 10.3928/01477447-20170907-02.
- Li Y, Bao RH, Jiang ZQ, Wu HY. Complications in operative fixation of calcaneal fractures. *Pak J Med Sci* 2016;**32**(4):857-862. doi: 10.12669/pjms.324.10225.
- Türkmen F, Korucu IH, Sever C, Göncü G, Kaçira BK, Tokar S. Calcaneal Fractures, Treatments and Problems. *Clin Res Foot Ankle* 2014;**2**(3):138-143. Doi: 10.4172/2329-910X.1000138.
- Schepers T, Patka P. Treatment of displaced intra-articular calcaneal fractures by ligamentotaxis: current concepts' review. *Arch Orthop Trauma Surg* 2009;**129**(12):1677-1683. doi: 10.1007/s00402-009-0915-8.
- Xia S, Lu Y, Wang H, Wu Z, Wang Z. Open reduction and internal fixation with conventional plate via L-shaped lateral approach versus internal fixation with percutaneous plate via a sinus tarsi approach for calcaneal fractures – A randomized controlled trial. *International Journal of Surgery* 2014;**12**(5):475-480. Doi: 10.1016/j.ijso.2014.03.001
- Backes M, Schep NWL, Luitse JSK, Goslings JC, Schepers T. The effect of postoperative wound infections on functional outcome following intra-articular calcaneal fractures. *Archives of Orthopaedic and Trauma Surgery* 2015;**135**(8):1045-1052. Doi: 10.1007/s00402-015-2219-5
- Badia JM, Casey AL, Petrosillo N, Hudson PM, Mitchell SA, Crosby C. Impact of surgical site infection on healthcare costs and patient outcomes: a systematic review in six European countries. *Journal of Hospital Infection* 2017;**96**(1):1-15. Doi: 10.1016/j.jhin.2017.03.004
- Naik MM, Nagaprasad N, Vishwanath V. The clinical study of incidence and role of co-morbid conditions in management and outcome of burns patients. *Int Surg J* 2017;**4**(10):3363-3370. Doi: 10.18203/2349-2902.isj20174497
- Wagstrom EA, Downes JM. Limited Approaches to Calcaneal Fractures. *Curr Rev Musculoskelet Med* 2018;**11**(3):485-494. doi: 10.1007/s12178-018-9511-2.
- Rammelt S, Amlang M, Barthel S, Gavlik JM, Zwipp H. Percutaneous treatment of less severe intraarticular calcaneal fractures. *Clin Orthop Relat Res* 2010;**468**(4):983-990. Doi: 10.1007/s11999-009-0964-x
- Heintzman SE, Lund EA, Bubla JW. A Novel Casting Technique for Tongue-Type Calcaneus Fractures With Soft Tissue Compromise. *Foot & Ankle Orthopaedics* 2017;**2**(4):1-6. Doi: 10.1177/2473011417712185
- Arastu M, Sheehan B, Buckley R. Minimally invasive reduction and fixation of displaced calcaneal fractures: surgical technique and radiographic analysis. *Int Orthop* 2014;**38**(3):539-545. doi: 10.1007/s00264-013-2235-4.
- Jordaan P, Maqungo S, Roche S, Magampa R, McCollum G. Open reduction and internal fixation of calcaneus fractures through a sinus tarsi approach. *SA orthop J* 2016; **15**(3):27-32. Doi: 10.17159/2309-8309/2016/v15n3a3
- Delgado DA, Lambert BS, Boutris N, McCulloch PC, Robbins AB, Moreno MR, Harris JD. Validation of Digital Visual Analog Scale Pain Scoring With a Traditional Paper-based Visual Analog Scale in Adults. *J Am Acad Orthop Surg Glob Res Rev* 2018;**2**(3):e088. doi: 10.5435/JAAOSGlobal-D-17-00088.
- Vasukutty N, Kumar V, Diab M, Moussa W. Operative treatment of calcaneal fractures: improved outcomes and low complications rates with a strict management protocol. *Ann R Coll Surg Engl* 2017;**99**(4):275-279. doi: 10.1308/rcsann.2016.0259.
- Haapasalo H, Laine HJ, Maenpää H, Wretenberg P, Kannus P, Mattila VM. Epidemiology of calcaneal fractures in Finland. *Foot Ankle Surg* 2017;**23**(4):321-324. Doi: 10.1016/j.fas.2016.10.004
- Su J, Cao X. Risk factors of wound infection after open reduction and internal fixation of calcaneal fractures. *Medicine (Baltimore)* 2017;**96**(44):e8411. doi: 10.1097/MD.00000000000008411.
- Tantavisut S, Phisitkul P, Westerlind BO, Gao Y, Karam MD, Marsh JL. Percutaneous Reduction and Screw Fixation of Displaced Intra-articular Fractures of the Calcaneus. *Foot Ankle Int* 2017;**38**(4):367-374. Doi: 10.1177/1071100716679160
- Park CH, Lee DY. Surgical treatment of Sanders type 2 calcaneal fractures using a sinus tarsi approach. *Indian J Orthop* 2017;**51**:461-467. Doi: 10.4103/ortho.IJOrtho_143_16