

Traction during Total Knee Arthroplasty Leads to a Bone-Conserving Tibial Resection: A Retrospective Comparative Study

James H M Brown¹, MB ChB, B Eng, FRCS (Trauma & Ortho)

¹ Department of Orthopaedic Surgery, Peninsula NHS Treatment Centre, Plymouth, United Kingdom.

Conflict-of-interest statement: The author has intellectual property (IP) interest in knee arthroplasty

Open-Access: This article is an open-access article which was selected by an in-house editor and fully peer-reviewed by external reviewers. It is distributed in accordance with the Creative Commons Attribution Non Commercial (CC BY-NC 4.0) license, which permits others to distribute, remix, adapt, build upon this work non-commercially, and license their derivative works on different terms, provided the original work is properly cited and the use is non-commercial. See: <http://creativecommons.org/licenses/by-nc/4.0/>

Correspondence to: James H M Brown, FRCS(T&O), Consultant orthopaedic surgeon, Peninsula NHS Treatment Centre, 20 Brest Road, Plymouth International Business Park, Plymouth, United Kingdom of Great Britain & Northern Ireland PL6 5XP.

Email: jhmbrown@gmail.com

Telephone: +44-0-7989599882

ORCID Id: 0000-0002-6591-9718

Received: January 11, 2020

Revised: April 18, 2020

Accepted: April 21 2020

Published online: June 28, 2020

ABSTRACT

OBJECTIVE: In Total Knee Arthroplasty, an insert is selected to give optimal movement and stability. The depth of tibial resection is the major influence on insert thickness. A deep resection has drawbacks: it may destabilise the posterior cruciate insertion, the cut may not be through strong subchondral bone, and inserts up to 20mm must be available. In-line traction has been used in some centres to select the resection depth, but has not been described. This paper compares the depth of resection achieved with stylus technique against manual in-line traction technique using the spacer block.

METHODS: Retrospective comparative study. 70 'Stylus' cases versus 70 'Traction' cases. Implanted insert thickness utilised as a

surrogate for tibial resection depth. Numbers of inserts used of each thickness, and data about potential confounding factors, retrieved from e-record. Wilcoxon rank-sum test for increase / decrease in the median insert thickness for 'Traction' compared to 'Stylus'. Observations made on limb alignment, joint line obliquity and kinematic resurfacing.

RESULTS: 'Traction' (median 8mm) gives a more bone-conserving cut than 'Stylus' (median 10 mm) ($p = 0.013$). Numbers of inserts implanted (Stylus, Traction): Tibial re-cut (6.6); 8mm insert (23.39); 10mm insert (26.18); 12.5 mm insert (13.7); 15mm insert (2.0).

DISCUSSION AND CONCLUSION: Study findings suggest in-line traction can reference from the distal femoral cut, appropriately tensioning the capsule and ligaments, to give a bone-conserving tibial cut. The technique can be used with existing instruments. Further investigation is proposed into limb alignment: specifically, intra-operative traction as a complement to kinematic resurfacing of the femur.

Key Words: Knee arthroplasty; Traction; Tibial resection; Kinematic alignment

© 2020 The Author(s). Published by ACT Publishing Group Ltd. All rights reserved.

Brown JHM. Traction during Total Knee Arthroplasty Leads to a Bone-Conserving Tibial Resection: A Retrospective Comparative Study. *International Journal of Orthopaedics* 2020; 7(3): 1283-1288 Available from: URL: <http://www.ghrnet.org/index.php/ijo/article/view/2767>

Level of Evidence - Therapeutic Level 3 - Retrospective Comparative Study

What is already known?

A bone-conserving tibial cut is optimal in total knee arthroplasty
Intra-operative manual traction is in use in some Centres to set the tibial resection depth, but is not described in the literature

What are the new findings?

Manual traction sets the tibial resection depth predictably
The resection depth is more bone-conserving than using the stylus
These Study results are a step along the path to utilising formal intra-operative traction as an aid to the intra-operative alignment of total knee arthroplasty

Ethical Consideration: Guidance was sought from the local University Hospital Research and Development Office [Acknowledgement A1]. This is a retrospective evaluation of existing data: ethical review is not indicated.

Institutional Approval: Granted

INTRODUCTION

During total knee arthroplasty (TKA), the tibial resection is conventionally referenced from bony landmarks on the tibia, either by direct measurement using a stylus, or by indirect measurements if using patient-specific instrumentation, navigation or robot-assisted surgery. The tibial resection is defined by the depth (or level) of the cut and by its spatial orientation in the coronal and sagittal planes. This paper is primarily concerned with the depth of resection. In the discussion section, its coronal plane orientation and the important effect on limb alignment will also be commented on.

The tibial resection depth can be referenced directly from the distal femoral cut, using manual in-line traction to tension the knee capsule and ligaments, *marking the tibial plateau anterior cortex to match a particular insert*. This technique employs the spacer block of matching insert thickness (Figure 1). Standard instrumentation is then used, aligning the saw capture with the mark on the tibial plateau anterior cortex (Figure 2). This manual traction technique has been a routine part of some surgeons' practise, but has not been compared to any alternative technique in the literature. It has been used in the UK [A2], Hungary, Spain and the USA[A3].

There is no ideal polyethylene insert thickness. However, consistently achieving a bone-conserving tibial resection, equating to the implantation of a thin insert, would confer advantages:

Firstly, an excessively deep resection can de-stabilise the posterior cruciate insertion^[1].

Secondly, a bone-conserving resection can provide a plane that is at least partly travelling through hard subchondral bone, reducing the risk of tray subsidence.

Thirdly, a predictable and bone-conserving cut may allow the thicker inserts to be eliminated from the inventory, reducing costs.

The simplicity of the technique - and its potential future application to limb alignment - prompted this retrospective comparative study.

Study Purpose: to investigate the depth of tibial resection for 'Traction' technique against 'Stylus' technique during TKA, when the surgical tactic was to plan and measure for a minimal, bone-conserving resection in all cases, while minimising the need to carry out an additional resection (tibial re-cut).

METHODS

Study Design

Retrospective comparative study. Comparison between 'Stylus' series ($n = 70$) and 'Traction' series ($n = 70$), testing for difference in the median insert thickness between the 2 series.

Three potential confounding factors were selected: pre-operative coronal plane (varus / valgus) deformity; pre-operative fixed flexion; and Body Mass Index (BMI). Statistical analysis to test for difference in the distribution of these characteristics between the 'Stylus' and 'Traction' series.

Data was retrieved retrospectively from the patient electronic record and radiographs, anonymised, and inputted to a Microsoft Excel spreadsheet: see supplementary file 1.

The 'Stylus' series ($n = 70$) was carried out by a single surgeon (index surgeon) as a consecutive series of primary TKA immediately prior to a change in usual practise (from stylus to traction) introduced

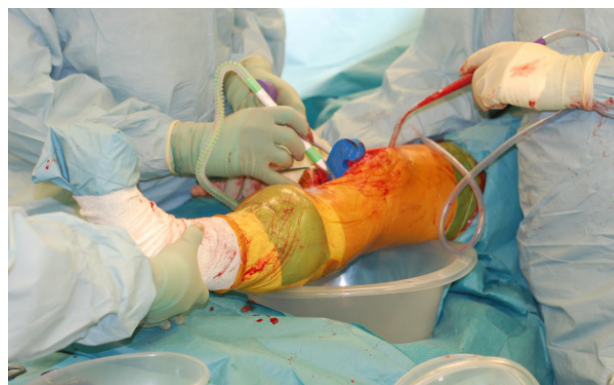

Figure 1 Traction technique: marking the tibial resection depth.

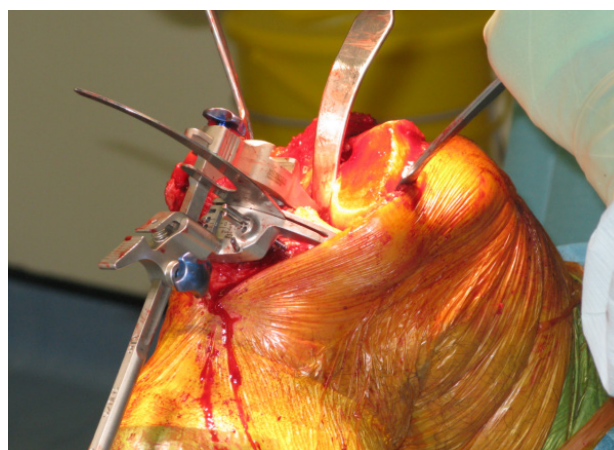


Figure 2 Tibial saw slot aligned to the mark.

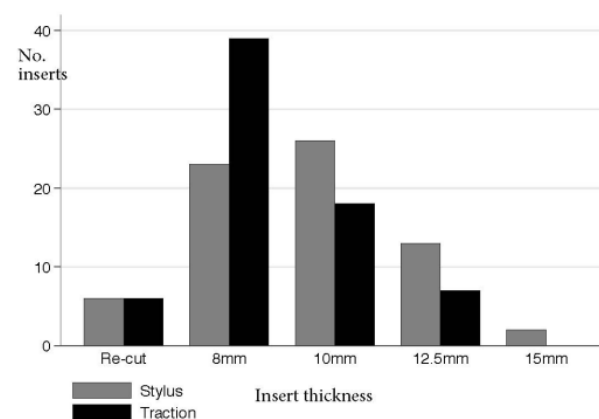


Figure 3 Results. Thickness of implanted inserts.

in May 2016[A2]. The 'Traction' series ($n = 70$) was performed by the index surgeon as a consecutive series of primary TKA immediately after the change in practise. All cases employed the PFC fixed bearing cemented TKA system (DePuy Orthopaedics Inc., Warsaw, Indiana 46582). This design has 8mm, 10mm, 12.5mm, 15mm, 17.5mm and 20mm insert thicknesses, in cruciate-retaining and cruciate-sacrificing (posterior-stabilised) variants. The following surgical tactics were followed: medial parapatellar approach - 9mm distal femoral cut - bone-conserving tibial cut made in accordance with the concept of constitutional varus^[2,3] - extension gap assessment - femoral finishing - flexion gap assessment - patellar resurfacing.

See supplementary file 2: Data was retrieved from the Centre's computerised stores inventory, detailing all PFC inserts used in the Centre during 2016, by staff and visiting surgeons (total: 7 surgeons,

445 inserts). This data was obtained in order to make a comparative assessment of the index surgeon's Stylus technique to colleagues, with respect to insert thickness.

Traction Method Description

Spacer blocks are standard instruments, for assessing the flexion and extension gaps. The 8mm extension spacer block was used in the 'Traction' series, as the surgical tactic was to aim for a bone-conserving tibial cut. The spacer block is equivalent in thickness to the sum of the distal thickness of the femoral component (9mm), the tray and the insert. Steps: (1) Distal femoral cut (9mm for this series), excise all accessible osteophytes, both from the femoral condyles and the tibial plateau; (2) Extend the knee, place a bowl under the knee so that it is 5 degrees flexed; (3) Assistant applies manual in-line traction, using both hands around the ankle; (4) (Figure 1) Bring the spacer block up against the distal femoral cut, and mark the tibial resection where the distal face of the block rests against the anterior aspect of the tibial plateau. Use diathermy or pen to mark a clean 1-2cm line running across the midline; (5) (Figure 2) Flex the knee. Use standard instrumentation to mount the cutting block; (6) Select posterior slope according to the pre-operative plan, or by following the native plateau posterior slope as is usual in kinematic technique; (7) Apply varus adjustment if indicated by the pre-operative plan, or if following kinematic technique; (8) Use the saw-blade, or an angeling, through the saw-slot, to align the block with the clean marked line. Secure with pins; (9) Cut.

Tips

Operating *without a tourniquet* allows draping proximally, and a better visual assessment of limb alignment.

Keep the knee a few degrees flexed over a bowl when using traction to set the tibial resection - and certainly *avoid hyper-extension caused by the foot bolster* as this will lead to a deeper tibial resection.

Data Retrieval And Statistical Analysis[A4]

Data retrieval was complete in all 140 cases, for all parameters. The thicknesses of the inserts implanted were retrieved from the patient e-record, and are displayed as a cluster-column chart (Figure 3). Wilcoxon rank sum test is effective for comparing the medians of two non-normal distributions: it was selected for the primary statistical test, looking for a trend to a significant increase / decrease in the insert thickness between the 'Stylus' ($n = 70$) and 'Traction' ($n = 70$) series. Note: the first cluster-column is 'Re-cut'. This represents the 6 cases in each series where an additional tibial resection was required to implant the thinnest (8 mm) insert.

Potential pre-operative confounding factors were retrieved from the Picture Archiving and Communication System (PACS) and from the patient e-record: varus / valgus deformity (Figure 4), fixed-flexion deformity (Figure 5), and BMI (Figure 6). The Figures show the data separated into the 'Stylus' and 'Traction' series, presented as box-and-whisker plots. As is customary with box-and-whisker plots the box limits represent the 25th and 75th centile data values, with the median data value represented by the line within the box.

Pre-operative fixed flexion was retrieved from the operation record. Varus / valgus pre-operative deformity was electronically measured directly in cases where the standing Hip-Knee-Ankle radiograph was available, or calculated after electronically measuring the pre-operative anatomic axis angle in the remaining cases, from the standing knee radiograph.

Logistical regression modelling of these three potential

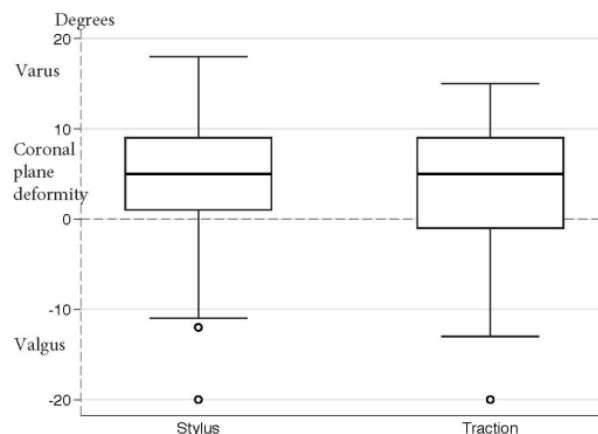


Figure 4 Coronal plane pre-operative deformity. Varus +ve.

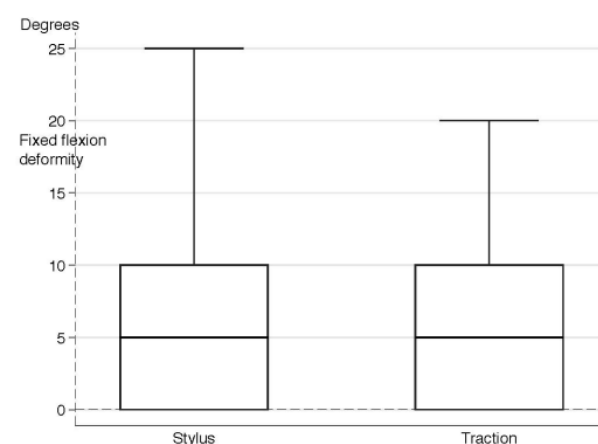


Figure 5 Fixed-flexion pre-operative deformity.

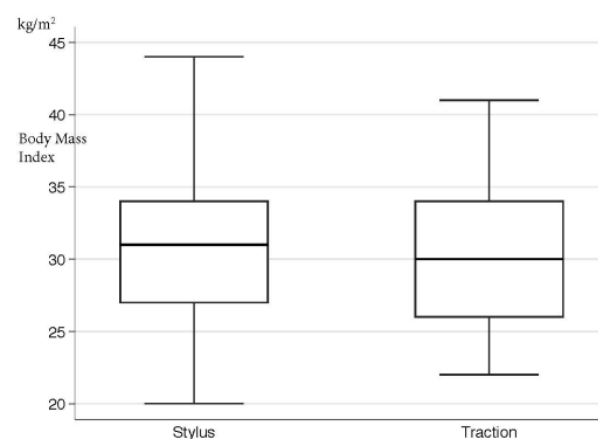


Figure 6 Body Mass Index.

confounding factors was performed, to detect variation in the distribution of these factors between the series.

Trend test for the insert thickness over time (date of operation), within the 'Stylus' series and separately within the 'Traction' series, was carried out as a check on consistency of technique over time.

See supplementary 2. This data lists all tibial inserts used in the Centre during 2016, by the index surgeon and 6 colleagues. By redacting the inserts used by the index surgeon, data from a representative surgeon group who use the 'Stylus' technique can then be compared, in Table 1 below, with the index surgeon's 'Stylus' series inserts:

Chi square test was selected to compare the two rows of data in Table 1, testing for a significant difference between the two sequences of inserts.

RESULTS

See Figure 3. ‘Traction’ technique led to a significantly thinner insert than ‘Stylus’ ($p = 0.013$). The median for ‘Traction’ is 8mm; and for ‘Stylus’ it is 10 mm.

See Figures 4,5 and 6. There was no detectable significant difference between the distributions of the potential confounding factors in the two series. With respect to these factors, the two series can be considered similar.

There was no change in insert thickness with time during the ‘Stylus’ series time period. Similarly, there was no change during the ‘Traction’ series time period ($p > 0.8$). Technique appears consistent with time, for both methods.

See Table 1. There is a significant difference in distribution between the two data rows ($p = 0.02$). The index surgeon’s ‘Stylus’ technique led to thinner inserts than the representative surgeon group.

DISCUSSION

Manual Traction To Set The Tibial Resection Depth

Study findings confirm that the manual in-line traction technique - which has been in use in multiple centres for some years[A2,A3] - is an effective and reproducible method for selecting the tibial resection depth. In this single-surgeon study, the resection using ‘Traction’ was more bone-conserving than using the ‘Stylus’ technique. It can be noted that the index surgeon’s ‘Stylus’ technique was already producing a bone-conserving resection compared to a representative surgeon group.

The technique is intuitive for orthopaedic surgeons as we are all trained in the use of traction for trauma cases. The technique uses standard instruments.

Care must be taken to avoid hyper-extension of the knee during the in-line traction step: this will lead to a deeper resection. This is countered by placing a bowl under the knee, aiming for 5 degrees flexion. This is especially recommended if a steep posterior slope is planned.

Note On The Principles Of Traction And Distraction

In-line traction underpins trauma practise, and has done for more than a century. By applying longitudinal tension to a segmented structure, perpendicular force vectors within the structure tend to resolve towards zero, aligning the segments. It has not previously been proposed as a method for intra-operative alignment of TKA.

By contrast, distraction is in clinical use for TKA. Distraction uses force applied within the joint to tension soft tissues, so that for example femoral sizing and component rotation can be referenced from the tibial cut, with the knee flexed.

Traction differs from distraction, in that limb deformity will tend to correct towards a neutral limb axis with application of in-line force at the limb extremity. This is not always the case with distraction: forces applied within the joint may tend to increase deformity.

Observations On Traction And Kinematic Technique

These study findings indicate that intra-operative traction can predictably tension the knee ligaments and capsule, allowing the tibial resection depth to be referenced from the femur. Could traction have a role in TKA alignment, referencing the tibial resection coronal plane orientation in a similar fashion, from the distal femoral cut? In

Table 1 Inserts implanted by a representative surgeon group using the stylus technique compared to the index surgeon’s stylus (n=70) series.

	8 mm	10 mm	12.5 mm	15 mm	17.5 mm
Representative surgeon group	55	207	71	19	5
Index surgeon ‘Stylus’ series	23	26	13	2	0

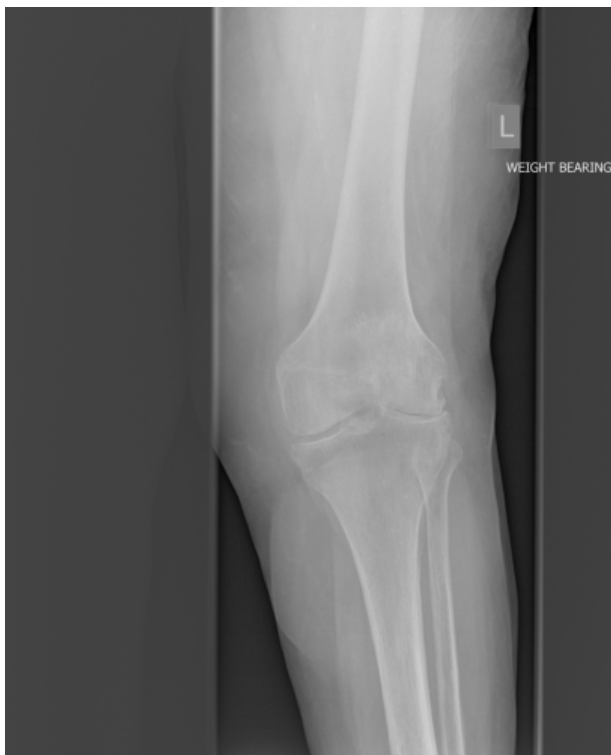

Figure 7 Case illustrating joint line obliquity. Standing radiograph.

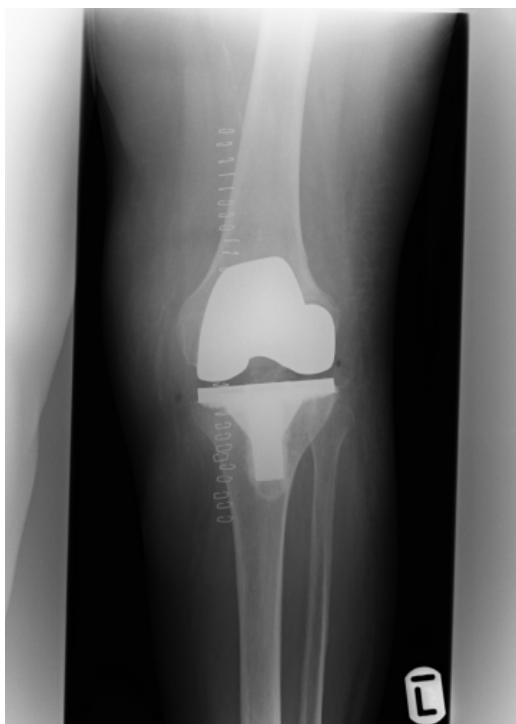

Figure 8 Standing post-operative radiograph of Figure 7 case.

this setting the structure to be aligned has two segments: the femur extending from hip centre to knee centre, and the leg, extending from knee centre to the point of application of traction. Lin et al^[4] have

described 5 patterns of coronal limb alignment, with combinations of overall limb alignment and joint line obliquity. Riviere et al^[5] summarise the 5 methods currently used to address TKA coronal alignment: mechanical alignment; anatomic alignment; adjusted mechanical alignment; kinematic alignment (KA), and restricted kinematic alignment (rKA). KA has emerged as an effective method of addressing differing patterns of coronal alignment. Survivorship rates and outcomes comparable with mechanical alignment have been reported at 10 years after surgery^[6].

When using the described manual in-line traction method to set the tibial resection depth, an observation was repeatedly made: limb deformities tend to correct towards neutral - as in fact is predicted by the principle of traction, as the structure has two segments.

When using Kinematic Alignment technique in a case with joint line obliquity such as Figure 7, it is interesting to hold a long alignment rod perpendicular to the distal femoral cut after it has been made, after osteophytes have been excised, and with in-line traction applied at the ankle: the distal end of the rod will be located lateral to the ankle centre. This gives an indication of the varus adjustment of the tibial cut that is required for that specific case, and a useful visual aid can be drawn by projecting the course of the long alignment rod onto the leg, from tibial tubercle distally to the ankle, using a marker pen: this line acts as an aid when mounting the extra-medullary tibial jig.

It is important to recognise that this additional visual alignment check has not been validated: the author cannot at this time recommend it as the primary alignment method for aligning the tibial cut: but it is an interesting check to make.

One surgical technique which has been validated at the present time (Medacta GMK sphere) recommends initially positioning the distal limit of the extra-medullary jig 15mm lateral to the ankle centre, in order to build in a standardised varus adjustment of 3 degrees; this is followed by a visual fine-tune of the varus/valgus setting of the cutting block, until it is parallel to the articular surface, compensating for bone and cartilage loss. This step can be technically difficult.

After the tibial cut, a further adjustment cut may be necessary to vary the varus/valgus until the knee is balanced in extension.

Consider Figure 7 once again. KA was used, maintaining joint line obliquity and the cylindrical axis^[7,8,9]. It is now recognised by many surgeons that careful kinematic resurfacing of the femur is key to successfully re-creating the cylindrical axis in the reconstructed joint. As for the tibia, the challenge that this type of case asks of the surgeon using kinematic alignment technique is: *how much coronal-plane (varus) adjustment to incorporate in the tibial resection?* (see Figure 8).

A modification to kinematic alignment technique is proposed for investigation: reference of tibial cut coronal-plane alignment directly from the distal femoral cut, with osteophytes removed and in-line traction applied. If in-line traction demonstrates overall limb alignment within acceptable limits, then any joint line obliquity followed by the kinematic femoral resurfacing will be translated across to the tibia by the technique, setting the varus adjustment to the tibial cut. This would be a useful complement to KA technique, combining alignment and a bone-conserving tibial resection.

Study Limitations

The study utilises the implanted tibial insert thickness as a surrogate measure of the bone-conserving nature of the tibial resection. This implies that the insert thickness has been selected to give a consistent balance between range of movement and stability across both series.

This is a retrospective study of data extracted from a single-surgeon TKA series.

The 'Traction' results include the surgeon learning curve, which could act to worsen the 'Traction' results relative to 'Stylus', although trend test appears to show that the results were consistent over time.

CONCLUSIONS

Traction is a fundamental principle of trauma and orthopaedic practise, familiar to every surgeon. Study results confirm - within the acknowledged limitations of the study - that intra-operative manual in-line traction can reference reproducibly from the distal femoral cut to give a bone-conserving tibial resection, using standard instrumentation. This is in keeping with the modern trend towards resurfacing, with minimal bone resection.

Further investigation is proposed into limb alignment: specifically, intra-operative traction as a complementary technique to kinematic resurfacing of the femur.

ACKNOWLEDGEMENTS

[A1] Dr Gary Minto FRCA and Dr Helen Neilens of the Research Office, University Hospitals Plymouth NHS Trust.

[A2] Professor David Barrett FRCS, Southampton UK, for teaching the in-line traction technique during an instructional visit to Spire Hospital Southampton in May 2016 sponsored by DePuy Synthes, and for his advice during manuscript preparation.

[A3] Dr Ivan Udvarhelyi MD, Budapest, Hungary; Dr Rafael Ferrer Gonzalez-Adrio, Tenerife, Spain; and Dr Richard Berger MD, Chicago USA for personal communications describing Centres where the in-line traction technique has been used currently or in the past.

[A4] Dr A Rosemary Tate DPhil CStat, Cambridge, UK, for her expertise in statistics.

REFERENCES

1. Cinotti G, Sessa P, Amato M, Ripani FR, Giannicola G. Preserving the PCL during the tibial cut in total knee arthroplasty. *Knee Surg Sports Traumatol Arthrosc.* 2017 Aug; **25**(8): 2594-2601. [DOI: 10.1007/s00167-015-3842-y]; [PMID: 26537596]
2. Bellemans J, Colyn W, Vandenneucker H, Victor J. The Chitranjan Ranawat Award: Is neutral mechanical alignment normal for all patients? The concept of constitutional varus. *Clin Orthop Relat Res.* 2012 Jan; **470**(1): 45-53. [DOI: 10.1007/s11999-011-1936-5]; [PMID: 21656315]
3. Vanlommel L, Vanlommel J, Claes S, Bellemans J. Slight undercorrection following total knee arthroplasty results in superior clinical outcomes in varus knees. *Knee Surg Sports Traumatol Arthrosc.* 2013 Oct; **21**(10): 2325-30. [DOI: 10.1007/s00167-013-2481-4]; [PMID: 23552665]
4. Lin YH, Chang FS, Chen KH, Huang KC, Su KC. Mismatch between femur and tibia coronal alignment in the knee joint: classification of five lower limb types according to femoral and tibial mechanical alignment. *BMC Musculoskelet Disord.* 2018 Nov 24; **19**(1): 411. [DOI: 10.1186/s12891-018-2335-9]; [PMID: 30474544]
5. Riviere C, Iranpour F, Auvinet E, Howell SM, Vendittoli PA, Cobb J, Parratte S. Alignment options for total knee arthroplasty: A systematic review. *Orthop Traumatol Surg Res.* 2017 Nov; **103**(7): 1047-1056 [DOI: 10.1016/j.otsr.2017.07.010]; [PMID: 28864235]
6. Howell SM, Shelton TJ, Hull ML. Implant Survival and Function Ten Years After Kinematically Aligned Total Knee Arthroplasty. *J Arthroplasty.* 2018 Dec; **33**(12): 3678-84. [DOI: 10.1016/j.arth.2018.07.020]; [PMID: 30122435]

Brown JHM. Traction during TKA

7. Riviere C, Iranpour F, Harris S, Auvinet E, Aframian A, Chabrand P, Cobb J. The kinematic alignment technique for TKA reliably aligns the femoral component with the cylindrical axis. *Orthop Traumatol Surg Res.* 2017 Nov; **103**(7): 1069-1073. [DOI: 10.1016/j.otsr.2017.06.016]; [PMID: 28870873]
8. Hollister AM, Jatana S, Singh AK, Sullivan WW, Lupichuk AG. The Axes of Rotation of the Knee. *Clin Orthop Relat Res.* 1993 Jun; 290: 259-68. [DOI: 10.1097/00003086-199305000-00033]; [PMID: 8472457]
9. Eckhoff DG, Bach JM, Spitzer V, Reinig KD, Bagur MM, Baldini T, Flannery NM. Three-Dimensional Mechanics, Kinematics, and Morphology of the Knee Viewed in Virtual Reality. *J Bone Joint Surg Am.* 2005; **87**(suppl 2): 71-80. [DOI: 10.2106/JBJS.E.00440]; [PMID: 16326726]