

Osteosynthesis of Fracture Neck Femur in the Sixth and Seventh Decades of Life

Barakat El-Alfy¹, MD; Tamer Niazy¹, MD; Bassam Abouelnas¹, MD

¹ Department of Orthopedic Surgery, Faculty of Medicine, Mansoura University, Egypt.

Conflict-of-interest statement: The author(s) declare(s) that there is no conflict of interest regarding the publication of this paper.

Open-Access: This article is an open-access article which was selected by an in-house editor and fully peer-reviewed by external reviewers. It is distributed in accordance with the Creative Commons Attribution Non Commercial (CC BY-NC 4.0) license, which permits others to distribute, remix, adapt, build upon this work non-commercially, and license their derivative works on different terms, provided the original work is properly cited and the use is non-commercial. See: <http://creativecommons.org/licenses/by-nc/4.0/>

Correspondence to: Barakat El-Alfy, Department of Orthopedic Surgery, Faculty of Medicine, Mansoura University, Egypt.
Email: barakatelalfy@yahoo.com

Received: November 30, 2019

Revised: January 13, 2020

Accepted: January 20, 2020

Published online: February 28, 2020

ABSTRACT

AIM: Fracture neck of femur is common in elderly people due to osteoporosis or osteomalacia. The aim of this study is to assess the results of internal fixation of fracture neck femur in the sixth and seventh decades of life by dynamic hip screw (DHS) and antirotation screw.

MATERIALS AND METHODS: 38 patients with displaced fracture neck femur were included in this study. The ages ranged from 50 to 69 years with an average of 61 years. 22 patients were males and 16 were females. All patients were treated by closed reduction and internal fixation by DHS and antirotation screw.

RESULTS: Bone union was achieved in all patients except four. The time to bone union ranged from 3 to 8 months with an average of 5 months. The time to full weight bearing ranged from 2 to 7 months with an average of 4 months. The complications included superficial wound infection in 3 cases, nonunion in 4 cases and osteonecrosis in 3 cases.

CONCLUSION: Internal fixation by DHS and antirotation screw

is a good method for treatment of fracture neck femur in the sixth and early seventh decades of life. It provides sufficient stability that allows for early weight bearing and increases the chances of bone union.

Key words: Fracture neck femur; Dynamic hip screw; Internal fixation; The sixth decade of life

© 2020 The Author(s). Published by ACT Publishing Group Ltd. All rights reserved.

El-Alfy B, Niazy T, Abouelnas B. Osteosynthesis of Fracture Neck Femur in the Sixth and Seventh Decades of Life. *International Journal of Orthopaedics* 2020; 7(1): 1227-1231 Available from: URL: <http://www.ghrnet.org/index.php/ijo/article/view/2807>

INTRODUCTION

Fracture neck of femur is common in elderly people due to osteoporosis or osteomalacia. The most common mechanisms of injury are either a fall that causes a direct blow to the greater trochanter or forced lateral rotation of the lower extremity^[1,2]. The treatment of this fracture depends mainly on the age of the patient and the degree of displacement. In young adults below the age of 50 the treatment is clear by reduction of the fracture and fixation by multiple cancellous screws. In elderly people nondisplaced or valgus impacted fractures can be treated with percutaneous pin fixation using cannulated screws while, displaced fracture is best treated with hemiarthroplasty using a cemented stem^[3,4,5,6].

In the 6th and 7th decades of life which is the period between 50-70 years there is no a universal agreement among the surgeons about the best method of treatment. Some are in favor of hip arthroplasty and others are in favor of internal fixation. Internal fixation of the fracture neck femur in this age group has several advantages compared with arthroplasty including: shorter operative time, decreased blood loss, and reduced perioperative mortality^[7,8,9].

The aim of this study is to assess the results of internal fixation of fracture neck femur in the sixth and seventh decades of life by DHS and antirotation screw.

PATIENTS AND METHODS

Between May 2012 and Jun 2017, 38 patients with displaced fracture

neck femur were treated in our institution by closed reduction and internal fixation by DHS and antirotation screw. The ages ranged from 50 to 69 years with an average of 61 years. 22 patients were males and 16 were females. The etiology was fall at home in 26 patients and outdoor injury in 12 patients. The fractures were Garden type III in 23 patients and garden type IV in 15 patients. Patients less than 50 years old or above seventy were excluded. Also patients with undisplaced fractures, pathological fractures or arthritic changes of the hip joint were excluded. The time elapsed between trauma and surgery ranged from few hours to 7 days with an average of 3 days. All patients gave their informed consent prior to surgery. After induction of anesthesia, patient was put on the traction table and accurate reduction was achieved under C-Arm control. The proximal femur was approached through a lateral incision started at the greater trochanter and extended distally. One guide wire was inserted in the inferior half of the neck at the proposed site of the lag screw and another two guide pins were inserted in the upper half of the neck to avoid rotational force during reaming and insertion of the DHS lag screw. The length of the lag screw was adjusted to keep the tip apex index less than 25 mm. After insertion of the DHS the superior guide wires were removed and partially threaded cancellous screw was inserted parallel to the lag screw of the DHS (Figure 1). The wound was then closed over drain. Active range of movement was encouraged from the second postoperative day. Patients were discharged on an average of 3 days postoperatively and followed up regularly in the outpatient clinic. During each visit patients were examined clinically for wound healing, range of hip and knee movements. Radiological evaluation was done to assess bone union and stability of fixation. Partial weight bearing was allowed from the second postoperative week. Progressive weight bearing was allowed according to the progress of bone healing on the serial radiographs.

RESULTS

The follow up period ranged from 26 to 58 months with an average of 37 months. The operative time ranged from 30 to 80 minutes with an average of 50 minutes. Bone union was achieved in all patients except four. The time to bone union ranged from 3 to 8 month with an average of 5 months. The time to full weight bearing ranged from 2 to 7 months with an average of 4 months.

At the final follow up radiological evaluation was done by measurement of the following parameters on both sides: (1) Femoral neck length: the distance between the center of the head to the axis of the femoral shaft along the femoral neck axis; (2) Horizontal offset of the femoral head: the shortest distance from the femoral head center to the femoral shaft axis; (3) Femoral neck-shaft angle: angle formed by the femoral shaft axis and the femoral neck axis (Figure 2).

The neck length and horizontal offsets were reduced on the operated sides in comparison to the normal sides. The reduction in the neck length ranged from 3 to 8 mm with an average of 5 mm. The reduction in the horizontal offsets ranged from 2 mm to 6 mm with an average of 3 mm. This reduction in neck length and horizontal offset was found statistically to be significant (p value < 0.05). No changes in the neck shaft angles were observed between the operated and non operated sides.

The complications included superficial wound infection in 3 cases, bed sore in 2 patients, nonunion in 4 cases and osteonecrosis in 3 cases. Non union was diagnosed by persistence of the fracture line for more than 6 months without any evidence of healing. Osteonecrosis was diagnosed by collapse and sclerosis of the femoral head. No cases were complicated by implant failure or deep infection. The Harris hip score ranged from 30 to 96 with an average of 86^[10].

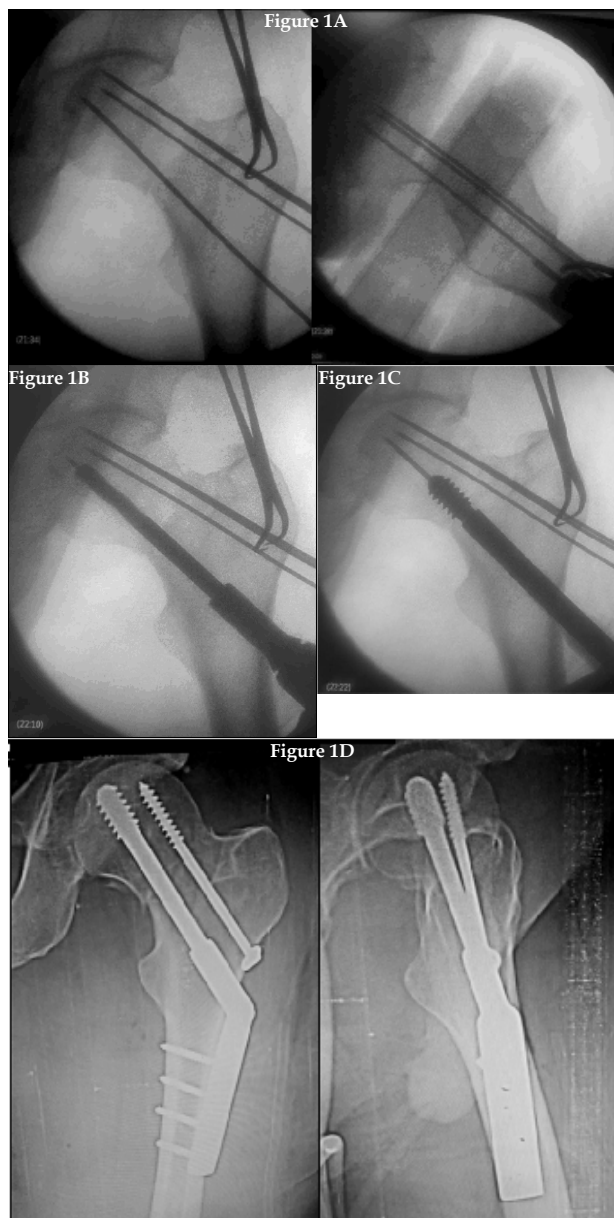


Figure 1A after accurate reduction, one guide wire is inserted in the inferior half of the neck at the proposed site of the lag screw and another two guide pins are inserted in the upper half of the neck.

Figure 1B Reaming is done along the inferior guide wire.

Figure 1C The lag screw is inserted.

Figure 1D The antirotation screw is inserted in the upper half of the neck.

DISCUSSION

Femoral neck fracture is a common orthopedic injury. In young adults treatment is usually done by closed reduction and internal fixation by cannulated screws. Above the age of seventy the ideal way of treatment is by hemi or total hip arthroplasty. In the sixth and seventh decades of life there is a controversy among the surgeons about the best way of treatment. Arthroplasty has the advantages of short postoperative rehabilitation, rapid return to daily activity and avoid the complications of non union and avascular necrosis that are common with internal fixation. On the other hand it is a major surgery with long operative time, increased intraoperative blood loss and high postoperative morbidity and mortality. The mortality rate is approximately 10- 30 % in the first year after surgery. Morbidity rates are about 2% for infection, 1-10% for dislocation, 3% for periprosthetic fractures, 25% for heterotrophic ossifications,

and 50% for deep venous thrombosis. In case of infection or dislocation the scope of reconstruction becomes limited and quite difficult^[9,11,12,13,14].

Internal fixation by cannulated screws has the advantages of being an easy and simple procedure but it has the disadvantages of long treatment time and high post operative complications. The construct of fixation is unstable and the risks of implant failure, nonunion and osteonecrosis are high^[7,15].

Dynamic hip screw is a stable construct. The lag screw produces good grip in the head and the sliding mechanism allows for compression at the fracture site without displacement. Zhang *et al*^[16] compared multiple cannulated screws versus dynamic hip screws for femoral neck fractures. They found that DHS is associated with high overall success rate and lower rates of implant failure, reoperation and postoperative complications.

Internal fixation of fracture neck femur should be optimized according to the patient age and bone quality. In young adults the bone stock is usually good and internal fixation by cannulated screws will produce sufficient stability that outstands bone healing. In the sixth and seventh decades of life the bone stock is reduced and cannulated screws become insufficient and a more stable device should be used^[3,5].

We think that dynamic hip screw would be a good method of fixation for fracture neck femur in this age group. It will allow for early mobilization of the patients and avoids the complications of prolonged recumbence. In the same time it is a simple surgery and preserves the natural head.

In this study 38 patients with displaced fracture neck femur in the sixth and seventh decades of their life were treated by closed reduction and internal fixation by DHS and antirotation screw. Early mobilization by partial weight bearing on crutches was achieved in all patients starting from the second post operative week. The average time to full weight bearing was 4 months. The technique was successful in 31 patients where bone union was achieved without avascular necrosis (Figure 3). Seven cases failed due to non union in four cases and avascular necrosis in 3 cases. The age of the patient and degree of displacement were the main predictors for poor outcome. About 87% of cases with Garden 3 fractures were successful while only 73% of cases with Garden 4 fractures were successful. Four of the seven cases with serious complications were above 65 year-old (Table 1). Precise application of the lag screw is very crucial for the stability of fixation. It should be inserted central in the inferior half of the neck with the tip apex index less than 25 mm. The antirotation screw is inserted in the upper half of the neck parallel to the lag screw in order to prevent rotation and allow compression at the same time^[18,19]. Following these rules, we achieved sufficient stability in our patients and no cases were complicated by implant failure or loss of fixation. The fractures united in 34 cases and failed to unit in 4 cases. The time to bone union ranged from 3- 8 months with an average of 5 months.

The neck length and the horizontal offsets were reduced significantly on the affected sides which means that axial collapse seems to be mandatory for bone healing of fracture neck femur. The device of fixation should allow this shortening to occur.

The complications did not affect the final outcome except in 7 cases. The four cases that were complicated by nonunion were treated by hemiarthroplasty while the three cases that were complicated by avascular necrosis were treated by total hip arthroplasty. The three cases with superficial wound infection were treated by wound debridement and systemic antibiotics. The two cases with bed sores improved once they started weight bearing.

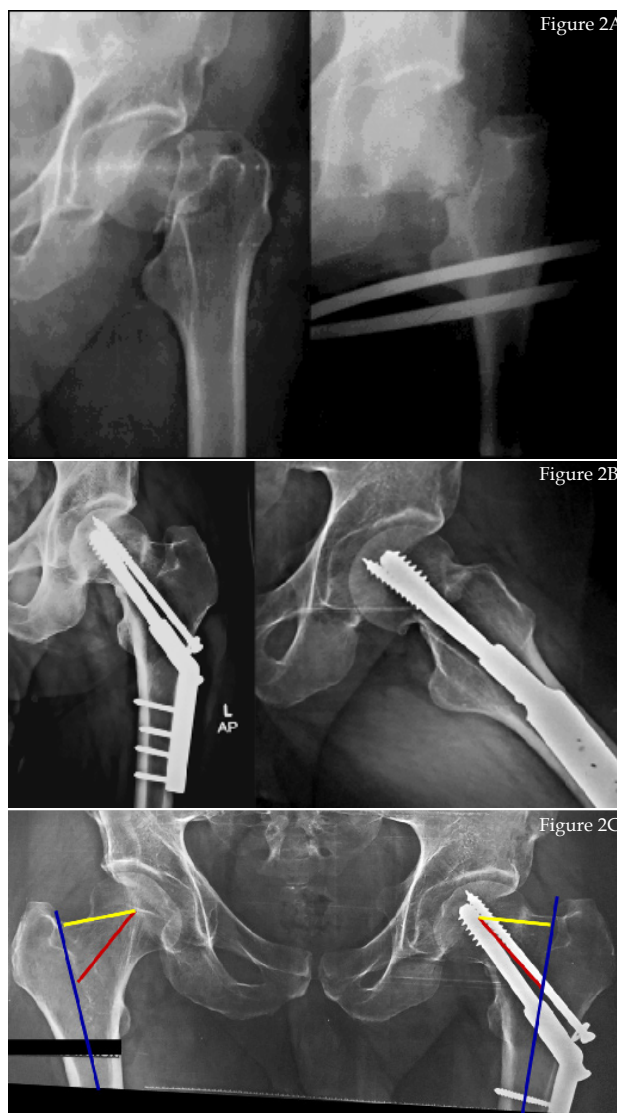

Figure 2A 58 year-old male patient with displaced fracture neck femur.
Figure 2B The radiographs three months after surgery with complete bone healing.
Figure 2C At the final follow up, the following parameters are measured on both sides: The femoral neck length (red line), horizontal offset of the femoral head (yellow line) and the neck shaft angle (between the red and blue line).

Table 1 Incidence of complications according to the age of the patients and displacement of the fractures.

Parameter	No	Avascular necrosis	Nonunion
Age distribution			
50 - 55 years	8	-	-
56 - 60 years	11	-	1
61 - 65 years	10	1	1
66 - 70 years	9	2	2
Displacement			
Garden type III	23	1	2
Garden type IV	15	2	2

Wani *et al*^[7] compared internal fixation versus arthroplasty in treatment of fracture neck femur in the same age group. They found that hip arthroplasty improves the hip function and reduces the risk of reoperation but at the cost of high complication rate, long operative time and length of hospital stay. The inferior results in the internal fixation group in their series may be related

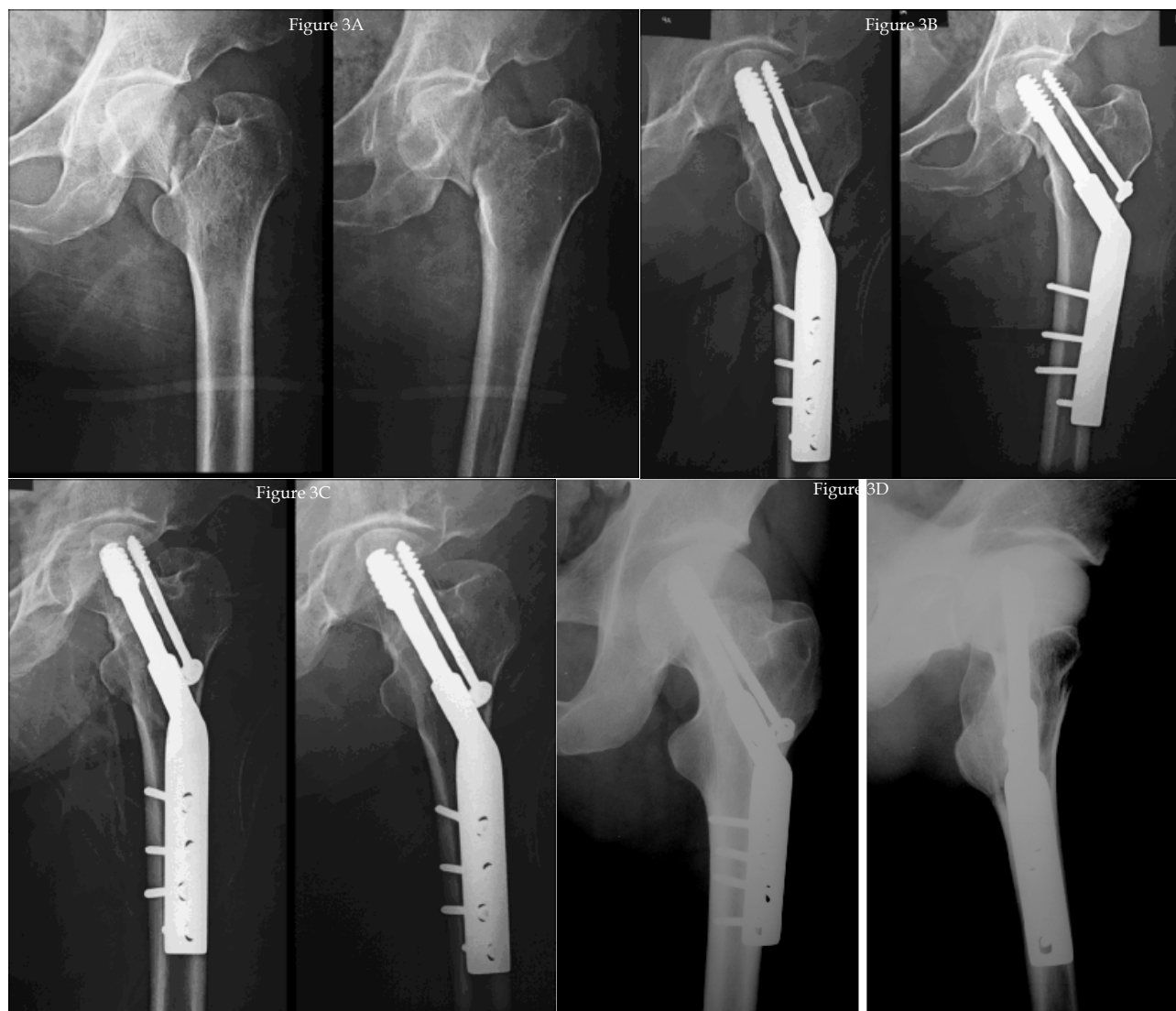

Figure 3A 62 year-old male patient with displaced fracture neck femur.
Figure 3C The radiographs 6 months after surgery.

Figure 3B The early post operative radiographs.
Figure 3D The radiographs two years after surgery with complete bone healing.

to the method of fixation. They used cannulated screws which is unstable construct that does not allow early weight bearing and has a high failure rate. Amnian *et al*^[15] compared the biomechanical stability of four different fixation techniques for stabilizing vertical shear femoral neck fractures. They found that the weakest construct was the 7.3-mm cannulated screw configuration. Failure occurs by backing out of the screws and varus collapse.

In this study we found that internal fixation by DHS and antirotation screws is quite beneficial. It provides sufficient stability that allow for early weight bearing without loss of fixation. The stable fixation together with the cyclic loading of the body weight exert more compression at the fracture site which increases the chance of bone healing. Also it is a simple surgery with short operative time and decreased intraoperative bleeding. We are in agreement of Zhang *et al*^[6] that DHS is recommended in elderly patients with osteoporosis due to its simplicity, efficacy, and stability.

CONCLUSION

Internal fixation of fracture neck femur in the sixth and early seventh decades of life by DHS and antirotation screw has the advantages of short operative time and early weight bearing with high union rate. It is a hip preserving surgery and if non union or avascular necrosis had

occurred, hip arthroplasty could be done without major difficulties. Patients above the age of 65 years and patients with Garden type IV fractures carry the risk of poor results.

Ethical standards

Informed consent: Informed consent was obtained from all individual participants included in the study.

REFERENCES

1. Zetterberg C, Elmerson S, Andersson GB. Epidemiology of hip fractures in Göteborg, Sweden, 1940-1983. *Clin Orthop Relat Res* 1984; **(191)**: 43-52. [PMID: 6499323]
2. Lu-Yao GL, Keller RB, Littenberg B, Wennberg JE. Outcomes after displaced fractures of the femoral neck. A meta-analysis of one hundred and six published reports. *J Bone Joint Surg Am* 1994; **76(1)**: 15-25. [PMID: 8288658]; [DOI: 10.2106/00004623-199401000-00003]
3. Lowe JA, Crist BD, Bhandari M, Ferguson TA. Optimal treatment of femoral neck fractures according to patient's physiologic age: an evidence-based review. *Orthop Clin North Am* 2010; **41(2)**: 157-66. [PMID: 20399355]; [DOI: 10.1016/j.ocl.2010.01.001]
4. Lieberman JR, Romano PS, Mahendra G *et al.* The treatment of hip fractures: variations in care. *Clin Orthop Relat Res*

- 2006; **442**: 239-24. [PMID: 16394767]; [DOI: 10.1097/01.blo.0000188558.67172.4e]
5. Slobogean GP, Sprague SA, Scott T, McKee M, Bhandari M. Management of young femoral neck fractures: is there a consensus? *Injury* 2005; **46(3)**: 435-40. [PMID: 25530411]; [DOI: 10.1016/j.injury.2014.11.028]
 6. Chammout GK, Mukka SS, Carlsson T, Neander GF, Stark AW, Skoldenberg OG. Total hip replacement versus open reduction and internal fixation of displaced femoral neck fractures: a randomized long-term follow-up study. *J Bone Joint Surg Am* 2012; **94(21)**: 1921-8. [PMID: 23014835]; [DOI: 10.2106/JBJS.K.01615]
 7. Wani IH, Sharma S, Latoo I, Salaria AQ, Farooq M, Jan M.J. Primary total hip arthroplasty versus internal fixation in displaced fracture of femoral neck in sexa- and septuagenarians. *Orthop Traumatol* 2014; **15(3)**: 209-14. [PMID: 24385140]; [DOI: 10.1007/s10195-013-0278-3]
 8. Miller CW. Survival and ambulation following hip fracture. *J Bone Joint Surg Am* 1978; **60**: 930-934. [PMID: 701341]
 9. Raaymakers EL. Fractures of the femoral neck: a review and personal statement. *Acta Chir Orthop Traumatol Cech* 2006; **73(1)**: 45-59. [PMID: 16613748]
 10. Harris WH. Traumatic arthritis of the hip after dislocation and acetabular fractures: treatment by mold arthroplasty: an end result study using a new method of result evaluation. *J Bone Jt Surg Am* 1969; **51-A**: 737-755. [PMID: 5783851]
 11. Chammout GK, Mukka SS, Carlsson T, Neander GF, Stark AW, Skoldenberg OG. Total hip replacement versus open reduction and internal fixation of displaced femoral neck fractures: a randomized long-term follow-up study. *J Bone Joint Surg Am* 2012; **94(21)**: 1921-8. [PMID: 23014835]; [DOI: 10.2106/JBJS.K.01615]
 12. Varady NH, Ameen BT, Hayden BL, Yeung CM, Schwab PE, Chen AF. Short term morbidity and mortality after hemiarthroplasty and total hip arthroplasty for pathologic proximal femur fractures. *J Arthroplasty* 2019; **34(11)**: 2698-2703. [PMID: 31279601]; [DOI: 10.1016/j.arth.2019.06.019]
 13. Garland A, Gordon M, Garellick G, Kärrholm J, Sköldenberg O, Hailer NP. Risk of early mortality after cemented compared with cementless total hip arthroplasty: a nationwide matched cohort study. *Bone Joint J* 2017; **99-B(1)**: 37-43. [PMID: 28053255]; [DOI: 10.1302/0301-620X.99B1.BJJ-2016-0304.R1]
 14. Weiss RJ, Kärrholm J, Rolfson O, Hailer NP. Increased early mortality and morbidity after total hip arthroplasty in patients with socioeconomic disadvantage: a report from the Swedish Hip Arthroplasty Register. *Acta Orthop* 2019; **90(3)**: 264-269. [PMID: 30931670]; [DOI: 10.1080/17453674.2019.1598710]
 15. Aminian A, Gao F, Fedoriw WW, Zhang LQ, Kalainov DM, Merk BR. Vertically oriented femoral neck fractures: mechanical analysis of four fixation techniques. *J Orthop Trauma* 2007; **21(8)**: 544-8. [PMID: 17805021]; [DOI: 10.1097/BOT.0b013e31814b822e]
 16. Zhang LL, Zhang Y, Ma X, Liu Y. Multiple cannulated screws vs. dynamic hip screws for femoral neck fractures: A meta-analysis. *Orthopade* 2017; **46(11)**: 954-962. [PMID: 29022057]; [DOI: 10.1007/s00132-017-3473-8]
 17. Ma JX, Kuang MJ, Xing F, Zhao YL, Chen HT, Zhang LK, Fan ZR, Han C, Ma XL. Sliding hip screw versus cannulated cancellous screws for fixation of femoral neck fracture in adults: A systematic review. *Int J Surg* 2018; **52**: 89-97. [PMID: 29471156]; [DOI: 10.1016/j.ijssu.2018.01.050]
 18. Rubio-Avila J, Madden K, Simunovic N, Bhandari M. Tip to apex distance in femoral intertrochanteric fractures: a systematic review. *J Orthop Sci* 2013; **18(4)**: 592-8. [PMID: 23636573]; [DOI: 10.1007/s00776-013-0402-5]
 19. Chen Z, Wang G, Lin J, Yang T, Fang Y, Liu L, Zhang H. Efficacy comparison between dynamic hip screw combined with anti-rotation screw and cannulated screw in treating femoral neck fractures. *Zhongguo Xiu Fu Chong Jian Wai Ke Za Zhi* 2011; **25(1)**: 26-9. [PMID: 21351604]