

Implant-Related Complications Following Proximal Femoral Nail Antirotation (PFNA) in Unstable Intertrochanteric Fractures – Early Follow Up

Shafat A Gangoo¹, Steven Cutts², G Charnley³

1 James Paget University Hospital, Great Yarmouth. Norfolk. NR31 6LA, United Kingdom;

2 Trauma & Orthopaedics, James Paget University Hospital. Great Yarmouth, United Kingdom;

3 Trauma & Orthopaedics, Broomfield Hospital, Chelmsford, Essex, United Kingdom.

Conflict-of-interest statement: The author(s) declare(s) that there is no conflict of interest regarding the publication of this paper.

Open-Access: This article is an open-access article which was selected by an in-house editor and fully peer-reviewed by external reviewers. It is distributed in accordance with the Creative Commons Attribution Non Commercial (CC BY-NC 4.0) license, which permits others to distribute, remix, adapt, build upon this work non-commercially, and license their derivative works on different terms, provided the original work is properly cited and the use is non-commercial. See: <http://creativecommons.org/licenses/by-nc/4.0/>

Correspondence to: Shafat A Gangoo, James Paget University Hospital, Great Yarmouth. Norfolk. NR31 6LA, United Kingdom.
Email: shafat333g@yahoo.com

Received: March 3, 2020

Revised: March 30, 2020

Accepted: April 2 2020

Published online: April 28, 2020

ABSTRACT

INTRODUCTION: Intertrochanteric fractures present in a wide variety of patterns that range from simple to complex and may be minimally displaced or widely displaced. Unstable intertrochanteric fracture can fail due to mechanical problems, including loss of fixation, re fracture, or implant failure.

PURPOSE: The aim of this study was to analyse the failures in patients with unstable intertrochanteric femur fractures treated with Proximal Femoral nail Antirotation (Synthes).

METHODS: A retrospective analysis of 97 patients with unstable intertrochanteric fractures (AO: 31A2: $n = 65 / 67.01\%$; 31-A3: $n = 32 / 32.9\%$; treated with a Proximal femoral nail Antirotation

(PFNA) in a self-contained District general hospital was conducted.

RESULTS: Study included 25 (26%) Males and 72 (74%) Females with mean age of 82 years. Study period over was 12 months with mean follow up 15 months (range 6 to 18 months). Intraoperative and Postoperative radiographs showed good reduction in 80, acceptable in 12 and 3 were deemed suboptimal. 20 patients had implant related complications. Consequently 10 patients (10.5 %) had to undergo revision surgery. Reasons of revision; Implant failures = 8 (8.4%) all were revised; Helical Blade backing out more than 1 cm = 9, only one (1.05 %) revised) and Greater trochanter splintering = 3 only 1 (1.05%) required revision.

CONCLUSION: Implant related complications requiring revision occurred in 10.5 % (10) in early term follow up. Of those requiring revision 6 patients had highly unstable 31 A2.3 type fracture. Our study reinforces high failures in unstable intertrochanteric fractures. Though Ideal implant remains elusive but Optimum intraoperative reduction and use of augments should be considered to improve outcomes.

Key Words: Unstable Inter trochanteric fracture; Cephalomedullary nail; PFNA; Mechanical complications

© 2020 The Author(s). Published by ACT Publishing Group Ltd. All rights reserved.

Gangoo SA, Cutts S, Charnley G. Implant-Related Complications Following Proximal Femoral Nail Antirotation (PFNA) in Unstable Intertrochanteric Fractures - Early Follow Up. *International Journal of Orthopaedics* 2020; 7(2): 1248-1251 Available from: URL: <http://www.ghrnet.org/index.php/ijo/article/view/2820>

INTRODUCTION

Intertrochanteric account for approximately 50% of all fractures in the proximal femur. These fractures occur mainly in elderly patients with osteoporosis and are a result of low-energy trauma and cause severe disability in such patients^[1]. Hagino et al. reported that individuals above 50 years of age have a lifetime risk of hip fractures and the incidence is 5.6% for men and 20% for women^[2]. The challenging goal in management of Unstable trochanteric Fractures is to achieve anatomical reduction with a stable fracture fixation, with

low morbidity and early mobilization. No implant is universally fit for these fractures and the best method of surgical fixation remains debatable.

The Intramedullary nail (PFNA - Synthes) provides an intramedullary construct with the advantages of a reduced level arm compared to extra medullary fixation. Several studies reported high-failure rates associated with this implant, such as implant failure, secondary. Varus collapse and screw cut-out. To prevent these complications, the importance of anatomical reduction and medial calcar support to prevent secondary Varus collapse and implant failure has been outlined^[3-10]. Fixation of proximal femoral fractures especially in old with osteoporosis remains a challenge. The cervical, trochanteric, and sub trochanteric fractures at all three levels in proximal femur increase with age and are greater for women than men^[11].

The aim of this study was to assess the reasons of revision in unstable intertrochanteric fractures treated with PFNA.

MATERIALS AND METHODS

We conducted a retrospective analysis of patients who underwent Proximal femur Nail Anti-rotation (Synthes) fixation for an unstable intertrochanteric fracture in our centre over a twelve months period. Radiographs of 156 patients were analysed for the type of fracture, the time to union, mechanical failures and for any revision procedures. Fractures were classified according to Arbeitsgemeinschaft für Osteosynthesefragen (AO), Figure 1^[19].

Fracture union was defined as radiological signs of fracture healing in three out of four cortices in conventional radiography or consolidation in computed tomography. Delayed-union was defined as missing radiological fracture healing after 6 months or no progressive signs of fracture healing in between the three- and 6-month controls. Other measurements were demographic data; age, gender and the grade of surgeon operating.

Inclusion criteria were the presence of unstable intertrochanteric fractures; 31 A2 and 31 A3 in patients over 65 years with no additional ipsilateral fracture. A sufficient follow-up was fulfilled when there were follow up radiographs available for review. Patients with stable Intertrochanteric fractures (AO 31 A1), pathological fractures, periprosthetic fractures (*n* = 44) were excluded from the study, figure 1, 17 patient with no follow up x rays were excluded as well. Total of 97 patients fulfilled the criteria and were included in the study. Patient's data were acquired from electronic patient's charting system. Mean follow-up was 15 months, ranging from 4 months to 18 months.

RESULTS

20 patients had implant related complications. Consequently 10 patients (10.5 %) had to undergo revision surgery. 8 patients (8.4%) had Implant related failures (Table 1); Helical blade cut out in three, Helical blade backed out more than 1 cm one, Implant fracture one, Migration of nail one, Peri prosthetic fracture one, and distal screw breakage broke in one. In 9 cases Helical Blade backed out more than 1 cm; only one (1.05%) was revised for impingement symptoms. 3 patients had Greater trochanter splintering and only 1 (1.05%) required revision, the splintering of greater trochanter was present pre operatively. One patient was revised due to malposition of the implant purely due to deficient technique. All implant failure had reoperations between 3 days to 4 months post index operation. The most common mechanical complication was the backing out or lateral migration of the helical blade, however only one patient is this

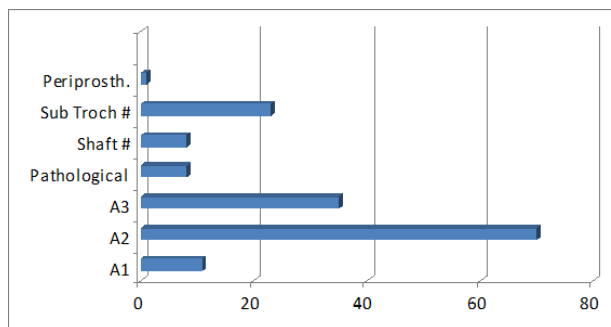


Figure 1 Fracture pattern in Pre-Operative X-rays (*n* = 156).

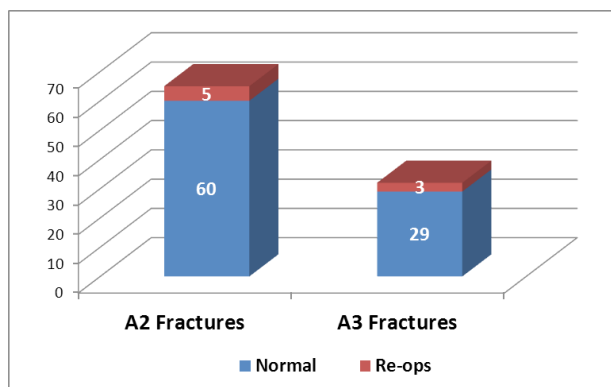


Figure 2 Distribution of Reoperations in 31A2 and 31A3 (*n* = 97) fracture types.

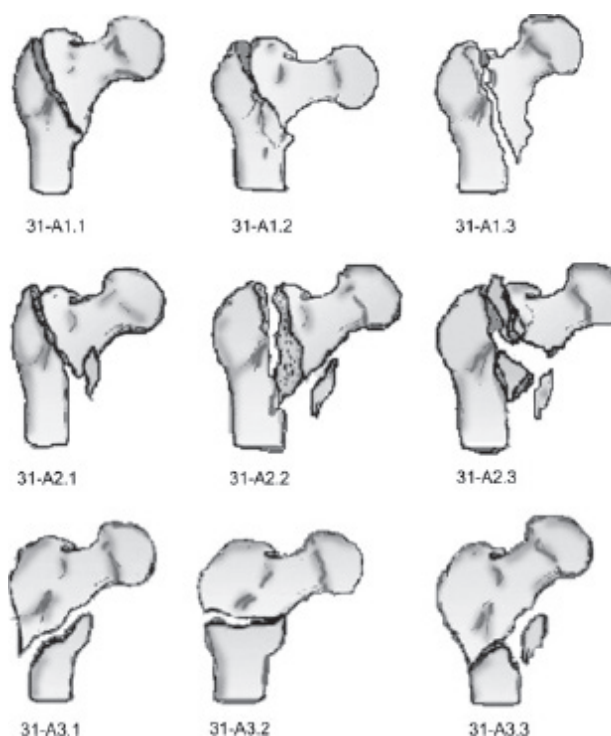


Figure 3 AO/ASIF classification for trochanteric femur fractures, Müller et al.

group had to be revised.

There was no case of non-union in our series, but three cases showed delayed union with Varus collapse.

All the revised cases had suboptimal intraop reduction of fracture and or suboptimal placement of the Helical blade. There was no difference in revision rate whether the index procedure was carried

Table 1 Breakdown of types of Mechanical failure.

Fracture type	Cause of failure	Grade of Surgeon	Revision procedure
A3.1	Helical blade backed out	MG	Revised to proximal femoral locking plate
A3.1	PFNA broke after 10 weeks	MG	Revised to DCS
A3.1	Helical blade cut out in 4 days, eccentric placement	MG	THR + stabilisation plate
A2.3	Distal screw backed out	Consultant	Redo distal locking
A2.3	Helical blade cut out in 2 weeks, eccentric placement	Consultant	Revised to DCS
A2.3	Nail migrated	MG	Exchange nailing
A2.3	Periprosthetic fracture	Consultant	Conversion to long PFNA following periprosthetic fracture

out by consultant or middle grade surgeon.

Cerclage wire was utilised as an adjunct in reduction and fixation of 6 highly unstable intertrochanteric fractures (31 A2.3 & 31 A3. fracture types) all of these cases healed in acceptable position.

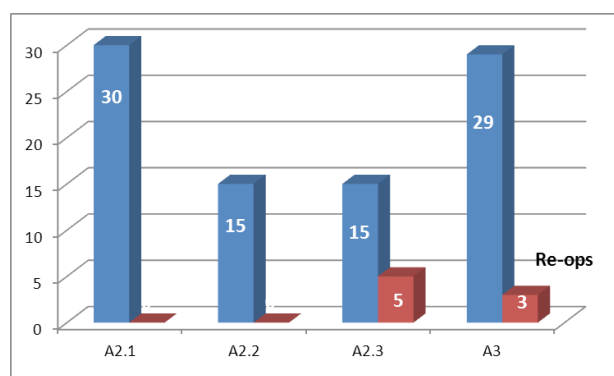
DISCUSSION

Unstable trochanteric fractures are considered to have one or more of the following configurations; posteromedial comminution, reverse obliquity, sub trochanteric extension, IT fractures with avulsed greater trochanter and lateral wall breach. Intramedullary devices have an advantage of load sharing with smaller bending moments allowing early weight bearing and preventing excessive collapse^[12]. The medial and posteromedial fracture fragments have been considered to be important elements in determining the severity of intertrochanteric hip fracture^[13]. unstable intertrochanteric fractures usually accompanied by poor bone quality have high failure rates, ranging from 18% to 56%^[14-15] The ideal implant to choose to fix unstable trochanteric fractures remains elusive and is a topic of debate with proponents of the various implants, each claiming advantages over the other methods^[16]. The failure rates of these unstable fractures fixed with sliding hip screws averages approximately 6-32%^[6-10]. Intramedullary devices, such as the gamma nail (GN) and proximal femoral nail (PFN) have some theoretical advantage over the DHS. However, gamma nail (GN) has a failure rate ranging from 12.7% to 15% in various studies^[17-22]. As for PFN, Fogagnolo et al. found that the intraoperative technical or mechanical complication rate is as high as 23.4%^[23]. In unstable intertrochanteric fractures CMN demonstrated significantly reduced failure and collapse rates when compared to SHS^[24].

Apel et al. showed that in unstable intertrochanteric femoral fractures, the fixation of large and small posteromedial bone fragments increased the mechanical stability by 57% and 17%, respectively while there was no general consensus regarding when to use cerclage wires or screws^[25].

In our study, we evaluated the outcome of the patients, and the fracture healing and related complications arising from the intramedullary construct in unstable intertrochanteric fractures. Our results showed 20 patients had implant related complications. Consequently 10 patients (10.5%) had to undergo revision surgery. The revised cases had suboptimal intraop reduction of fracture and or suboptimal placement of the Helical blade. To maintain the reduction achieved intraoperatively, the decision to use an adjunct like cerclage wiring or loop may be considered. A better implant does not compensate for an inadequate surgical approach or deficient surgical techniques which are paramount for successful treatment. There was no difference in revision rate whether the index procedure was carried out by consultant or middle grade surgeon.

The mechanical complication following unstable intertrochanteric fracture remains high. Our findings are corroborated by The (AO - PFNA study group) leading to (8.8%) unplanned re-operation^[26].

**Figure 4** Reoperation distribution.

CONCLUSIONS

When fixing fractures with intramedullary nailing systems, achieving anatomic reduction and a perfect implant positioning is key to allow immediate full weight bearing and minimise risk of cut-out, non-union and implant failure in unstable intertrochanteric fractures. Cerclage wires as an augmentation may be considered to get anatomical reduction and support to posteromedial and greater trochanteric comminution.

REFERENCES

- Zuckerman JD. Hip fractures. *N Engl J Med.* 1996; **334**: 1519. [PMID: 8975123]; [DOI: 10.1056/NEJM199612263352612]
- Hagino H, Furukawa K, Fujiwara S, et al. Recent trends in the incidence and lifetime risk of hip fracture in Tottori, Japan. *Osteoporosis Int.* 2009; **20**(4): 543-548. [PMID: 18633667]; [DOI: 10.1007/s00198-008-0685-0]
- Kyle RF, Gustillo RB, Premer RF. Analysis of six hundred and twenty two intertrochanteric hip fractures. *J Bone Jt Surg.* 1979; **216**. [PMID: 422605]
- Mariani E, Rand JA. Nonunion of intertrochanteric fractures of the femur following open reduction and internal fixation. *Clin Orthop Relat Res.* 1987; **218**: 81. [PMID: 3568500]
- Haentjens P, Casteleyn PP, De Boeck H, et al. Treatment of unstable intertrochanteric and subtrochanteric fractures in elderly patients. *J Bone Joint Surg Am.* 1989; **71**(8): 1214-1225. [PMID: 2777850]
- Gundle R, Gargan MF, Simpson HRW. How to minimize failure of fixation of unstable intertrochanteric fractures. *Injury.* 1995; **26**: 611-614. [PMID: 8550168]; [DOI: 10.1016/0020-1383(95)00125-s]
- Simpson AHRW, Varty K, Dodd CA. Sliding hip screws: modes of failure. *CAF. Injury.* 1989; **20**: 227-231. [PMID: 2592101]; [DOI: 10.1016/0020-1383(89)90120-4]
- JanErikMadsen,LeifNaess,ArneKristianAune,AnttiAlho,Arne Ekeland,Knut Stromsoe. Dynamic Hip Screw with trochanteric stabilising plate in the treatment of unstable proximal femoral fractures: a comparative study with the Gamma nail and Compression Hip Screw. *J Orthop Trauma* 1998; **12**(May (4):

- 241-8. [PMID: 2592101]; [DOI: 10.1016/0020-1383(89)90120-4]
9. Haidukewych GJ, Israel TA, Berry DJ. Reverse obliquity fractures of the intertrochanteric region of the femur. *J Bone Joint Surg Am* 2001; **83**: 643-50.
 10. Sadowski C, Lubbeke A, Saudan M, Riand N, Stern R, Hoffmeyer P. Treatment of reverse oblique and transverse intertrochanteric fractures with the use of an intramedullary nail or a 95 degree screw-plate. *J Bone Joint Surg Am* 2002; **84**: 372-82. [PMID: 11886906]
 11. Hinton RY, Lennox DW, Ebert FR, et. al.: Relative rates of fracture of the hip in the United States. Geographic, sex, and age variations. *J Bone Joint Surg Am* 1995; **77**: 695-702. LOE II. [PMID: 7744894]; [DOI: 10.2106/00004623-199505000-00005]
 12. Jones HW, Johnston P, Parker M (2006) Are short femoral nails superior to the sliding hip screw? A meta-analysis of 24 studies involving 3279 fractures. *Int Orthop* **30(2)**: 69-78. [PMID: 16496147]; [PMCID: PMC2532072]
 13. Clawson DP, Melcher PJ. Fractures and dislocation of the hip, in Fractures. Rockwood CA, Green DP, Editors. Philadelphia, JB, Lippincott Company, 1975; 1012-1074. [PMID: 25086117]; [DOI: 10.1302/0301-620X.96B8.33644]
 14. Haidukewych GJ, Israel TA, Berry DJ. Reverse obliquity fractures of the intertrochanteric region of the femur. *J Bone Joint Surg Am* 2001; **83-A**: 643-650. [PMID: 11379732]; [DOI: 10.2106/00004623-200105000-00001]
 15. Kashigar A, Vincent A, Gunton MJ, Backstein D, Safir O, Kuzyk PR. Predictors of failure for cephalomedullary nailing of proximal femoral fractures. *Bone Joint J* 2014; **96-B**: 1029-1034. [PMID: 25086117]; [DOI: 10.1302/0301-620X.96B8.33644]
 16. Steinberg EL, Nehemia B, Dekel S. The fixation proximal femur nailing system: biomechanical properties of the nailing and a cadaveric study. *J Biomech* 2005; **38**: pp. 63 [PMID: 15519340]; [DOI: 10.1016/j.jbiomech.2004.03.014]
 17. Valverde Jose A, Alonso Manuel G, Porro Jaime G, Rueda Domingo, Larrauri Pedro M, Soler Juan J. Use of the Gamma nail in the treatment of fractures of the proximal femur. *J Orthop Trauma* 2003; **8**: S51-6 [PMID: 14696778]; [DOI: 10.1097/00005131-200309001-00010]
 18. Lorich DG, Geller DS, Nielson JH. Osteoporotic pertrochanteric hip fractures: management and current controversies. *J Bone Joint Surg Am* 2004; **86**: 398 [PMID: 15116633]
 19. Saarenpaa, T. Heikkinen, J. Ristiniemi. Functional comparison of the dynamic hip screw and the gamma locking nail in trochanteric hip fractures: a matched-pair study of 268 patients *Int Orthop*, 2009; **33(1)**: 255-260
 20. C. Sadowski, A. Lübbeke, M. Saudan, *et al.* Treatment of reverse oblique and transverse intertrochanteric fractures with use of an intramedullary nail or a 95 degrees screw-plate: a prospective, randomized study. *J Bone Joint Surg Am* 2002; **84**: pp. 372-381 [PMID: 28097113]; [PMCID: PMC5240315]
 21. Schipper IB, Steyerberg EW, Castelein RM, *et al.* Treatment of unstable trochanteric fractures. Randomised comparison of the gamma nail and the proximal femoral *J Bone Joint Surg Br*, 2004; **86(1)**: 86-94. [PMID: 14765872]
 22. Sehat K, Baker RP, Pattison G, *et al.* The use of the long gamma nail in proximal femoral fractures. *Injury* 2005; **36(11)**: 1350-1354. [PMID: 16054630]
 23. Fogagnolo F, Kfuri Jr M, Paccola CAJ. Intramedullary fixation of pertrochanteric hip fractures with the short AO-ASIF proximal femoral nail. 2004. [PMID: 13680275]
 24. Whale CS, Hulet DA, Beebe MJ, Rothberg DL, Zhang C, Presson AP, Stuart AR, Kubiak EN. Cephalomedullary nail versus sliding hip screw for fixation of AO 31 A1/2 intertrochanteric femoral fracture: a 12-year comparison of failure, complications, and mortality. *Curr Orthop Pract* 2016 November 1; **27(6)**: 604-613. [PMID: 28348717]; [PMCID: PMC5364496]
 25. Apel DM, Patwardhan A, Pinzur MS, Dobozi WR. Axial loading studies of unstable intertrochanteric fractures of the femur. *Clin Orthop Relat Res* 1989; undefined: 156-164. [PMID: 2766604]
 26. Simmermacher RK, Ljungqvist J, Bail H, Hockertz T, Vochteloo AJ, Ochs U, Werken Cv; AO - PFNA studygroup. The new proximal femoral nail antirotation (PFNA) in daily practice: results of a multicentre clinical study. *Injury*. 2008 Aug; **39(8)**: 932-9. [PMID: 18582887]