

Tips And Tricks to Obtain Good Results in the Surgical Treatment of Congenital Scoliosis By Posterior Hemivertebra Resection and Segmental Spinal Fusion

Stefan Gavrilu^{1,2}, Ecaterina Maria Japie¹, Serban Hamei¹, Bianca Mihaescu¹, Cosmin Simion¹

1 “Maria Sklodowska Curie” Hospital, Bucharest, Romania;

2 “Carol Davila” University of Medicine and Pharmacology, Bucharest, Romania.

Conflict-of-interest statement: The author(s) declare(s) that there is no conflict of interest regarding the publication of this paper.

Open-Access: This article is an open-access article which was selected by an in-house editor and fully peer-reviewed by external reviewers. It is distributed in accordance with the Creative Commons Attribution Non Commercial (CC BY-NC 4.0) license, which permits others to distribute, remix, adapt, build upon this work non-commercially, and license their derivative works on different terms, provided the original work is properly cited and the use is non-commercial. See: <http://creativecommons.org/licenses/by-nc/4.0/>

Correspondence to: Stefan Gavrilu, “Carol Davila” University of Medicine and Pharmacology, Bucharest, Romania.

Email: banteo@gmail.com

Telephone: +40722515011

Received: March 17, 2020

Revised: April 12, 2020

Accepted: April 17 2020

Published online: April 28, 2020

ABSTRACT

Fully segmented hemivertebra represents one of the most frequent cause of congenital scoliosis. This spinal malformation requires in many cases surgery and nowadays the *golden standard* is represented by posterior hemivertebra resection and segmental posterior fusion. The technique is a demanding one, but with proper preoperative planning and careful surgery, it ensures good results. Some tips and tricks are useful to avoid poor results and re-interventions.

Key Words: Hemivertebra, Congenital scoliosis, Posterior approach, Segmental fusion

© 2020 The Author(s). Published by ACT Publishing Group Ltd. All rights reserved.

Gavrilu S, Japie EM, Hamei S, Mihaescu B, Simion C. Tips And Tricks to Obtain Good Results in the Surgical Treatment of Congenital Scoliosis By Posterior Hemivertebra Resection and Segmental Spinal Fusion. *International Journal of Orthopaedics* 2020; 7(2): 1236-1238 Available from: URL: <http://www.ghrnet.org/index.php/ijo/article/view/2832>

INTRODUCTION

Scoliosis due to hemivertebra is one of the most frequent deformity encountered in congenital spinal problems. The presence of a fully segmented hemivertebra may evolve with a progressive spine curve, and usually it requires surgery at an early age in order to avoid the presence of a severe and stiff scoliosis, degenerative changes of the involved spinal segment and possible consequent neurological issues like paresthesia or even paralysis^[1]. Very often, these congenital malformations of the spine are associated with malformations of other systems, like cardiac, vascular, renal, nervous, genitor-urinary and/or digestive system. These malformations are important to be diagnosed and addressed to avoid complications before, during and after surgery. Nowadays the golden standard in the surgical treatment of hemivertebra is represented by hemivertebra resection by posterior approach and segmental fusion, involving the fusion of a limited number of adjacent vertebrae. This technique described by Ruf and Harms is represented by piece-by-piece hemivertebra resection (posterior arch, pedicle, hemivertebral body and adjacent disks), followed by a short fusion of the upper and lower normal vertebrae fixed with 4 anchorage points and 2 longitudinal rods^[2]. Proper diagnosis of the spinal deformity, associated spinal malformations and surgical technique, when dealing with hemivertebrae, will ensure best treatment results and avoid serious surgery related complications. A series of tips and tricks may ensure best surgical outcomes in many instances.

PROPER DIAGNOSIS OF THE DEFORMITY

In many spinal congenital malformations due to formation and segmentation defects, the findings on the plain X-rays are not actually corresponding to the real malformation. The correspondence to the spatial relationship of each structure of the vertebrae should be described properly. That's why it is mandatory to perform a CT-3D whole spinal column scan when dealing with a congenital scoliosis.

We may have the surprise that the anterior component of the malformation does not match to the posterior one, also known in the literature as “discordant anomaly”. These types of anterior-posterior discordances may be due to posterior formation and segmentation defects^[3]. When dealing with these issues, the preoperative planning should be in accordance to these anomalies and the hemivertebra resection technique and posterior fixation require adaptation to the situation (Figure 1). A careful analysis of the patients imagistic exams (X-rays, CT-scan and MRI) may highlight other malformations like medullar anomalies, spinal dysraphism^[4] or the presence of a L5 mega-apophysis articulating to the sacrum (Figure 2). The presence of these conditions require special attention and actions in order to avoid disasters and to obtain best correction of the spinal curves. Diastematomyelia has to be removed before hemivertebra resection to avoid medullar impairment during spinal surgery and the mega-apophysis, if present, should be resected to avoid further worsening of the lumbar scoliotic curve and pelvic imbalance.

PROPER TIMING OF THE SURGICAL PROCEDURE

Best results of hemivertebra resection is at an early age, starting with 1.5 years of age up to 6 years of age^[5]. The main goal in the treatment of congenital scoliosis due to hemivertebra is to prevent curve progression and to ensure a proper growth of the spine. Delaying of hemivertebra resection in children with scoliotic curve progression may result in the presence of deformities which develop degenerative changes, neurologic risks and require longer fusions with difficult-to-obtain good results (Figure 3). Some time ago the literature presented concerns on the use of pedicle screws in small children with growth potential, related to the growth of the spinal canal. Ruf and Harms proved that their technique did not show a considerable shortcoming on the spinal growth and did not result in any narrowing of the spinal canal^[6]. Maybe the avoidance to use a cross-link in this technique is also a factor permitting a proper development of the spinal canal in very young patients.

PROPER SURGICAL TECHNIQUE

Proper planning and respecting the surgical technique described by Ruf and Harms ensures best surgical results and allows a normal growth of the spine in young patients. The steps of this technique supposes pre- and intraoperative hemivertebra identification, a short posterior approach centered on the spinous processes of the upper and lower adjacent vertebrae. Two pedicular screws are placed in the vertebrae above and below the hemivertebra, opposite to it (on the concave side). The spine is stabilized by a short rod fixed to these two screws. Next the hemivertebra is resected, component by component (hemilamina, pedicle, hemivertebral body and both disks, above and below the hemivertebra). The intercostal nerve corresponding to a thoracic hemivertebra should be protected in order to avoid neurologic sensitive issues. A careful management of the procedure avoids hemorrhage, medullar and visceral lesions. The complete hemivertebra resection, with both hemidisks, should be checked intraoperative by fluoroscopy. The presence of disk and hemivertebra parts will lead to pseudarthrosis with consecutive complications. After complete hemivertebra resection, another two pedicular screws are placed in the upper and lower vertebrae, on the side of hemivertebra resection. The second rod is placed and careful compression is performed to close the gap left by the resection of the hemivertebra and not to “squeeze” the spinal cord. This maneuver ensures curve correction. The rod on the opposite side should be loose on the screws during

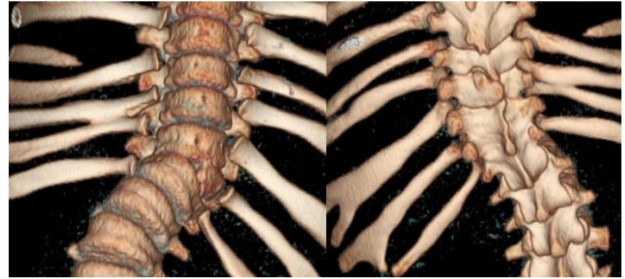


Figure 1 Congenital scoliosis due to hemivertebra. Discordant anomaly with anterior T11 hemivertebral body and the T11 posterior hemiarch being locked in a T10-T12 bony plate.

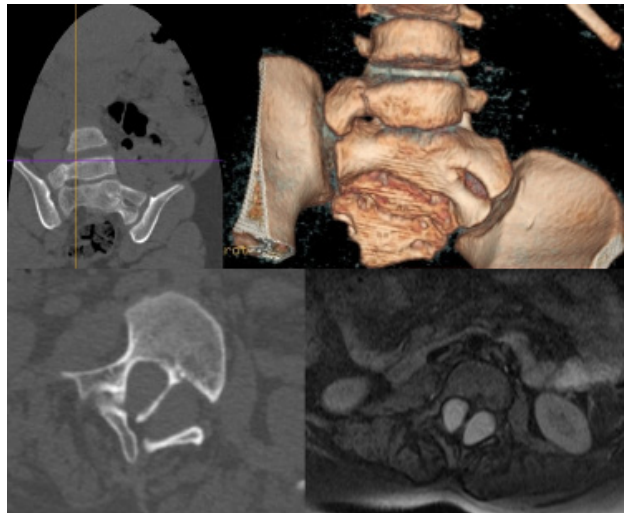


Figure 2 L5 mega-apophysis articulated to the sacral wing (up). Bony diastematomyelia evidenced on CT-scan and MRI.

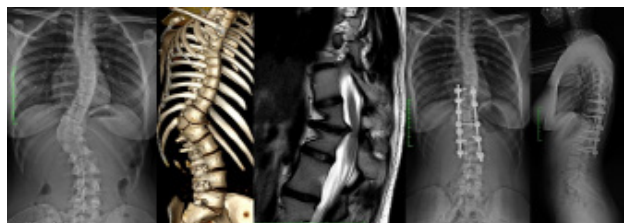

Figure 3 Degenerative changes and a stiff curve in a 16 years old patient with T12 hemivertebra. In order to obtain a good result, the fixation required a longer fusion area after hemivertebra resection.

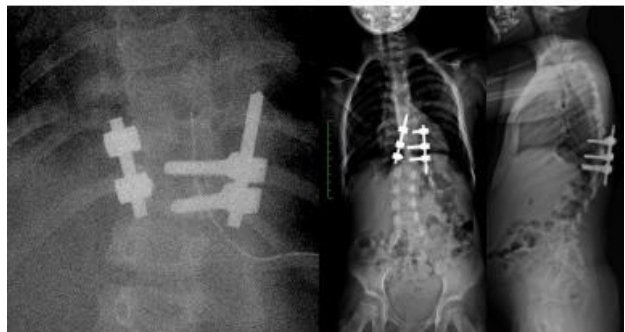

Figure 4 Pedicle fracture requiring implant extension with one level up.

compression (sometimes it requires a bit of distraction) in order to avoid pedicle fracture. The resected hemivertebra should be used as autologous bone graft to ensure effective fusion of the short spinal segment. The interspinous ligaments of the upper and lower vertebrae should be left intact to avoid kyphosis above or below the fusion

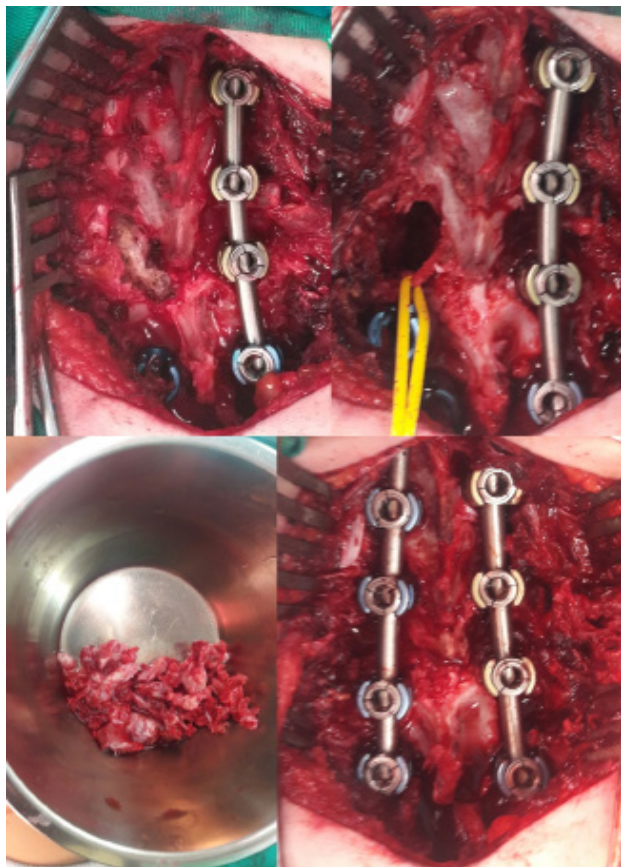


Figure 5 Ruf and Harms technique using a longer implant in a 15 years old patient. Convex side fixation with a rod, hemivertebra resection with intercostal nerve protection. Autologous bone graft resulted from hemivertebra resection. Final fixation after compression on the hemivertebra resection side.

area. The fracture of the pedicles requires the extension of the implant by 1-2 levels (Figure 4) or the use of a laminar hook instead of the pedicular screw placed in the fractured pedicle. In older patients the fixation of more than 2 levels should be performed *per primam* due to stiffness and degenerative changes (risk of pedicle fracture during compression) of the involved spinal segment (Figure 5). Another tip to avoid pedicle fracture is the use of a third rod with laminar hooks placed on the laminae of the upper and lower vertebrae. The lamina is stronger in younger patients and compression on this third bar will alleviate the forces on the pedicles during the compression maneuvers (Figure 6).

CONCLUSIONS

Each case of congenital scoliosis has to be carefully evaluated related to the present malformations, age at surgery and a proper preoperative planning and surgical procedure are mandatory in order to obtain best results. Complete hemivertebra resection with both adjacent disks and proper fixation are the key of success to avoid further re-interventions. If complications like pedicle fractures are encountered during surgery, the tricks with laminar hook instead of pedicular

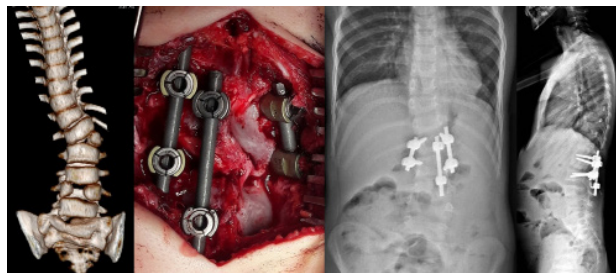


Figure 6 The use of a third rod to avoid pedicle fracture during compression after hemivertebra resection.

screw, the third rod and/or minimal extension of the spinal implant overcome the inconveniences. This technique described by Ruf and Harms makes obsolete an anterior approach of the hemivertebra, with similar results, but less extensive surgery. The growth of the spine is not impaired and favorable long term results are demonstrated.

ACKNOWLEDGEMENTS

All procedures performed in studies involving human participants were in accordance with the ethical standards of the institutional and/or national research committee and with the 1964 Helsinki declaration and its later amendments or comparable ethical standards. Informed consent was obtained from all individual participants included in the study.

Funding: This research did not receive any specific grant from funding agencies in the public, commercial, or not-for-profit sectors. There is no conflict of interest about the study.

REFERENCES

1. Zhang J, Shengru W, Qiu G. et al. The efficacy and complications of posterior hemivertebra resection. *Eur Spine J* 2011; **20**: 1692-1702. [DOI: 10.1007/s00586-011-1710-0]
2. Ruf M, Harms J. Hemivertebra resection by a posterior approach: innovative operative technique and first results. *Spine (Phila Pa 1976)*. 2002 May 15; **27(10)**: 1116-23. [PMID: 12004182]; [DOI: 10.1097/00007632-200205150-00020]
3. Kawakami N, Tsuji T, Imagama S, Lenke LG, Puno RM, Kuklo TR. Spinal Deformity Study Group. Classification of congenital scoliosis and kyphosis: a new approach to the three-dimensional classification for progressive vertebral anomalies requiring operative treatment. *Spine (Phila Pa 1976)*. 2009 Aug 1; **34(17)**: 1756-65. [PMID: 19644327]; [DOI: 10.1097/BRS.0b013e3181ac0045]
4. Cheng B, Li FT, Lin L. Diastematomyelia. A retrospective review of 138 patients. *J Bone Joint Surg Br*. 2012 Mar; **94(3)**: 365-72. [PMID: 22371545]; [DOI: 10.1302/0301-620X.94B3.27897]
5. Chang DG, Suk SI, Kim JH, Ha KY, Na KH, Lee JH. Surgical outcomes by age at the time of surgery in the treatment of congenital scoliosis in children under age 10 years. *Spine J*. 2015 Aug 1; **15(8)**: 1783-95. [PMID: 25862509]; [DOI: 10.1016/j.spinee.2015.04.009]
6. Ruf M, Jensen R, Letko L, Harms J. Hemivertebra Resection and Osteotomies in Congenital Spine Deformity. *Spine (Phila Pa 1976)*. 2009 Aug 1; **34(17)**: 1791-9. [PMID: 19644330]; [DOI: 10.1097/BRS.0b013e3181ab6290]