

The Kingpin Technique: An Aid for Optimal Tibial Component Rotation during Total Knee Arthroplasty

Firas Arnaout¹, Gavin Holt²

1 Arthroplasty Fellow, Trauma & Orthopaedics, Department of Trauma & Orthopaedics, Cheltenham General Hospital, United Kingdom;

2 Consultant surgeon, Trauma & Orthopaedics, Department of Trauma & Orthopaedics, Cheltenham General Hospital, United Kingdom.

Conflict-of-interest statement: The author(s) declare(s) that there is no conflict of interest regarding the publication of this paper.

Open-Access: This article is an open-access article which was selected by an in-house editor and fully peer-reviewed by external reviewers. It is distributed in accordance with the Creative Commons Attribution Non Commercial (CC BY-NC 4.0) license, which permits others to distribute, remix, adapt, build upon this work non-commercially, and license their derivative works on different terms, provided the original work is properly cited and the use is non-commercial. See: <http://creativecommons.org/licenses/by-nc/4.0/>

Correspondence to: Firas Arnaout, Arthroplasty Fellow, Trauma & Orthopaedics, Department of Trauma & Orthopaedics, Cheltenham General Hospital, United Kingdom.

Email: Firasarnaout@doctors.org.uk

Telephone: +00447919542581

Received: October 23, 2019

Revised: February 17, 2020

Accepted: February 20, 2020

Published online: April 28, 2020

ABSTRACT

Total Knee Replacements with malalignment are associated with increased pain, wear, and loosening. The recommended position of the tibial component is in line with the tibial tubercle in the axial plane. However, this can be variable due to patient's anatomy. We describe a novel technique extending Whiteside's line as a reference for tibial positioning and name it to mark Whiteside's contribution in this area.

Key Words: TKR; Rotational alignment; Whiteside

© 2020 The Author(s). Published by ACT Publishing Group Ltd. All rights reserved.

Arnaout F, Holt G. The Kingpin Technique: An Aid for Optimal Tibial Component Rotation during Total Knee Arthroplasty. *International Journal of Orthopaedics* 2020; 7(2): 1245-1247 Available from: URL: <http://www.ghmet.org/index.php/ijo/article/view/2881>

INTRODUCTION

Performing Total Knee Replacements with a pre-existing malalignment are associated with increased risk of post-operative mal-rotation. Resulting in pain, wear, and loosening^[1]. To aid the correct rotational alignment, the recommended position of the tibial component is in line with the tibial tubercle in the axial plane^[2]. However, this anatomical landmark can be variable due to inconsistent patient's anatomy.

We describe a novel technique extending the well documented Whiteside's line from the femur to be used as a reference for tibial positioning, and name it to mark Whiteside's contribution in this area.

TECHNIQUE

Whiteside's line is defined by the lateral border of the centre of the inter-condylar notch posteriorly and the deepest part of the patellar groove anteriorly^[3]. It has a high inter-observer and intra-observer reliability^[4].

We first mark Whiteside's line with a diathermy (Figure 1), the leg is then held in the desired anatomical position and Whiteside's line is extended onto the anterior tibia.

A small drill hole is then made, distal to the expected tibial cut, perpendicular to the mechanical axis, as defined by the extended Whiteside's line, and in a true AP direction, without breaching the posterior cortex (Figure 2).

The drill bit is then removed and the remaining hole is used as tibial rotational reference point.

This reference is used as the "Kingpin" defining a line for both the mediolateral position and axial rotation of the tibial component. Our landmark is then used to set the axial rotation of the tibial cutting jig (Figure 3) and again when preparing the tibia for final positioning the tibial component (Figure 4).

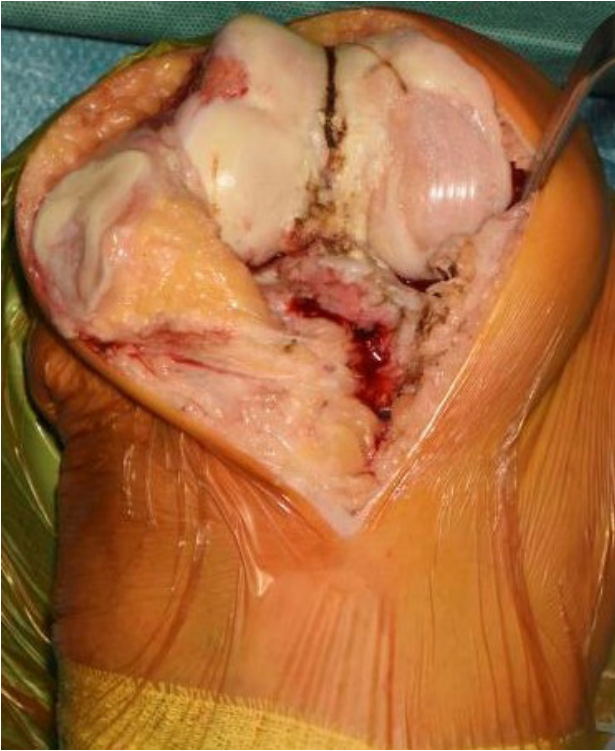


Figure 1 Whiteside's line marked with diathermy.

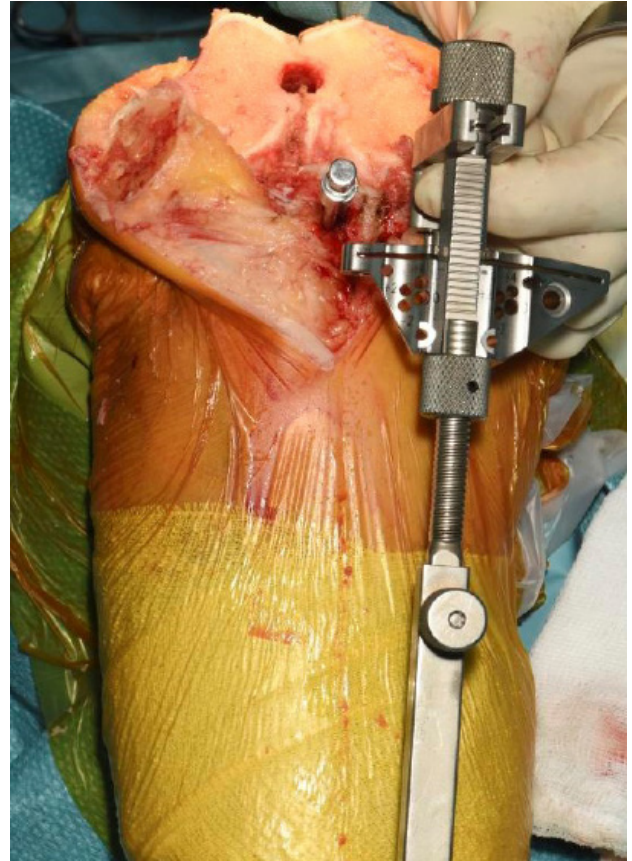


Figure 3 Landmark used to set axial rotation of tibia.

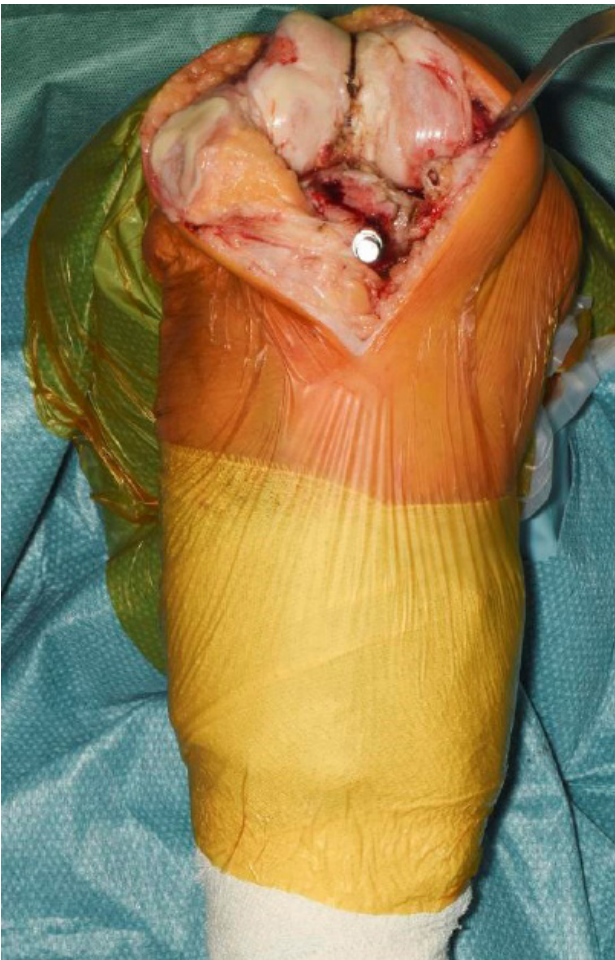

Figure 2 A drill hole used to define the extension of Whiteside's line on the tibia.

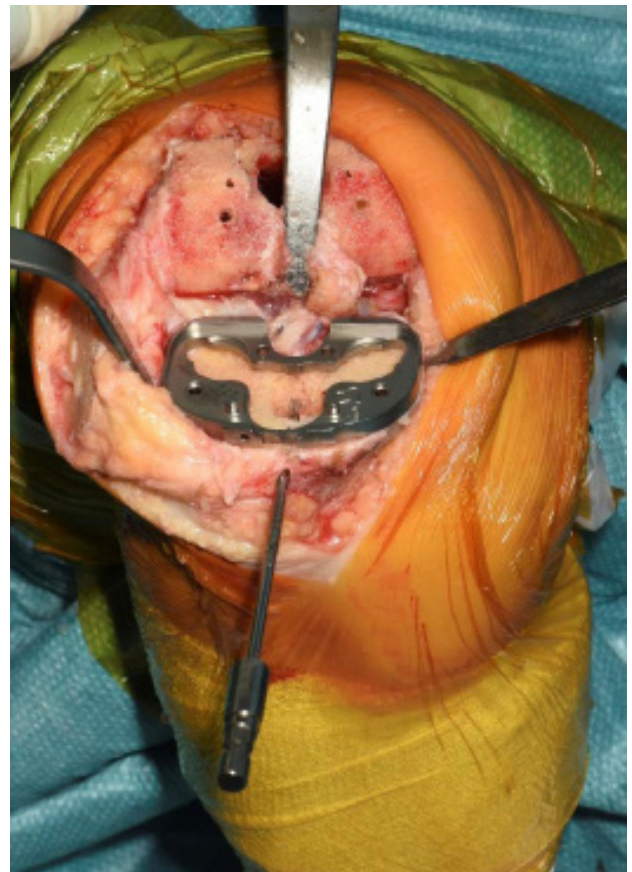


Figure 4 Landmark used for final tibial preparation.

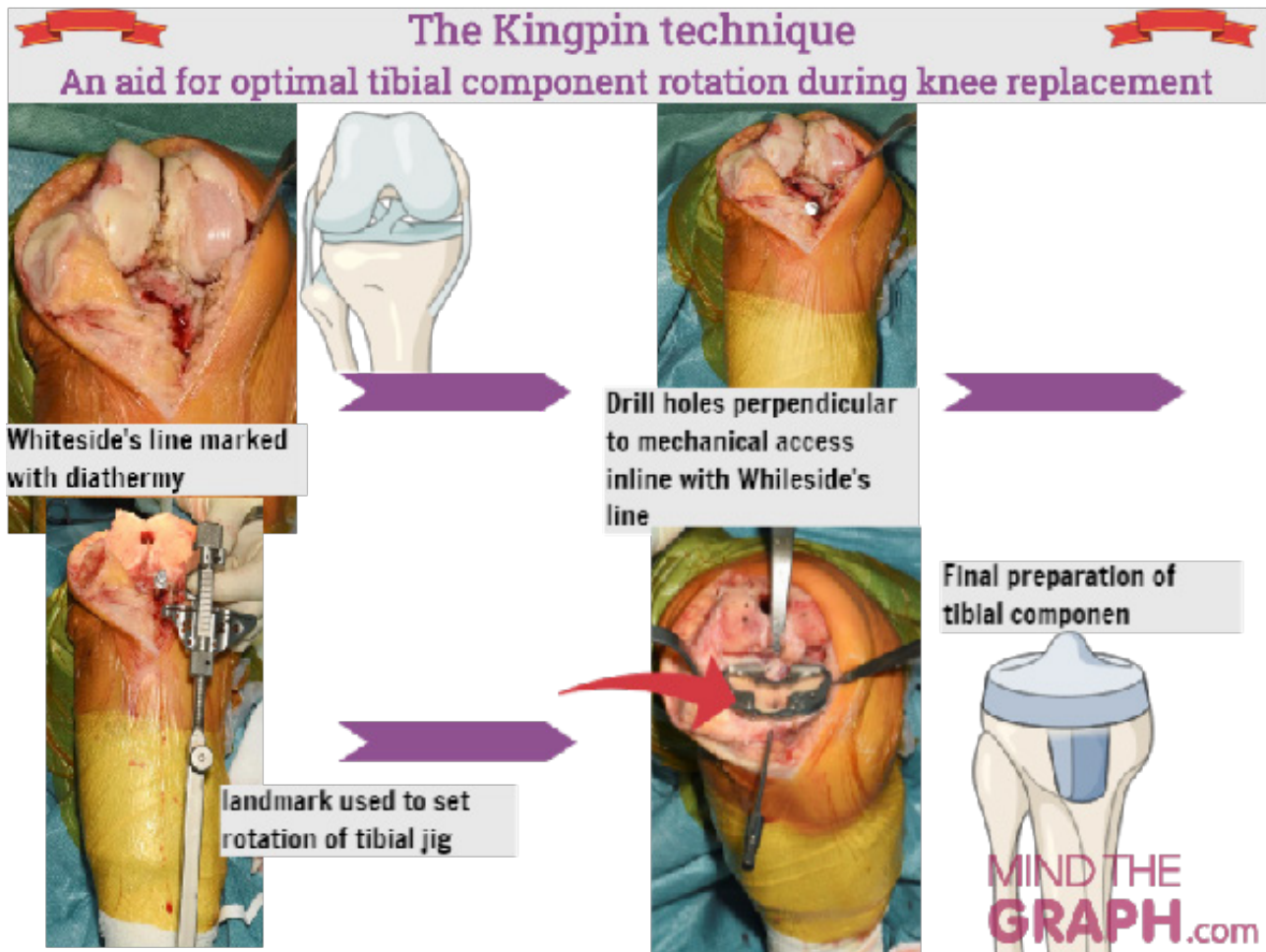


Figure 5 Summary of the Kingpin technique.

CONCLUSION

We have utilized a well-recognized landmark. The Whiteside's line, for femoral component positioning and extended it distally to minimise the risks of tibial mal-positioning.

This landmark is preserved throughout the operation and after resection of the tibia, and is unaffected by knee flexion, subluxation or soft tissue retraction.

Whiteside's line is only one of several landmarks, and care should be taken when there is discordance with other visible landmarks or instrumented guidance.

REFERENCES

1. Vince KG, Abdeen A, Sugimori T. The unstable total knee arthroplasty: causes and cures. *J Arthroplasty*. 2006 Jun; **21(4 Suppl 1)**: 44-9. [PMID: 16781428]; [DOI: 10.1016/j.arth.2006.02.101]
2. Lee GC, Cushner FD, Scuderi GR, Insall JN. Optimizing patellofemoral tracking during total knee arthroplasty. *J Knee Surg*. 2004 Jul; **17(3)**: 144-9; [PMID: 15366269]; [DOI: 10.1055/s-0030-1248213]
3. Whiteside LA. Soft tissue balancing: the knee. *J Arthroplasty*. 2002 Jun; **17(4 Suppl 1)**: 23-7. [PMID: 12068398]; [DOI: 10.1054/arth.2002.33264]
4. Nicolas Vanin, Martin Panzica, Stefan Hankemeier. Rotational alignment in total knee arthroplasty: intraoperative inter- and intraobserver reliability of Whiteside's line. 2011; **131**: 1477-1480. [DOI: 10.1007/s00402-011-1329-y]