

Knee Extensor Mechanism Disruptions: A Review

Devon M. Myers¹, DO; Matthew Glazier¹, DO; Benjamin C. Taylor², MD

1 Department of Orthopedic Surgery, OhioHealth Grant Medical Center, Columbus, OH, United States;

2 Fellowship Director, Orthopaedic Trauma and Reconstructive Surgery, Department of Orthopedic Surgery, OhioHealth Grant Medical Center, Columbus, OH, United States.

Conflict-of-interest statement: The author(s) declare(s) that there is no conflict of interest regarding the publication of this paper.

Open-Access: This article is an open-access article which was selected by an in-house editor and fully peer-reviewed by external reviewers. It is distributed in accordance with the Creative Commons Attribution Non Commercial (CC BY-NC 4.0) license, which permits others to distribute, remix, adapt, build upon this work non-commercially, and license their derivative works on different terms, provided the original work is properly cited and the use is non-commercial. See: <http://creativecommons.org/licenses/by-nc/4.0/>

Correspondence to: Devon M. Myers, DO, 285 E State St. Suite 500, Columbus, OH, United States.

Email: devon.myers@ohiohealth.com

Telephone: +1-314-607-6811

Received: March 30, 2020

Revised: April 20, 2020

Accepted: April 22 2020

Published online: June 28, 2020

ABSTRACT

Native extensor mechanism (EM) injuries are rare but disabling injuries and can present significant treatment challenges, especially in cases of chronic injury or re-rupture. The goal of this review was to provide an overview of the evaluation and management pertaining to a spectrum of extensor mechanism disruptions. Quadriceps and patellar tendon ruptures comprise less than half of EM failures and are usually amenable to predictable repair and recovery regardless of repair method. While suture anchor and cortical button fixation may be biomechanically superior, no high-level clinical evidence exists to recommend a particular method at this time. Chronic tears and re-ruptures are complex problems for which multiple novel techniques have been described, most with acceptable outcomes. No comparative studies exist to recommend a particular method. Patellar

fractures are the most common EM injuries and vary in complexity. Tension band wiring, fixed angle plating and mesh plating can be used successfully depending on the fracture pattern, with plating favored as comminution increases. Important considerations include stable fixation, restoration of articular surface, re-establishment of the EM and minimal hardware prominence. In this review, we highlight pertinent anatomy, surgical indications and methods of fixation for acute and chronic injuries of the native extensor mechanism with the goal of providing a concise, thorough understanding of the subject.

Key Words: Extensor mechanism; Patella; Quadriceps; Tendon; Rupture

© 2020 The Author(s). Published by ACT Publishing Group Ltd. All rights reserved.

Myers DM, Glazier M, Taylor BC. Knee Extensor Mechanism Disruptions: A Review. *International Journal of Orthopaedics* 2020; 7(3): 1260-1267 Available from: URL: <http://www.ghrnet.org/index.php/ijo/article/view/2901>

INTRODUCTION

The knee's extensor mechanism (EM) is formed by a unique linkage of the quadriceps and patellar tendons through the patella. Together, functional knee extension and normal gait are possible. EM injuries are relatively rare but can be disabling to patients and equally as challenging for surgeons to manage. New techniques are being developed to treat complex EM disruptions, especially for chronic injuries or failed primary repairs. The goal of this review is to highlight current management guidelines and evaluate the effectiveness of novel techniques being used for complex EM ruptures.

QUADRICEPS TENDON RUPTURES

Overview

Quadriceps tendon (QT) ruptures account for approximately one-third of EM injuries^[1]. Mechanism of injury is an indirect, eccentric contraction of the quadriceps muscle with the knee flexed. Greater than 85-90% of QT ruptures occur in males who are more likely to be obese and older than 40 years old^[1,2]. A history of previous tendinopathy or systemic disease is common, which may alter

inflammatory responses and tendinous blood flow^[3]. Conditions affecting tendon quality include renal disease, diabetes, inflammatory arthritides, and use of corticosteroids or fluoroquinolones^[4]. In women, 96% of QT ruptures were linked to systemic conditions, compared to 68% of males^[1].

Anatomy/Biomechanics

The QT is the confluence of the rectus femoris and the three vastus muscles. The rectus femoris crosses the hip joint, lessening its relative role in knee extension^[3]. The vastus lateralis and medialis combine with fascia lata to form the extensor retinaculum which can maintain some knee extension with EM rupture^[5]. The quadriceps muscles are innervated by the femoral nerve. The vastus medialis blood supply is derived from branches of the femoral and popliteal arteries, while the remaining muscles are supplied by the lateral femoral circumflex artery^[6]. An area of hypovascularity has been described by Ciriello approximately 1-2 cm above the superior pole of the patella, making ruptures more common in this location. QT ruptures superior to the 2 cm landmark appear relatively rare^[7].

Examination/Imaging

Patients with QT ruptures describe predictable injury mechanisms and an inability to extend the knee^[8]. If the extensor retinaculum remains intact, knee extension may be possible, but usually with some degree of extensor lag^[5]. Palpable defect at the superior patellar pole can be appreciated with complete rupture. If examination is equivocal, imaging may be useful for diagnosis. Plain radiographs demonstrate anterior tilt of the superior patella with patella baja or superior pole avulsions (Figure 1). MRI can differentiate between complete and partial tears and define degree of retraction and tendon quality in cases of chronic tear or re-rupture^[3]. MRI may also identify associated knee injuries although not regularly indicated with QT rupture due to rarity of associated injuries^[9].

Management

Complete QT ruptures are an indication for surgical repair^[3,10]. Without adequate repair, extensor function is compromised, and ambulatory status significantly declines. Partial tears may be treated non-operatively with the knee braced in extension for at least six weeks^[3]. Repair should be performed within two to three weeks at the latest to prevent tendon retraction, scarring and compromised tissue quality^[2,7,8,10].

In addition to timing, the other primary factor affecting success is the fixation method. Mid-substance QT ruptures, while uncommon, can be successfully repaired using end-to-end suture fixation^[7]. With acute rupture from the superior patella, several techniques may be utilized for repair, with debate ongoing in regard to most efficacious methods. Regardless of chosen fixation, clean tendon edges should be prepared and a locking, grasping suture should be placed through the tendon (Figure 2). The “gold standard,” of QT repair involves passing the suture ends through transosseous patellar drill tunnels and tying them over the inferior patellar. Some have suggested suture anchors used to fixate the tendon may provide increased load to failure with less repair site gapping, while offering comparable clinical outcomes^[11-14]. Suture and anchor type may also play a role in construct strength, as knotless anchors loaded with Arthrex® SutureTape (Arthrex, Inc; Naples, FL) have demonstrated decreased cyclical displacement, improved stiffness and greater loads to failure compared to standard suture anchors and transosseous tunnels using high-strength #2 suture in biomechanical cadaveric studies^[15]. Other theoretical advantages to suture anchor

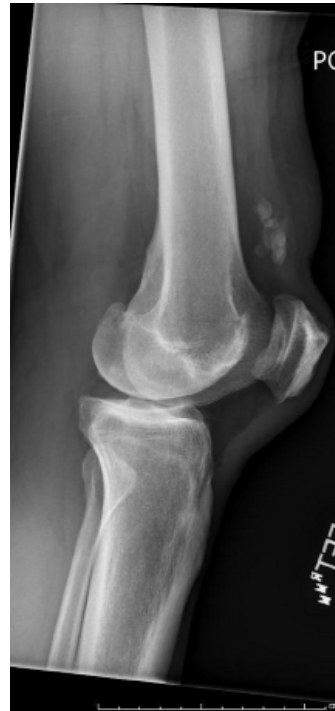

Figure 1 Lateral radiograph demonstrating superior pole patellar avulsion representative of quadriceps tendon rupture.

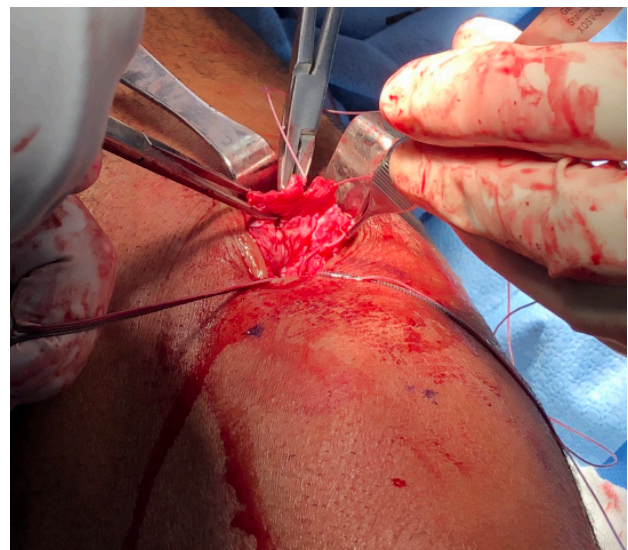

Figure 2 Intraoperative quadriceps tendon rupture with heavy sutures being placed through the tendon prior to fixation.

fixation include smaller incisions, less soft tissue stripping and more aggressive early therapy^[12]. However, there is a paucity of literature comparing clinical outcomes with regards to fixation methods. One such study was performed by Plesser, examining 27 patients with no difference in outcomes or failures between transosseous and suture anchor repairs^[16]. Ciriello noted that transosseous drill holes were most commonly used, and did not appear to affect outcomes; however, they did not include studies using suture anchors^[7]. Arthroscopic repair techniques have been recently described with excellent functional results, no failures, and lower risk of wound complications. No comparative data exists comparing arthroscopic and open techniques, therefore it remains too soon to consider arthroscopic procedures equivalent. Overall, it appears transosseous and suture anchor fixation can provide acceptable outcomes in acute repairs. Although biomechanical and soft tissue advantages are seen

with suture anchor use, comparative data continues to be lacking.

While acute QT repairs have predictable, satisfactory outcomes, chronic ruptures >3 weeks old and re-ruptures are challenging for surgeons. If tendon approximation is possible, primary repair techniques may be used. Depending on time duration from initial injury, augmentation may be considered, given progressive, underlying tendinous degeneration^[17]. If tendon approximation is not possible, several options exist. Tendon V-Yplasty or Codivilla's technique can be performed to lengthen the tendon and allow re-approximation^[3]. Codivilla's technique creates an inverted V in the QT which is sewed on top of the patella, while performing side to side closure of the created QT defect^[3]. Unfortunately, outcomes have been poor with Codivilla's technique^[18]. In cases where this technique fails or a large defect remains, hamstring autograft augmentation is another option for repair. Specific hamstring augmentation techniques vary but semitendinosus and gracilis tendons are usually harvested and whipstitched. Some describe weaving the autograft through the QT with transosseous drill tunnels for final tendon fixation^[19-21]. Maffulli passed the hamstring autograft through a transverse patellar tunnel, using the graft to reinforce the native QT^[22]. All of these techniques are difficult and not easily compared. Rehman described a 10° extensor lag but all other aforementioned patients were able to return to daily activities with no re-ruptures^[20].

PATELLA FRACTURES

Overview

Patellar fractures comprise 1% of adult fractures and are six times more common than ruptures of the QT or patellar tendon (PT)^[1,23,24]. There are two primary mechanisms of injury, which dictate fracture pattern. A direct blow to the anterior patella causes a more complex, comminuted fracture, while indirect tension forces from the QT and PT lead to transverse fractures^[23,25].

Anatomy/Biomechanics

The patella is the largest sesamoid bone, linked by the QT and PT and covered by extensor retinaculum. Seven facets are present, with three medial and lateral and an extra facet medially, devoid of cartilage, called the odd facet^[23,24]. Vascular supply is formed by an anastomotic ring of the geniculate arteries with the most important branches penetrating the inferior patella and flowing retrograde, making proximal fractures susceptible to osteonecrosis^[23,24].

Biomechanically, the patella begins to engage the femoral trochlea at 20° of flexion and is fully engaged by 40°. Patellar articular cartilage is the thickest in the body in order to withstand forces up to seven times body weight with deep flexion^[5].

Fracture Classification

Patellar fractures can be identified as OTA 34A1-34C3, although classification is mostly descriptive. Terms used to describe fracture patterns include: nondisplaced, displaced, transverse, vertical, superior or inferior pole, comminuted, marginal or osteochondral^[10,24]. Most important to consider are the displacement, orientation and comminution. Also important is the ability to perform a straight leg raise. Vertical, marginal and osteochondral fracture patterns typically present with an intact EM^[10]. Complex fracture patterns typically have more retinacular and soft tissue disruption.

Evaluation/Imaging

Patients complain of anterior knee pain and a hemarthrosis may be present. Depending on severity, straight leg raise may or may

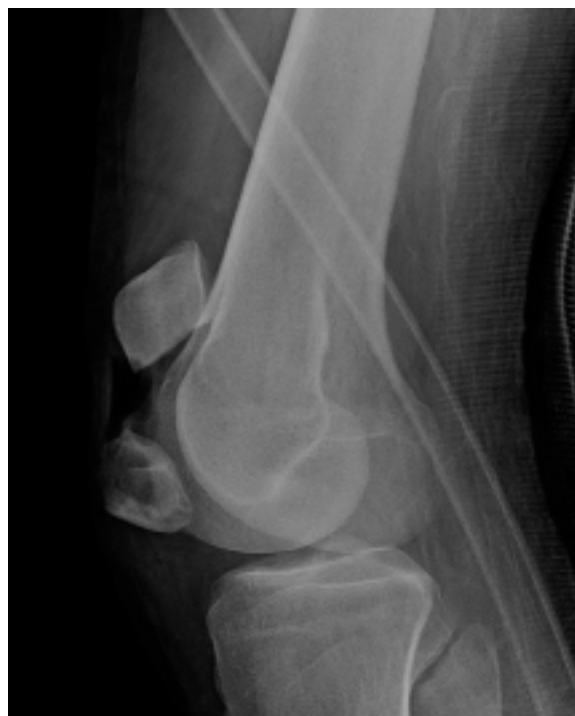

Figure 3 Lateral radiograph demonstrating simple, transverse patella fracture.

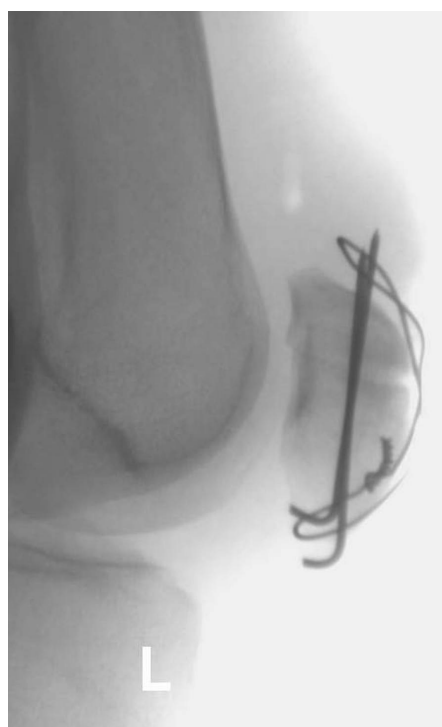

Figure 4 Radiographs demonstrate tension band construct used to treat transverse patellar fracture.

not be possible. Low suspicion should exist to obtain imaging^[25]. Orthogonal knee radiographs should be obtained first (Figure 3). CT may be worthwhile in some cases. Lazaro noted that CT changed operative management in half of cases, especially when there was comminution or inferior pole involvement^[26].

Management

Surgical indications for fracture fixation include deficient EM,

articular step-off > 2 mm, fracture displacement > 1-4 mm, osteochondral fractures or loose bodies^[27,28]. Goals of surgery include stable fixation, articular surface restoration, EM re-establishment and minimal hardware prominence^[10,24].

Non-operative treatment may be appropriate with non-displaced or minimally displaced fractures with an intact EM. Hinged-knee brace locked in full extension can be placed initially. At two-week follow-up, patients are allowed passive and active range of motion, while locked in extension during weight-bearing. Patients may weight-bear without the brace at six weeks^[25]. Studies have supported excellent non-operative outcomes with few failures in appropriate patients^[29].

Multiple methods of fixation exist for patellar fractures, dictated by fracture pattern. The patella is approached through a midline incision, preserving ability to perform total knee arthroplasty in future if necessary. Full thickness flaps are created, and surrounding tissues are evaluated for retinacular tears. In complex patterns, a lateral arthrotomy may improve articular surface reduction but should be used cautiously to not disturb blood supply^[28].

The most common technique used for transverse fractures is tension band wiring (TBW), in order to convert EM tensile forces into compressive forces at the articular surface^[3,24,28,30]. To achieve interfragmentary compression, two k-wires are placed across the fracture, close to the cartilaginous surface (Figure 4). Wire is then wrapped anteriorly in a figure-of-eight configuration to provide compression. K-wires should be tamped flush to the bone, but are often prominent, leading to high rates of symptomatic hardware. Rates of symptomatic hardware removal range from 33-50% with use of TBW, although hardware removal does not always improve outcomes^[31,32]. TBW is inexpensive and has generally demonstrated reliable bony healing, but there have been reports of fracture gapping and failure (Figure 5)^[33]. Smith noted 22% of fractures treated with TBW displaced >2mm post-operatively; several cases were attributed to patient non-compliance but overall, rates were unacceptably high^[34]. To address the aforementioned issues, supplemental techniques have been introduced, including cannulated screws being described as a substitute for k-wires in tension band constructs. This involves passing wire through the cannulated screws and reproducing the figure-of-eight configuration anteriorly. LeBrun and Tian compared tension band models with cannulated screw and k-wires and demonstrated lower rates of symptomatic hardware removal with cannulated screws^[31,35]. Tian also noted less displacement and slightly reduced time to healing in the cannulated screw group^[35]. Functional outcomes were improved for the cannulated screw group in Tian's cohort, but unchanged per LeBrun^[31,35]. Gao used TBW with supplemental mini-fragment plates and noted union with satisfactory outcomes in all patients, reducing fracture displacement concerns in TBW^[36].

With increasing comminution, tension band principles may not provide stable osteosynthesis. In these cases, options include plating, cerclage wiring or patellectomy (Figure 6). Current literature supports patellar preservation and avoidance of complete patellectomy, as this decreases EM mechanical advantage by almost 50%^[10,25,37]. Partial patellectomy may be appropriate with small, de-vascularized fragments of the superior or inferior poles. At least 60% of native patella should be preserved or functional results are equivalent to complete patellectomy^[38]. In cases of partial patellectomy, the QT or PT is whipstitched and advanced to bone. Decreases in patellectomy have paralleled improvements in patellar plating, including fixed angle mini-fragment and mesh plates. Fixed angle plates (FAP) can be used for simple or comminuted fractures and may be beneficial in osteoporotic bone (Figure 7)^[30]. Multiple authors have demonstrated

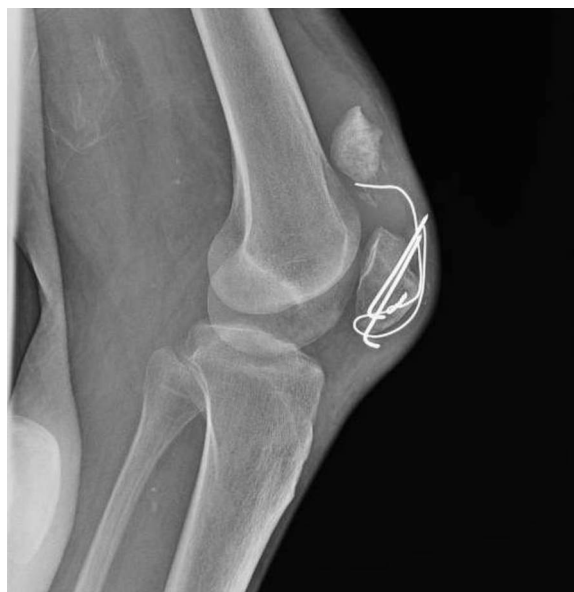

Figure 5 Lateral radiograph demonstrating failure of tension band construct

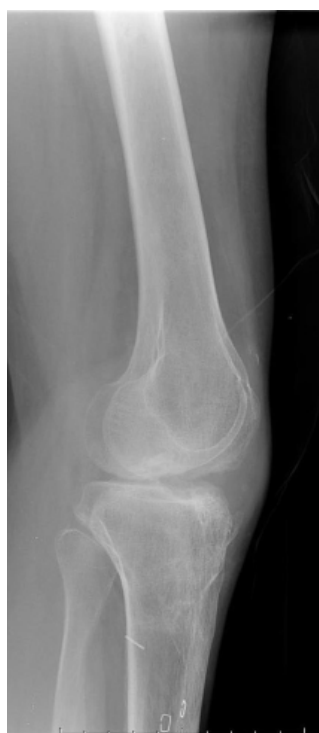

Figure 6 Lateral radiograph status post complete patellectomy.

easy and reliable use, excellent outcomes, no displacement and no hardware removals using FAP for comminuted fractures^[28,39-41]. Wurm followed 35 patients with FAP and found good outcomes with no EM deficits and only one implant related complication^[30].

Mesh plates (MP) have been popularized because of their versatility. They consist of multiplanar screw holes that accommodate locking or non-locking screws and can be shaped to the patient's anatomy. Lorich studied 9 patients and noted MPs were effective in stabilizing inferior pole comminution without compromising vascularity^[42]. Others have supported these findings, reporting high union rates, possibly secondary to less fracture gapping compared to TBW^[43-45]. Increased thigh circumference, less knee pain, improved

motion, and less hardware irritation have been noted compared to TBW^[45-47].

Patellar nonunion occurs in < 1% of cases and may be well tolerated when the EM is intact^[3]. Open fractures have higher rates of nonunion, approaching 7% and may require revision with bone grafting or salvage patellectomy^[3]. Other surgical complications may include infection, stiffness, and complex regional pain syndrome. Infection risk is normally 0-5% but increases to > 10% in open fractures.

In summary, TBW provides predictable healing in simple fractures with high rates of hardware removal. Conversely, FAPs may increase stiffness with less symptomatic hardware in simple fractures. FAPs and MPs are useful in comminuted fractures, with no clear comparison to recommend a specific plate. One advantage of MPs is multiplanar screw fixation, which increases reduction and maintenance of fixation. At this time, we cannot recommend a specific plate, as more direct comparisons are needed.

PATELLAR TENDON RUPTURES

Overview

PT ruptures are the least common EM disruptions, at approximately 10%. They are more common in males younger than age 40, with the majority being sport-related^[1-3]. Mechanism of injury is an eccentric contraction of a flexed knee, with the most common site of rupture at the inferior patella^[10,48]. Risk factors include prior tendinopathy or systemic disease, similar to QT ruptures^[3].

Anatomy/Biomechanics

The PT originates broadly on the deep surface of the inferior patellar pole and attaches narrowly to the tibial tubercle^[5]. Some say it would be better termed the, “patellar ligament,” given its bony attachments. However, histologically its makeup is more consistent with tendinous origin^[49]. Additionally, it functions as a tendon, connecting the quadriceps musculature to the tibia through the patella.

Nomenclature aside, the PT is a vital portion of the EM. Vascularity of the PT is somewhat complex, derived from a vascular anastomosis of the superior and inferior geniculate arteries, with contributions from surrounding fat pad.

Evaluation/Imaging

Patients present with an inability to perform a straight leg raise. Patient’s may describe having felt their knee, “pop,” or give way. A palpable defect may be noted at the inferior patella. Orthogonal radiographs should be obtained and commonly demonstrate a joint effusion and patella alta^[8]. PT rupture is generally a clinical diagnosis but McKinney noted that 30% of patients with PT ruptures had other injuries identified on MRI, with 75% of “high energy” PT ruptures having associated injuries^[9]. While routine MRI is not recommended based on a small body of evidence, low clinical suspicion should exist to obtain MRI.

Management

With partial rupture and intact EM, nonoperative management in an extension brace or cast is possible^[3]. This said, cases must be individualized, as repair and/or augmentation may still be considered given the young, athletic population affected.

With complete PT rupture, surgical repair is almost universally indicated. In acute ruptures, fixation methods are similar to QT ruptures. Timing and fixation method are again important. Ruptures should be repaired quickly, within 2-3 weeks^[2]. A large, nonabsorbable locking suture should be weaved through the tendon

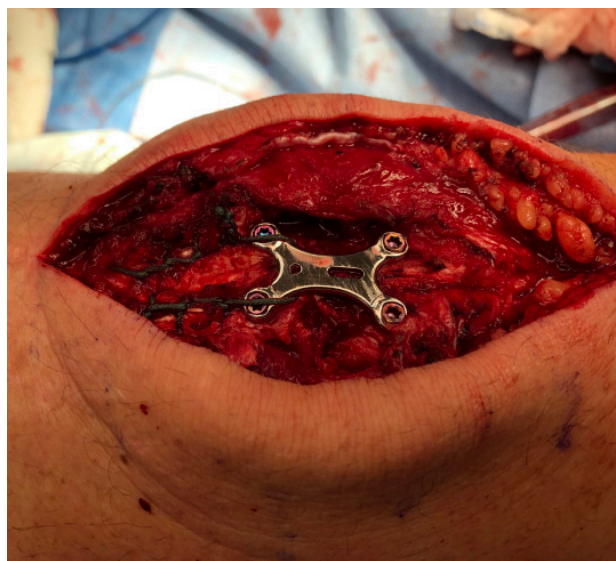


Figure 7 Intraoperative use of fixed angle patellar plating with suture reinforcement.

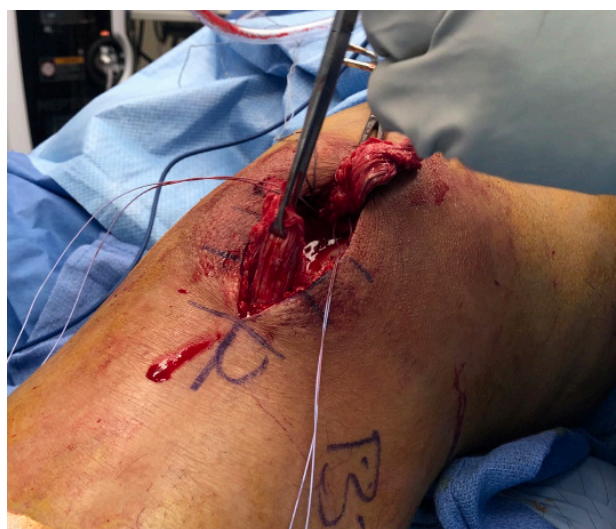

Figure 8 Intraoperative patellar tendon rupture with suture anchor fixation at inferior patellar pole.

and reapproximated through transosseous tunnels, suture anchors, or cortical button fixation. Suture anchor preparation is shown in Figure 8. Comparison of transosseous tunnels and suture anchors has shown similar results in PT ruptures when compared to QT ruptures as discussed above. Biomechanical studies by Lanzi and Ettinger demonstrated less gap formation and higher failure loads using suture anchors for PT repair^[50,51]. The debate continues, as Sherman did not show any differences in load to failure^[52]. Cortical button fixation has also been explored for PT ruptures. Transosseous tunnels are created and a button device, similar to that used in ACL graft fixation, is inserted, flipped and tensioned over the superior patella. Ode used 23 cadavers to compare transosseous, suture anchor and cortical button repair and noted significantly less gap formation and two-times higher failure loads with cortical buttons compared to the other groups^[53]. Comparative clinical trials evaluating PT repair fixation methods remain sparse. Meyer augmented acute repairs with oblique bone tunnels to create a “belt-over-suspenders” repair to compress the repaired tendon^[17]. Schütte used an internal brace technique, creating transverse tunnels in the tibial tuberosity and patella and using Arthrex® Fibertapes (Arthrex, Inc; Naples, FL), in “O” and “X”

configurations tied through the drill holes^[54]. The authors noted positive results with 10-year follow-up in both acute and chronic ruptures.

Results are inconsistent with chronic PT ruptures or re-ruptures^[55]. Challenges include tendon quality, retraction and lack of patellar mobility. Prolonged post-operative immobilization is often necessary, leading to quadriceps contracture, weakness and loss of knee flexion^[55,56]. The patella is pulled proximally secondary to quadriceps contracture and distal patellar mobilization is a primary surgical goal^[55]. This has been achieved several ways. Rocha de Faria performed a two-stage procedure using patellar skeletal traction to mobilize the patella then used a hamstring autograft passed through transverse tunnels in the tibia and patella^[21]. They then whipstitched the remaining PT and passed the suture through transosseous tunnels, fixing the graft with interference screws. Other authors have reported good results using hamstring autografts fixated through patellar and tibial bone tunnels, citing low donor morbidity and ability to augment poor native tissue quality. von Glinski noted full motion and strength at one-year using a semitendinosus autograft, while Van der Bracht argued for earlier rehabilitation given technique strength^[57,58]. Other techniques have been used to mobilize the patella. Jain used cerclage wire through transverse holes in the patella and tibia, followed by a QT “turn-down,” sewn into the superior PT defect^[59]. Similarly, Falconiero and McNally both used cerclage wires to mobilize the patella but reinforced the repair with an achilles allograft^[60,61]. Both noted mild limitations in knee flexion and diminished quadriceps strength, with secondary surgery for wire removal required. Kumar used a ring-fixator to mobilize the patella and QT and reconstructed the PT with an achilles allograft^[62]. They noted flexion limitation of 110° and 85% of quadriceps strength compared contralaterally. In cases of chronic tears or re-rupture, one technique cannot be recommended as no comparative, high-level data exists. We recommend following the principles discussed, including patellar mobilization and one of the several native tissue augmentation techniques.

REHABILITATION

Tendon Ruptures

Similar post-operative rehabilitation protocols have been described for PT and QT repair. Quality prospective studies are lacking, with immobilization time and weight-bearing status being the main protocol differences noted in the literature. Traditionally, patients were immobilized for six weeks post-operatively in a brace or cylinder cast^[7].

With stronger fixation methods, patients may safely begin rehabilitation sooner with lower failure risk^[53,63]. Earlier weight-bearing may allow faster remodeling and increased strength in the repaired collagen fibers^[51]. Rugraff found no difference in QT repair failure with three or six weeks of immobilization post-operatively^[64]. Some have even suggested immediate full weight-bearing protocols may demonstrate non-inferior outcomes and similar complication rates.

While protocols vary, patients begin weight-bearing-as-tolerated in a hinged-knee-brace in extension post-operatively. Knee flexion is progressed approximately 30° at two-week intervals, with a goal of 90° flexion between six and eight weeks post-operatively. Strengthening exercises are then initiated^[65,66]. Patients usually return to activities between six and nine months after QT repair and PT repair^[66,67].

Patellar Fractures

Similar debate exists regarding rehabilitation after patellar fixation.

Typically, patellar fractures patients may weight-bear-as-tolerated while immobilized in a hinged-knee-brace locked in extension for four weeks post-operatively^[68]. Isometric exercises are incorporated within two weeks of surgery, with some arguing as early as postoperative day one without complication^[69]. The brace may be unlocked at four weeks and patients may begin riding a stationary bike without resistance. Targeted strengthening begins six to eight weeks postoperatively once evidence of fracture union is noted^[68]. Athletes are cleared to return to play when range of motion and strength are similar to the uninjured knee, usually within six to nine months. Of note, athletes may have a difficult time returning to pre-injury levels of competition^[70].

CONCLUSION

EM ruptures are disabling injuries and often require surgical reconstruction. Multiple acceptable techniques exist to repair tendinous ruptures, although new suture anchor and cortical button fixation appear more advantageous biomechanically. Chronic tendon ruptures present difficult problems with no definitive gold-standard technique currently able to be recommended. Multiple methods of fixation appear to lead to reliable union of patellar fractures, while certain techniques may offer improved versatility and lower complication rates.

REFERENCES

1. Garner MR, Gausden E, Berkes MB, Nguyen JT, Lorich DG. Extensor Mechanism Injuries of the Knee: Demographic Characteristics and Comorbidities from a Review of 726 Patient Records. *J Bone Joint Surg Am.* 2015; **97(19)**: 1592-1596. [PMID: 26446967]; [DOI: 10.2106/JBJS.O.00113]
2. Pengas IP, Assiotis A, Khan W, Spalding T. Adult native knee extensor mechanism ruptures. *Injury.* 2016; **47(10)**: 2065-2070. [PMID: 27423309]; [DOI: 10.1016/j.injury.2016.06.032]
3. Saragaglia D, Pison A, Rubens-Duval B. Acute and old ruptures of the extensor apparatus of the knee in adults (excluding knee replacement). *Orthop Traumatol Surg Res.* 2013; **99(1 Suppl)**: S67-S76. [PMID: 23352566]; [DOI: 10.1016/j.otsr.2012.12.002]
4. Lang TR, Cook J, Rio E, Gaida JE. What tendon pathology is seen on imaging in people who have taken fluoroquinolones? A systematic review. *Fundam Clin Pharmacol.* 2017; **31(1)**: 4-16. [PMID: 27477928]; [DOI: 10.1111/fcp.12228]
5. Hsu H, Siwiec RM. (2020) Patellar Tendon Rupture. In: *StatPearls*. Treasure Island, FL
6. Pope JD, Plexousakis MP. (2020) Quadriceps Tendon Rupture. In: *StatPearls*. Treasure Island, FL
7. Ciriello V, Gudipati S, Tosounidis T, Soucacos PN, Giannoudis PV. Clinical outcomes after repair of quadriceps tendon rupture: a systematic review. *Injury.* 2012; **43(11)**: 1931-1938. [PMID: 22959496]; [DOI: 10.1016/j.injury.2012.08.044]
8. Duthon VB, Fritschy D. Ruptures de l'appareil extenseur du genou Knee extensor mechanism ruptures. *Rev Med Suisse.* 2011; **7(304)**: 1544-1548.
9. McKinney B, Cherney S, Penna J. Intra-articular knee injuries in patients with knee extensor mechanism ruptures. *Knee Surg Sports Traumatol Arthrosc.* 2008; **16(7)**: 633-638. [PMID: 18478204]; [DOI: 10.1007/s00167-008-0516-z]
10. Bui CN, Learned JR, Scolaro JA. Treatment of Patellar Fractures and Injuries to the Extensor Mechanism of the Knee: A Critical Analysis Review. *JBJS Rev.* 2018; **6(10)**: e1. [PMID: 30277900]; [DOI: 10.2106/JBJS.RVW.17.00172]
11. Huleatt J, Gebrelul A, Premkumar A, Xerogeanes J. Suture Anchor Repair of Quadriceps Tendon and Patellar Tendon Ruptures. *Techniques in Orthopaedics.* 2019; **34(2)**: 134-139. [DOI: 10.1097/BTO.0000000000000315]

12. Colombelli A, Polidoro F, Guerra G, Belluati A. Patellar and quadriceps tendons acute repair with suture anchors. *Acta Biomed.* 2019; **90(1-S)**: 209-213. [PMID: 30715027]; [PMCID: PMC6503402]; [DOI: 10.23750/abm.v90i1-S.8108]
13. Amini MH. Quadriceps Tendon Repair Using Knotless Anchors and Suture Tape *Arthrosc Tech.* 2017; **6(5)**: e1541-e1545. [PMID: 29354471]; [PMCID: PMC5709721]; [DOI: 10.1016/j.eats.2017.06.013]
14. Brossard P, Le Roux G, Vasse B; Orthopedics, Traumatology Society of Western France (SOO). Acute quadriceps tendon rupture repaired by suture anchors: Outcomes at 7 years' follow-up in 25 cases. *Orthop Traumatol Surg Res.* 2017; **103(4)**: 597-601. [PMID: 28373140]; [DOI: 10.1016/j.otsr.2017.02.013]
15. Kindya MC, Konicek J, Rizzi A, Komatsu DE, Paci JM. Knotless Suture Anchor With Suture Tape Quadriceps Tendon Repair Is Biomechanically Superior to Transosseous and Traditional Suture Anchor-Based Repairs in a Cadaveric Model. *Arthroscopy.* 2017; **33(1)**: 190-198. [PMID: 27514943]; [DOI: 10.1016/j.arthro.2016.06.027]
16. Plessner S, Keilani M, Veksler G, et al. Clinical outcomes after treatment of quadriceps tendon ruptures show equal results independent of suture anchor or transosseous repair technique used - A pilot study. *PLoS One.* 2018; **13(3)**: e0194376. [PMID: 29554109]; [PMCID: PMC5858832]; [DOI: 10.1371/journal.pone.0194376]
17. Meyer Z, Ricci WM. Knee Extensor Mechanism Repairs: Standard Suture Repair and Novel Augmentation Technique. *J Orthop Trauma.* 2016; **30 Suppl 2**: S30-S31. [PMID: 27441933]; [DOI: 10.1097/BOT.0000000000000604]
18. Popov I, Ristić V, Maljanović M, Milankov V. Quadriceps tendon rupture - treatment results. *Med Pregl.* 2013; **66(11-12)**: 453-458. [PMID: 24575632]; [DOI: 10.2298/mpns1312453p]
19. McCormick F, Nwachukwu BU, Kim J, Martin SD. Autologous hamstring tendon used for revision of quadriceps tendon tears. *Orthopedics.* 2013; **36(4)**: e529-e532. [PMID: 23590798]; [DOI: 10.3928/01477447-20130327-36]
20. Rehman H, Kovacs P. Quadriceps tendon repair using hamstring, prolene mesh and autologous conditioned plasma augmentation. A novel technique for repair of chronic quadriceps tendon rupture. *Knee.* 2015; **22(6)**: 664-668. [PMID: 26003216]; [DOI: 10.1016/j.knee.2015.04.006]
21. Rocha de Faria JL, Barroso de Matos M, de Araújo Barros Cobra HA, et al. Surgical Treatment of Chronic Rupture of the Quadriceps Using a Modified Pulvertaft Weave Technique. *Arthrosc Tech.* 2019; **8(10)**: e1163-e1169. [PMID: 31921591]; [PMCID: PMC6950773]; [DOI: 10.1016/j.eats.2019.06.006]
22. Maffulli N, Papalia R, Torre G, Denaro V. Surgical Treatment for Failure of Repair of Patellar and Quadriceps Tendon Rupture With Ipsilateral Hamstring Tendon Graft. *Sports Med Arthrosc Rev.* 2017; **25(1)**: 51-55. [PMID: 28045874]; [DOI: 10.1097/JSA.0000000000000138]
23. Jarraya M, Diaz LE, Arndt WF, Roemer FW, Guermazi A. Imaging of patellar fractures. *Insights Imaging.* 2017; **8(1)**: 49-57. [PMID: 27905071]; [PMCID: PMC5265199]; [DOI: 10.1007/s13244-016-0535-0]
24. Henrichsen JL, Wilhem SK, Siljander MP, Kalma JJ, Karadsheh MS. Treatment of Patella Fractures. *Orthopedics.* 2018; **41(6)**: e747-e755. [PMID: 30321439]; [DOI: 10.3928/01477447-20181010-08]
25. Melvin JS, Mehta S. Patellar fractures in adults. *J Am Acad Orthop Surg.* 2011; **19(4)**: 198-207. [PMID: 21464213]; [DOI: 10.5435/00124635-201104000-00004]
26. Lazaro LE, Wellman DS, Pardee NC, et al. Effect of computerized tomography on classification and treatment plan for patellar fractures. *J Orthop Trauma.* 2013; **27(6)**: 336-344. [PMID: 22955333]; [DOI: 10.1097/BOT.0b013e318270dfe7]
27. Kakazu R, Archdeacon MT. Surgical Management of Patellar Fractures. *Orthop Clin North Am.* 2016; **47(1)**: 77-83. [PMID: 26614923]; [DOI: 10.1016/j.ocl.2015.08.010]
28. Müller EC, Frosch KH. Plattenosteosynthese bei Patellafrakturen Plate osteosynthesis of patellar fractures. *Oper Orthop Traumatol.* 2017; **29(6)**: 509-519. [PMID: 29071377]; [DOI: 10.1007/s00064-017-0522-8]
29. Braun W, Wiedemann M, Rüter A, Kundel K, Kolbinger S. Indications and results of nonoperative treatment of patellar fractures. *Clin Orthop Relat Res.* 1993; **(289)**: 197-201.
30. Wurm S, Bühren V, Augat P. Treating patella fractures with a locking patella plate - first clinical results. *Injury.* 2018; **49 Suppl 1**: S51-S55. [DOI: 10.1016/S0020-1383(18)30304-8]
31. LeBrun CT, Langford JR, Sagi HC. Functional outcomes after operatively treated patella fractures. *J Orthop Trauma.* 2012; **26(7)**: 422-426. [PMID: 22183197]; [DOI: 10.1097/BOT.0b013e318228c1a1]
32. Greenberg A, Kadar A, Drexler M, et al. Functional outcomes after removal of hardware in patellar fracture: are we helping our patients? *Arch Orthop Trauma Surg.* 2018; **138(3)**: 325-330. [PMID: 29185046]; [DOI: 10.1007/s00402-017-2852-2]
33. Siljander MP, Vara AD, Koueiter DM, Wiater BP, Wiater PJ. Novel Anterior Plating Technique for Patella Fracture Fixation. *Orthopedics.* 2017; **40(4)**: e739-e743. [PMID: 28632289]; [DOI: 10.3928/01477447-20170615-02]
34. Smith ST, Cramer KE, Karges DE, Watson JT, Moed BR. Early complications in the operative treatment of patella fractures. *J Orthop Trauma.* 1997; **11(3)**: 183-187. [PMID: 9181501]; [DOI: 10.1097/00005131-199704000-00008]
35. Tian Y, Zhou F, Ji H, Zhang Z, Guo Y. Cannulated screw and cable are superior to modified tension band in the treatment of transverse patella fractures. *Clin Orthop Relat Res.* 2011; **469(12)**: 3429-3435. [PMID: 21573937]; [PMCID: PMC3210283]; [DOI: 10.1007/s11999-011-1913-z]
36. Gao S, Zhang F, Gao T, Liu X, Zhang Z, Dai M. A novel technique of using a miniature plate in combination with tension band wiring to treat comminuted patellar fractures. *Medicine (Baltimore).* 2018; **97(15)**: e0311. [PMID: 29642160]; [PMCID: PMC5908579]; [DOI: 10.1097/MD.00000000000010311]
37. Sutton FS Jr, Thompson CH, Lipke J, Kettelkamp DB. The effect of patellectomy on knee function. *J Bone Joint Surg Am.* 1976; **58(4)**: 537-540.
38. Böstman O, Kiviluoto O, Nirhamo J. Comminuted displaced fractures of the patella. *Injury.* 1981; **13(3)**: 196-202. [DOI: 10.1016/0020-1383(81)90238-2]
39. Moore TB, Sampathi BR, Zamorano DP, Tynan MC, Scolaro JA. Fixed angle plate fixation of comminuted patellar fractures. *Injury.* 2018; **49(6)**: 1203-1207. [PMID: 29609972]; [DOI: 10.1016/j.injury.2018.03.030]
40. Taylor BC, Mehta S, Castaneda J, French BG, Blanchard C. Plating of patella fractures: techniques and outcomes. *J Orthop Trauma.* 2014; **28(9)**: e231-e235. [PMID: 24343252]; [DOI: 10.1097/BOT.0000000000000039]
41. Wild M, Fischer K, Hilsenbeck F, Hakimi M, Betsch M. Treating patella fractures with a fixed-angle patella plate-A prospective observational study. *Injury.* 2016; **47(8)**: 1737-1743. [PMID: 27354301]; [DOI: 10.1016/j.injury.2016.06.018]
42. Lorich DG, Warner SJ, Schottel PC, Shaffer AD, Lazaro LE, Helfet DL. Multiplanar Fixation for Patella Fractures Using a Low-Profile Mesh Plate. *J Orthop Trauma.* 2015; **29(12)**: e504-e510. [PMID: 26270460]; [DOI: 10.1097/BOT.0000000000000415]
43. Singer MS, Halawa AM, Adawy A. Outcome of low profile mesh plate in management of comminuted displaced fracture patella. *Injury.* 2017; **48(6)**: 1229-1235. [PMID: 28413065]; [DOI: 10.1016/j.injury.2017.03.026]
44. Dickens AJ, Salas C, Rise L, et al. Titanium mesh as a low-profile alternative for tension-band augmentation in patella fracture fixation: A biomechanical study. *Injury.* 2015; **46(6)**: 1001-1006.

- [PMID: 25769202]; [DOI: 10.1016/j.injury.2015.02.017]
45. Lorich DG, Fabricant PD, Sauro G, et al. Superior Outcomes After Operative Fixation of Patella Fractures Using a Novel Plating Technique: A Prospective Cohort Study. *J Orthop Trauma*. 2017; **31(5)**: 241-247. [PMID: 28166170]; [DOI: 10.1097/BOT.0000000000000787]
 46. Siljander M, Koueiter DM, Gandhi S, Wiater BP, Wiater PJ. Outcomes Following Low-Profile Mesh Plate Osteosynthesis of Patella Fractures. *J Knee Surg*. 2018; **31(9)**: 919-926. [PMID: 29381883]; [DOI: 10.1055/s-0038-1625958]
 47. Verbeek DO, Hickerson LE, Warner SJ, Helfet DL, Lorich DG. Low Profile Mesh Plating for Patella Fractures: Video of a Novel Surgical Technique. *J Orthop Trauma*. 2016; **30 Suppl 2**: S32-S33. [PMID: 27441934]; [DOI: 10.1097/BOT.0000000000000589]
 48. Gilmore JH, Clayton-Smith ZJ, Aguilar M, Pneumaticos SG, Giannoudis PV. Reconstruction techniques and clinical results of patellar tendon ruptures: Evidence today. *Knee*. 2015; **22(3)**: 148-155. [PMID: 25819155]; [DOI: 10.1016/j.knee.2014.10.007]
 49. Dan M, Parr W, Broe D, Cross M, Walsh WR. Biomechanics of the knee extensor mechanism and its relationship to patella tendinopathy: A review. *J Orthop Res*. 2018; **36(12)**: 3105-3112. [PMID: 30074265]; [DOI: 10.1002/jor.24120]
 50. Lanzi JT Jr, Felix J, Tucker CJ, et al. Comparison of the Suture Anchor and Transosseous Techniques for Patellar Tendon Repair: A Biomechanical Study. *Am J Sports Med*. 2016; **44(8)**: 2076-2080. [PMID: 27179054]; [DOI: 10.1177/0363546516643811]
 51. Ettinger M, Dratzidis A, Hurschler C, et al. Biomechanical properties of suture anchor repair compared with transosseous sutures in patellar tendon ruptures: a cadaveric study. *Am J Sports Med*. 2013; **41(11)**: 2540-2544. [PMID: 23982397]; [DOI: 10.1177/0363546513500633]
 52. Sherman SL, Black B, Mooberry MA, et al. Biomechanical Evaluation of Suture Anchor versus Transosseous Tunnel Patellar Tendon Repair Techniques. *J Knee Surg*. 2019; **32(8)**: 825-832. [PMID: 30189438]; [DOI: 10.1055/s-0038-1669790]
 53. Ode GE, Piasecki DP, Habet NA, Peindl RD. Cortical Button Fixation: A Better Patellar Tendon Repair? *Am J Sports Med*. 2016; **44(10)**: 2622-2628. [PMID: 27390345]; [DOI: 10.1177/0363546516651614]
 54. Schütte V, Schmidt-Hebbel A, Imhoff AB, Achtnich A. Patellarsehnenruptur: Internal Bracing und Augmentationstechnik [Patellar tendon ruptures: Internal bracing and augmentation technique]. *Oper Orthop Traumatol*. 2019; **31(1)**: 45-55. [PMID: 30683978]; [DOI: 10.1007/s00064-018-0585-1]
 55. Harato K, Kobayashi S, Udagawa K, et al. Surgical Technique to Bring Down the Patellar Height and to Reconstruct the Tendon for Chronic Patellar Tendon Rupture. *Arthrosc Tech*. 2017; **6(5)**: e1897-e1901. [PMID: 29430392]; [PMCID: PMC5799493]; [DOI: 10.1016/j.eats.2017.07.015]
 56. Lewis PB, Rue JP, Bach BR Jr. Chronic patellar tendon rupture: surgical reconstruction technique using 2 Achilles tendon allografts. *J Knee Surg*. 2008; **21(2)**: 130-135. [PMID: 18500064]; [DOI: 10.1055/s-0030-1247807]
 57. von Glinski A, Yilmaz E, Rausch V, Königshausen M, Schildhauer TA, Seybold D, Geßmann J. Semitendinosus autograft augmentation after bilateral patellar tendon re-rupture: a case report and technique note. *Eur J Orthop Surg Traumatol*. 2019; **29(6)**: 1347-1353. [PMID: 30900018]; [DOI: 10.1007/s00590-019-02420-8]
 58. Van der Bracht H, Verdonk R, Stuyts B. Augmentation of a patellar tendon repair with an autologous semitendinosus graft. *Acta Orthop Belg*. 2009; **75(3)**: 417-419.
 59. Jain S, Jain AK, Dhammi IK, Modi P. Neglected Patellar Tendon Rupture Treated by Trans-Osseous Encirclage Wire and Turn-O-Flap: Case Report. *J Orthop Case Rep*. 2014; **4(3)**: 5-8. [PMID: 27298970]; [PMCID: PMC4719328]; [DOI: 10.13107/jocr.2250-0685.183]
 60. Falconiero RP, Pallis MP. Chronic rupture of a patellar tendon: A technique for reconstruction with achilles allograft. *Arthroscopy*. 1996; **12(5)**: 623-626. [DOI: 10.1016/s0749-8063(96)90204-2]
 61. McNally PD, Marcelli EA. Achilles allograft reconstruction of a chronic patellar tendon rupture. *Arthroscopy*. 1998; **14(3)**: 340-344. [DOI: 10.1016/s0749-8063(98)70154-9]
 62. Kumar A, Rutherford-Davies J, Thorpe P, Newson A. Combined quadriceps lengthening (using an external ring fixator) and patellar tendon reconstruction (using a tendoachilles allograft) in a case of chronic patellar tendon rupture: A case report *Knee*. 2020 Mar; **27(2)**: 598-606. [PMID: 32014413]; [DOI: 10.1016/j.knee.2019.12.014]
 63. Bhargava SP, Hynes MC, and Dowell JK. Traumatic patella tendon rupture: early mobilisation following surgical repair. *Injury*. 2004; **35(1)**: 76-79. [DOI: 10.1016/s0020-1383(03)00069-x]
 64. Rougraff BT, Reeck CC, Essenmacher J. Complete quadriceps tendon ruptures. *Orthopaedics* 1996; **19(6)**: 509-514
 65. Hantes ME, et al. Better knee function after surgical repair of acute quadriceps tendon rupture in comparison to acute patellar tendon rupture. *Orthop Traumatol Surg Res*. 2019; **105(1)**: 119-123. [PMID: 30455100]; [DOI: 10.1016/j.otsr.2018.09.019]
 66. Chalha, Jorge, MD, PhD; Dephillipo, Nicholas. Open Repair of Quadriceps Tendon with Suture Anchors and Semitendinosus Tendon Allograft Augmentation. *Arthrosc Tech*. 2017; **6(6)**: e2071-32077. [PMID: 29348999]; [PMCID: PMC5766257]; [DOI: 10.1016/j.eats.2017.08.005]
 67. Beranger J-S, et al. Return to sport after early surgical repair of acute patellar tendon ruptures. *Orthop Traumatol Surg Res*. 2020; [PMID: 32179020]; [DOI: 10.1016/j.otsr.2020.01.010]
 68. Arsoy D, Donders J, Helfet D. Patella Fractures: Plating. In: *Operative Techniques: Orthopedic Trauma Surgery*, 2nd edition. Philadelphia, PA, 2019; 536-544
 69. Yang L, Yue-ping O, Wen YQ. Management of displaced comminuted patellar fracture with titanium cable cerclage. *The Knee*. 2010; **17(4)**: 283-6. [PMID: 20223675]; [DOI: 10.1016/j.knee.2010.02.005]
 70. Smith ST, Cramer KE, Karges DE, Watson JT, Moed BR. Early Complications in the Operative Treatment of Patella Fractures. *J Orthop Trauma*. 1997; **11(3)**: 183-187. [PMID: 9181501]; [DOI: 10.1097/00005131-199704000-00008]